



Original Research

Cryotherapy plus oral zinc sulfate versus cryotherapy plus placebo to treat common warts: A double blind, randomized, placebo-controlled trial^{☆,☆☆}



H. Mahmoudi, MD^{a,b}, S.Z. Ghodsi, MD^{a,b,*}, S. Tavakolpour^b, M. Daneshpazhooh, MD^{a,b}

^a Department of Dermatology, Razi Hospital, Tehran University of Medical Sciences, Tehran, Iran

^b Autoimmune Bullous Diseases Research Center, Tehran University of Medical Sciences, Tehran, Iran

ARTICLE INFO

Article history:

Received 11 April 2017

Received in revised form 11 August 2017

Accepted 18 September 2017

Keywords:

common wart
warts
zinc sulfate
cryotherapy
treatment

ABSTRACT

Background: Cutaneous warts are caused by a small group of specific types of human papillomaviruses. Cryotherapy is a highly effective treatment for patients with viral warts; however, it is a painful method and usually requires several treatment sessions. Zinc is a trace element with many proven effects on the immune system.

Objective: Our aim was to assess the efficacy and safety of oral zinc sulfate in the treatment and recurrence rate of common warts.

Methods: Eighty-three patients with common warts participated in this double-blind, randomized, placebo-controlled trial. In both groups, three sessions of liquid nitrogen cryotherapy were performed for up to 2 months with 3-week intervals. The treatment group (n = 45) received oral zinc sulfate capsules in a dose of 10 mg/kg per day up to 600 mg day. The control group (n = 38) was provided with placebo of similar appearance. Treatment continued for 2 months and the follow-up period lasted up to 6 months.

Results: Warts completely resolved in 26 patients in the treatment group (68.4%) and 23 patients in the placebo group (63.9%; $p = .68$). Three patients (7.9%) in the treatment group and six patients (16.6%) in the placebo group has a recurrence of the warts ($p = .19$).

Conclusion: According to our study, the addition of zinc to cryotherapy was not beneficial in the treatment of patients with common warts nor did it prevent recurrences.

© 2017 Published by Elsevier Inc. on behalf of Women's Dermatologic Society. This is an open access article under the CC BY-NC-ND license (<http://creativecommons.org/licenses/by-nc-nd/4.0/>).

Introduction

Papillomaviruses are a large group of DNA viruses that induce warts (zur Hausen, 1996). Cutaneous warts are caused by a small group of specific types of human papillomaviruses. "Common warts" are the most frequent clinical presentation of the cutaneous warts (Plunkett et al., 1999) with an overall prevalence of 20% in school children and a decline thereafter with patients' increasing age (Massing and Epstein, 1963).

No specific antiviral therapy is available to cure warts. Although spontaneous recovery often occurs, it usually takes a long time, even years, for warts to resolve (Kirnbauer et al., 2008). There are

several therapies for warts, but none that is uniformly effective in the elimination of the lesions and all have different adverse effects (Micali et al., 2004). Existing modalities focus primarily on the destruction or removal of visible lesions or induction of the immune system against infected cells. Cryotherapy with liquid nitrogen is one of the most effective treatments and destroys the warts by freezing the infected tissues. Treatment that is repeated every 3 weeks gives a 30% to 70% cure rate after 3 months for warts on the hands (Bourke et al., 1995).

Zinc is a trace element with a proven effect on the immune system and a deficiency causes reduced immune capacity and lymphopenia (Fraker, 1987). Zinc is considered an immunomodulator and has been used successfully to treat patients with skin diseases who have an altered immune response such as cutaneous leishmaniasis (Sharquie et al., 2001), erythema nodosum leprosum (Mahajan et al., 1994), alopecia areata (Lutz and Kreysel, 1990), and perifolliculitis capitis (Bern et al., 1985).

The role of oral zinc in the treatment of patients with cutaneous warts is controversial. A number of previous clinical reports have suggested that oral zinc sulfate can successfully treat cutaneous warts

[☆] Conflicts of interest: None.

^{☆☆} Funding sources: This study was approved by the Tehran University of Medical Sciences Ethics Committee and supported by a university grant.

* Corresponding Author.

E-mail address: ghodsisz@tums.ac.ir (S.Z. Ghodsi).

(Al-Gurairi et al., 2002; Mun et al., 2011; Yaghoobi et al., 2009). On the other hand, one study questioned this role (López-García et al., 2009). In this study, we used a combination of zinc sulfate and cryotherapy to evaluate any additive effect of zinc in the treatment and recurrence rate of common warts.

Methods

This study was a double-blind, randomized, placebo-controlled trial that was performed at Razi Hospital in Tehran, Iran from September 2011 to November 2012. Eighty-three patients were enrolled in the study.

The inclusion criteria for the study were patient age >7 years, more than two common warts, no history of systemic or iatrogenic immunosuppression, no use of medication or procedures for the treatment of warts within 6 months of the study, and not pregnant or currently breastfeeding. Patients were assigned to either the treatment or placebo group by simple randomization. All patients included in the study were informed of the treatment protocol and asked to sign an informed consent form. In the case of patients who were not of legal age, parents provided the consent on their behalf. The treatment was blinded to the patients, investigators, and pharmacist. Both products were similar in color, shape, and smell. The study was conducted in accordance with the Declaration of Helsinki.

Full patient history including age, sex, past medical and family history of disease, time since the warts first appeared, any previous treatment and/or systemic illnesses, sites and distribution of the warts, and any signs of zinc deficiency were recorded for each patient with a questionnaire.

Serum zinc was measured in all patients both at the beginning of the trial (baseline) and after discontinuation of the treatment (final) using the atomic absorption spectrophotometer assay method (Hitachi 902, Seoul, South Korea).

Patients in the treatment group received oral zinc sulfate in the form of 220 mg capsules (Al-havi, Tehran, Iran) in a dose of 10 mg/kg per day in three divided doses up to 600 mg/day. Patients in the placebo (control) group were given capsules of similar appearance that were filled with starch.

In both groups, liquid nitrogen cryotherapy was administered with a saturated, cotton-tipped applicator until an ice-ball formation had spread from the center to a margin of 2 mm around each wart

with a double freeze-thaw cycle. Cryotherapy was repeated at intervals of 3 weeks for up to 2 months. Cryotherapy and clinical assessments were performed by the same physician for all patients.

Due to the common digestive adverse effects of zinc sulfate, patients were recommended to take the drug with food and one glass of water or juice. If any drug adverse effect occurred, patients were recommended to stop the drug intake for 2 to 3 days. If the patient showed an adequate drug tolerance afterward, they were advised to keep taking the medication. Otherwise, they were told to discontinue the drug and excluded from the study.

The treatment trial lasted for 2 months and the follow-up period was up to 6 months. A cure was defined as the total elimination of all lesions and the appearance of any new warts in any location was considered a recurrence. With a statistically significant level of 0.05 and a statistical power of 80%, 40 patients in each group were needed.

The data analysis was performed with IBM SPSS Statistics for Windows (IBM Corp., Armonk, NY) Version 19. Standard deviation (SD) was calculated for means, and the comparisons were done by χ^2 , paired T-test, and ANOVA tests for rates, means, and groups, respectively. A p -value <.05 was considered statistically significant. A logistic regression test was used to calculate odds ratio.

Results

Eighty-three patients (40 male; 43 female) participated in the study. A total of 38 of 45 patients in the treatment group and 36 of 38 patients in placebo group completed the study (Fig. 1). The demographic and clinical data of patients are shown in Table 1. The patients were assigned randomly to the groups, and there were no significant difference between the two groups with regard to age, sex, location, mean number of warts, and duration of the disease. No symptoms or signs of zinc deficiency were observed.

At the end of the study, the serum zinc level had increased significantly in patients in the treatment group ($p < .001$) but the change in the placebo group was not significant (Table 1). Twenty-six patients (68.4%) in the treatment group and 23 patients (63.9%) in the placebo group showed a complete resolution of their warts with no significant difference ($p = .68$). There was no difference in the cure rate in each session of the cryotherapy between the two groups (Table 3). Local side effects such as hyperpigmentation, hypopigmentation, and scar formation were seen in both groups with no significant difference.

In the treatment group, there was a high frequency of gastrointestinal adverse effects such as nausea (68.89%), vomiting (17.77%), and epigastric pain (17.77%) in comparison with the placebo group. Seven patients (15.56%) in the treatment group discontinued the drug because of severe nausea, vomiting, and epigastric pain. In the placebo group, 2 patients (5.13%) discontinued the treatment due to gastrointestinal adverse effects and acute appendicitis (1 patient each).

The mean duration of the disease was 16.84 ± 12.91 months in patients who were cured and 24.17 ± 15.97 months in patients with treatment failure ($p = .03$). The mean counts of the lesions in patients who were cured were 6.55 ± 5.49 and 9.75 ± 4.19 in patients with treatment failure ($p = .04$).

Only three patients in the study had a zinc deficiency (i.e., below $72 \mu\text{g}/\text{dl}$ in male and $70 \mu\text{g}/\text{dl}$ in female patients). One patient was completely cured without any significant rise in serum zinc levels, another patient had treatment failure, and another patient did not complete the study. No significant differences were observed between the basic and final serum zinc levels in patients who were cured and those with treatment failure (Table 2). Nine patients had a recurrence during the 6-month follow-up period including three patients (7.9%) in the treatment group and six patients (16.6%) in the placebo group. The recurrence rate was higher in the placebo group although the difference was not significant ($p = .19$; Table 3).

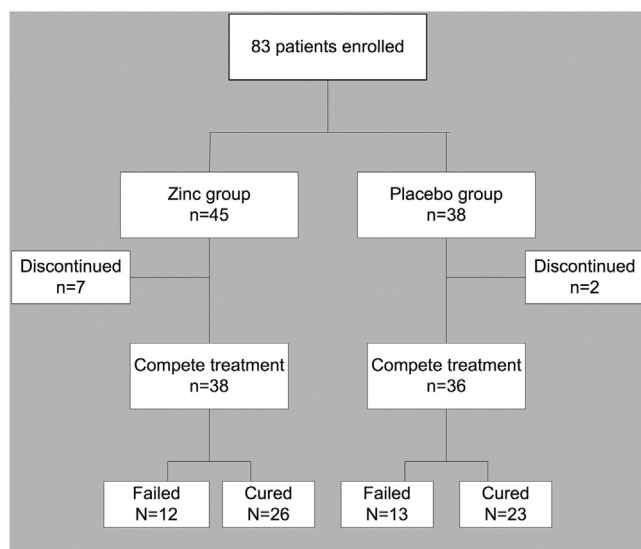


Fig. 1. Flowchart of study design and results

Table 1
Clinical characteristics and serum zinc level of the study population

	Treatment Group		Placebo Group	p Value
Mean age	45 ± 6.60		39 ± 7.47	.2
Sex	M: 24 (53.3%) F: 21 (46.7%)		M: 18 (46.2%) F: 21 (53.8%)	.5
Number of warts (mean)	7.34 ± 4.14		7.8 ± 6.29	.7
Mean zinc levels, (µg/dl)*				
Baseline	113.77 ± 20.50	<i>p</i> < .001	114.00 ± 21.76	<i>p</i> = .3
Final	129.23 ± 19.20		110.40 ± 17.01	
Disease duration (months)	21.9 ± 17.05		17.20 ± 12.97	.29

* Normal range: Male patient: 72–121 µg/dl; female patient: 70–115 µg/dl

Discussion

To the best of our knowledge, this is one of the few studies to evaluate the effectiveness of a destructive and immunomodulator modality in the treatment of common warts (Lu et al., 2012; Luk et al., 2006). Cryotherapy is one of the most effective treatments for warts but it is a painful procedure and has some adverse effects such as scarring and dyspigmentation (Micali et al., 2004). Zinc sulfate has many confirmed effects on immune response and infectious disease treatment, for example in toxoplasma retinochoroiditis (Avunduk et al., 2007).

Impairment of the immune system during zinc deficiency has been observed in previous studies. The main mechanism of immune dysfunctions that are caused by zinc deficiency is the decrease in gene expression of interleukin-2 (IL-2) and IL-2 receptor a (IL-2Ra) due to the decreased activation of nuclear factor-κB (NF-κB) in T helper cells. Decreased gene expression and generation of tumor necrosis factor-α (TNF-α), IL-1β and IL-8, reduced T-cell numbers, decreased ratio of type 1 to 2 T-helper cells with a reduced production of T-helper type 1 cytokines such as interferon-gamma are other mechanisms. Zinc is also an antioxidant and has antiinflammatory qualities (Avunduk et al., 2007; Hönscheid et al., 2009; Kaltenberg et al., 2010; Prasad, 2008).

In addition, polyclonal activation of the lymphocytes has been yielded by the addition of zinc to culture media. According to these data, the enforcement of the immune system of individuals with low levels of zinc and those with marginal or normal levels of zinc are possible (Wirth et al., 1989). Zinc is considered an immunomodulator and has been used successfully in the treatment of patients with skin diseases who have an altered immune system function (Fraker, 1986). Zinc is non-toxic and non-cumulative (Prasada, 1979).

There are controversial reports about the effectiveness of zinc sulfate in the treatment of patients with viral warts. Al-Gurairi et al. (2002) treated recalcitrant warts with oral zinc sulfate versus placebo with 86.9% clearance after 2 months. Another similar study was performed in Iran by Yaghoobi et al. (2009) and found similar results. In an open-label study in Korea, the effectiveness of oral zinc sulfate 10 mg/kg for 2 months in the treatment of patients with nongenital viral warts was assessed and 50% of patients showed a complete resolution (Mun et al., 2011). Sharma et al. (2014) reported the clearance of recalcitrant warts in a patient with epidermodysplasia verruciformis in 12 weeks with oral zinc (10 mg/kg/day). In addition, some evidence showed that a combination therapy of oral zinc sulfate with conventional treatments of vulvar warts appeared to reduce the relapse rate of genital warts (Akhavan et al., 2014). On the other hand, the results of a study in Mexico showed that zinc supplement was not superior to placebo in the treatment of patients with viral warts (López-García et al., 2009).

Our study did not show any difference in the complete resolution of the warts between patients who were treated with cryotherapy and zinc sulfate and those who were treated with cryotherapy and

placebo (68.4% vs 63.9% cure rate; *p* = .68). This finding supports the study by López-García et al. (2009) that showed that there was no superiority of zinc supplement to placebo.

There was no significant difference in basic serum zinc levels between patients in the treatment and placebo groups. Final zinc levels significantly increased in patients assigned to the treatment group (*p* < .001; Table 1), which is an encouraging document for the proper use of the drug by patients. Surprisingly, there was no significant difference in the basic, final, and rising of the serum zinc levels between patients who were cured and those that failed treatment (Table 2). This can be a questionable finding for the role of zinc in the treatment of common warts.

The recurrence rate during the 6-month follow-up period was lower in the treatment group (Table 3) but the difference was not significant (7.79% vs 16.67%, *p* = .19) and does not support the role of zinc sulfate in the prevention of recurrence of common warts. A larger sample size may change this finding.

Interestingly, our findings showed a significant relation between the duration of disease (*p* = .03; odds ratio [OR] = 1.05) and mean number of warts (*p* = .048; OR = 1.12) with response rate. Patients with a shorter disease duration and fewer lesions may have a better response so the duration and number of warts can be prognostic factors in response to the cryotherapy. A similar finding was seen in a study by Khaled et al. (2009). These findings can be somehow logical because wart is basically a self-limiting disease and long-standing lesions have less possibility to heal spontaneously. Also, patients with fewer warts may have a better immune reaction.

Some points are worth mentioning with regard to our study. Considering the different target population in our study compared with previous studies (i.e., common warts versus recalcitrant warts), it is possible that zinc may have some additional effects but only on recalcitrant warts (Al-Gurairi et al., 2002; Mun et al., 2011; Yaghoobi et al., 2009). Furthermore, zinc deficiency was reported in a significant percentage of patients with a good response to oral zinc sulfate in previous studies (Al-Gurairi et al., 2002; Mun et al., 2011; Yaghoobi et al., 2009). However, zinc deficiency was not a common finding in our

Table 2
Clinical characteristics and zinc levels of patients who were cured and those who failed treatment

	Cured Group	Failed Treatment Group	p Value
Mean zinc levels, (µg/dl)*			
Baseline	112.08 ± 18.71	118.63 ± 24.00	.16
Final	120.19 ± 18.34	121.68 ± 25.51	.24
Disease duration (months)	16.84 ± 12.91	24.17 ± 15.97	.03
Number of warts (mean)	6.55 ± 5.49	9.75 ± 4.19	.048
Sex	Male: 25 Female: 24	Male: 25 Female: 11	.69

* Normal range: Male: 72 to 121 µg/dl, Female: 70 to 115 µg/dl

Table 3
Cure and recurrence rates in the two study groups

	Treatment Group	Placebo Group	p Value
Cure rate	26 (68.42%)	23 (63.9%)	.68
Cure after first session of cryotherapy	3 (7.89%)	2 (5.56%)	.69
Cure after second session	8 (21.05%)	6 (16.67%)	.77
Cure after third session	15 (39.47%)	15 (42.67%)	1
New lesion after treatment	5 (13.16%)	4 (11.11%)	.78
Recurrence	3 (7.89%)	6 (16.67%)	.19

patients. Therefore, different results in our study could be due to differences in population and nutritional status.

Conclusions

The addition of oral zinc sulfate to the treatment of warts as a routine modality may not be justified for all patients because of a lack of proven efficacy, considerable gastrointestinal adverse effects, and long periods of treatment (i.e., 1 to 2 months). Zinc sulfate can be recommended for patients with recalcitrant warts or low or marginal levels of serum zinc.

References

Akhavan S, Mohammadi SR, Modarres Gillani M, Mousavi AS, Shirazi M. Efficacy of combination therapy of oral zinc sulfate with imiquimod, podophyllin or cryotherapy in the treatment of vulvar warts. *J Obstet Gynaecol Res* 2014;40:2110–3.

Al-Gurairi FT, Al-Waiz M, Sharquie KE. Oral zinc sulphate in the treatment of recalcitrant viral warts: Randomized placebo-controlled clinical trial. *Br J Dermatol* 2002;146:423–31.

Avunduk AM, Avunduk MC, Baltaci AK, Moqukoc R. Effect of melatonin and zinc on the immune response in experimental *Toxoplasma retinochoroiditis*. *Ophthalmologica* 2007;221:421–5.

Bern B, Venge P, Ohman S. Perifolliculitis capitis abscondens et suffodiens (Hoffman). Complete healing associated with oral zinc therapy. *Arch Dermatol* 1985;121:1028–30.

Bourke JF, Berth-Jones L, Hutchinson PE. Cryotherapy of common viral warts at intervals of 1, 2 and 3 weeks. *Br J Dermatol* 1995;132:433–6.

Fraker PJ. Interrelationship between zinc and immune function. *Fed Proc* 1986;45:1475.

Fraker PJ. Zinc deficiency and immune function. *Arch Dermatol* 1987;123:1699–701.

Hönscheid A, Rink L, Haase HT. Lymphocytes: A target for stimulatory and inhibitory effects of zinc ions. *Endocr Metab Immune Disord Drug Targets* 2009;9:132–44.

Kaltenberg J, Plum LM, Ober-Blöbaum JL, Hönscheid A, Rink L, Haase H. Zinc signals promote IL-2-dependent proliferation of T cells. *Eur J Immunol* 2010;40:1496–503.

Khaled A, Ben Romdhane S, Kharfi M, Zegloui F, Faza B, Kamoun MR. Assessment of cryotherapy by liquid nitrogen in the treatment of hand and feet warts. *Tunis Med* 2009;87:690–2.

Kirnbauer R, Lenz P, Okun M. Human Papillomavirus. In: Bologna JL, Jorizzo JL, Rapini RP. *Dermatology*. Callen JP, Horn TD, Mancini AJ, et al, editors. 2nd edition. Spain: Elsevier; 2008. p. 1183–98.

López-García DR, Gómez-Flores M, Arce-Mendoza AY, de la Fuente-García A, Ocampo-Candiani J. Oral zinc sulfate for unresponsive cutaneous viral warts: Too good to be true? A double-blind, randomized, placebo-controlled trial. *Clin Exp Dermatol* 2009;34:984–5.

Lu YG, Yang YD, Wu JJ, Lei X, Cheng QH, He Y, et al. Treatment of perianal condyloma acuminata with topical ALA-PDT combined with curettage: outcome and safety. *Photomed Laser Surg* 2012;30:186–90.

Luk NM, Tang WY, Tang NL, Chan SW, Wong JK, Hon KL, et al. Topical 5-fluorouracil has no additional benefit in treating common warts with cryotherapy: A single-centre, double-blind, randomized placebo-controlled trial. *Clin Exp Dermatol* 2006;31:394–7.

Lutz G, Kreysel HW. Selective changes in lymphocytic differentiation antigens in the peripheral blood of patients with alopecia areata treated with oral zinc. *Z Hautkr* 1990;65(132–4):137–8.

Mahajan PM, Jadhav VH, Patki AH, Jogaikar DG, Mehta JM. Oral zinc therapy in recurrent erythema nodosum leprosum: A clinical study. *Indian J Lepr* 1994;66:51–7.

Massing AM, Epstein WL. Natural history of warts: A two years study. *Arch Dermatol* 1963;87:306–10.

Micali G, Dalloligo F, Nasca MR, Tedeschi A. Management of cutaneous warts: An evidence-based approach. *Am J Clin Dermatol* 2004;5:311–7.

Mun JH, Kim SH, Jung DS, Ko HC, Kim BS, Kwon KS, et al. Oral zinc sulfate treatment for viral warts: An open-label study. *J Dermatol* 2011;38:541–5.

Plunkett A, Merlin K, Gill D, Zuo Y, Jolley D, Marks R. The frequency of common non-malignant skin conditions in adults in central Victoria, Australia. *Int J Dermatol* 1999;38:901–8.

Prasad AS. Zinc in human health: Effect of zinc on immune cells. *Mol Med* 2008;14:353–7.

Prasada A. Zinc in Human Nutrition. Boca Raton: CRC Press; 1979.

Sharma S, Barman KD, Sarkar R, Manjhi M, Garg VK. Efficacy of oral zinc therapy in epidermodysplasia verruciformis with squamous cell carcinoma. *Indian Dermatol Online J* 2014;5:55–8.

Sharquie KE, Najim RA, Farjow IB, Al-Timimi DJ. Oral zinc sulphate in the treatment of cutaneous leishmaniasis. *Clin Exp Dermatol* 2001;26:21–6.

Wirth JJ, Fraker PJ, Kierszenbaum F. Zinc requirement for macrophage function: Effect of zinc deficiency on uptake and killing of a protozoan parasite. *Immunology* 1989;68:114–9.

Yaghoobi R, Sadighha A, Baktash D. Evaluation of oral zinc sulfate effect on recalcitrant multiple viral warts: a randomized placebo-controlled clinical trial. *J Am Acad Dermatol* 2009;60:706–8.

zur Hausen H. Papillomavirus infection - A major cause of human cancers. *Biochim Biophys Acta* 1996;1288:55–78.