

*Images in Nephrology*  
(Section Editor: G.H. Neild)

## March hemoglobinuria-associated acute tubular injury

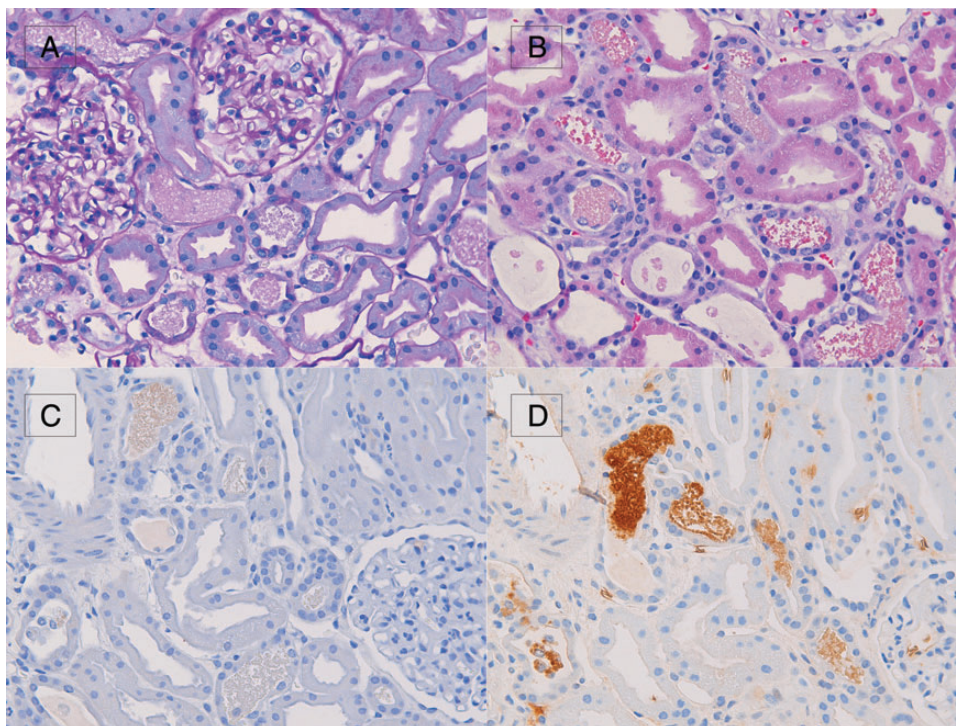
Mazdak A. Khalighi, Kammi J. Henriksen, Anthony Chang and Shane M. Meehan

Department of Pathology, University of Chicago, Chicago, IL, USA

Correspondence and offprint requests to: Mazdak A. Khalighi; E-mail: mazdak.khalighi@uchospitals.edu

A previously healthy 17-year-old African-American male presented with acute kidney injury after playing basketball without rest for 5–6 h. At presentation, his serum creatinine was 468.5  $\mu\text{mol/L}$  (5.3 mg/dL) with an estimated glomerular filtration rate (eGFR) of 17 mL/min/1.73 m<sup>2</sup> calculated by the four-variable modification of diet in renal disease study equation. He had no history of kidney disease and was not taking any medications. Serum creatine kinase was elevated at 2277 U/L (reference range: 9–185 U/L) and his unconjugated bilirubin was 75.2  $\mu\text{mol/L}$  (4.4 mg/dL). Hemoglobin was 133 g/L (13.3 g/dL) and a direct agglutination test was negative. Serum haptoglobin and hemoglobin electrophoresis studies were not done. Due to concern for rhabdomyolysis-associated acute tubular injury/necrosis, a kidney biopsy was performed.

Seventeen glomeruli were sampled and were histologically unremarkable. Proximal tubules showed marked attenuation of brush borders and epithelial cell flattening. Granular cast material was identified within distal tubular lumina, which stained weakly by periodic acid–Schiff (PAS) reagent (Figure 1A) and eosinophilic on the hematoxylin and eosin stain (Figure 1B). Immunohistochemical staining for myoglobin was negative (Figure 1C); however, hemoglobin A diffusely and strongly stained the cast material (Figure 1D). A Prussian blue histochemical stain was negative for hemosiderin deposition. No glomerular, tubular basement membrane or interstitial deposits were seen by immunofluorescence or electron microscopy. The biopsy was interpreted as acute tubular injury/necrosis with hemoglobin casts, suggestive of hemolysis-associated acute kidney injury.



**Fig. 1.** By light microscopy, distal tubules show granular cast material, which stains weakly by PAS reagent (A), and eosinophilic on the hematoxylin and eosin-stained section (B). The granular casts were negative upon immunohistochemical staining for myoglobin (C) but showed diffuse and strong positivity upon staining for hemoglobin A (D).

The patient was treated supportively with return to normal kidney function (eGFR > 90 mL/min/1.73 m<sup>2</sup>) 1 month after presentation. Due to the rapid recovery and absence of persistent hemolysis, it was felt that the hemoglobinuria was a result of exertion-related hemolysis.

Renal exposure to excess heme is a known cause of kidney injury and can occur in the setting of intravascular hemolysis (hemoglobinuria) and rhabdomyolysis (myoglobinuria) [1]. Uncommonly, hemoglobinuria can occur as a consequence of physical exertion and subsequent mechanical injury to erythrocytes. This phenomenon, referred to as 'march hemoglobinuria,' was first observed in military personnel in the nineteenth century and has since been reported in patients participating in activities with repetitive impact, including runners and percussionists [2–4]. Reports of hemolysis-associated kidney injury have almost exclusively focused on the accumulation of intracytoplasmic hemosiderin (hemosiderosis) within tubular cells, [5] which was absent in our case and is a feature of persistent and/or recurrent bouts of hemolysis and hemoglobinuria.

The differential diagnosis of acute tubular injury in the setting of excessive physical exertion includes hypovolemic acute tubular injury, rhabdomyolysis-associated acute tubular injury and hemolysis-associated injury. Hypovolemic acute tubular injury can show intratubular casts formed by the sloughing of cell cytoplasm into the tubular lumina; however, these casts fail to stain for both myoglobin and hemoglobin A. Rhabdomyolysis and hemolysis-associated tubular injury can both demonstrate intratubular hyaline

and granular casts, which appear identical on light microscopy. Immunohistochemical staining for myoglobin and hemoglobin A is required to separate these entities pathologically.

In summary, acute intravascular hemolysis can rarely occur in the setting of physical exertion and can result in toxic tubular injury with intratubular cast formation.

*Conflict of interest statement.* The authors have no financial interests or disclosures to report.

## References

1. Tracz MJ, Alam J, Nath KA. Physiology and pathophysiology of heme: implications for kidney disease. *J Am Soc Nephrol* 2007; 18: 414–420
2. Pollard TD, Weiss IW. Acute tubular necrosis in a patient with march hemoglobinuria. *N Engl J Med* 1970; 283: 803–804
3. Eichner ER. Runner's macrocytosis: a clue to footstrike hemolysis. Runner's anemia as a benefit versus runner's hemolysis as a detriment. *Am J Med* 1985; 78: 321–325
4. Caro XJ, Sutherland PW, Mitchell DB et al. Traumatic hemoglobinuria associated with conga drumming. *West J Med* 1975; 123: 141–144
5. Qian Q, Nath KA, Wu Y et al. Hemolysis and acute kidney failure. *Am J Kidney Dis* 2010; 56: 780–784

*Received for publication: 2.6.14; Accepted in revised form: 1.7.14*