

## Quadriceps tendon rupture

Subhadra Nori<sup>1,2</sup>

<sup>1</sup>Department of Rehabilitation Medicine, Icahn School of Medicine at Mount Sinai, <sup>2</sup>Department of Rehabilitation Medicine, Queens Health Network, Elmhurst and Queens Hospital Centers, USA

### ABSTRACT

Acute knee pain is a frequently encountered problem in the clinical settings. In 2003, American Orthopedic Association recorded that 19.4 million people visited a physician because of a knee problem. Knee pain due to injuries is increasing even among the older population, as a greater number of persons are participating in recreational activities. The quadriceps tendon rupture is not a common condition among acute causes of knee pain. However, it can be quite debilitating. The usual clinical presentation includes a middle-aged person presenting with a history of fall accompanied by swelling and inability to extend the knee. Providers who are faced with this clinical situation should be able to recognize this condition sooner than later. It is very important that precise clinical decisions be made, so as to achieve best outcomes. This article reviews the etiology, epidemiology, clinical presentation, differential diagnosis, and management of quadriceps tendon rupture.

**Keywords:** Patellar tendon, quadriceps tendon, rupture

### Introduction

The etiology of acute knee pain is quite variable and encompasses many structures including bones, ligaments, soft tissues, and menisci, while the differential diagnosis of chronic knee pain includes infection, arthritis, tumors and other space occupying lesions, acute knee pain particularly trauma is related to menisci ligaments, fractures and tendon rupture. We present a case of traumatic quadriceps tendon rupture and discuss the etiology, diagnostic testing and management.

### Case Report

A middle aged male with a history of hypertension presented to our institution with a history of fall on the street. He was unable to straighten his leg and bear weight on the right lower extremity

Physical examination revealed a heavy set male in moderate distress. He reported pain level of an 8 on visual analogue scale.

**Address for correspondence:** Dr. Subhadra Nori, Department of Rehabilitation Medicine, Elmhurst Hospital Center, Broadway 79-01 Queens N.Y 11373 USA.  
E-mail: noris@nychhc.org

There was anterior knee swelling. The range of motion (ROM) of the knee was limited in both flexion and extension. Manual muscle testing was limited due to pain. The popliteal pulse and dorsalis pedis pulses were intact. There was a visible gap in the quadriceps tendon about 2–3 cm above the patella. The patient was unable to stand or extend his knee due to pain.

### Clinical course

A tentative diagnosis of quadriceps tendon rupture was made. The patient had a magnetic resonance imaging (MRI) which confirmed the diagnosis. He had repair of the quadriceps tendon and was placed in a long leg cast. After undergoing acute rehabilitation for 8 days, he was discharged. At 3-month follow-up, the patient was walking with a cane.

### Discussion

Quadriceps tendon rupture is not commonly seen in clinical practice. Complete ruptures can be very disabling and occur during a fall while the person is trying to prevent the fall. This occurs because during flexion the knee is under maximum tensile stress and when an attempt is made to extend the knee to stand, the tendon strength can not withstand the stress. This causes it

This is an open access journal, and articles are distributed under the terms of the Creative Commons Attribution-NonCommercial-ShareAlike 4.0 License, which allows others to remix, tweak, and build upon the work non-commercially, as long as appropriate credit is given and the new creations are licensed under the identical terms.

For reprints contact: reprints@medknow.com

**How to cite this article:** Nori S. Quadriceps tendon rupture. J Family Med Prim Care 2018;7:257-60.

#### Access this article online

##### Quick Response Code:



**Website:**  
www.jfmpc.com

**DOI:**  
10.4103/jfmpc.jfmpc\_341\_16

to break. Clinical findings include acute pain, inability to actively extend the knee, and a suprapatellar gap. Ambulation is not possible due to inability to extend the knee and excruciating pain.

### Anatomy

The quadriceps muscle is composed of 4 muscle bellies: the rectus femoris, vastus medialis, lateralis, and intermedius. This tendon inserts into the patella. The quadriceps muscle is the main extensor of the knee. Three major vascular arcades, i.e., medial, lateral, and peripatellar arcades provide blood supply to the quadriceps tendon. A relatively hypovascular zone exists about 1–2 cm superior to the patella, thus making it more susceptible to injury.<sup>[1]</sup>

### Epidemiology

The incidence of complete quadriceps tendon ruptures is reported as rare. One study from the UK reported it as 1.37/100,000/year, with a mean age of 50.5 in men and 51.7 in women.<sup>[2]</sup> Patellar tendon ruptures occur in younger than 40 and quadriceps ruptures in older than 40 group. The extensor mechanism injuries are more likely to occur as a sequela to preexisting pathology, which is usually of the overuse type as tendonitis, microtears, and poor structural mechanism.

Ninety-one percent of the quadriceps and 95.5% of the patellar tendon ruptures occurred in males between 61 years for quadriceps tendon rupture and 39.5 years for patellar tendon rupture. Body mass index varied between  $30.0 \pm 6.05 \text{ kg/m}^2$  for quadriceps tendon rupture.

Frequently associated medical comorbidities are rheumatoid arthritis, SLE, gout, chronic renal Failure, secondary hyperparathyroidism, diabetes mellitus, and peripheral vascular disease [Table 1].<sup>[3]</sup>

**Table 1: Predisposing factors**

Chronic microtrauma (tendinopathy): Also known as jumper’s knee
Prior therapeutic intervention
Direct injection of steroids (for treatment of jumper’s knee)
Previous ACL repair
Systemic illness
Chronic renal failure/uremia
Diabetes mellitus
RA
SLE
CPPD
Hyperparathyroidism
Steroid use
Quinolone use
Collagen gene variants
Gout
Obesity

RA: Rheumatoid arthritis; SLE: Systemic lupus erythematosus; CPPD: Calcium pyrophosphate deposition disease; ACL: Anterior cruciate ligament

Fluoroquinolones have also been associated with tendon ruptures. Although the exact mechanism is not clear. Corticosteroid injections in and around tendons and joints have been known to alter the collagen composition and ability to heal.

Spontaneous ruptures were reported in 3.2% of cases. The most common sites of tear were noted between 1 cm and 2 cm of the superior pole of the patella and in older people, at the osseotendinous junction.

Tears of quadriceps occur through the rectus tendon at its insertion into the proximal pole of patella. Tears usually occur a few centimeters proximal to the superior pole of the patella. A small piece of rectus tendon may avulse.

In 65% of people, it is seen at the insertion of the patellar tendon over the patella and in 25% at the quadriceps tendon insertion on the patella and in 10% patellar insertion over the tibial tuberosity.<sup>[4]</sup>

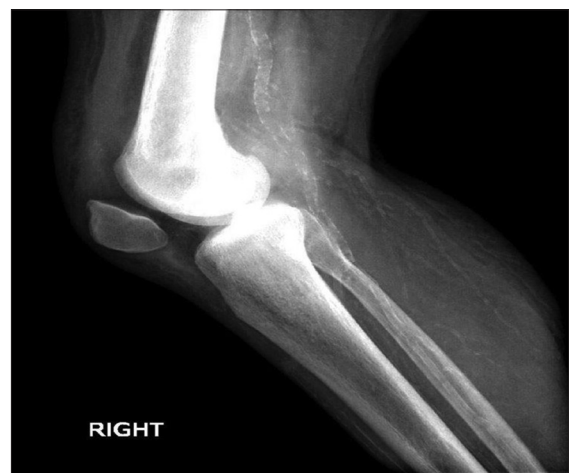Ruptures of the patellar tendon usually occur in the inferior pole of the patella and can also cause avulsion of bone.

The deferential diagnosis of acute knee pain is outlined in Table 2.

### Imaging

Radiographs may show inferior displacement of the patella along with bony avulsion in quadriceps tendon rupture and superior displacement in patella tendon rupture [Figure 1]. MRI examination may be helpful in detecting other intraarticular pathology [Figure 2]. Parfitt and Petrie propose that all suspected patients should either proceed directly to MRI or be initially assessed by ultrasound (US), followed by an MRI to eliminate false positive diagnoses.<sup>[5]</sup>

Bedside utility of US has become easier and less expensive than MRI. Quad tendon is 6–11 mm thick with linearly oriented

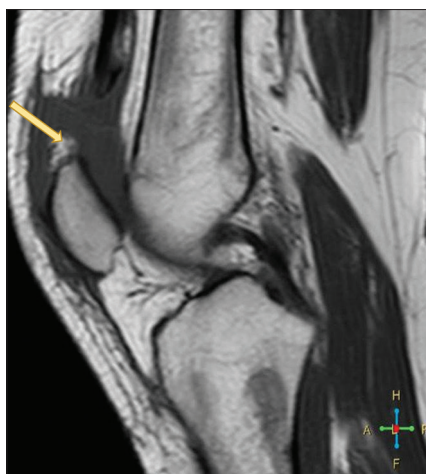

**Figure 1:** X-ray showing migration of patella due to quadriceps tendon rupture, case courtesy of <http://radiopedia.org/>. From the case <http://radiopedia.org/cases/11858>

**Table 2: Differential diagnosis of acute knee pain**

Diagnosis	History	Physical examination	Plain film	MRI or US	Electromyography
Tendinosis	Insidious onset of pain on activity	Normal findings	May be normal	MRI negative US may show reduction in echogenicity and blurring	Negative
Partial rupture	Acute onset of pain, relatively minor trauma	Patient able to extend knee	May be normal	MRI positive may show minor changes	Negative
Complete rupture	Acute onset of pain, relatively minor trauma	Patient unable to extend knee or walk Area of depression in the tendon to palpation	Migration of patella superiorly or inferiorly depending on quad rupture or patellar tendon rupture	MRI positive Dark area representing blood US shows hypochoic area	Negative
Meniscal tear	Acute onset of pain, with trauma symptoms	Positive Lachman's test	May be negative	MRI positive for defects in the meniscus medial or lateral horn	Negative
Cruciate ligament tear	Acute onset of pain, with trauma	Positive drawer test	May be negative	MRI positive shows defects of US may be unhelpful	Negative

MRI: Magnetic resonance image; US: Ultrasound



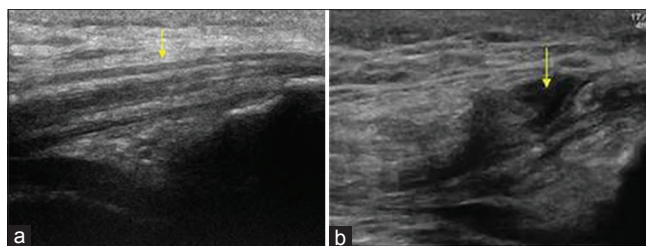
**Figure 2:** Magnetic resonance imaging of quadriceps tendon rupture. Yellow arrow pointing to the gap between the tendon and its insertion on the patella. <http://radiopaedia.org/cases/quadriceps-tendon-rupture-3>. Case courtesy of Dr. Ahmed Abd Rabou, Radiopaedia.org, rID: 22644

homogeneous echoes extending through the length of the tendon [Figure 3a]. With complete tears a hypo echoic area separating the tendon from the bone is seen. This is due to the hematoma. A focal hypoechoic area represents a partial tear. In complete tears, fiber continuity is lost and is replaced by intratendinous fluid [Figure 3b].<sup>16]</sup>

## Management

Partial ruptures are managed by evacuation of the hemarthrosis to reduce pain and tenderness followed by rest, ice, compression, and anti-inflammatory medication. Knee is immobilized in full extension for about 6 weeks, followed by progressive knee ROM and strengthening in therapy. For complete ruptures, open repair and reconstruction is required. Early repair is recommended to avoid retraction and atrophy of quad muscle.<sup>7]</sup>

Gradual progression to weight-bearing is advocated.<sup>18,9]</sup>



**Figure 3:** (a) Ultrasound of normal homogeneous fibrillary pattern of the quadriceps tendon (yellow arrow) (<http://www.ultrasoundcases.info>) (b) Ultrasound of rupture of quad tendon yellow arrow pointing to hematoma. Quadriceps tendon rupture longitudinal. ID:/34262-Afbeelding2.jpg (<http://www.ultrasoundcases.info>) The Netherlands

## Chronic ruptures

Repeated chronic ruptures can be challenging due to scar formation and tendon retraction. Primary approximation and reconstruction with hamstring grafts have been recommended.<sup>110]</sup>

## Outcomes of surgical repair for complete tears

Patients generally report satisfactory results following their surgical repair.

Worst results were noted in delayed repairs. Reported complications included heterotopic ossifications in 6.9% of patients, deep venous thrombosis or pulmonary embolism in 2.5%, superficial infection in 1.2%, and deep infection in 1.1%. It appears that the type of surgical repair does not influence the clinical results. The overall rate of rerupture was 2%.

## Conclusions

Knee injuries can account for 19.4 million visits/year. Complete quadriceps tendon ruptures are uncommon injuries, usually resulting from indirect trauma, in middle-aged men more than women. Early diagnosis and prompt repair is crucial, to obtain

optimal results. Good to excellent functional results are usually achieved. Patients with associated comorbidities such as DM and CRF may be particularly susceptible to complications, which include deep vein thrombosis, pulmonary embolism, and rerupture.

### Financial support and sponsorship

Nil.

### Conflicts of interest

There are no conflicts of interest.

### References

1. Yepes H, Tang M, Morris SF, Stanish WD. Relationship between hypovascular zones and patterns of rupture of the quadriceps tendon. *J Bone Joint Surg Am.* 2008;90:2135-41
2. Clayton RAE, Court-Brown CM. The epidemiology of musculoskeletal tendinous and ligamentous injuries. *Injury* 2008;39:1338-44.
3. Karistinos A, Paulos LE. "Ciprofloxacin-induced" bilateral rectus femoris tendon rupture. *Clin J Sport Med* 2007;17:406-7.
4. Ferreti A. Epidemiology of jumper's knee. *Sports Med* 1986;3:289-95.
5. Perfitt JS, Petrie MJ, Blundell CM, Davies MB. Acute quadriceps tendon rupture: A pragmatic approach to diagnostic imaging. *Eur J Orthop Surg Traumatol* 2014;24:1237-41.
6. Orlandi D, Corazza A, Arcidiacono A, Messina C, Serafini G, Sconfienza LM, *et al.* Ultrasound-guided procedures to treat sport-related muscle injuries. *Br J Radiol* 2016;89:20150484.
7. Ramseier LE, Werner CM, Heinzelmann M. Quadriceps and patellar tendon rupture. *Injury* 2006;37:516-9.
8. O'Shea K, Kenny P, Donovan J, Condon F, McElwain JP. Outcomes following quadriceps tendon ruptures. *Injury.*2002;33:257-260.
9. Konrath GA, Chen D, Lock T, *et al.* Outcomes following repair of quadriceps tendon ruptures. *J Orthop Trauma.* 1998;12:273-9.
10. Hak DJ, Sanchez A, Trobisch P. Quadriceps tendon injuries. *Orthopedics* 2010;33:40-6.