

# Knee Anterolateral Ligament Reconstruction With Knotless Soft Anchor: Shallow Fixation Prevents Tunnel Convergence



Timothée Mesnier, M.D., Marie Cavaignac, M.D., Vincent Marot, M.D.,  
Nicolas Reina, M.D., Ph.D., and Etienne Cavaignac, M.D., Ph.D.

**Abstract:** We describe an independent anterolateral ligament reconstruction technique using the gracilis tendon that can be added to any type of anterior cruciate ligament (ACL) reconstruction procedure. No additional tunnels are drilled. The dual-strand graft is attached to the bone cortex with a nonmetallic, knotless anchor using minimally invasive incisions. For the ACL reconstruction, the semitendinosus is attached to the femur with an ENDOBUTTON and to the tibia with a BioComposite interference screw. The ACL remnant is preserved to improve ligamentization, and the ACL graft is pedicled to the tibia to encourage its vascularization.

Several techniques have been described for anatomic reconstruction of the anterolateral ligament (ALL).<sup>1</sup> All require additional tunnels. Drilling several adjacent tunnels for anterior cruciate ligament (ACL) and ALL reconstruction can be a challenging procedure, with a high risk of convergence.<sup>2</sup> The following technique is our primary procedure for simultaneous ACL and ALL reconstruction. Patients who suffered an ACL tear with anterior instability associated with a grade 2 and 3 pivot shift and/or ALL deficiency confirmed by ultrasound analysis<sup>3-6</sup> undergo this combined procedure: tripled or quadrupled semitendinosus graft for ACL reconstruction; anatomic ALL reconstruction using the gracilis tendon folded in 2 strands, secured with a knotless soft anchor (Fig 1) and no additional tunnels drilled.

## Surgical Technique (With Video Illustration)

### Patient Positioning

An overview of knee ALL reconstruction with knotless soft anchor is described in Video 1. The patient is placed supine on the operating table in the standard arthroscopy position, with a lateral post proximal to the knee at the level of the tourniquet and 2 foot rolls at 90° and 120° flexion. After anesthesia, the bony landmarks of Gerdy's tubercle, the fibular head, and the lateral epicondyle are located by palpation and marked (Figs 2 and 3). An ultrasound machine (SonoSite; GE Healthcare, Milwaukee, WI) can be used to confirm the position of the bony landmarks and explore the ALL.<sup>3,4</sup> This ultrasound analysis allows for short percutaneous incisions to be made exactly at the desired location.

### Graft Harvesting

A standard vertical 2-cm incision is made medial to the anterior tibial tuberosity. The semitendinosus and gracilis tendons are harvested with an open tendon stripper, then cleaned of their fat and muscle residue and vincula attachment. Hyperflexion provides better access to the most proximal vincula.<sup>7</sup> The gracilis is cut close to its tibial insertion. The semitendinosus is kept attached to tibia, thereby improving the graft's fixation and vascularity.<sup>8</sup> Once harvested, the semitendinosus is evaluated to determine whether an 8-, 9-, or 10-mm graft diameter with a 12-cm length can be obtained. The semitendinosus graft will be prepared and looped with the ACL TightRope RT implant (Arthrex, Naples,

From the Department of Orthopedic Surgery and Trauma (T.M., V.M., N.R., E.C.), Pierre-Paul Riquet Hospital; Clinique rive Gauche (M.C.), and Institut de Recherche Riquet (I2R) (N.R., E.C.), Toulouse, France.

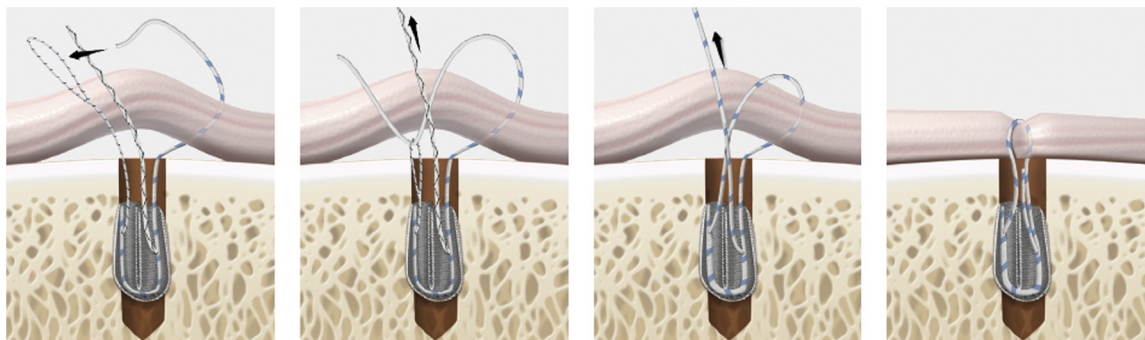
The authors report the following potential conflicts of interest or sources of funding: E.C. is a paid consultant for Arthrex. Full ICMJE author disclosure forms are available for this article online, as supplementary material.

Received August 25, 2021; accepted November 22, 2021.

Address correspondence to Etienne Cavaignac, M.D., Ph.D., 1 Place Baylac, 31059 Toulouse, France. E-mail: [cavaignac.etienne@gmail.com](mailto:cavaignac.etienne@gmail.com)

© 2021 THE AUTHORS. Published by Elsevier Inc. on behalf of the Arthroscopy Association of North America. This is an open access article under the CC BY-NC-ND license (<http://creativecommons.org/licenses/by-nc-nd/4.0/>). 2212-6287/211235

<https://doi.org/10.1016/j.eats.2021.11.024>



**Fig 1.** Illustration of how the knotless anchor is used for anterolateral ligament reconstruction.

FL) only after drilling the bone tunnels to ensure accurate length adjustments.<sup>9</sup> Once looped, the graft size can be adjusted if its diameter ends up being too large. Both tendons are soaked in a vancomycin solution before implantation.<sup>10</sup>

### ACL Reconstruction

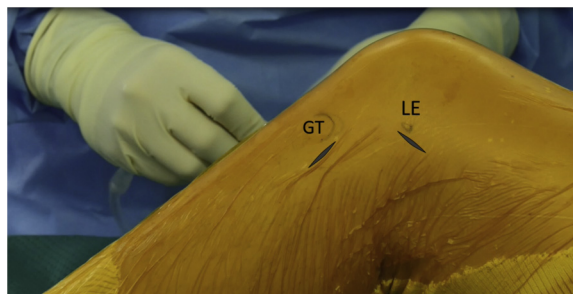
After minimal notch debridement, the ACL remnant is preserved at its tibial attachment to encourage proprioception, vascularization, and ligamentization of the graft.<sup>11-14</sup> ACL reconstruction is performed first, with the 4-strand semitendinosus graft kept pedicled.<sup>8,9</sup> A complete tibial tunnel is drilled from the hamstring incision with an outside-in guide aimed at the center of the ACL remnant. Then, an inside-out guide is used to drill a 15-mm long femoral tunnel in a diameter that matches that of the graft.<sup>15</sup>

The distance between tibial insertion of the ST graft and the bottom of the femoral socket is measured using a traction suture. The suture is passed from distal to proximal through the tibial and femoral tunnels. The proximal tip of the suture is locked at the proximal margin of the femoral socket, and forceps are clamped onto the distal part of the suture at the ST tibial insertion (Fig 4). The distance between the forceps and the proximal margin of the suture is equal to the distance between the graft's tibial insertion and the proximal

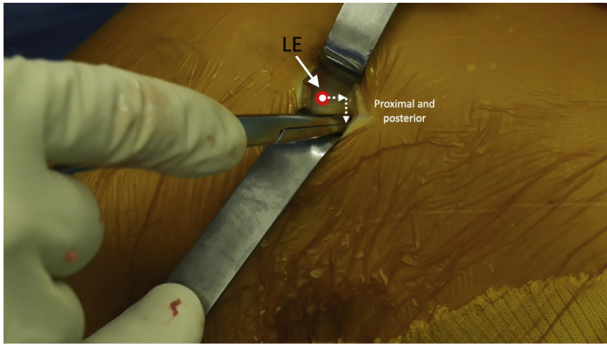
end of the femoral socket.<sup>9</sup> The graft is prepared 5 mm shorter than the measured distance to obtain adequate graft tensioning. A pen is used to mark the previously measured graft length minus 0.5 cm. A second pen mark is placed 4 cm from the tibial insertion to obtain a minimum length of 10 cm for the tripled or quadrupled graft portion (Fig 5). The graft is tripled or quadrupled over an ACL TightRope RT implant (Arthrex) between these 2 pen marks, and the looped graft is sutured to itself (Fig 6). The ACL graft is passed into the tunnels only after drilling the ALL tunnel; this prevents damaging the ENDOBUTTON by accidentally drilling it and ensures there is no convergence between the tunnels.<sup>9</sup>

### ALL Reconstruction

Before fixation of the ACL graft, 2 incisions are made, one just posterior and proximal to the lateral epicondyle and the other midway between Gerdy's tubercle and the fibular head. Starting at the proximal incision, the fascia lata is incised proximal and posterior to the lateral epicondyle. The arthroscope is introduced into the anteromedial portal to view the ACL femoral tunnel. Then, using a 1.8-mm Knotless FiberTak Soft Anchor (Arthrex), a 2.6-mm × 35-mm tunnel is drilled through the cannula into the femoral cortex while using the arthroscope to ensure the ALL and ACL tunnels do



**Fig 2.** Bony landmarks for anterolateral ligament reconstruction (GT, Gerdy's tubercle, LE, lateral epicondyle).

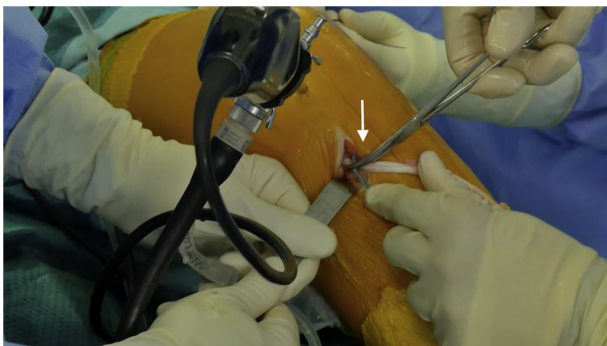


**Fig 3.** Entry point for the proximal anterolateral ligament tunnel. (LE, lateral epicondyle.)

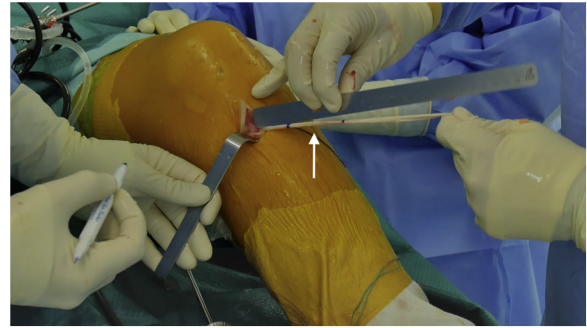
not converge (Fig 7). While holding the cannula at the same position, the anchor is passed into it and then impacted into the tunnel. The cannula is removed, and firm traction is applied to the anchor's strands to ensure satisfactory fixation.

The ACL graft is then passed from distal to proximal, the TightRope implant (Arthrex) is secured on the femoral cortex, and the graft is tightened with a Bio-Composite interference screw (Arthrex) on the tibial side in 30° flexion. We used a screw of the same diameter as the graft.

A Kelly clamp is introduced through the proximal incision under the fascia lata and superficial to the lateral collateral ligament, towards the distal incision. The gracilis tendon is folded into 2 and pulled with the clamp from distal to proximal, with the 2 free ends hanging distally. The anchor's fixation suture is passed through the loop of the ALL graft (Fig 8). This fixation suture is passed through the anchor using the shuttle suture. Traction is applied on the fixation suture to secure the proximal part of the graft on the femoral cortex. With the knee in full extension and neutral rotation, the distal part of the graft is tightened and



**Fig 4.** Measuring the distance between tibial insertion of semitendinosus tendon graft and bottom of femoral socket.



**Fig 5.** ACL graft is marked and prepared so it is 5 mm shorter than the measured distance. (ACL, anterior cruciate ligament.)

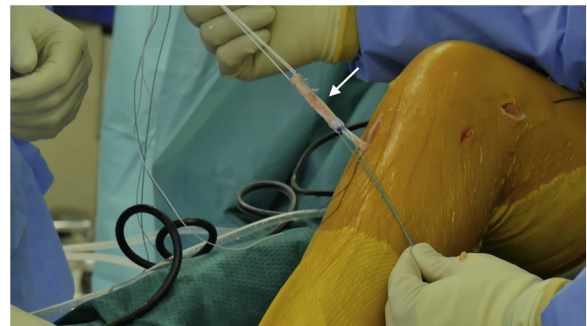
secured with another FiberTak anchor positioned posterior to Gerdy's tubercle (Fig 9). The free end of the graft is cut flush to the anchor. Tips and pearls of the surgical technique are listed in Table 1.

### Postoperative Rehabilitation

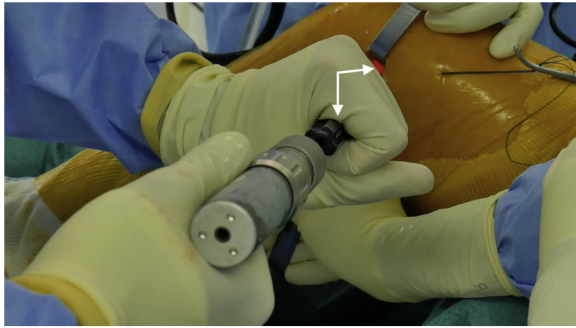
All patients are operated on an outpatient basis. Our routine ACL rehabilitation program is started on the first postoperative day, entailing full weight-bearing and progressive exercises to regain range of motion and quadriceps function. A gradual return to sports is generally allowed starting at 4 months for nonpivoting sports, 6 months for noncontact pivoting sports, and 8 to 9 months for contact pivoting sports, after isokinetic tests and functional evaluation.

### Discussion

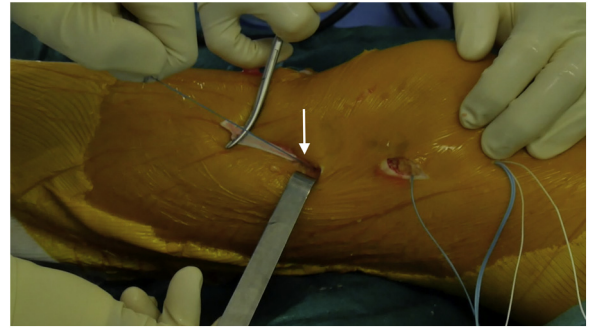
In this article, we describe an independent ALL reconstruction technique that does not require drilling additional tunnels or the use of metal-fixation devices. According to recent studies, ALL injury happens concurrently with ACL rupture in 46% to 79% of cases.<sup>16-18</sup> The role of the ALL in controlling internal



**Fig 6.** ACL graft is looped and sutured to itself over ENDO-BUTTON and traction suture. (ACL, anterior cruciate ligament.)



**Fig 7.** Drilling of anterolateral ligament anchor tunnel through cannula into femoral cortex (entry point shown in Fig 3).



**Fig 9.** Distal anterolateral ligament graft is tensioned and attached to tibial cortex with a second anchor.

tibial rotation and thus its involvement in rotational stability have encouraged surgeons to perform combined ACL and ALL reconstruction. Those techniques appear to have excellent result, especially in young patients participating in high-intensity pivot sports. Furthermore, combined ACL and ALL reconstruction is associated with a significantly lower occurrence of graft failure and an increased survival rate of medial meniscal repairs.<sup>19-22</sup>

ALL reconstruction is most often performed with iliotibial band or gracilis tendon.<sup>23</sup> At our facility, combined ACL and ALL reconstruction is performed in 80% of our primary cases. Advantages and limitations of our technique are listed in Table 2. We prefer using the hamstring tendons with an autologous dual-strand gracilis for the ALL graft. This technique does not require preoperative planning or preparation of the gracilis. Its length is always sufficient and it has suitable biomechanical properties for ALL reconstruction; this preserves the fascia lata and its contribution in controlling rotational stability.<sup>24,25</sup> Since the ALL technique is independent, it is compatible with all ACL outside-in or inside-out techniques. Also, it allows surgeons to decide intraoperatively whether to carry out a

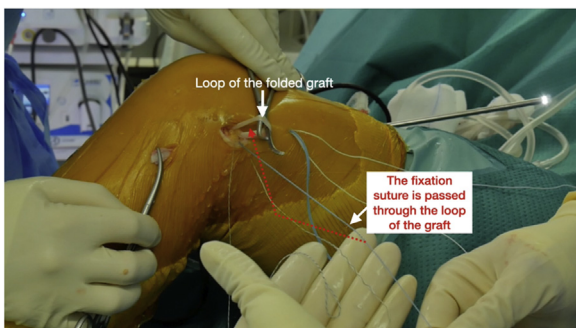
combined ACL and ALL reconstruction, for example if a RAMP lesion or other concomitant injury is discovered.<sup>21</sup>

This technique also has minimal impact on the bone stock. For the ALL reconstruction, only a 2.6- × 35-mm tunnel is needed to impact the anchor into the femoral cortex. The graft is attached to the cortical bone both in the femur and the tibia. It has been shown that cortical attachment provides satisfactory graft incorporation.<sup>26,27</sup> No additional tunnels are drilled, thereby minimizing the risk of tunnel convergence. ACL and ALL tunnel convergence can occur in 67% of cases and become a major issue if a weak femoral attachment causes the reconstructed ACL to be inefficient.<sup>2</sup>

In addition, the fact that the anchor is knotless provides surgeons with fast and simple fixation technique that produces minimal tissue congestion under the skin in the anterolateral area of the knee. Finally, this anchor is not metallic; thus, there is no artifact on magnetic resonance imaging, which simplifies future imaging of the knee.

## Acknowledgments

The authors are grateful to Joanne Archambault, Ph.D., for English-language assistance.



**Fig 8.** Fixation suture is passed through loop of proximal anterolateral ligament graft.

**Table 1.** Tips and Pearls

- Combination of pivot-shift testing under anesthesia and ultrasound analysis of the ALL are valuable decision aids to set the indication for a combined ACL and ALL procedure
- Hyperflexion while harvesting the graft helps to view and cut the proximal vincula
- Tendon grafts are soaked in a vancomycin solution
- ACL graft is passed into the tunnels only after drilling the ALL tunnel to ensure there is no convergence between tunnels

ACL, anterior cruciate ligament; ALL, anterolateral ligament.

**Table 2.** Advantages and Limitations

## Advantages

- Preservation of ACL remnant to improve ligamentization
- ACL graft is pedicled to tibia to encourage vascularization
- Intraoperative verification of no tunnel convergence
- Knotless fixation of the ALL graft
- ALL and ACL graft techniques are independent
- Nonmetallic fixation
- Minimally invasive incisions

## Limitations

- Both semitendinosus and gracilis grafts are needed
- Additional implant cost

ACL, anterior cruciate ligament; ALL, anterolateral ligament.

## References

- DePhillipo NN, Cinque ME, Chahla J, Geeslin AG, LaPrade RF. Anterolateral ligament reconstruction techniques, biomechanics, and clinical outcomes: A systematic review. *Arthroscopy* 2017;33:1575-1583. <https://doi.org/10.1016/j.arthro.2017.03.009>.
- Smeets K, Bellemans J, Lamers G, et al. High risk of tunnel convergence during combined anterior cruciate ligament and anterolateral ligament reconstruction. *Knee Surg Sports Traumatol Arthrosc* 2019;27:611-617. <https://doi.org/10.1007/s00167-018-5200-3>.
- Cavaignac E, Laumond G, Reina N, et al. How to test the anterolateral ligament with ultrasound. *Arthrosc Tech* 2018;7:e29-e31. <https://doi.org/10.1016/j.eats.2017.08.046>.
- Cavaignac E, Faruch M, Wytrykowski K, et al. Ultrasonographic evaluation of anterolateral ligament injuries: Correlation with magnetic resonance imaging and pivot-shift testing. *Arthroscopy* 2017;33:1384-1390. <https://doi.org/10.1016/j.arthro.2017.01.040>.
- Cavaignac E, Wytrykowski K, Reina N, et al. Ultrasonographic identification of the anterolateral ligament of the knee. *Arthroscopy* 2016;32:120-126. <https://doi.org/10.1016/j.arthro.2015.07.015>.
- Cavaignac E, Wytrykowski K, Murgier J, Reina N, Chiron P, Faruch M. Regarding "Editorial Commentary: Ultrasound barely beats magnetic resonance imaging in knee anterolateral ligament evaluation ... but does this change the treatment of the anterior cruciate ligament-deficient knee?". *Arthroscopy* 2017;33:1918-1919. <https://doi.org/10.1016/j.arthro.2017.08.278>.
- Reina N, Abbo O, Gomez-Brouchet A, Chiron P, Moscovici J, Laffosse J-M. Anatomy of the bands of the hamstring tendon: How can we improve harvest quality? *Knee* 2013;20:90-95. <https://doi.org/10.1016/j.knee.2012.06.003>.
- Papachristou G, Nikolaou V, Efstathopoulos N, et al. ACL reconstruction with semitendinosus tendon autograft without detachment of its tibial insertion: A histologic study in a rabbit model. *Knee Surg Sports Traumatol Arthrosc* 2007;1:1175-1180. <https://doi.org/10.1007/s00167-007-0374-0>.
- Sonnery-Cottet B, Freychet B, Murphy CG, Pupim BHB, Thauinat M. Anterior cruciate ligament reconstruction and preservation: The single-anteromedial bundle biological augmentation (SAMBBA) technique. *Arthrosc Tech* 2014;3:e689-e693. <https://doi.org/10.1016/j.eats.2014.08.007>.
- Pérez-Prieto D, Torres-Claramunt R, Gelber PE, Shehata TMA, Pelfort X, Monllau JC. Autograft soaking in vancomycin reduces the risk of infection after anterior cruciate ligament reconstruction. *Knee Surg Sports Traumatol Arthrosc* 2016;24:2724-2728. <https://doi.org/10.1007/s00167-014-3438-y>.
- Lee BI, Kim BM, Kho DH, Kwon SW, Kim HJ, Hwang HR. Does the tibial remnant of the anterior cruciate ligament promote ligamentization? *Knee* 2016;23:1133-1142. <https://doi.org/10.1016/j.knee.2016.09.008>.
- Takazawa Y, Ikeda H, Kawasaki T, et al. ACL Reconstruction preserving the ACL remnant achieves good clinical outcomes and can reduce subsequent graft rupture. *Orthop J Sports Med* 2013;1:2325967113505076. <https://doi.org/10.1177/2325967113505076>.
- Mifune Y, Ota S, Takayama K, et al. Therapeutic advantage in selective ligament augmentation for partial tears of the anterior cruciate ligament: Results in an animal model. *Am J Sports Med* 2013;41:365-373. <https://doi.org/10.1177/0363546512471614>.
- Takahashi T, Kimura M, Hagiwara K, Ohsawa T, Takeshita K. The effect of remnant tissue preservation in anatomic double-bundle ACL reconstruction on knee stability and graft maturation. *J Knee Surg* 2019;32:565-576. <https://doi.org/10.1055/s-0038-1660513>.
- Cavaignac E, Marot V, Faruch M, et al. Hamstring graft incorporation according to the length of the graft inside tunnels. *Am J Sports Med* 2018;46:348-356. <https://doi.org/10.1177/0363546517733472>.
- Faruch Bilfeld M, Cavaignac E, Wytrykowski K, et al. Anterolateral ligament injuries in knees with an anterior cruciate ligament tear: Contribution of ultrasonography and MRI. *Eur Radiol* 2018;28:58-65. <https://doi.org/10.1007/s00330-017-4955-0>.
- Claes S, Luyckx T, Vereecke E, Bellemans J. The Segond fracture: A bony injury of the anterolateral ligament of the knee. *Arthroscopy* 2014;30:1475-1482. <https://doi.org/10.1016/j.arthro.2014.05.039>.
- Van Dyck P, Clockaerts S, Vanhoenacker FM, et al. Anterolateral ligament abnormalities in patients with acute anterior cruciate ligament rupture are associated with lateral meniscal and osseous injuries. *Eur Radiol* 2016;26:3383-3391. <https://doi.org/10.1007/s00330-015-4171-8>.
- Helito CP, Camargo DB, Sobrado MF, et al. Combined reconstruction of the anterolateral ligament in chronic ACL injuries leads to better clinical outcomes than isolated ACL reconstruction. *Knee Surg Sports Traumatol Arthrosc* 2018;26:3652-3659. <https://doi.org/10.1007/s00167-018-4934-2>.
- Sonnery-Cottet B, Saithna A, Cavalier M, et al. Anterolateral ligament reconstruction is associated with significantly reduced ACL graft rupture rates at a minimum follow-up of 2 years: A prospective comparative study of 502 patients from the SANTI study group. *Am J Sports Med* 2017;45:1547-1557. <https://doi.org/10.1177/0363546516686057>.

21. Sonnery-Cottet B, Saithna A, Blakeney WG, et al. Anterolateral ligament reconstruction protects the repaired medial meniscus: A comparative study of 383 anterior cruciate ligament reconstructions from the SANTI study group with a minimum follow-up of 2 years. *Am J Sports Med* 2018;46:1819-1826. <https://doi.org/10.1177/0363546518767659>.
22. Lee DW, Kim JG, Cho SI, Kim DH. Clinical outcomes of isolated revision anterior cruciate ligament reconstruction or in combination with anatomic anterolateral ligament reconstruction. *Am J Sports Med* 2019;47:324-333. <https://doi.org/10.1177/0363546518815888>.
23. Hewison CE, Tran MN, Kaniki N, Remtulla A, Bryant D, Getgood AM. Lateral extra-articular tenodesis reduces rotational laxity when combined with anterior cruciate ligament reconstruction: A systematic review of the literature. *Arthroscopy* 2015;31:2022-2034. <https://doi.org/10.1016/j.arthro.2015.04.089>.
24. Wytrykowski K, Swider P, Reina N, et al. Cadaveric study comparing the biomechanical properties of grafts used for knee anterolateral ligament reconstruction. *Arthroscopy* 2016;32:2288-2294. <https://doi.org/10.1016/j.arthro.2016.03.004>.
25. Godin JA, Chahla J, Moatshe G, et al. A Comprehensive reanalysis of the distal iliotibial band: quantitative anatomy, radiographic markers, and biomechanical properties. *Am J Sports Med* 2017;45:2595-2603. <https://doi.org/10.1177/0363546517707961>.
26. Cavaignac E, Mesnier T, Marot V, et al. Effect of lateral extra-articular tenodesis on anterior cruciate ligament graft incorporation. *Orthop J Sports Med* 2020;8:2325967120960097. <https://doi.org/10.1177/2325967120960097>.
27. Tan H, Wang D, Lebaschi AH, et al. Comparison of bone tunnel and cortical surface tendon-to-bone healing in a rabbit model of biceps tenodesis. *J Bone Joint Surg Am* 2018;100:479-486. <https://doi.org/10.2106/JBJS.17.00797>.