

Acute lymphoid leukemia presenting with superior vena cava syndrome

Mohammad Emami Ardestani, Firouzeh Moeinzadeh¹

Departments of Pulmonology, ¹Internal Medicine, School of Medicine, Isfahan University of Medical Sciences, Isfahan, Iran

When superior vena cava (SVC) compress or obstructed by internal or external pressure, we encounter to SVC syndrome. The cause of this compression is malignant or benign. Although the widespread use of permanent central venous access catheters coupled with the improved success of chemotherapy has increased the incidence of SVC syndrome not caused by direct tumor infiltration (non-malignant SVC syndrome) but SVC syndrome may be a sign of advanced malignancy. In this report, we present a 30-year-old man with lymphoma that present with SVC syndrome at presentation. With chemotherapy, patient was recovered from signs and symptoms.

Key words: Acute lymphoid leukemia, adriamycine, dexamethasone regimen, hyper cyclophosphamide, superior vena cava syndrome, vincristin

INTRODUCTION

Clinical manifestation of superior vena cava syndrome (SVC syndrome) results from complete or partial obstruction of the SVC.^[1] The SVC carries approximately one-third of the venous return to the heart and collects blood from the arms, head, and upper chest to the heart. When the SVC is obstructed, blood flows through a collateral vascular network to the lower body and the inferior vena cava or the azygus vein. Therefore, obstruction below or at the level of azygus vein results blood bypassing from superficial venous system.^[2] During several weeks venous collaterals dilate sufficiently to accommodate the blood flow of the SVC.^[3] However, if the obstruction occur above the level of azygus vein, SVC bypasses and no clinical manifestation of syndrome occur.^[4]

Like other veins in body, the SVC has a thin wall without any muscles in the walls. Therefore, any compression of the vein results in increasing in pressure inside the vein. Symptoms depend on the acuity of SVC obstruction and collateral development. Facial, neck and bilateral upper extremity swelling are the most common presenting symptom. Dypnea, hoarseness, cough and orthopnea indicate airway obstruction.^[5] Head fullness, lethargy and syncope are suggesting cerebral edema. Symptoms develop over a period of 2 weeks in approximately a third of patients, and over longer periods in other cases Physical signs include plethora, swelling of neck or chest veins and tackypnea. Rarely, cyanosis, Horner's syndrome and a paralyzed vocal cord may also be present.^[6]

Although infectious causes of SVC syndrome included syphilitic and tuberculosis, but these etiologic factors are rare in these years. The most common etiology of SVC syndrome is malignant disease and most common malignancies, including non-small-cell lung cancer (in 50% of patients), small-cell lung cancer (approximately 25% of patients), lymphoma, and metastatic lesions (each approximately 10% of patients).^[7,8] Currently, obstruction of the SVC caused by thrombosis or non-malignant condition's accounts for approximately 35% of cases, reflecting the increased use of long-term central venous catheters or permanent pacing electrodes.^[9]

CASE REPORT

A 30-year-old man was admitted to Alzahra hospital, Isfahan, Iran in January, 2012, because of dyspnea and facial edema.

The patient had been well until 4 days before admission, when sudden onset dyspnea and orthopnea developed. He was afebrile and without sore throat. He reported any weight loss during the previous months. Medications included Brome hexin syrup, Theophylin and antihistamins without any effects.

On examination, the blood pressure was 120/80 mm Hg, the pulse 80 beats per min, the temperature 37°C, the respiratory rate 16 breaths per minute, the oxygen saturation 92% while the patient was breathing ambient air, and the weight 80 kg. The patient was

Address for correspondence: Dr. Firouzeh Moeinzadeh, Department of Internal Medicine, Isfahan University of Medical Sciences Isfahan Iran.
E-mail: moinzade@resident.mui.ac.ir

Received: 07-10-2012; **Revised:** 04-12-2012; **Accepted:** 15-12-2012

using intercostal muscles of chest wall during respiration. A variceal vein was seen on upper chest and neck. The remainder of the examination was normal.

Results of a complete blood count blood levels of urea nitrogen, albumin, total and direct bilirubin, creatine kinase, prothrombin time (PT), activated partial thromboplastin time (aPTT), international normalized ratio (INR),

aspartate aminotransferase and arterial blood gas were normal. A urinalysis was normal. An electrocardiogram showed sinus rhythm at a rate of 90 beats per min, without any problem. In echocardiography left ventricular ejection fraction was 55% and other finding was normal. In analysis, PaO₂ and PH were normal (60 mmHg, 7.42 respectively). A chest radiograph was done as Figure 1. Thoracic Computed tomography (CT) with Intravenous contrast performed as illustrate in Figure 2. In order to reducing his respiratory symptoms and improving respiratory distress, the patient received intravenous Corticosteroid (Dexamethasone 8 mg 3 times a day for 3 days.). Transthoracic mediastinal biopsy was done and in pathologic report lymphoblastic lymphoma was reported. Immunohistochemistry revealed leukocyte common antigen (LCA) and Terminal deoxynucleotidyl transferase (TdT) positive.

Treatment with hyper cyclophosphamide, vincristin, adriamycine, dexamethasone (CVAD) regimen^[10,11] done and respiratory symptoms resolved after 5 days completely. Patient was selected for bone marrow transplantation.

DISSCUSION

The SVC syndrome, occurs in approximately 15,000 persons in the United States each year.^[2] If the syndrome occurs after the use of intravascular devices, diagnosis of the cause is straightforward. In other situations imaging

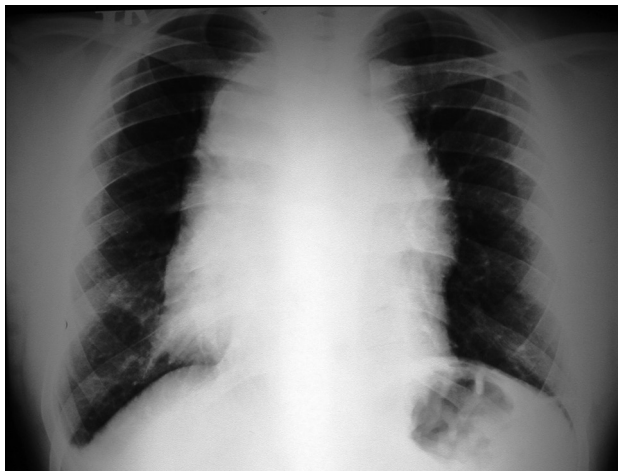

Figure 1: Chest X-ray of patient in arrival day

with CT scanning of chest with intravascular media made diagnosis correctly.

Initial management of patient with SVC syndrome includes supportive measures such as providing supplemental oxygen and elevating the head of the bed. Other treatments like diuretic therapy for reducing the intravascular volume, or a short course of parenteral steroids (dexamethasone, 4 mg every 6 h) to decrease edema and tumor burden are controversies. Several treatments have been introduced for SVC syndrome depending on the underlying disease like thrombolytic therapy or stenting in thrombosis of SVC in patients that SVC damaged in introducing intravascular devices.^[9,10,12] Mainstem of treatments in SVC syndrome induce malignancies is chemotherapy and radiotherapy after definite tissue diagnosis via CT scan-guided biopsy of mediastinal mass. Surgical bypass grafting is infrequently used to treat the SVC syndrome.^[2]

In malignant cause of SVC syndrome, untreated symptom reduces life expectancy less than 30 days. However, treated cases expectancy depends on type of malignancy and applying proper therapy like chemotherapy. In our case, after chemotherapy introduced, symptoms and signs of disease disappear and patient arrives to complementary treatments.

REFERENCES

1. Silversti G, Jeti J. Clinical aspects of lung cancer. Murray and Nadel's Textbook of respiratory medicine. 5th ed. Saunders: Philadelphia; 2010. p. 1116-39.
2. Wilson LD, Detterbeck FC, Yahalom J. Clinical practice. Superior vena cava syndrome with malignant causes. N Engl J Med 2007;356:1862-9.
3. Kim HJ, Kim HS, Chung SH. CT diagnosis of superior vena cava

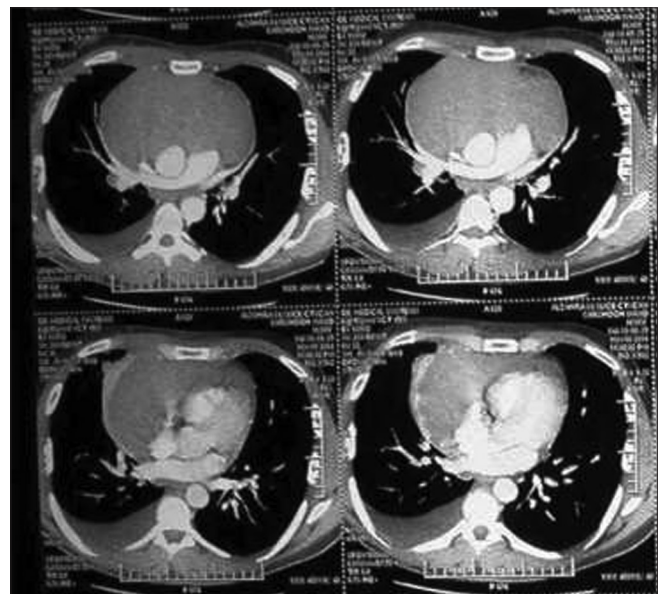


Figure 2: Chest CT scan of patient

- syndrome: Importance of collateral vessels. *AJR Am J Roentgenol* 1993;161:539-42.
4. Markman M. Diagnosis and management of superior vena cava syndrome. *Cleve Clin J Med* 1999;66:59-61.
 5. Roberts J, Kaiser L. Acquired lesions of the mediastinum: Benign and malignant. In: Fishman A, editor. *Fishman's pulmonary diseases and disorders*. 4th ed. New York. Mc GrawHill; 2008. p. 1611-2.
 6. Wan JF, Bezjak A. Superior vena cava syndrome. *Emerg Med Clin North Am* 2009;27:243-55.
 7. Rice TW, Rodriguez RM, Barnette R, Light RW. Prevalence and characteristics of pleural effusions in superior vena cava syndrome. *Respirology* 2006;11:299-305.
 8. Detterbeck FC, Parsons AM. Thymic tumors. *Ann Thorac Surg* 2004;77:1860-9.
 9. Abbasi M, Soltani G, Karamroudi A, Javan H. Superior vena cava syndrome following central venous cannulation. *Iran Cardiovasc Res J* 2009;3:172-4.
 10. Kantarjian H, Thomas D, O'Brien S, Cortes J, Giles F, Jeha S, *et al.* Long-term follow-up results of hyperfractionated cyclophosphamide, vincristine, doxorubicin, and dexamethasone (Hyper-CVAD), a dose-intensive regimen, in adult acute lymphocytic leukemia. *Cancer* 2004;101:2788-801.
 11. Azadbakht S, Moeinzadeh F, Mehrzad V, Alamsamimy M, Tazhibi M, Ashrafi F. Evaluating the feasibility of prescribing hyper-CVAD regimen in adult acute lymphoblastic leukemia. *J Isfahan Med Sch* 2012;30:1-8.
 12. Schifferdecker B, Shaw JA, Piemonte TC, Eisenhauer AC. Nonmalignant superior vena cava syndrome: Pathophysiology and management. *Catheter Cardiovasc Interv* 2005;65:416-23.

How to cite this article: Ardestani ME, Moeinzadeh F. Acute lymphoid leukemia presenting with superior vena cava syndrome. *J Res Med Sci* 2013;18:80-82.

Source of Support: Nil, **Conflict of Interest:** None declared.