

# Comparative evaluation of ultrasound guided supraclavicular and infraclavicular subclavian venous catheterizations in adult patients

Vikas Saini, Amburu Vamsidhar, Tanvir Samra, Sameer Sethi, B. N. Naik

Department of Anesthesia, Post Graduate Institute of Medical Education and Research, Sector 12, Chandigarh, India

## Abstract

**Background and Aims:** Ultrasound-guided subclavian vein cannulation has two approaches: supraclavicular and infraclavicular. The aim of this study was to compare the ease of cannulation by recording the puncture time of the subclavian vein with the two approaches in adult patients.

**Material and Methods:** This study was approved by our institutional ethics committee, and a written informed consent was obtained from the patients. This prospective randomized trial recruited patients aged 18 to 80 years with definite indications of subclavian vein cannulation. Real-time in-plane ultrasound-guided technique was used, and the subclavian vein was punctured at the junction of the brachiocephalic and IJV in supraclavicular approach (SC) and in oblique axis below the border of the clavicle in infraclavicular approach (IC).

**Results:** A total of 96 patients were randomly allocated equally into two groups of 48 each, but only 45 patients in each group could be successfully cannulated. Median puncture times were comparable; 15 (9–39) s in SC and 21 (5–80) s in IC group. The first attempt success rate was 82.2% and 62.2%, and the mean total access time was  $99.11 \pm 34.66$  s and  $103.44 \pm 50.27$  s in SC and IC approaches, respectively and were comparable. The attempts of needle puncture were significantly higher in IC approach ( $1.40 \pm 0.54$  vs  $1.20 \pm 0.46$  in SC approach;  $P = 0.04$ ). The complication rates were comparable and less than 5%.

**Conclusion:** Ease of cannulation of the subclavian vein using ultrasound-guided supraclavicular and infraclavicular approach is comparable as no statistically significant difference is noted in the puncture time and first-attempt success rate. The increased number of needle punctures reported in our study with the IC approach did not translate to an increased complication rate.

**Keywords:** Infraclavicular approach, subclavian vein cannulation, supraclavicular approach, ultrasound guidance

## Introduction

Technological advances in ultrasound (US) imaging have facilitated US-guided subclavian venous cannulations and encouraged researchers to describe various new approaches in a different subset of patients. Subclavian vein cannulation can be performed using the supraclavicular (SC) or infraclavicular (IC) approach.<sup>[1]</sup> The advantages of the

supraclavicular approach are a well-defined insertion landmark (the clavi-sternomastoid angle); a shorter skin-to-vein distance; a larger target area; a straighter path to the superior vena cava; less proximity to the lung, and fewer complications of pleural or arterial puncture. Byon *et al.*<sup>[2]</sup> and Prasad *et al.*<sup>[3]</sup> compared real-time US-guided supraclavicular vs infraclavicular approaches of subclavian vein (SCV) cannulation in pediatric patients and adult patients, respectively

Address for correspondence: Dr. Tanvir Samra,  
Department of Anesthesia, Post Graduate Institute of Medical  
Education and Research, Sector 12, Chandigarh - 160 012, India.  
E-mail: drtanvirsamra@yahoo.co.in

This is an open access journal, and articles are distributed under the terms of the Creative Commons Attribution-NonCommercial-ShareAlike 4.0 License, which allows others to remix, tweak, and build upon the work non-commercially, as long as appropriate credit is given and the new creations are licensed under the identical terms.

For reprints contact: WKHLRPMedknow\_reprints@wolterskluwer.com

Access this article online	
Quick Response Code:	Website: <a href="https://journals.lww.com/joacp">https://journals.lww.com/joacp</a>
	DOI: 10.4103/joacp.JOACP_400_20

**How to cite this article:** Saini V, Vamsidhar A, Samra T, Sethi S, Naik BN. Comparative evaluation of ultrasound guided supraclavicular and infraclavicular subclavian venous catheterizations in adult patients. *J Anaesthesiol Clin Pharmacol* 2022;38:411-6.

Submitted: 04-Jul-2020

Revised: 04-Jan-2021

Accepted: 07-Apr-2021

Published: 24-Feb-2022

and reported a significantly shorter puncture time and lower incidence of puncture attempts with the supraclavicular approach.

We conducted this study with the primary aim to compare the time to puncture the subclavian vein using ultrasound-guided supraclavicular and infraclavicular approaches in adult patients. The secondary objectives of this study were to compare the total time taken for cannulation, first attempt success rate, quality of needle visualization, and the complication rates.

## Material and Methods

This prospective randomized trial was approved by the Institutional Ethics Committee, NK/1777/ MD/10149-50 dated 7-8-2015. Written informed consent was taken from all the study participants and the trial was registered at ClinicalTrials.gov(NCT02925715).

The patients aged 18–80 years belonging to American Society of Anesthesiology (ASA) physical status (PS) I–IV with a definitive indication for central venous catheterization were enrolled. The patients with a history of prior catheterization at the same site, infection at the puncture site, contralateral pneumothorax, trauma to the clavicle and the upper ribs, distorted anatomy of the neck (burns), cervical spine injury, known vascular abnormality, coagulopathy, and more than three attempts at needle puncture were excluded. The patients were randomized equally into two groups of 48 patients each based on the technique used for subclavian vein cannulation; US-guided supraclavicular (SC) or US-guided infraclavicular (IC) approach. Randomization was done using random number tables, and allocation was done using the sealed envelope technique. The anesthesiologist attempting the cannulation and the investigator recording the data could not be blinded.

After confirming the fasting status of the patient, a preprocedural ultrasound scanning was done in the preoperative room with a portable software-controlled, MicroMaxx ultrasound system (SonoSite Inc, Bothell, Washington, USA) with a 13–6 MHz, 38 mm broadband linear array transducer HFL38/13–6 MHz (SonoSite Inc, Bothell, Washington, USA). The patency and diameter of the vessel were measured with the patient in the supine position. Scan time was noted and defined as the time from probe placement on the skin to the visualization of the vessel.

After shifting the patient in the operation theatre (OT), routine monitors were attached, (electrocardiography, pulse oximetry, and noninvasive blood pressure), and the patient was administered general anesthesia. The skin over the puncture

site was prepared with betadine and draped using sterile precautions. The patient was then positioned supine with a sandbag between the shoulder blades. The transducer was covered with ultrasonic gel and inserted into a sterile probe cover. All the anesthesiologists who performed the cannulation had at least 5 years of experience in central venous catheter placement.

### Probe positioning for supraclavicular approach

The linear array probe was placed perpendicular to the neck, 2 cm above the supraclavicular fossa, and lateral to the medial head of the sternocleidomastoid muscle. A short-axis view of the internal jugular vein (IJV) was obtained close to the carotid artery, and the probe was moved caudally towards the supraclavicular fossa. It was gently rotated, so that it was aligned parallel to the clavicle to obtain a view of the subclavian vein forming the brachiocephalic trunk after joining the IJV [Figure 1].

### Probe positioning for infraclavicular approach

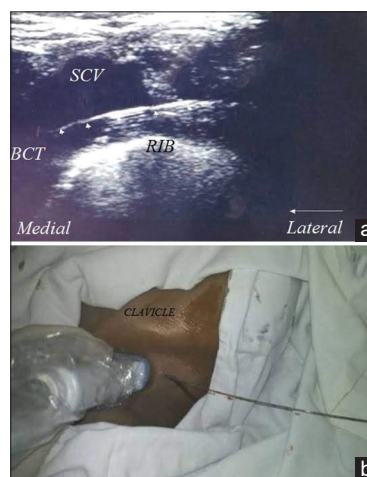The linear array probe was placed in a parasagittal plane at the mid-point of the clavicle. The clavicle was recognized as a bright hyperechoic structure with an acoustic shadow below it, whereas the subclavian artery and vein were recognized as hypoechoic structures. The vein is medial, compressible, and superficial in location to the artery. USG probe was gently moved below the border of the clavicle and rotated to obtain an oblique axis view of the subclavian vein [Figure 2].

### Real-time cannulation and catheterization

The needle was inserted in real-time using in-plane technique in both groups.

The following data were recorded:

1. Puncture time: Time between penetration of skin and aspiration of venous blood into the syringe.



**Figure 1:** 2 D USG image of the guidewire (arrow) in supraclavicular SCV (a). Percutaneous puncture site for supraclavicular approach with the guidewire in situ (b).

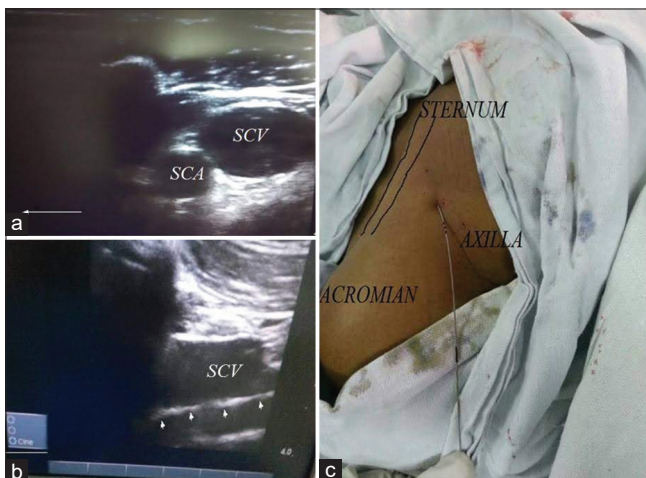
- Total access time: Time from the needle puncture to the appropriate placement of the catheter.
- Quality of needle visualization in the two techniques: Good or Poor.
- The number of attempts of needle puncture.
- The number of attempts in the insertion of a guidewire.
- Diameter of the vessel.
- Mechanical complications defined as carotid artery puncture, neck hematoma, hemothorax, pneumothorax, injury to the brachial plexus, phrenic nerve, and cardiac tamponade.

All catheterizations were performed with Certofix® Duo (B. Braun Melsungen AG, Germany) double-lumen catheter set with an outer diameter of 7 F, and a length of 15 cm was used.

Chest X-ray (CXR) was done postoperatively to detect complications such as pneumothorax, hemothorax, and assess the placement of the catheter's tip after the procedure. A minimum distance of 2.9 cm caudal to the right trachea-bronchial angle was preferred.

Sample size estimation was done in accordance with a previous study in which puncture times [median (IQR)] were 36 (24–60) s in supraclavicular and 48 (30–114) s in infraclavicular group.<sup>[2]</sup> The mean difference of puncture time was 12 s with a standard deviation (SD) of 20. Thus, we chose a sample size of 44 patients in each group for analysis for a power of 80% and a confidence interval of 95%.

The quantitative data were presented as mean  $\pm$  SD or median and interquartile range, as appropriate. Mann-Whitney *U*-test was used for statistical analysis of skewed continuous variables and ordered categorical variables. For normally distributed data, student's *t*-test was applied.



**Figure 2:** Infraclavicular 2 D short axis view of SCV (a). Long axis view of SCV with guidewire in SCV (b). Percutaneous puncture site with guidewire in situ (c)

Pearson  $\chi^2$  test or Fisher's exact test was used for the analysis of categorical variables with two categories. Statistical significance was set at  $P < 0.05$  and 95% confidence intervals (CIs). All calculations were performed using SPSS® version 22 (Statistical Packages for the Social Sciences, Chicago, IL)

## Results

A hundred patients were assessed for eligibility, but four were excluded [Figure 3]. The remaining 96 patients were randomized into either supraclavicular group (Group SC,  $N = 48$ ) or infraclavicular group (Group IC,  $N = 48$ ). A successful cannulation was possible in only 45 patients in each group.

The demographic variables were comparable between the two groups [Table 1]. The median (IQR) preprocedural scan time in SC group was 17 (12.25–24) s and 20.5 (12–34.25) s in IC group ( $P = 0.28$ ). The mean (SD) diameter of the vein measured in the longitudinal axis in the SC and IC group in the end-expiratory phase of the respiration was  $0.69 \pm 0.1$  cm and  $0.71 \pm 0.12$  cm ( $P = 0.48$ ), respectively.

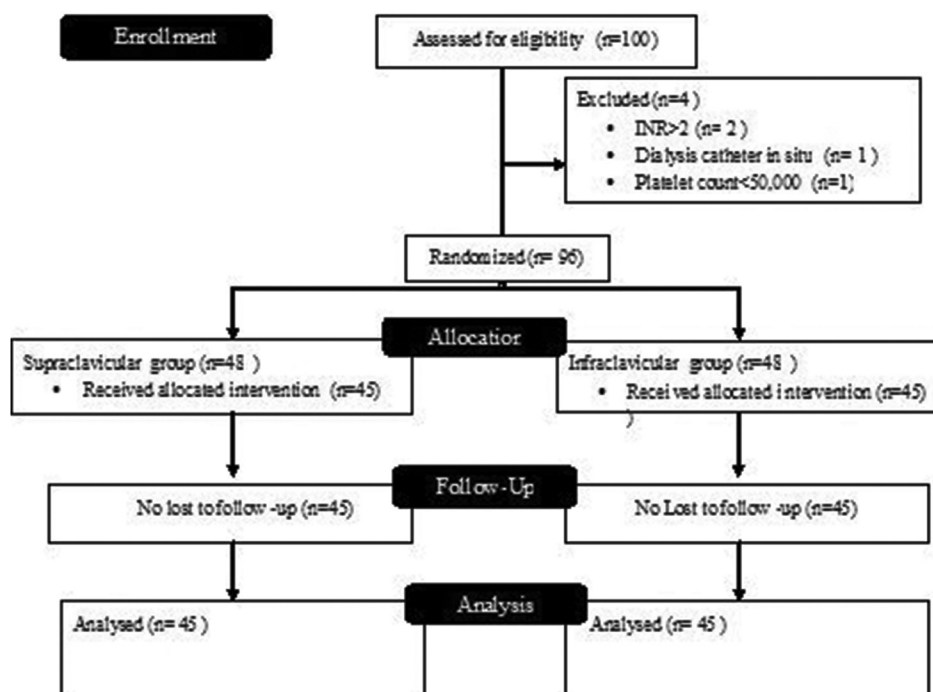
USG-guided subclavian vein cannulation performance data using SC and IC approaches is compared in Table 2. The median (IQR) value of puncture time was 15 (9–39) s in SC group and 21 (5–80) s in IC group ( $P = 0.21$ ). The first attempt success rate was 82.2% and 62.2% with a mean (SD) total access time of  $99.11 \pm 34.66$  s and  $103.44 \pm 50.27$  s in SC and IC approaches, respectively, and all values were comparable.

There was no statistically significant difference in the incidence of mechanical complications ( $P = 0.39$ ) between the two groups: arterial puncture ( $n = 1$ ) and pneumothorax ( $n = 1$ ) were reported in the IC group, and difficulty in removal of guidewire was reported in SC group ( $n = 1$ ). Intracardiac placement of the catheter was seen in 33.33% of the

**Table 1: Demographic and clinical data**

Variable	SC group (n=45)	IC group (n=45)	P
Age (years)	43.02 $\pm$ 1 5.36	46.10 $\pm$ 17.70	0.36
Male/female	33/15	35/13	0.65
Weight (kg)	62.70 $\pm$ 12.9 0	63.92 $\pm$ 12.14	0.63
Height (cm)	163.54 $\pm$ 9.10	165 $\pm$ 6.78	0.38
BMI (kg/m <sup>2</sup> )	23.43 $\pm$ 4.31	23.29 $\pm$ 4.21	0.88
ASA status	20/9/14/5	19/12/16/1	0.35
1/2/3/4			

Values are expressed as mean $\pm$ SD, except for sex and ASA status. Chi square test for categorical data; *t*-test for numerical data,  $P < 0.05$  significant. ASA-American Society of Anesthesiologists; BMI-Body Mass Index; Kg-kilogram; cm-centimeter. SC-Supraclavicular; IC-Infraclavicular



**Figure 3:** Patient randomization and follow-up according to the Consolidated Standards of Reporting Trials (CONSORT) guidelines

**Table 2: US-guided subclavian vein cannulation performance data using SC and IC approaches**

	SC group (n=45)	IC group (n=45)	95% CI	P
Quality of needle visualization				
Good	27	21	0.281–.298	0.29
Poor	18	24		
The first attempt success rate	82.2% (37/45)	62.2% (28/45)	0.24–.27	0.26
@Puncture time (in seconds)	15 (9-39)	21 (5-80)	0.192–.207	0.20
#Total access time (in seconds)	99.11±34.66	103.44±50.27	0.980–.985	0.98
#Attempts of needle puncture	1.20±0.46	1.40±0.54	0.04–.057	0.04
#Attempts of guidewire insertion	1.07±0.25	1.16±0.37	0.305–.323	0.318
#Catheter insertion length (in cm)	11.49±1.04	12.62±1.37	0.000–.000	<0.001

Values expressed as mean ±SD; @Value expressed as median (IQR); quality of needle visualization expressed in terms of number of subjects; SC-Supraclavicular, IC-Infraclavicular

subjects in either group. The percentage of patients with extrathoracic (venous) placement was comparable (8.8% in IC group and 6.7% in SC group). Malpositioning of the catheter in the ipsilateral internal jugular vein was detected in 2 subjects in IC group and 1 subject in SC group.

## Discussion

In our prospective randomized trial, there was no significant difference in the puncture times, first attempt success rate, and incidence of mechanical complications between USG-guided supraclavicular and infraclavicular subclavian venous catheterizations. This is in contrast to a study conducted by Prasad *et al.*<sup>[3]</sup> in which the puncture time and total procedural time were significantly more than those in USG infraclavicular approach to subclavian vein cannulation. They also reported a

higher first-attempt success rate in supraclavicular approach. The lack of similarity between the results of their study and ours is due to the difference in the study population and settings: intensive care unit for them and operating theater for our study. The total procedural times ( $177.92 \pm 12.46$  in SC vs  $199.66 \pm 18.53$  s in IC) and venous puncture times ( $35.29 \pm 10.42$  in SC vs  $46.25 \pm 15.01$  in IC) mentioned in the study by Prasad *et al.*<sup>[3]</sup> do not match with the previously published literature, which limits further comparisons.

The puncture time in seconds for USG infraclavicular approach in a previous study in adults has been reported as  $18.9 \pm 10.9$ , which is further decreased to  $12.1 \pm 6.5$  with the use of an echogenic cannula.<sup>[4]</sup> The mean insertion time using short-axis versus long-axis approaches to ultrasound-guided

subclavian vein cannulation has been reported as  $69 \pm 74$  s and  $98 \pm 103$  s, respectively.<sup>[5]</sup> In our study, the median puncture time was 15 (9–39) s in SC and 21 (5–80) s in IC group and closer to the previously published figures. The clinical relevance of a 22-s difference reported by Prasad *et al.*<sup>[3]</sup> is also questionable, especially when the overall success rate was 100% in both groups.

Stachura *et al.*<sup>[6]</sup> have reported a better sonographic visualization of the SCV in the SC fossa, but in our study the preprocedural scan times were comparable. Stachura *et al.*<sup>[6]</sup> conducted a prospective anatomical survey and did not perform any cannulations in their study.

A significantly increased number of needle punctures were reported in our study with the IC approach, but the incidence of mechanical complications was comparable. This may be due to the small sample size; the study was not powered for the same. Previous studies have reported that failure of catheterization at the first attempt is associated with increased risk for pneumothorax and mechanical complications in SCV cannulation.<sup>[7-9]</sup>

Probes with a smaller footprint such as an endocavitary, hockey stick, or micro-convex ultrasound probe have been advocated for supraclavicular SCV cannulation.<sup>[10-13]</sup> In our study, we have used a linear array probe for both approaches because the availability of probes with a smaller footprint was limited. It is a common practice to choose a new approach or new puncture site when the first fails and, in such situations, it is ergonomically easier to perform USG cannulations if a single type of probe is being used. The use of a linear probe may have led to puncture of the caudal most part of IJV for SC approach and the distal SCV or proximal axillary vein for the IC approach.<sup>[13,14]</sup> Table 3 enumerates the differences

**Table 3: Differences between US-guided Axillary and subclavian vein cannulation**

Anatomical characteristics	US-guided Axillary vein cannulation	US-guided subclavian vein cannulation
Skin to vein distance	Greater	Smaller
Anatomical relation with surrounding structures	The vein is deeper than the artery and brachial plexus	There is an overlap of artery and vein
Catheter pinch-off syndrome	Less chance	Increased risk
Positioning of the arm	Catheterization does not need any specific positioning	Catheterization requires positioning of arms (90° abduction)
Risk of infection	Closer to the armpit. Hence, a higher chance of infection	Lesser chance of infection

between the midclavicular subclavian and axillary vein puncture.<sup>[15-17]</sup>

The National Institute for Clinical Excellence (NICE) guidelines (2002) and American Society of Echocardiography and the society of cardiovascular Anesthesiologists advocate the use of US for IJV cannulations but do not support the routine use of US for uncomplicated patients undergoing SCV cannulation.<sup>[18,19]</sup> It has not gained popularity because of the anatomical proximity of the clavicle, which obstructs complete sonographic visualization of the subclavian vein.<sup>[20]</sup> This has led to a recent increase in USG cannulations of the IJV, and the subclavian vein has become a less preferred option now. It is to be noted that SCV vein cannulation has certain advantages over IJV cannulations such as lower rates of infection, reduced incidence of mechanical complications, and thrombosis.<sup>[1]</sup> Thus, attempts should be made to encourage residents to gain training in both blind and US-guided cannulations of the SCV. A preliminary study of the learning curves with anesthetic trainees for ultrasound-guided subclavian vein cannulation using the short axis approach has documented it as a difficult technique requiring rigorous training and learning.<sup>[21]</sup>

With improved resolution and needle recognition software, the use of US is expanding; publications supporting safety and ease of USG subclavian cannulations are increasing, and this may lead to a revision of the guidelines in the near future.<sup>[2-5,12-17,22]</sup> Recommendations need to be framed separately for use of US during cannulations of the SCV in patients with chest trauma, previous catheterization, surgery, or radiotherapy in the clavicular region as the local anatomy is distorted in this subset of patients, which may increase the failure rate of blind subclavian cannulations.

## Limitations

The results of our study may not hold true for left SCV catheterization, and further studies are required for comparing the catheterization characteristics between left and right-sided SCV cannulations.<sup>[23]</sup> The anesthesiologists performing the ultrasound-guided cannulation and the person recording puncture time, scan time, complications, etc., were not blinded in our study. In this study, we have used an in-plane (longitudinal axis view) approach as it is associated with a greater first-attempt success and fewer needle redirections and arterial punctures compared with the transverse orientation<sup>[17]</sup>; thus, results of our study cannot be extrapolated for out of plane approaches (short-axis view). Interindividual variation about the quality of needle visualization is unavoidable.

## Conclusion

The ease of cannulation of the subclavian vein using ultrasound-guided supraclavicular and infraclavicular

approach is comparable as no statistically significant difference is noted in the puncture time. The first attempt success rate was comparable. The significantly increased number of needle punctures reported in the IC approach did not translate to an increased complication rate.

### Financial support and sponsorship

Nil.

### Conflicts of interest

There are no conflicts of interest.

### References

- Bannon MP, Heller SF, Rivera M. Anatomic considerations for central venous cannulation. *Risk Manag Healthc Policy* 2011;4:27-39.
- Byon HJ, Lee GW, Lee JH, Park YH, Kim HS, Kim CS, *et al.* Comparison between ultrasound-guided supraclavicular and infraclavicular approaches for subclavian venous catheterization in children--A randomized trial. *Br J Anaesth* 2013;111:788-92.
- Prasad R, Soni S, Janweja S, Rajpurohit JS, Nivas R, Kumar J. Supraclavicular or infraclavicular subclavian vein: Which way to go- A prospective randomized controlled trial comparing catheterization dynamics using ultrasound guidance. *Indian J Anaesth* 2020;64:292-8.
- Stefanidis K, Fragou M, Pentilas N, Kouraklis G, Nanas S, Savel RH, *et al.* Optimization of cannula visibility during ultrasound-guided subclavian vein catheterization, via a longitudinal approach, by implementing echogenic technology. *Crit Care Res Pract* 2012;2012:617149.
- Raphael PO, Simon BP, Thankappan C, Chacko L. Comparison between ultrasound guided supraclavicular and infraclavicular approaches for subclavian venous catheterisation in adults. *J Evid Based Med Healthc* 2016;36:774-8.
- Stachura MR, Socransky SJ, Wiss R, Betz M. A comparison of the supraclavicular and infraclavicular views for imaging the subclavian vein with ultrasound. *Am J Emerg Med* 2014;32:905-8.
- Ruesch S, Walder B, Tramer MR. Complications of central venous catheters: Internal jugular versus subclavian access-A systematic review. *Crit Care Med* 2002;30:454-60.
- Schummer W, Schummer C, Rose N, Niesen WD, Sakka SG. Mechanical complications and malpositions of central venous cannulations by experienced operators. A prospective study of 1794 catheterizations in critically ill patients. *Intensive Care Med* 2007;33:1055-9.
- Kilbourne MJ, Bochicchio GV, Scalea T, Xiao Y. Avoiding common technical errors in subclavian central venous catheter placement. *J Am Coll Surg* 2009;208:104-9.
- Mallin M, Louis H, Madsen T. A novel technique for ultrasound-guided supraclavicular subclavian cannulation. *Am J Emerg Med* 2010;28:966-9.
- Saini V, Samra T. Ultrasound guided supraclavicular subclavian cannulation: A novel technique using "hockey stick" probe. *J Emerg Trauma Shock* 2015;8:72-3.
- Lanspa MJ, Fair J, Hirshberg EL, Grissom CK, Brown SM. Ultrasound-guided subclavian vein cannulation using a micro-convex ultrasound probe. *Ann Am Thorac Soc* 2014;11:583-6.
- Pirotte T, Veyckemans F. Ultrasound-guided subclavian vein cannulation in infants and children: A novel approach. *Br J Anaesth* 2007;98:509-14.
- Yamauchi M, Sasaki H, Yoshida T, Niiya T, Mizuno E, Narimatsu E, *et al.* Ultrasound-guided supraclavicular central venous catheterization in patients with malignant hematologic diseases. *J Anesth* 2012;12:775-8.
- Sharma A, Bodenham AR, Mallick A. Ultrasound-guided infraclavicular axillary vein cannulation for central venous access. *Br J Anaesth* 2004;93:188-92.
- Sandhu NS. Transpectoral ultrasound-guided catheterization of the axillary vein: An alternative to standard catheterization of the subclavian vein. *Anesth Analg* 2004;99:183-7.
- Sommerkamp SK, Romaniuk VM, Witting MD, Ford DR, Allison MG, Euerle BD. A comparison of longitudinal and transverse approaches to ultrasound-guided axillary vein cannulation. *Am J Emerg Med* 2013;31:478-81.
- Troianos CA, Hartman GS, Glas KE, Skubas NJ, Eberhardt RT, Walker JD, *et al.* Guidelines for performing ultrasound guided vascular cannulation: Recommendations of the American Society of Echocardiography and the Society of Cardiovascular Anesthesiologists. *J Am Soc Echocardiogr* 2011;24:1291-318.
- National Institute for Clinical Excellence. NICE technology appraisal guidance No 49: guidance on the use of ultrasound locating devices for placing central venous catheters. London: NICE, September; 2002. [www.nice.org.uk/pdf/ultrasound\\_49\\_GUIDANCE.pdf](http://www.nice.org.uk/pdf/ultrasound_49_GUIDANCE.pdf). [Last accessed on 2019 Feb 11].
- Randolph AG, Cook DJ, Gonzales CA, Pribble CG. Ultrasound guidance for placement of central venous catheters: A meta-analysis of the literature. *Crit Care Med* 1996;24:2053-8.
- Maddali MM, Arora NR, Chatterjee N. Ultrasound Guided Out-of-Plane Versus In-Plane Transpectoral Left Axillary Vein Cannulation. *J Cardiothorac Vasc Anesth* 2017;31:1707-12.
- Schulman PM, Gerstein NS, Merkel MJ, Braner DA, Tegtmeier K. Ultrasound-guided cannulation of the subclavian vein. *N Engl J Med* 2018;379:e1.
- Tan CO, Weinberg L, Peyton P, Story D, McNicol L. Size variation between contralateral infraclavicular axillary veins within individual patients-implications for subclavian venous central line insertion. *Crit Care Med* 2013;41:457-63.