



Severe heart failure in the setting of inflammatory cardiomyopathy with likely pathogenic titin variant

Titin is a protein responsible for stabilization of the entire sarcomere in muscle cells. Truncating variants in the titin gene appear to be the most common cause of familial dilated cardiomyopathy (DCM), replicated by one study, including numerous cohorts [1]. Such variants account for up to 25% of familial cases of DCM - mostly autosomal dominant [2]. Additionally, patients with TTN truncating variants have an increased risk of developing ventricular arrhythmias [3]. Choi and colleagues reported that atrial fibrillation was more common in truncating variants of TTN (2.1%) vs controls (1.1%), with results replicated in a large population ($n > 40,000$) [4]. However, truncating variants in TTN appear to be associated with milder and treatable forms of DCM vs Lamin A/C (LMNA) variants, as one study shows that DCM patients respond better to standard heart failure therapy [5]. These findings are highly relevant for clinical practice as they identify that exogenous triggers may precipitate grave transient deterioration of cardiac function in patients with predisposing genetic variants, and that severe heart failure may be completely reversible in those cases. In the following report, myocardial inflammation may have been the triggering factor.

A 42-year-old woman presented with signs of acute heart failure after viral infection. The patient did not have any significant past medical history and did not take any medications. Family history was unremarkable. Laboratory data revealed inflammatory parameters within normal range. Transthoracic echocardiography showed severe systolic dysfunction (left ventricular ejection fraction 20%). Coronary angiography excluded coronary artery disease. Endomyocardial biopsy revealed inflammatory cardiomyopathy with predominance of macrophages (Fig. 1). There was no detection of genomes for Epstein-Barr virus, ParvovirusB19, Human Herpesvirus 6, Adenoviruses, Enteroviruses, Human Cytomegalovirus, Herpesvirus 1, Herpesvirus 2, Human Herpesvirus7, Varicella-zoster virus, Toxoplasma gondii or Borrelia spp.

Due to the fulminant presentation and because our patient had children that may benefit from genetic screening if an actionable variant was detected, genetic testing was performed. A novel heterozygous truncating variant in the titin (TTN) gene was detected (TTN, NP003310.4:p.Ser10860*, NM_003319.4:c.32579C > G,

NC_000002.11:g.179456857G > C), which is likely pathogenic according to ACMG criteria. The variant is located in the A-band of TTN and affects an exon that is expressed in all main isoforms of TTN and is incorporated to all transcripts of adult cardiac tissue [6]. The frequency in the general population appears to be low, as it has not been identified in studies involving thousands of individuals on control data bases.

In our case, the truncation occurred in the A band of the protein, which has been found more frequently in DCM than in controls [7]. Herman et al. reported > 95% of carriers being affected by DCM [1], while penetrance in studies by Akinrinade and Jansweijer reached 100% and 83%, respectively, by the age of 70 [5].

The TTN truncating variant of our case is associated with a milder course of DCM [5]. Also, our patient fully recovered normal left ventricular function under standard heart failure therapy within several months.

Severe manifestations of inflammatory cardiomyopathy may be the result of multiple predisposing factors. We have previously shown that HLA-DQ1 is more commonly expressed in the transcriptome of patients with myocarditis [8]. Recent studies have shown that genetic variants may predispose to more aggressive forms of myocarditis [9]. Triggers such as viral infection or toxins appear to induce a self-sustaining autoimmune reaction.

We encourage broader use of genetic testing and sharing of such findings through publications of case reports and case series to achieve a better understanding of the disease, particularly with respect to genomic and environmental interactions.

Declaration of Competing Interest

The authors declare that they have no known competing financial interests or personal relationships that could have appeared to influence the work reported in this paper.

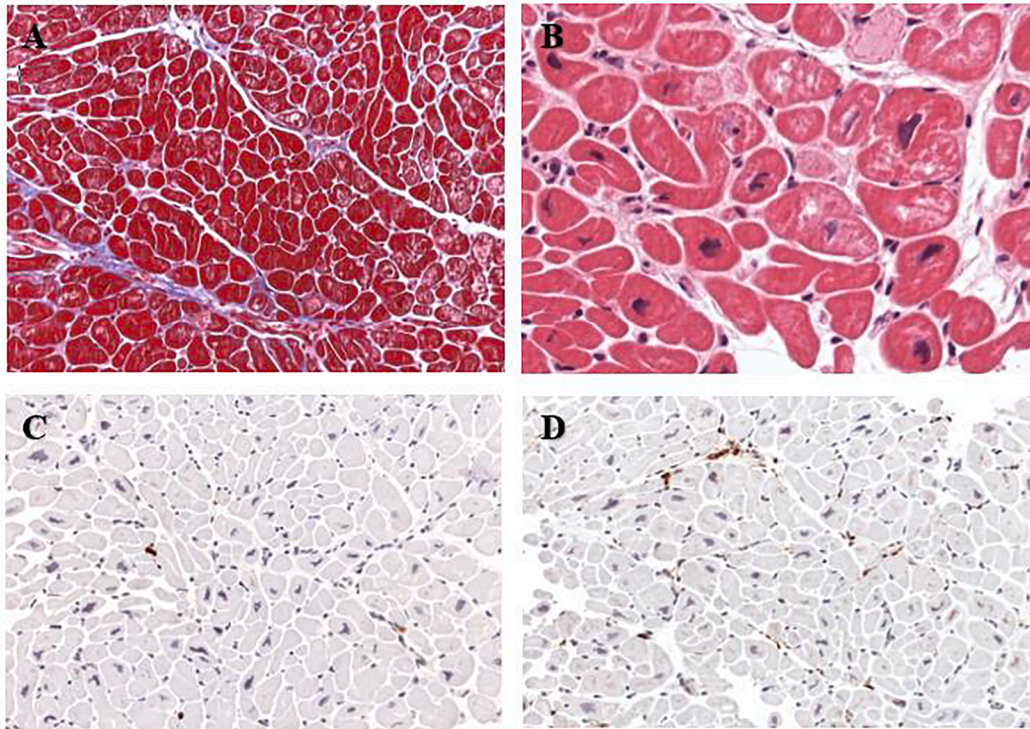


Fig. 1. Inflammatory cardiomyopathy with predominance of macrophages: Heart muscle of our patient in different histological examinations (A) Masson's Trichrome (B)HE (x400) (C) CD3+ T-cells (D) CD68+ macrophages. (A, C, D x200).

References

- [1] D.S. Herman, L. Lam, M.R.G. Taylor, L. Wang, P. Teekakirikul, D. Christodoulou, L. Conner, S.R. DePalma, B. McDonough, E. Sparks, D.L. Teodorescu, A.L. Cirino, N. R. Banner, D.J. Pennell, S. Graw, M. Merlo, A. Di Lenarda, G. Sinagra, J.M. Bos, M. J. Ackerman, R.N. Mitchell, C.E. Murry, N.K. Lakdawala, C.Y. Ho, P.J.R. Barton, S. A. Cook, L. Mestroni, J.G. Seidman, C.E. Seidman, Truncations of titin causing dilated cardiomyopathy, *N Engl. J. Med.* 366 (7) (2012) 619–628.
- [2] B.L. Siu, H. Niimura, J.A. Osborne, D. Fatkin, C. MacRae, S. Solomon, D.W. Benson, J.G. Seidman, C.E. Seidman, Familial dilated cardiomyopathy locus maps to chromosome 2q31, *Circulation* 99 (8) (1999) 1022–1026.
- [3] B. Corden, J. Jarman, N. Whiffin, U. Tayal, R. Buchan, J. Sehmi, A. Harper, W. Midwinter, K. Lascelles, V. Markides, M. Mason, J. Baksi, A. Pantazis, D. J. Pennell, P.J. Barton, S.K. Prasad, T. Wong, S.A. Cook, J.S. Ware, Association of titin-truncating genetic variants with life-threatening cardiac arrhythmias in patients with dilated cardiomyopathy and implanted defibrillators, *JAMA Netw. Open* 2 (6) (2019) e196520, <https://doi.org/10.1001/jamanetworkopen.2019.6520>.
- [4] S.H. Choi, L.-C. Weng, C. Roselli, H. Lin, C.M. Haggerty, M.B. Shoemaker, J. Barnard, D.E. Arking, D.I. Chasman, C.M. Albert, M. Chaffin, N.R. Tucker, J. D. Smith, N. Gupta, S. Gabriel, L. Margolin, M.A. Shea, C.M. Shaffer, Z.T. Yoneda, E. Boerwinkle, N.L. Smith, E.K. Silverman, S. Redline, R.S. Vasan, E.G. Burchard, S. M. Gogarten, C. Laurie, T.W. Blackwell, G. Abecasis, D.J. Carey, B.K. Fornwalt, D. T. Smelser, A. Baras, F.E. Dewey, C.E. Jaquish, G.J. Papanicolaou, N. Sotoodehnia, D.R. Van Wagoner, B.M. Psaty, S. Kathiresan, D. Darbar, A. Alonso, S.R. Heckbert, M.K. Chung, D.M. Roden, E.J. Benjamin, M.F. Murray, K.L. Lunetta, S.A. Lubitz, P. T. Ellinor, Association between titin loss-of-function variants and early-onset atrial fibrillation, *JAMA - J. Am. Med. Assoc.* 320 (22) (2018) 2354, <https://doi.org/10.1001/jama.2018.18179>.
- [5] J.A. Jansweijer, K. Nieuwhof, F. Russo, E.T. Hoorntje, J.D.H. Jongbloed, R. H. Lekanne Deprez, A.V. Postma, M. Bronk, I.A.W. van Rijsingen, S. de Haij, E. Biagini, P.L. van Haelst, J. van Wijngaarden, M.P. van den Berg, A.A.M. Wilde, M. M.A.M. Mannens, R.A. de Boer, K.Y. van Spaendonck-Zwarts, J.P. van Tintelen, Y. M. Pinto, Truncating titin mutations are associated with a mild and treatable form of dilated cardiomyopathy, *Eur. J. Heart Fail.* 19 (4) (2017) 512–521, <https://doi.org/10.1002/ehf.673>.
- [6] A.M. Roberts, J.S. Ware, D.S. Herman, S. Schafer, J. Baksi, A.G. Bick, R.J. Buchan, R. Walsh, S. John, S. Wilkinson, F. Mazzarotto, L.E. Felkin, S. Gong, J.A. L. MacArthur, F. Cunningham, J. Flannick, S.B. Gabriel, D.M. Altshuler, P.S. Macdonald, M. Heinig, A.M. Keogh, C.S. Hayward, N.R. Banner, D.J. Pennell, D.P. O'Regan, T. R. San, A. de Marvao, T.J. W. Dawes, A. Gulati, E.J. Birks, M.H. Yacoub, M. Radke, M. Gotthardt, J.G. Wilson, C.J. O'Donnell, S.K. Prasad, P.J. R. Barton, D. Fatkin, N. Hubner, J.G. Seidman, C.E. Seidman, S.A. Cook, Integrated allelic, transcriptional, and phenomic dissection of the cardiac effects of titin truncations in health and disease, *Sci. Transl. Med.* 7 (270) (2015), <https://doi.org/10.1126/scitranslmed.3010134>.
- [7] T.J. Pugh, M.A. Kelly, S. Gowrisankar, E. Hynes, M.A. Seidman, S.M. Baxter, M. Bowser, B. Harrison, D. Aaron, L.M. Mahanta, N.K. Lakdawala, G. McDermott, E. T. White, H.L. Rehm, M. Lebo, B.H. Funke, The landscape of genetic variation in dilated cardiomyopathy as surveyed by clinical DNA sequencing, *Genet. Med.* 16 (8) (2014) 601–608, <https://doi.org/10.1038/gim.2013.204>.
- [8] B. Heidecker, M.M. Kittleson, E.K. Kasper, I.S. Wittstein, H.C. Champion, S. D. Russell, R.H. Hruban, E.R. Rodriguez, K.L. Baughman, J.M. Hare, Transcriptomic biomarkers for the accurate diagnosis of myocarditis, *Circulation* 123 (11) (2011) 1174–1184.
- [9] J.J. Moslehi, J.-E. Salem, J.A. Sosman, B. Lebrun-Vignes, D.B. Johnson, Increased reporting of fatal immune checkpoint inhibitor-associated myocarditis, *The Lancet* 391 (10124) (2018) 933, [https://doi.org/10.1016/S0140-6736\(18\)30533-6](https://doi.org/10.1016/S0140-6736(18)30533-6).

Melina Mueller, Lilli Zwinger

Department of Cardiology, Charité Universitätsmedizin Berlin, Berlin, Germany

Sabine Klaassen

Experimental and Clinical Research Center (ECRC), a cooperation between the Charité Medical Faculty and the Max-Delbrück-Center for Molecular

Medicine, Berlin, Germany

Department of Pediatrics, Division of Cardiology, Charité

Universitätsmedizin Berlin, Berlin, Germany

DZHK (German Centre for Cardiovascular Research), partnersite Berlin, Berlin, Germany

Wolfgang Poller

Department of Cardiology, Charité Universitätsmedizin Berlin, Berlin, Germany

Lorenzo Monserrat Iglesias
Medical Director. Dilemma Solutions. A Coruna. Spain, and Cardiovascular
Research Group. A Coruna University

Juan Pablo Ochoa
Cardiovascular Research Group, University of Coruna, Coruña, Spain

Karin Klingel
Cardiopathology, Institute for Pathology, University Hospital Tübingen,
Tübingen, Germany

Ulf Landmesser, Bettina Heidecker*
Department of Cardiology, Charité Universitätsmedizin Berlin, Berlin,
Germany

* Corresponding author at: Hindenburgdamm 30, 12203 Berlin,
Germany.

E-mail address: bettina.heidecker@charite.de (B. Heidecker).