

CLINICAL RESEARCH

Efficacy of a commercial dry sleeve cryotherapy system for cooling the equine metacarpus

Carrie C. Jacobs DVM, DACVS-LA  | Erin O'Neil DVM |
Timo Prange Dr.Med.Vet, MS, DACVS

Department of Clinical Sciences, College of Veterinary Medicine, North Carolina State University, Raleigh, North Carolina, USA

Correspondence

Carrie C. Jacobs, Department of Clinical Sciences, College of Veterinary Medicine, North Carolina State University, 1060 William Moore Drive, Raleigh, NC 27607, USA.

Email: ccjacob5@ncsu.edu

Funding information

North Carolina State University College of Veterinary Medicine

Abstract

Objective: To determine the ability of a commercial cryotherapy system (Game Ready Equine) to cool the metacarpal subcutaneous tissue and the superficial digital flexor tendon (SDFT) in horses.

Study design: Experimental study.

Animals or sample population: Six healthy adult horses.

Methods: Thermocouples were implanted into the metacarpal subcutaneous tissues and the SDFT of six horses. Two treatments (cryotherapy or cryotherapy with 5–50 mmHg intermittent compression) were randomly assigned to forelimbs and performed for 20 minutes. Temperatures were compared to the target range of 10–19°C and between groups.

Results: Only one limb in the cryotherapy/compression group reached the target range after cryotherapy. Temperatures did not differ between treatment groups at time 0. Lowest temperatures achieved in the subcutaneous tissue ($p = .0043$) and SDFT ($p = .005$) were 4.9 and 7.6°C lower when intermittent compression was applied. Similarly, applying compression induced a maximum change in temperature of approximately 7.0°C in the subcutaneous tissue ($p = .014$) and 10.2°C in the SDFT ($p = .0001$).

Conclusion: The cryotherapy system did not cool equine subcutaneous tissue or SDFT to the target temperature range, except in one limb. Combining cryotherapy with intermittent compression did result in lower temperatures and a greater change in temperature of the subcutaneous tissue and SDFT.

Clinical significance: When using this cryotherapy system, the addition of intermittent compression should be considered to achieve lower temperatures and potentially greater reduction in inflammation. Further studies are warranted to determine the effect of longer treatment times, higher compression settings, and the optimal temperature for benefits in normal and diseased equine tissues.

Results presented at the American College of Veterinary Sports Medicine and Rehabilitation 2021 Virtual CE.

This is an open access article under the terms of the [Creative Commons Attribution-NonCommercial-NoDerivs](https://creativecommons.org/licenses/by-nc-nd/4.0/) License, which permits use and distribution in any medium, provided the original work is properly cited, the use is non-commercial and no modifications or adaptations are made.

© 2022 The Authors. *Veterinary Surgery* published by Wiley Periodicals LLC on behalf of American College of Veterinary Surgeons.

1 | INTRODUCTION

Cryotherapy is a common rehabilitation method used in the acute phase of equine musculoskeletal injury to minimize inflammation and its secondary effects.^{1,2} The benefits of cryotherapy, including reduction of inflammation and edema, analgesia, and improved recovery, are believed to be the result of local vasoconstriction and reduced blood flow, slowed nerve conduction, and decreased cellular metabolism.³ To achieve beneficial effects, suggested target tissue temperatures should be maintained in the range of 10–19°C for 15–20 minutes.^{4,5}

A variety of cooling methods for the equine foot have been studied,^{6–9} but few studies have evaluated cooling methods for other areas of the equine limb.^{4,10–12} A dry sleeve cryotherapy system designed for use in horses (Game Ready Equine, Concord, California) is a portable, easily applied commercial system that can be used in a variety of settings to apply cryotherapy to the distal limb of horses. It can be set to allow for (1) cryotherapy without compression or (2) cryotherapy with three different settings of intermittent compression therapy (low 5–15 mmHg, medium 5–50 mmHg, and high 5–75 mmHg). A previous study evaluated the use of a prototype of this system to cool the superficial digital flexor tendon (SDFT) over 60 minutes. Results found that following cryotherapy with intermittent compression, the SDFT core temperature was reduced by a mean of 21.8°C and the core temperature of the SDFT decreased more rapidly than that of the skin surface.⁴ Cryotherapy protocols for equine musculoskeletal injuries are recommended for as little as 20–30 minutes for 2–3 applications per day.^{2,13} Compliance with longer cryotherapy treatments, as tested in the mentioned study, may be difficult given patient behavior and time constraints of the owners, trainers, and barn managers performing the treatment. Knowledge regarding the effectiveness of shorter treatment periods using this system is essential when designing rehabilitation plans.

The previously mentioned study found a significant decrease in the SDFT core temperature, however compression was applied at 103 mmHg, which is higher than any of the three settings on the commercially available system.⁴ In people, cooling of muscle was greater with intermittent compression compared to cryotherapy alone.¹⁴ No studies have been performed to assess the effectiveness of cooling of the metacarpal region in horses with and without compression over any time period.

The objective of this study was to evaluate the degree of cooling of the metacarpal subcutaneous tissues and the SDFT using the dry sleeve cryotherapy system over a 20-minute treatment period. We hypothesized that the system would decrease metacarpal subcutaneous and

SDFT temperatures to 10–19°C in healthy horses and that cryotherapy combined with intermittent compression would provide a greater decrease in metacarpal subcutaneous and SDFT temperatures compared to cryotherapy alone.

2 | MATERIALS AND METHODS

2.1 | Horses

All procedures were approved by the North Carolina State University Animal Care and Use Committee. Six healthy, adult horses free of lameness, musculoskeletal problems, or cellulitis were used for this study (mean age 9.8 years, range = 4–20 years, three mares, three geldings). Each horse underwent both therapies (cryotherapy alone and cryotherapy + compression) which were assigned randomly per treatment and limb. The target range for cryotherapy treatments was a temperature recorded within the range of 10–19°C.

2.2 | Thermocouple placement

All procedures and data collection were performed in a temperature-controlled university research procedure room. Prior to the procedures, physical examinations were performed and both distal forelimbs were clipped. Both forelimbs were instrumented with thermocouples for data collection. To perform thermocouple placement, horses were sedated (detomidine 0.01 mg/kg IV, butorphanol 0.01 mg/kg IV) and restrained with a halter and lead rope. The dorsal and palmar aspects of the mid-metacarpus of both forelimbs were aseptically prepared using 4% chlorohexidine gluconate scrub and isopropyl alcohol. Approximately 3 ml of 2% mepivacaine (Carbocaine, Zoetis Inc, Parsippany, New Jersey) was administered subcutaneously at the site of proposed thermocouple insertion in both the dorsal and palmar aspects of the mid-metacarpus. Thermocouples (IT-18, Physitemp Instruments LLC, Clifton, New Jersey) were threaded through 18-gauge needles and implanted into the subcutaneous tissue of the dorsal metacarpus and into the core of the SDFT, equidistant from the metacarpophalangeal and carpometacarpal joints- at the level of the mid-metacarpus, of each front limb using aseptic technique. Once the 18-gauge needle with thermocouple was inserted into the subcutaneous tissue or SDFT, the thermocouple was manually held in place as the needle was removed from the tissue. Placement of the thermocouple into the SDFT was performed using ultrasound

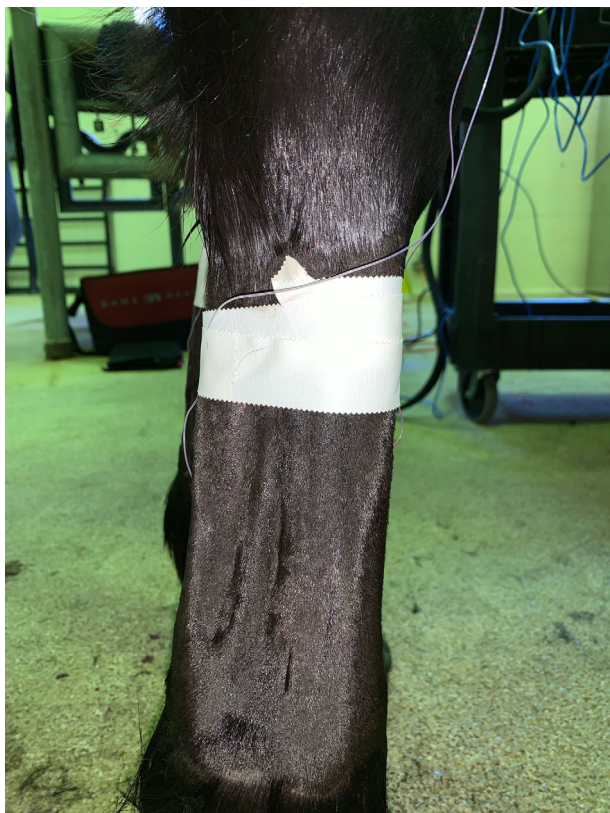

FIGURE 1 An example of thermocouple placement in the dorsal subcutaneous tissue and within the superficial digital flexor tendon, at the level of the mid-metacarpus

guidance. The thermocouples and their wire leads were secured to the limb using medical tape in two locations: just above the insertion site and approximately 10 cm above the accessory carpal bone (Figure 1). The wire leads were attached to probe extension leads (EXT-6, Physitemp Instruments LLC) which were placed through braids in the mane and then to the data collection equipment (Thermes USB, Physitemp Instruments LLC). A thermocouple was placed into the reservoir chamber of the cryotherapy system to monitor the temperature of the circulating water and a second thermocouple was placed next to the data collection equipment to measure the ambient temperature of the procedure room. These thermocouples were attached to extension leads and then to the data collection equipment.

2.3 | Application of cryotherapy

Prior to application of the cryotherapy sleeve, the reservoir chamber was filled with crushed ice and then cold tap water was added to the “MAX FILL” line, approximately 1 inch below the lid as directed in the system manual. The temperature control was set at the lowest




FIGURE 2 An example of the placement of the cryotherapy sleeve on the limb prior to the treatment periods

temperature setting of the machine. The full limb sleeve of the cryotherapy system (Equine Full Leg Wrap, Game Ready Equine) was placed onto a randomly assigned forelimb with the distal part being placed over the metacarpophalangeal joint (Figure 2). The connector hose (Single Connector Hose, GameReady Equine) was attached to the sleeve, draped over the horse's withers, and then attached to the control unit of the cryotherapy system (GameReady Pro Equine Control Unit, Game Ready Equine). Following application of the sleeve, one of the two treatments (cryotherapy alone or cryotherapy and medium intermittent compression of 5–50 mmHg) was randomly assigned and performed for 20 minutes. Temperature data was collected every 30 s from the treated limb, the untreated limb, the reservoir of the cryotherapy system, and the ambient room temperature using data collection equipment and software (Thermes USB, Physitemp Instruments LLC). After completion of the first treatment, the sleeve of the cryotherapy system was removed and additional temperature data collected for an additional 20 minutes or until the limb returned to baseline temperature. Once the treated limb had returned to its baseline temperature, as measured by the thermocouples, the second treatment was performed on the opposite, untreated forelimb. Temperature data was recorded

every 30 seconds for 20 minutes of the treatment period and then for an additional 20 minutes following removal of the cryotherapy system or until the limb returned to its baseline temperature. Throughout the study, additional sedation was administered as needed (detomidine 0.005–0.01 mg/kg IV or xylazine 0.3–0.5 mg/kg IV). Once temperature measurements on the second leg had been completed, the thermocouples were removed, light distal limb bandages were placed, and a single dose of intravenous phenylbutazone (4.4 mg/kg) was administered. On the day following the procedure, physical examinations were performed, the bandages were removed, and the horses were assessed for lameness and the forelimbs were examined for signs of heat, swelling, or sensitivity.

2.4 | Statistical analysis

Statistical analyses were performed using commercially available software (GraphPad Prism, GraphPad Software, San Diego, California) with $p < .05$. Fisher's exact test was used to compare the number of limbs between treatment groups that achieved temperatures in the range of 10–19°C. Continuous data was tested for normality using the Shapiro–Wilk test. The variables of temperature at time 0, the lowest temperature, and the max change in temperature were normally distributed and therefore data was presented as mean (\pm standard deviation). Temperature at time 0, the lowest temperature, and the max change in temperature were compared between treatment groups (cryotherapy vs. cryotherapy/compression) using a paired t -test.

3 | RESULTS

All six horses completed the study without complication. Thermocouple placement and cryotherapy treatments were well tolerated by all horses. The day following the procedures, mild edema was noted over the dorsal metacarpus at the thermocouple insertion site in one limb of one horse. In another horse, mild sensitivity was noted over both thermocouple insertion sites in one limb. No other adverse events were noted during or after the procedures.

The mean ambient temperature of the room was 25.3 and 24.9°C during cold and cold/compression treatments respectively. The mean temperature within the water reservoir was 3.5 and 4.0°C during cold and cold/compression treatments, respectively.

The mean temperature of the subcutaneous tissue at time 0 of the cryotherapy and cryotherapy/compression groups was $27.8 \pm 3.49^\circ\text{C}$ and $27.4 \pm 1.58^\circ\text{C}$, respectively. Mean temperature of the SDFT at time 0 of the cryotherapy and cryotherapy/compression groups was $30.6 \pm 3.67^\circ\text{C}$ and $32.8 \pm 1.90^\circ\text{C}$, respectively. Temperatures of the subcutaneous tissue ($p = .79$) and SDFT ($p = .14$) did not differ between treatment groups at time 0.

Subcutaneous and SDFT temperatures in the range of 10–19°C were not measured in any of the limbs in the cryotherapy group (Figures 3 and 4). Subcutaneous temperatures below 19°C were measured in one limb in the cryotherapy/compression group for a period of 8.5 minutes. A one-time subcutaneous temperature of 19.2°C and a one-time SDFT temperature of 19.1°C were measured in two

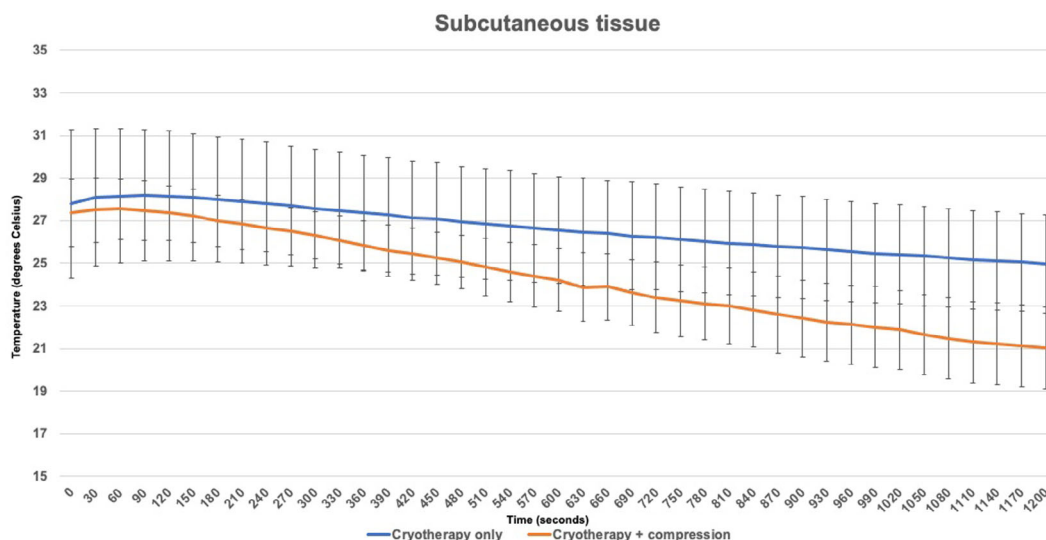


FIGURE 3 Mean temperatures of the subcutaneous tissue in the cryotherapy and cryotherapy/compression groups throughout the treatment period

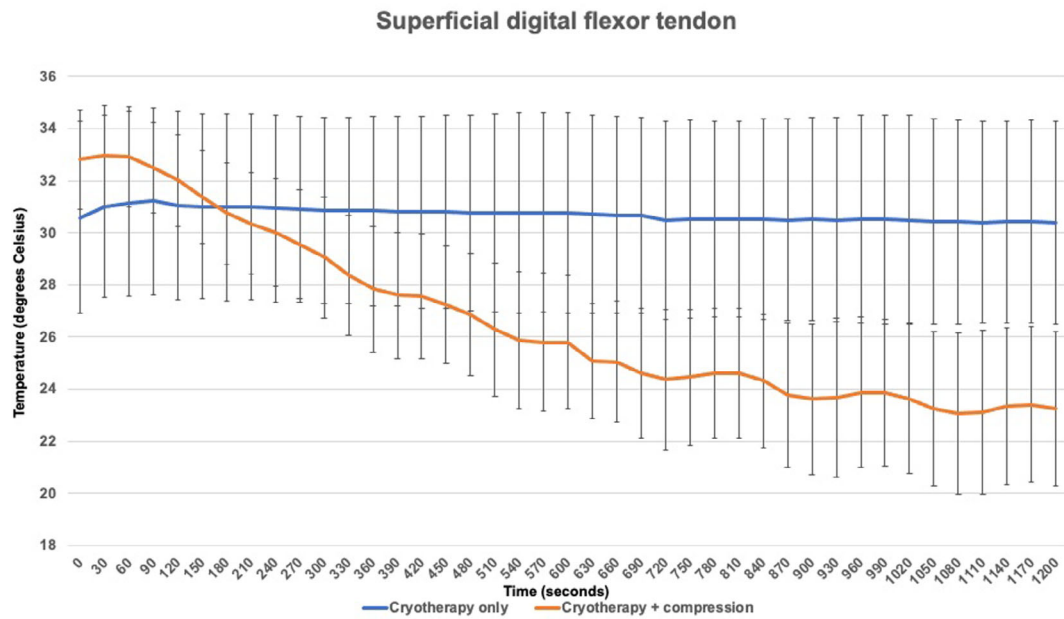


FIGURE 4 Mean temperatures of the superficial digital flexor tendon in the cryotherapy and cryotherapy/compression groups throughout the treatment period

	Cryotherapy only (°C)	Cryotherapy/compression (°C)	p-value
Horse 1	24.4	17.8	
Horse 2	26.4	22.6	
Horse 3	28.1	22.1	
Horse 4	27.0	19.2	
Horse 5	20.9	19.7	
Horse 6	26.6	22.5	
Mean	25.6	20.7	.0038*

*p < .05.

TABLE 1 Lowest temperatures achieved of the subcutaneous tissues during cryotherapy and cryotherapy/compression treatments

	Cryotherapy only (°C)	Cryotherapy/compression (°C)	p-value
Horse 1	27.1	23.3	
Horse 2	27.7	22.1	
Horse 3	33.6	25.8	
Horse 4	37.3	27.0	
Horse 5	29.7	19.1	
Horse 6	27.1	19.6	
Mean	30.4	22.8	.0009*

*p < .05.

TABLE 2 Lowest temperatures achieved of the superficial digital flexor tendon during cryotherapy and cryotherapy/compression treatments

separate limbs in the cryotherapy/compression group, immediately following removal of the compression sleeve. There was no difference between treatment groups in the number of limbs with subcutaneous or SDFT temperatures measured in the range of 10–19°C ($p > .9$).

The mean lowest temperature within subcutaneous tissue with cryotherapy alone was $25.6 \pm 2.58^\circ\text{C}$ and

$20.7 \pm 2.02^\circ\text{C}$ with cryotherapy/compression (Table 1). The mean lowest temperature within the SDFT with cryotherapy alone was $30.4 \pm 4.18^\circ\text{C}$ and $22.8 \pm 3.2^\circ\text{C}$ with cryotherapy/compression (Table 2). The lowest temperatures achieved in the subcutaneous tissue ($p = .0043$) and SDFT ($p = .005$) were 4.9 and 7.6°C lower when intermittent compression was applied.

TABLE 3 Maximum change in temperature achieved of the subcutaneous tissue during cryotherapy and cryotherapy/compression treatments

	Cryotherapy only (°C)	Cryotherapy/compression (°C)	<i>p</i> -value
Horse 1	3.5	10.4	
Horse 2	4.3	3.0	
Horse 3	0.2	6.1	
Horse 4	2.3	9.3	
Horse 5	3.3	6.9	
Horse 6	5.5	6.4	
Mean	3.2	7.0	.04*

**p* < .05.

TABLE 4 Maximum change in temperature achieved of the superficial digital flexor tendon during cryotherapy and cryotherapy/compression treatments

	Cryotherapy only (°C)	Cryotherapy/compression (°C)	<i>p</i> -value
Horse 1	2.8	11.3	
Horse 2	2.5	10.3	
Horse 3	−0.3	8.8	
Horse 4	0.9	7.9	
Horse 5	1.8	12.3	
Horse 6	2.2	10.6	
Mean	1.65	10.2	.0001*

**p* < .05.

The mean max change in temperature for the subcutaneous tissue with cryotherapy alone was $3.2 \pm 1.8^\circ\text{C}$ and $7.0 \pm 2.6^\circ\text{C}$ for cryotherapy/compression (Table 3). For the SDFT, the mean max change in temperature with cryotherapy alone was $1.65 \pm 1.16^\circ\text{C}$ and $10.2 \pm 1.61^\circ\text{C}$ with cryotherapy/compression (Table 4). The maximum change in temperature of the subcutaneous tissue ($p = .014$) and the SDFT ($p = .0001$) was greater when intermittent compression was applied.

4 | DISCUSSION

In this study, after 20 minutes of treatment, we found that cryotherapy alone or with compression using the dry sleeve cryotherapy system did not consistently decrease metacarpal subcutaneous or SDFT temperatures to within the targeted therapeutic range of $10\text{--}19^\circ\text{C}$. We did identify, however, a significantly greater change in temperature when using cryotherapy combined with intermittent compression when compared to cryotherapy alone, thus resulting in lower temperatures of the subcutaneous tissue and the SDFT.

The temperature range of $10\text{--}19^\circ\text{C}$ was selected as the therapeutic target in this study as it has been suggested that a decrease in tissue temperature to within this range is needed to achieve beneficial effects with cryotherapy.^{4,5}

In the cryotherapy/compression group, only one limb

achieved a subcutaneous tissue temperature below 19°C and two other limbs achieved temperatures approaching 19°C . No limbs in the cryotherapy group approached 19°C . Our results differ from what we expected, even with the application of compression, and could be for a variety of reasons. First, the 20-minute time period that we chose to test may not have been long enough to allow the limbs to reach temperatures within the range of $10\text{--}19^\circ\text{C}$. After 60 minutes of treatment, Petrov et al. found the mean temperature within the SDFT core to be 10.4°C . After 20 minutes of cryotherapy/compression treatment, the lowest temperatures within the subcutaneous (20.7°C) and SDFT (22.8°C) approached the upper limit of the therapeutic range, and a longer treatment period may have allowed the temperatures to fall within this range. Second, the cryotherapy system functions by cold transfer through contact. Given the multiple contours of the equine distal limb, achieving and maintaining contact can be difficult. The addition of compression appeared to improve contact and cooling of the distal limb. The use of the higher compression setting ($5\text{--}75\text{ mmHg}$) may have enhanced contact with the equine distal limb and allowed a greater degree of cooling over the treatment period. We did clip the limbs in this study in order to improve contact between the limb and the cryotherapy system; however, other methods to enhance contact, such as the addition of gel to the distal limb, may also improve the transfer of cryotherapy

during treatment. Further studies evaluating differing treatment times and compression settings as well as methods to increase contact between the limb and the system, are warranted.

It has been reported that for every 10°C decrease in tissue temperature, metabolic and enzymatic activity of the tissues will decrease by 2- to 3-fold.^{10,15,16} With cooling of tissues, vasoconstriction will decrease blood flow and the rate of enzymatic proinflammatory reactions. With decreased blood flow, fewer numbers of proinflammatory cells and cytokines will be dispersed into an area.¹⁷ Overall, even some degree of tissue cooling will have beneficial anti-inflammatory effects. With the application of cryotherapy, decreased nerve conduction and subsequent analgesia is thought to decrease in a linear fashion until tissue temperatures approach 10°C.¹⁷ In the cryotherapy/compression group, the mean max change in SDFT temperature was 10.2°C and in subcutaneous temperature was 7.0°C. While most of the limbs in this study did not achieve temperatures within the recommended therapeutic range, the mean max change in temperature met or approached a change in temperature of 10°C. Even without being in the recommended therapeutic range in the cryotherapy/compression group, we would expect to see both anti-inflammatory and analgesic benefits.

A similar study evaluated this cryotherapy system during 60 minutes of cryotherapy treatment with compression of 103 mmHg, and achieved a mean decrease in temperature of the SDFT of 21.8°C.⁴ Obvious differences between our study and the Petrov et al. study include a greater treatment period and a greater degree of compression used. We chose to test both a shorter treatment duration and lower compression as these are more clinically applicable based on current cryotherapy recommendations. In dogs, general treatment recommendations for cryotherapy is 15–20 minutes up to every 2–4 hours depending on the type of injury.¹⁷ In horses, cryotherapy for musculoskeletal injuries is recommended for 20–30 minutes every 2–4 hours in the first 24–48 hours of an injury and then 2–3 times daily thereafter up to 3 weeks.^{2,13} In our clinical experience, the high compression setting of the cryotherapy system is not tolerated by all horses, therefore we chose to use the medium compression setting as we expected this to be well tolerated and used by those in a clinical setting. Based on the results found by Petrov et al., it is likely that the high compression setting would provide a greater decrease in tissue temperature with a similar treatment period, however further studies are needed to determine this.

Cryotherapy is often used following human and small animal orthopedic surgery and has been shown to

decrease inflammation and edema, to decrease pain, and improve range of motion in the immediate postoperative period.^{18–20} In equine orthopedics, cryotherapy is most commonly used following acute musculoskeletal injury and for laminitis prevention, but should be considered for management of inflammation and pain in postoperative orthopedic cases. The use of more traditional methods of cryotherapy, such as standing in cold water or ice packs, is difficult given the presence of surgical incisions, however using the commercial dry sleeve cryotherapy system would allow incisions and wounds to stay clean and dry.

Limitations include a small sample size of horses and inherent variability in response to cryotherapy treatment between horses. Additionally, healthy horses were used in this study and therefore we could not assess how active inflammation may have affected the degree of cooling achieved with this cryotherapy system. We also only measured the effect of intermittent compression at the medium setting of the system and are unaware of how the low or high compression setting may affect the cooling of these tissues.

Results of our study indicate that when using this cryotherapy system, the addition of medium intermittent compression, a significantly greater decrease in the metacarpal subcutaneous and SDFT temperatures were identified. This is similar to a study in humans where cooling of muscle was greater with intermittent compression compared to cryotherapy alone.¹⁴ Our results suggest that greater cooling and therefore a greater therapeutic effect may be seen with the addition of compression, however further studies are needed to determine optimal temperature ranges for therapeutic benefits in normal and diseased equine tissue. Practitioners should consider the addition of intermittent compression when using this cryotherapy system for rehabilitation of equine musculoskeletal injuries to achieve lower temperatures and a potentially greater reduction in inflammation.

ACKNOWLEDGMENTS

The authors would like to thank Robertson J BS, MS and Dembek KA DVM, PhD, DACVIM for their assistance with statistical analysis and interpretation.

Author Contributions: Carrie C. Jacobs DVM, DACVSLA: participated in study design, in the acquisition, analysis, and interpretation of data, and in drafting, and final approval of the manuscript; Erin O'Neil DVM: participated in the acquisition of data and in the drafting and final approval of the manuscript. Timo Prange Dr.Med. Vet, MS, DACVS: participated in study design, interpretation of data, and in drafting and final approval of the manuscript.

CONFLICT OF INTEREST

The authors declare no conflict of interests or any personal or financial affiliations with the products used in this project.

ORCID

Carrie C. Jacobs  <https://orcid.org/0000-0002-0579-6891>

REFERENCES

- Wilson J, McKenzie E, Duesterdieck-Zellmer K. International survey regarding the use of rehabilitation methods in horses. *Front Vet Sci*. 2018;5:120. doi:10.3389/fvets.2018.00120
- Bergh A. Physical treatment of the equine athlete. In: Hinchcliff KW, Kaneps AJ, Geor RJ, eds. *Equine Sports Medicine and Surgery*. 2nd ed. Elsevier; 2014:1231-1241.
- Roszkowska K, Witkowska-Pilaszewicz O, Przewozny M, Cywinska A. Whole body and partial body cryotherapies- lessons from human practice and possible application for horses. *BMC Vet Res*. 2018;14:394. doi:10.1186/s12917-018-1679-6
- Petrov R, MacDonald MH, Tesch AM, Van Hoogmoed LM. Influence of topically applied cold treatment on core temperature and cell viability in equine superficial digital flexor tendons. *Am J Vet Res*. 2003;64:835-844.
- Ortved KF. Regenerative medicine and rehabilitation for tendinous and ligamentous injuries in sports horses. *Vet Clin Equine*. 2018;34:359-373.
- Reesink HL, Divers TJ, Bookbinder LC, et al. Measurement of digital laminar and venous temperatures as a means of comparing three methods of topically applied cold treatment for digits of horses. *Am J Vet Res*. 2012;73:860-866.
- van Eps AW, Orsini JA. A comparison of seven methods for continuous therapeutic cooling of the equine digit. *Equine Vet J*. 2016;48:120-124.
- Burke MJ, Tomlinson JE, Blikslager AT, Johnson AL, Dallap-Schaer BL. Evaluation of digital cryotherapy using a commercially available sleeve style ice boot in healthy horses and horses receiving i.v. endotoxin. *Equine Vet J*. 2018;50:848-853.
- Morgan J, Stevanofski D, Lenfest M, Chatterjee S, Orsini J. Novel dry cryotherapy system for cooling the equine digit. *Vet Rec Open*. 2018;5:1-5. doi:10.1136/vetreco-2017-000244
- Kaneps AJ. Tissue temperature response to hot and cold therapy in the metacarpal region of a horse. *Proceedings of the Annual Convention of the AAEP*. American Association of Equine Practitioners. Vol 46; 2000:208-213.
- Marlin DJ. Evaluation of the cooling efficacy of different equine leg cooling methods. *Comp Exerc Physiol*. 2019;15(2): 113-122.
- Haussler KK, Wilde SR, Davis MS, Hess AM, McIlwraith CW. Contrast therapy: tissue heating and cooling properties within the equine distal limb. *Equine Vet J*. 2021;53:149-156.
- Kaneps AJ. Practical rehabilitation and physical therapy for the general equine practitioner. *Vet Clin Equine*. 2016;32: 167-180.
- Holwerda SW, Trowbridge CA, Womochel KS, Keller DM. Effects of cold modality application with static and intermittent pneumatic compression on tissue temperature and systemic cardiovascular responses. *Sports Health*. 2013;5(1): 27-33.
- von Neida K, Michlovitz SL. Cryotherapy. In: Michlovitz SL, ed. *Thermal Agents in Rehabilitation*. 3rd ed. F.A. Davis Company; 1996:78-102.
- Swenson C, Sward L, Karlsson J. Cryotherapy in sports medicine. *Scan J Med Sci Sports*. 1996;6:193-200.
- Dragone L, Heinricks K, Levine D, Tucker T, Millis D. Superficial thermal modalities. In: Millis D, Levine D, eds. *Superficial Thermal Modalities*. 2nd ed. Elsevier; 2014:312-327.
- Rexing J, Dunning D, Siegel AM, Knap K, Werbe B. Effects of cold compression, bandaging, and microcurrent electrical therapy after cranial cruciate ligament repair in dogs. *Vet Surg*. 2010;39:54-58.
- Drygas KA, McClure SR, Goring RL, Pozzi A, Robertson SA, Wang C. Effects of cold compression therapy on postoperative pain, swelling, range of motion, and lameness after tibial plateau leveling osteotomy in dogs. *J Am Vet Med Assoc*. 2011;238: 1284-1291.
- Murgier J, Cassard X. Cryotherapy with dynamic intermittent compression for analgesia after anterior cruciate ligament reconstruction. Preliminary study. *OTSR*. 2014;100:309-312.

How to cite this article: Jacobs CC, O'Neil E, Prange T. Efficacy of a commercial dry sleeve cryotherapy system for cooling the equine metacarpus. *Veterinary Surgery*. 2022;51(7): 1070-1077. doi:10.1111/vsu.13847