

## Treatment of Large Arteriovenous Malformation in Right Lower Limb

Young Ok Lee, M.D.<sup>1</sup>, Seong Wook Hong, M.D.<sup>2</sup>

A 10-year-old boy with arteriovenous malformation (AVM) of the right lower limb was scheduled for an amputation of the affected limb. Limb amputation was necessary because of the ineffectiveness of previous sclerotherapy and the rapid progression of AVM causing pain and heart failure. Right hip disarticulation was considered the best option to improve his quality of life. To prevent congestive heart failure and uncontrollable hemorrhage during surgery, the disarticulation was done under a partial cardiopulmonary bypass. The patient underwent surgery successfully without complications.

Key words: 1. Arteriovenous malformations  
2. Cardiopulmonary bypass  
3. Heart failure

### CASE REPORT

A 10-year-old boy (height, 120 cm; weight, 20 kg) presented with an 8-year history of arteriovenous malformation (AVM) involving the right lower limb. He had been started on sclerotherapy 4 years earlier because of leg length discrepancy causing gait disturbance. However, this treatment was stopped because there was no remarkable improvement. A year before presentation, the AVM had undergone rapid expansion causing significant pain and high-output cardiac failure. Therefore, an amputation of the affected lower limb was recommended at the other hospital.

On admission to Kyungpook National University Hospital, an examination revealed that AVM with soft tissue hypertrophy had spread all over the right leg (Fig. 1). A chest X-ray showed marked cardiomegaly with increased pulmonary

vascularities (Fig. 2A). Electrocardiography showed normal sinus rhythm with right ventricular hypertrophy. Two-dimensional echocardiography showed an enlarged right atrium, right ventricle, and left ventricle, but relatively good left ventricular contractility. The pulmonary artery was also enlarged, but there was no pulmonary edema. Computed tomographic (CT) angiography of the right lower extremity revealed extensive AVM with feeding arteries from the branches of the right profunda femoris and superficial femoral arteries. The venous drainage was through the superficial femoral and deep femoral veins, and there was a marked dilatation of the pelvic vein and inferior vena cava (Fig. 3A). The blood investigations were found to be normal.

One week before surgery, the patient was scheduled to receive preoperative selective embolization to reduce the size of the AVM and minimize the risk of uncontrolled intra-

Departments of <sup>1</sup>Thoracic and Cardiovascular Surgery and <sup>2</sup>Anesthesiology and Pain Medicine, Kyungpook National University School of Medicine

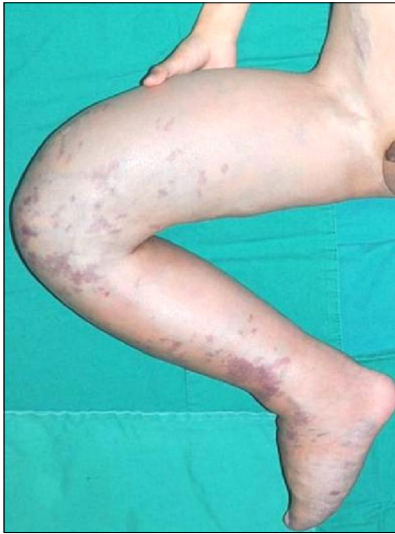Received: June 19, 2013, Revised: September 16, 2013, Accepted: October 24, 2013

Corresponding author: Seong Wook Hong, Department of Anesthesiology and Pain Medicine, Kyungpook National University School of Medicine, 680 Gukchaebosang-ro, Jung-gu, Daegu 700-842, Korea

(Tel) 82-53-200-5872 (Fax) 82-53-426-2760 (E-mail) [hsuaa@naver.com](mailto:hsuaa@naver.com)

© The Korean Society for Thoracic and Cardiovascular Surgery. 2014. All right reserved.

© This is an open access article distributed under the terms of the Creative Commons Attribution Non-Commercial License (<http://creativecommons.org/licenses/by-nc/3.0>) which permits unrestricted non-commercial use, distribution, and reproduction in any medium, provided the original work is properly cited.



**Fig. 1.** Photo of arteriovenous malformation of right lower limb.

operative bleeding. For embolization, the radiologist performed catheterization through the left common femoral artery and installed a tourniquet over the right proximal thigh. Soon after, remarkable bradycardia developed due to a baroreceptor reflex-induced abrupt increase in the systemic vascular resistance (SVR), and this procedure was cancelled. After a thorough discussion with the plastic surgeons, orthopedic surgeons, and vascular surgeons, right hip disarticulation was considered to be the best option for improving the patient's quality of life. It was anticipated that the large feeding vessel branches of the right profunda femoris artery, superficial femoral artery, and the large veins draining the limb would be difficult to control during a hip disarticulation. To minimize the chances of torrential hemorrhage, a disarticulation was planned under cardiopulmonary bypass.

After anesthetic induction, an intra-arterial catheter 22G was inserted into the left radial artery to check the invasive arterial pressure and cardiac output by using an arterial pressure waveform-derived cardiac index sensor (FloTrac; Edward Lifesciences LLC, Irvine, CA, USA) and monitor (Vigileo, Edward Lifesciences LLC). Further, a central venous catheter was positioned into the left subclavian vein.

After induction, the mean arterial pressure was maintained between 60 and 80 mmHg. The cardiac index (CI) and the central venous pressure (CVP) were recorded at 10 and 18,

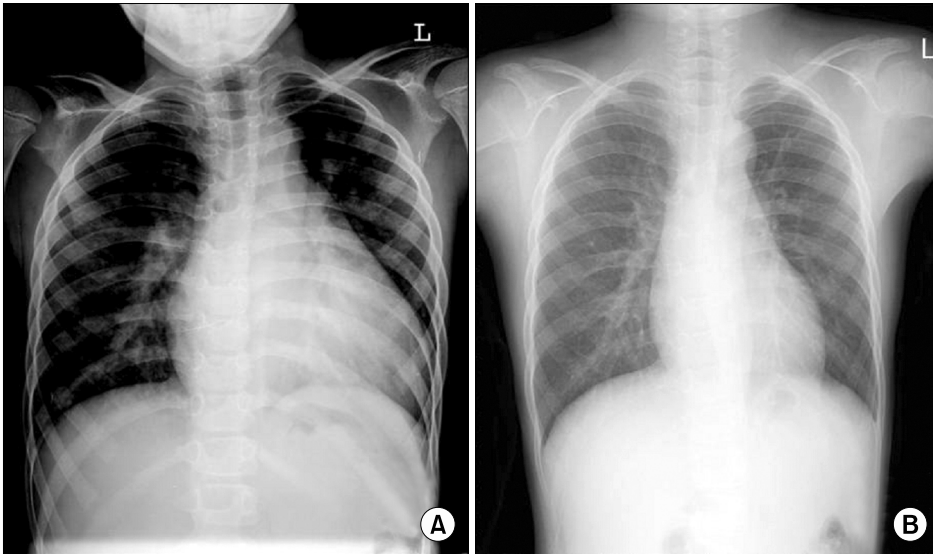
respectively, which were considered to be high.

After heparinization, the right iliac artery was cannulated using an 18 French (Fr) cannula, and a 24 Fr venous cannula was placed through the right iliac vein. Partial cardiopulmonary bypass (CPB) was commenced at a flow rate of 1,200 mL/m<sup>2</sup>/min. The patient's body was maintained at a normal temperature, and the activated clotting time was greater than 400 seconds throughout the CPB. During a partial CPB, a continuous intravenous infusion of milrinone 0.5 µg/kg/min was used to improve the right ventricle function by decreasing the pulmonary vascular resistance. After the initiation of CPB, the CI and CVP were lowered to 2.5 and 3, respectively. The amputation was performed at the level of the proximal one-third of the right femur. The CPB time was 180 minutes. After heparin neutralization using protamine, the patient was weaned off of the bypass with 0.1 µg/kg/min of norepinephrine and 0.5 µg/kg/min of milrinone. Despite the use of CPB, the blood loss was extensive, and a transfusion of 8 units of packed red cells, 6 units of fresh frozen plasma, and 5 units of cryoprecipitate was required.

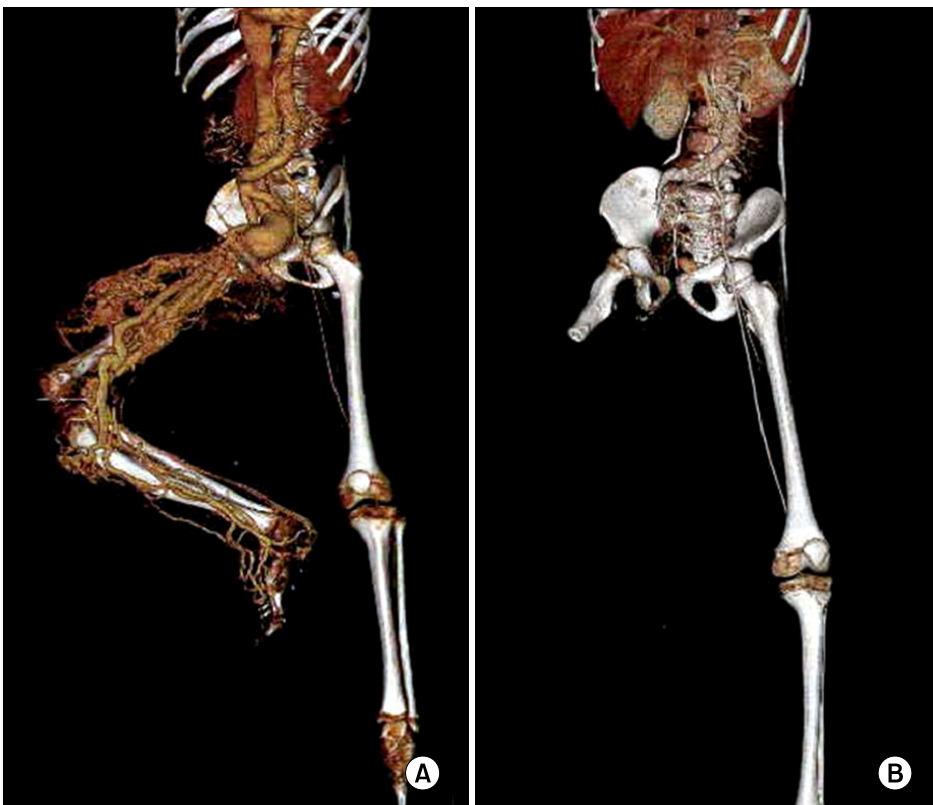
He was extubated on the following day. The postoperative period was uneventful, and he recovered fully with no neurologic deficit. A two-dimensional echocardiography, which was performed a week after surgery, showed a significantly smaller cardiac chamber. Two months after surgery, no residual lesion was observed in a CT angiography (Fig. 3B), and a chest X-ray was unremarkable without cardiomegaly (Fig. 2B).

## DISCUSSION

AVM, an abnormal connection between an artery and a vein with a bypass of the capillary bed [1], can occur anywhere in the body. However, certain anatomical sites, such as the pelvis, extremities, lungs, and brain, seem to be commonly affected [2]. Many AVMs regress spontaneously. Although smaller AVMs are usually asymptomatic, larger AVMs may cause cosmetic disfiguration, functional impairment, distal ischemia, and even hemorrhage due to ulceration in the limb [3,4]. Finally, AVM may lead to cardiac decompensation and death, if not treated. A large AVM with a significant shunt between the artery and the vein causes a



**Fig. 2.** A preoperative chest X-ray shows (A) marked cardiomegaly with increased pulmonary vascularities. (B) A postoperative chest X-ray shows unremarkable finding without cardiomegaly.



**Fig. 3.** A preoperative computed tomographic (CT) angiography of the right lower extremity (A) revealed extensive arteriovenous malformation with feeding arteries from branches of right profunda femoris artery and superficial femoral artery. (B) A postoperative CT angiography.

chronic volume overload of the heart, which leads to remodeling, ventricular dilatation, and heart failure [4]. Our patient was presented with extensive AVM involving the right lower limb, which induced limb length inequality, significant pain of the affected lesion, and moderate cardiomegaly. Since he

had suffered from recurrences of AVM in spite of previous sclerotherapy and his AVM was thought to be life-threatening, an amputation of the affected limb was recommended.

Management of AVM varies, with a conservative approach adopted for patients who are asymptomatic or have minor

symptoms. Symptomatic AVMs may be treated using techniques such as percutaneous sclerotherapy, endovascular embolization, or surgery [3,4]. Complete eradication of the nidus of AVM has been known to be the only option for a potential cure. However, surgical treatment alone can result in massive bleeding during the surgery and can be life-threatening. In addition, surgical trauma and incomplete resection with a remnant nidus can result in the explosive growth of AVM due to a high blood flow between the arteries and the veins. Therefore, to minimize the complications related with surgery, a multidisciplinary approach should be considered [3]. Embolization has been commonly used for reducing the vascularity of extensive AVM before surgery. Anoop et al. [4] reported a case of huge subclavian AVM causing heart failure, which was treated using embolization followed by surgical resection. In our patient, preoperative embolization was also attempted, but it failed due to a decompensated cardiac function that was unable to withstand an abrupt increase in the SVR at the moment of pressure application to the right proximal thigh using a tourniquet for catheter embolization.

As an alternative method for reducing the risk of massive bleeding during surgery, CPB was considered. CPB has been used for managing massive vascular lesions when vascular control cannot be achieved by conventional methods. There was one case of vascular malformation of the lower limb undergoing hip disarticulation under CPB; this case has been reported in the literature [5]. CPB enables the resection to proceed in a bloodless field and the surgeon to identify the adjacent structures, thereby minimizing the risk of damage to these structures and enabling a more complete resection. In patients with significant right-side heart failure, surgical resection with CPB is relatively beneficial because it provides a more prompt resolution of heart failure than multiple embolization [6]. The effects of CPB and heparin may result in significant postoperative bleeding. Fortunately, no bleeding tendency was observed and no other complications occurred postoperatively.

Milrinone is an inotropic drug with vasodilator activity that has been shown to be useful in increasing cardiac output and decreasing wedge pressure. As a phosphodiesterase III inhibitor, it prevents degradation of cyclic adenosine monophosphate in cardiac myocytes in order to increase the con-

tractile force of the heart muscle, and it relaxes the vascular smooth muscle to reduce systemic vascular resistance, as well as pulmonary vascular resistance [7]. Studies on patients with low right ventricular function have shown that milrinone increases the cardiac index while reducing systemic vascular resistance, thereby playing a beneficial role in improving the right ventricular function [8]. In our patient, intravenous infusion of milrinone was administered at 0.5 µg/kg/min in order to prevent the worsening of the existing heart failure, thereby improving cardiac function and maintaining hemodynamic stability. Although milrinone can induce hypotension and arrhythmia, these complications did not develop.

In conclusion, to manage AVMs successfully, a careful assessment of the treatment strategy before the treatment is important and there must be a positive balance between subsequent morbidity and treatment gains from a plan. This case of AVM implies the need for a multidisciplinary approach that must be tailored to each patient. Based on this concept, CPB may be considered an efficient adjunctive method for the treatment of extensive AVM in which surgical resection is necessary.

## CONFLICT OF INTEREST

No potential conflict of interest relevant to this article was reported.

## REFERENCES

1. Duncan JM, Cooley DA, Vargo TA, Gutgesell HP. *Successful surgical management of congenital arteriovenous fistula of the subclavian artery: case report.* Cardiovasc Dis 1978;5:139-43.
2. Ching AS, Chan PN, Cheung H, Chan YL, Metreweli C. *CT and DSA appearances of a ruptured congenital arteriovenous malformation of the posterior mediastinal aorta.* Br J Radiol 2000;73:1320-2.
3. Lee BB, Do YS, Yakes W, Kim DI, Mattassi R, Hyon WS. *Management of arteriovenous malformations: a multidisciplinary approach.* J Vasc Surg 2004;39:590-600.
4. Anoop TM, Sreejith P, Thomas JK, et al. *Congenital subclavian arteriovenous malformation causing cardiac failure in an adult.* J Am Soc Echocardiogr 2009;22:864.e5-6.
5. Ismail MS, Sharaf I, Thambidorai CR, et al. *Cardiopulmonary bypass in surgery for complex-combined vascular mal-*

- formation of the lower limb: case report. Pediatr Surg Int* 2005;21:392-5.
6. McCready RA, Fehrenbacher JW, Divelbiss JL, Bryant A, Savader S. *Surgical resection of a large recurrent pelvic arteriovenous malformation using deep hypothermic circulatory arrest. J Vasc Surg* 2004;39:1348-50.
  7. Borow KM, Come PC, Neumann A, Baim DS, Braunwald E, Grossman W. *Physiologic assessment of the inotropic, vasodilator and afterload reducing effects of milrinone in subjects without cardiac disease. Am J Cardiol* 1985;55:1204-9.
  8. Lee JH, Oh YJ, Shim YH, Hong YW, Yi G, Kwak YL. *The effect of milrinone on the right ventricular function in patients with reduced right ventricular function undergoing off-pump coronary artery bypass graft surgery. J Korean Med Sci* 2006;21:854-8.