

Neurovascular Bundle Decompression without Excessive Dissection for Tarsal Tunnel Syndrome

Kyongsong KIM,¹ Toyohiko ISU,² Daijiro MORIMOTO,³ Toru SASAMORI,²
Atsushi SUGAWARA,⁴ Yasuhiro CHIBA,² Masahiro ISOBE,² Shiro KOBAYASHI,¹
and Akio MORITA³

¹Department of Neurosurgery, Chiba Hokuso Hospital, Nippon Medical School, Inzai, Chiba;

²Department of Neurosurgery, Kushiro Rosai Hospital, Kushiro, Hokkaido;

³Department of Neurosurgery, Nippon Medical School, Tokyo;

⁴Department of Neurosurgery, Iwate Medical University, Morioka, Iwate

Abstract

Tarsal tunnel syndrome (TTS) is an entrapment neuropathy of the posterior tibial nerve and its branches in the tarsal tunnel. We present our less invasive surgical treatment of TTS in 69 patients (116 feet) and their clinical outcomes. The mean follow-up period was 64.6 months. With the patient under local anesthesia we use a microscope to perform sharp dissection of the flexor retinaculum and remove the connective tissues surrounding the posterior tibial nerve and vessels. To prevent postoperative adhesion and delayed neuropathy, decompression is performed to achieve symptom improvement without excessive dissection. Decompression is considered complete when the patient reports intraoperative symptom abatement and arterial pulsation is sufficient. The sensation of numbness and/or pain and of foreign substance adhesion was reduced in 92% and 95% of our patients, respectively. In self-assessments, 47 patients (68%) reported the treatment outcome as satisfactory, 15 (22%) as acceptable, and 7 (10%) were dissatisfied. Of 116 feet, 4 (3%) required re-operation, initial decompression was insufficient in 2 feet and further decompression was performed; in the other 2 feet improvement was achieved by decompression of the distal tarsal tunnel. Our surgical method involves neurovascular bundle decompression to obtain sufficient arterial pulsation. As we use local anesthesia, we can confirm symptom improvement intraoperatively, thereby avoiding unnecessary excessive dissection. Our method is simple, safe, and without detailed nerve dissection and it prevents postoperative adhesion.

Key words: decompression, entrapment neuropathy, tarsal tunnel syndrome

Introduction

Tarsal tunnel syndrome (TTS) is an entrapment neuropathy of the posterior tibial nerve and its branches in the tarsal tunnel on the medial side of the ankle.^{1–3)} Its accurate diagnosis is difficult and TTS is regularly under-diagnosed, leading to a range of symptoms affecting the plantar aspect of the foot.^{1,4)} Its etiology has been ascribed to tumors, changes in anatomical structures due to trauma, and idiopathic factors such as tortuous veins, hypertrophy of the flexor retinaculum muscle, and fibrosis of a variety of origins.^{5–11)}

Although patients may benefit from surgery, the management of this entrapment neuropathy remains challenging.¹⁾ While direct nerve decompression,

neurolysis, and the insertion of fat tissue between the tibial nerve and vessels have been used to address TTS, their execution is difficult because the tibial nerve is thin and postoperative adhesion may occur. Our treatment method involves neurovascular bundle decompression without excessive dissection. It is simple, safe, and without detailed nerve dissection, and it prevents postoperative adhesion. Here we present our procedure and the treatment outcomes in patients with idiopathic TTS.

Patients and Methods

The senior author (T.I.) operated 116 feet in 69 patients. They were 32 men and 37 women ranging in age from 35 years to 90 years (average 69.2 years) at the time of treatment. One foot was affected in 22- and both feet in 47 patients. The mean follow-up

period was 64.6 months (range 59–72 months). All patients presented with idiopathic disease, no patients with TTS due to tumor or with lumbar degenerative disease or arteriosclerosis obliterans were included. The 69 patients underwent lumbar magnetic resonance imaging (MRI) and assessment of the ankle brachial pressure index. Nine patients (13%) had medically-treated diabetes mellitus, and 32 (46%) had previously undergone spinal surgery for cervical (n = 2), thoracic (n = 1), and lumbar lesions (n = 29) that failed to abate their symptoms completely. Persistent numbness and pain in the anterior sole was the main complaint after spinal surgery.

Our diagnosis was primarily based on clinical symptoms. All patients complained of sensory disturbance in the sole of the affected foot. There were 106 feet (91%) with paresthesia, 79 (68%) with a foreign-body sensation like walking on gravel, 57 (49%) with a cold sensation, and 54 (47%) with burning or tingling sensation (Table 1). The symptoms did not involve the heel of the affected foot (heel sparing).^{1,7,11–14} In all patients, prolonged standing or walking exacerbated their symptoms; 90 feet (78%) were positive for the Tinel-like sign, a radiating pain due to compression at the entrapment point of the tibial nerve in the tarsal tunnel.

We operated patients in whom 3-month conservative treatment with anti-inflammatory drugs, immobilization, and stretching or massaging of the ankle joint failed. We explained the surgical procedure and obtained prior informed consent from all patients.

I. Surgical procedure

We first make a 3–4 cm bow-like skin incision 1.5 cm below the medial malleolus over the point of the Tinel-like sign (Fig. 1) without using a tourniquet. All surgical procedures are performed under local anesthesia with 1% lidocaine, infiltrated

superficially into the incision to avoid a nerve block. To make it possible for the patient to report symptom improvement intraoperatively, we do not administer sedatives. Using a microscope we dissect the flexor retinaculum sharply from the proximal end of the tarsal tunnel to its distal end at the edge of the abductor pollicis muscle (Fig. 2A).

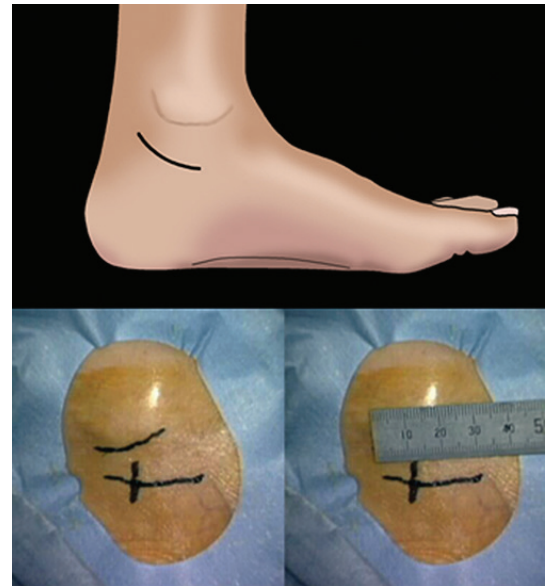


Fig. 1 A 3–4 cm bow-like skin incision is made 1.5 cm below the medial malleolus over the point of the Tinel-like sign.

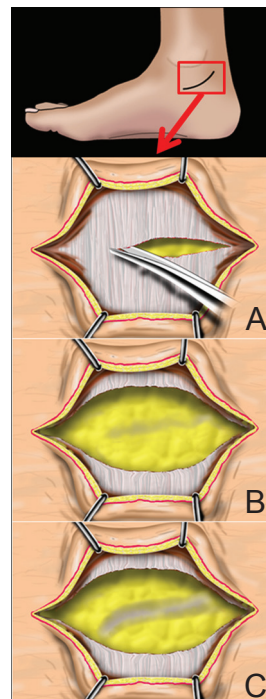


Fig. 2 A: Under a microscope the flexor retinaculum is dissected sharply from the proximal end of the tarsal tunnel to its distal end. B: Dissection of the flexor retinaculum may be insufficient for symptom relief and arterial pulsation. C: When necessary, for sufficient decompression, we remove more connective tissues surrounding the posterior tibial nerve and vessels. To protect important structures we do not completely remove fat tissue surrounding the tibial nerve and vessels.

Table 1 Symptoms of tarsal tunnel syndrome and postoperative changes (116 feet)

Symptoms	Before surgery	After surgery		
		Disappeared	Reduced	No change
Numbness	106 (91%)	33 (31%)	65 (61%)	8 (8%)
Foreign-body sensation	79 (68%)	26 (33%)	49 (62%)	4 (5%)
Cold sensation	57 (49%)	24 (42%)	24 (42%)	9 (16%)
Burning sensation	54 (47%)	19 (35%)	32 (59%)	3 (6%)

As dissection of the abductor pollicis muscle elicits postoperative pain we do not routinely dissect this muscle. After dissection of the flexor retinaculum we confirm pulsation in the posterior tibial artery. If the patient at this point reports more than 50% symptom reduction and disappearance of the Tinel-like sign, and if arterial pulsation is adequate we consider decompression of the tarsal tunnel to be completed. If symptom relief and arterial pulsation are insufficient (Fig. 2B) we proceed to further removal of connective tissue surrounding the posterior tibial nerve and vessels. To prevent postoperative adhesion and delayed neuropathy, decompression is carried out until the patient reports symptom improvement. We neither avoid excessive dissection, i.e., dissection into the neurovascular bundle to separate the nerve and vessels, nor do we completely remove the fat tissue surrounding the tibial nerve and vessels (Fig. 2C). However, in rare cases with insufficient intraoperative symptom relief and inadequate arterial pulsation we may perform dissection between the vessels and nerves, or coagulation, and we may cut a part of the vein. Skin closure is performed without closure of the dissected retinaculum. After surgery the patients are allowed to walk without cast immobilization; they can be discharged the next day.

II. Evaluation of the surgical results

We used patient self-assessments to evaluate postoperative changes in their symptoms and their degree of satisfaction (satisfied, acceptable, and dissatisfied) and we analyzed factors contributing to low satisfaction.

Results

In all 69 patients, arterial pulsation was insufficient before- and improved after dissection. However, insufficiency in the arterial pulsation was not related to preoperative clinical ischemia. In 2 feet, arterial pulsation and symptom relief were insufficient upon removal of connective tissue surrounding the posterior tibial nerve and vessels. Under these conditions we performed coagulation and cut a part of the vein.

As shown in Table 1, preoperative numbness and pain disappeared in 33 of 106 feet (31%) with paresthesia and decreased in 65 (61%); in 8 (8%) there was no change. The sensation of walking on gravel disappeared in 26 of 79 feet (33%) and was decreased in 49 (62%); in 4 (5%) there was no change. The sensation of coldness disappeared or was decreased in 24 of 57 feet (42%) and remained unchanged in 9 (16%); burning disappeared in 19

of 54 feet (35%), was decreased in 32 (59%), and was unchanged in 3 feet (5%).

Based on their self-assessments, 47 of the 69 patients (68%) were satisfied with the results, 15 (22%) found them acceptable, and 7 (10%) were dissatisfied. Of the 7 dissatisfied patients, one each had a history of ankle joint fracture, Morton disease, or plantar fasciitis. The other 4 patients (4 feet, 3%) underwent re-operation. In 2 the initial decompression was insufficient and they underwent additional decompression surgery. At the time of re-operation we performed dissection between vessels and nerves to obtain sufficient arterial pulsation and applied decompression because adhesion resulted in insufficient arterial pulsation. In these cases we were unable to determine whether re-operation was necessary because pulsation remained insufficient after the initial surgery or whether dissection between the vessels and nerve was necessary at the first operation. The re-operated patients reported postoperative symptom improvement.

In the other two patients we observed entrapment at the distal tarsal tunnel; additional decompression of the distal tarsal tunnel yielded sufficient symptom improvement.

Discussion

The tarsal tunnel is a fibro-osseous tunnel under the flexor retinaculum muscle below the medial malleolus. The posterior tibial nerve that bifurcates into the medial and lateral plantar nerve passes inside the tarsal tunnel together with the posterior tibial artery and vein. TTS is an entrapment neuropathy of the posterior tibial nerve within the tarsal tunnel. Tumors (e.g., ganglions and neuromas), changes in the anatomical structure due to trauma, tortuous veins, hypertrophy of the flexor retinaculum muscle, and fibrosis of different origins contribute to the manifestation of TTS.^{1,5-11} Idiopathic TTS includes conditions in which no nerve-compressing lesion is evident. Arterial and tortuous vein compression may elicit TTS although a tortuous vein may be considered a normal variation.⁷ According to earlier reports, in 18-69% of patients with TTS the etiology was idiopathic.^{11,14,15} Our series did not include patients with space-occupying masses, all patients presented with idiopathic TTS and some with tortuous veins.

As the diagnosis of TTS is not easy, the presenting clinical symptoms are of great importance.^{1,4} Although sonography,¹⁶ computed tomography, MRI,¹⁷ and electrophysiological studies⁹ have been reported to be diagnostically useful especially in patients with space-occupying lesions, the identification of

idiopathic TTS remains difficult. TTS cannot be diagnosed by electrophysiological means alone.^{1,6,18,19)} A symptomatology involving numbness and pain in the sole of the foot and radiating numbness and pain due to compression at the entrapment point (the Tinel-like sign) provide diagnostic clues.¹³⁾ Heel sparing by the symptom is useful for the diagnosis of TTS because the calcaneal branch of the posterior tibial nerve branches proximal to the tarsal tunnel and is not involved.^{7,11,12-14)} One of the best indicators for a favorable outcome after decompression surgery is a positive Tinel sign,⁴⁾ thought to be the most reliable diagnostic criterion.^{11,13,14,20,21)} Kinoshita et al.²²⁾ recommended that a positive Tinel sign and local tenderness over the tibial nerve be verified by tapping on or compressing the tibial nerve at the tarsal tunnel with the ankle in the dorsiflexion-eversion position. Of our 116 feet, 79 (68%) manifested a foreign-body sensation akin to walking on gravel and 90 (78%) were positive for a Tinel-like sign. These symptoms combined with findings returned by Kinoshita's provocation ankle position are diagnostically valuable and may increase the number of confirmed TTS cases.

The co-existence of TTS and spinal disease may affect the outcome of spinal surgery. Although we cannot rule out selection bias, we found that after spinal surgery, one-third of our patients suffered residual TTS symptoms, even though their radicular pain and/or myelopathy had subsided. The symptoms of TTS may be misdiagnosed as part of the symptomatology of spinal disease and as sequelae after spinal surgery. In our patients, their intolerable residual symptoms improved after our treatment procedure. Our findings indicate that TTS must be considered and addressed when patients treated by spinal surgery continue to experience numbness and/or pain of the anterior sole.

In patients with lumbar disease or TTS it can be difficult to identify the origin of their sole numbness preoperatively although TTS should be ruled out in patients with sole- but not heel numbness and a Tinel-like sign over the tarsal tunnel. However, postoperative residual symptoms may be tolerable and observation therapy alone may be appropriate in many patients. However, severe symptoms affect their activities of daily living negatively and cannot be addressed by observation therapy alone. In such situations TTS surgery may help to alleviate their symptoms.

The effectiveness of conservative therapy including anti-inflammatory drugs and physiotherapy comprised of a variety of techniques such as taping, bracing, stretching, icing, massaging, and ultrasound have

not been documented^{6,23)} and when it fails, surgery becomes an option. Methods to treat idiopathic TTS include tarsal tunnel opening by dissection of the flexor retinaculum,²⁴⁾ nerve decompression of the posterior tibial nerve and its branches,^{15,19,25,26)} resection of the veins or arterial branches,^{2,13)} and the insertion of fat tissue between the tibial nerve and vessels to act as a cushion and prevent their adherence to each other.⁷⁾

Our surgical method involves dissection of the flexor retinaculum and connective tissue around the neurovascular bundle of the tibial nerve and vessels. It differs from simple dissection of the flexor retinaculum in that decompression of the vessel bundle is obtained by providing sufficient arterial pulsation. Components in the tarsal tunnel are separated by a septum^{12,15)} and slight changes in this space can easily result in neuropathy. The neurovascular bundle in the tarsal tunnel is accompanied by loose adipose tissue and it is fixed relatively firmly to its surroundings.²²⁾ As the neurovascular bundles are often attached to these septa, they are more vulnerable to minor degrees of traction upon foot movement.^{5,12)} In our experience the layer under the tarsal tunnel is not a simple one-layer structure. Microscopic inspection shows that in most patients with idiopathic TTS there is overlapping of the membrane and connective tissue on the surface of the tibial nerve, vein, and artery, and adhesions of connective tissue are observed even in the absence of a history of trauma or surgery. Consequently, for adequate decompression of the tarsal tunnel, dissection of only the outer single layer of the flexor retinaculum is insufficient. Rather, only if sufficient arterial pulsation is achieved by careful dissection of several layers and connective tissue under the flexor retinaculum can indirect decompression of the neurovascular bundle be considered successful. Although we cannot deny that in some cases dissection between the nerves and vessels is necessary, we obtained sufficient arterial pulsation and satisfactory results with minimum dissection around the nerves.

Because we used local anesthesia we could check intraoperatively for symptom improvement and disappearance of the Tinel-like sign in all our patients. This helped to avoid unnecessary excessive dissection and reduced the incidence of surgical complications. Our patients were also able to notify the surgeon of radiating pain and this may help to protect nerves and vessel branches that are difficult to protect from iatrogenic injury.^{6,7)} Restrained dissection of fat tissue around the nerve and vessels prevents bleeding and postoperative adhesion.

Table 2 Surgical procedures to treat idiopathic tarsal tunnel syndrome and treatment outcomes

Surgical procedure	Cases	F/U (months)	Effectiveness (%)	Complications
Only tarsal tunnel opening ²⁴⁾	28	N/L	N/L	N/L
PTN direct decompression ¹⁵⁾	10	N/L	E 80, G 10, F 10	N/L
PTN direct decompression ¹⁹⁾	32 (feet)	31	E 16, G 28, F 19, P 38	13% wound infection
PTN direct decompression ²⁶⁾	18	8	E 72, G 2, P 6	N/L
Resection of vessels ¹³⁾	24	24	G 50, F 29, P 21	None
Insertion of fat tissue between PTN and vessels ⁷⁾	9	27	E 55, G 36, F 9	None
Our procedure	69	65	Sa 68, Ac 22, Dissa 10	None

Ac: acceptable, Dissa: dissatisfied, E: excellent, F: fair, F/U: follow-up periods, G: good, N/L: not listed, P: poor, PTN: posterior tibial nerve, Sa: satisfied with the results.

In addition, postoperative management does not require immobilization and patients can walk immediately and resume to their normal lives.

Although the outcome of surgery for idiopathic TTS is generally good, some patients experience only partial or no improvement (Table 2).^{1,2,13,15,19,25,26)} In 44–96% of patients, significant symptom improvement was reported after tarsal tunnel decompression.^{14,15,19,25,26)} The surgical results were satisfactory in 62 of our 69 patients (90%) and similar to earlier studies. However, 7 patients reported poor results; in 2 there was insufficient decompression of the tarsal tunnel at the first operation, 2 other patients manifested distal TTS, and one patient each had a history of ankle joint fracture, Morton's disease, or plantar fasciitis. Reported factors that affect the surgical results are fibrosis around the nerve, the severity of the preoperative condition, a history of sprained ankle, heavy work, and prolonged symptom duration.^{4,11,27)} DiGiovanni et al.²⁸⁾ who evaluated a subset of patients with chronic proximal plantar fasciitis and distal TTS introduced a surgical technique that combines complete plantar fascia release and proximal and distal tarsal tunnel release. They found that operated patients had high rates of total satisfaction (82%) and that many reported resolution of pain and elimination of activity limitations.

In conclusion, our surgical method that involves neurovascular bundle decompression produced symptom relief in patients with TTS. The use of local anesthesia makes it possible for the patients to report symptom improvement intraoperatively, thereby avoiding unnecessary excessive dissection. Our method is simple and safe, it does not require detailed nerve dissection, and it prevents postoperative adhesion.

Conflicts of Interest Disclosure

None.

Neurol Med Chir (Tokyo) 54, November, 2014

References

- Ahmad M, Tsang K, Mackenney PJ, Adedapo AO: Tarsal tunnel syndrome: A literature review. *Foot Ankle Surg* 18: 149–152, 2012
- Keck C: The tarsal tunnel syndrome. *J Bone Joint Surg Am* 44: 180–182, 1962
- LAM SJ: A tarsal-tunnel syndrome. *Lancet* 2: 1354–1355, 1962
- Baba H, Wada M, Annen S, Azuchi M, Imura S, Tomita K: The tarsal tunnel syndrome: evaluation of surgical results using multivariate analysis. *Int Orthop* 21: 67–71, 1997
- Dowling GL, Skaggs RE: Neurilemoma (schwannoma) as a cause of tarsal tunnel syndrome. Case report and review. *J Am Podiatry Assoc* 72: 45–48, 1982
- Gould N, Alvarez R: Bilateral tarsal tunnel syndrome caused by varicosities. *Foot Ankle* 3: 290–292, 1983
- Kohno M, Takahashi H, Segawa H, Sano K: Neurovascular decompression for idiopathic tarsal tunnel syndrome: technical note. *J Neurol Neurosurg Psychiatr* 69: 87–90, 2000
- Matricali B: Tarsal tunnel syndrome caused by ganglion compression. *J Neurosurg Sci* 24: 183–185, 1980
- Park TA, Del Toro DR: The medial calcaneal nerve: anatomy and nerve conduction technique. *Muscle Nerve* 18: 32–38, 1995
- Tachibana S, Saegusa H, Suzuki S, Yamazaki Y, Iida H: Latent tarsal tunnel syndrome with the provocation of flexor spasms in a paraplegic person. Case report. *Paraplegia* 33: 482–484, 1995
- Takakura Y, Kitada C, Sugimoto K, Tanaka Y, Tamai S: Tarsal tunnel syndrome. Causes and results of operative treatment. *J Bone Joint Surg Br* 73: 125–128, 1991
- Edwards WG, Lincoln CR, Bassett FH, Goldner JL: The tarsal tunnel syndrome. Diagnosis and treatment. *JAMA* 207: 716–720, 1969
- Linscheid RL, Burton RC, Fredericks EJ: Tarsal-tunnel syndrome. *South Med J* 63: 1313–1323, 1970
- Radin EL: Tarsal tunnel syndrome. *Clin Orthop Relat Res* 167–170, 1983

- 15) Lam SJ: Tarsal tunnel syndrome. *J Bone Joint Surg Br* 49: 87–92, 1967
- 16) Nagaoka M, Matsuzaki H: Ultrasonography in tarsal tunnel syndrome. *J Ultrasound Med* 24: 1035–1040, 2005
- 17) Reade BM, Longo DC, Keller MC: Tarsal tunnel syndrome. *Clin Podiatr Med Surg* 18: 395–408, 2001
- 18) Galardi G, Amadio S, Maderna L, Meraviglia MV, Brunati L, Dal Conte G, Comi G: Electrophysiologic studies in tarsal tunnel syndrome. Diagnostic reliability of motor distal latency, mixed nerve and sensory nerve conduction studies. *Am J Phys Med Rehabil* 73: 193–198, 1994
- 19) Pfeiffer WH, Cracchiolo A: Clinical results after tarsal tunnel decompression. *J Bone Joint Surg Am* 76: 1222–1230, 1994
- 20) Mann RA: Tarsal tunnel syndrome. *Orthop Clin North Am* 5: 109–115, 1974
- 21) Satoh K, Kanazawa N, Egawa M: Clinical study on tarsal tunnel syndrome. *Seikei Geka* 37: 271–279, 1986 (Japanese)
- 22) Kinoshita M, Okuda R, Morikawa J, Jotoku T, Abe M: The dorsiflexion-eversion test for diagnosis of tarsal tunnel syndrome. *J Bone Joint Surg Am* 83-A: 1835–1839, 2001
- 23) Alshami AM, Babri AS, Souvlis T, Coppieters MW: Strain in the tibial and plantar nerves with foot and ankle movements and the influence of adjacent joint positions. *J Appl Biomech* 24: 368–376, 2008
- 24) DiStefano V, Sack JT, Whittaker R, Nixon JE: Tarsal-tunnel syndrome. Review of the literature and two case reports. *Clin Orthop Relat Res* 88: 76–79, 1972
- 25) Hendrix CL, Jolly GP, Garbalosa JC, Blume P, DosRemedios E: Entrapment neuropathy: the etiology of intractable chronic heel pain syndrome. *J Foot Ankle Surg* 37: 273–279, 1998
- 26) Kaplan PE, Kernahan WT Jr: Tarsal tunnel syndrome: an electrodiagnostic and surgical correlation. *J Bone Joint Surg Am* 63(1): 96–99, 1981
- 27) Sammarco GJ, Chang L: Outcome of surgical treatment of tarsal tunnel syndrome. *Foot Ankle Int* 24: 125–131, 2003
- 28) DiGiovanni BF, Abuzzahab FS, Gould JS: Plantar fascia release with proximal and distal tarsal tunnel release: a surgical approach to chronic, disabling plantar fasciitis with associated nerve pain. *Tech Foot Ankle Surg* 2: 254–261, 2003

Address reprint requests to: Kyongsong Kim, MD, Department of Neurosurgery, Chiba Hokusyo Hospital, Nippon Medical School, 1715 Kamagari, Inzai city, Chiba 270-1694, Japan.
e-mail: kyongson@nms.ac.jp