

Endoscopic Therapy in Inflammatory Bowel Diseases

Helmut Neumann Markus F. Neurath Raja Atreya

Medical Clinic I, Friedrich-Alexander University Erlangen-Nürnberg, Erlangen, Germany

Keywords

Endoscopy · Endoscopic therapy · Inflammatory bowel diseases · Crohn's disease · Ulcerative colitis

Summary

Background: Endoscopy is an essential diagnostic and therapeutic modality in the clinical care of inflammatory bowel disease (IBD) patients. Endoscopic therapy can be used for treatment of disease-related strictures, surveillance and resection of intraepithelial neoplasia, and treatment of fistulas or disease-related complications, and is currently being evaluated regarding its capacity in in vivo molecular imaging procedures. **Methods:** A literature search using Medline and Science Citation Index was performed in March 2015. All studies on endoscopic therapy in IBD published from 1980 to 2015 (March) were reviewed. Potential studies were initially screened by title and abstract. The terms 'endoscopy IBD', 'endoscopy therapy IBD', 'dilatation IBD', 'stricture-plasty Crohn's disease', 'endoscopy therapy fistula', 'endoscopy toxic megacolon', 'endoscopy dysplasia IBD', 'endoscopy complications IBD', and 'molecular imaging IBD' were used in the search. A total of 115 articles were studied to construct this review. **Results:** Dilatation is most useful in short anastomotic strictures, but can be also undertaken in colonic strictures. Strictures in ulcerative colitis are always suspicious for neoplasia and should be evaluated carefully. Lesions with intraepithelial neoplasia can be resected when complete removal can be assured. The finding of carcinoma or high-grade dysplasia in a random biopsy is an indication for colectomy. If intraepithelial neoplasia is present in random biopsy specimens, colectomy should similarly be recommended. Endoscopic therapy of Crohn's fistulas is a possible emerging technology. In vivo molecular imaging is currently being studied in IBD patients and offers promising therapeutic opportunities. **Conclusion:** Thera-

peutic endoscopy is indispensable in the management of IBD. It has to be carefully evaluated against alternative surgical options but often offers an effective therapeutic approach.

© 2015 S. Karger GmbH, Freiburg

Introduction

Inflammatory bowel diseases (IBD) comprise Crohn's disease and ulcerative colitis, and are defined as chronic relapsing inflammation of the gastrointestinal tract not due to specific pathogens. Although the etiology of IBD is still debated, increasing evidence suggests that it results from an inappropriate inflammatory response to intestinal microbes in a genetically susceptible host. Excessive production of proinflammatory cytokines and increased resistance of intestinal T cells to apoptosis are finally leading to an uncontrolled chronic activation of the mucosal immune system [1–3]. Both entities show a growing incidence with approximately 1.4 million persons in the United States and 2.2 million persons in Europe suffering from these diseases [4]. Patients with IBD can suffer from persistent diarrhea, malabsorption, weight loss, abdominal pain, fever, and often rectal bleeding [5]. In addition, various extra-intestinal manifestations are associated with IBD and can affect the eyes, skin, joints, and liver [6]. Moreover, patients with ulcerative colitis or Crohn's colitis have an increased risk for development of colitis-associated neoplasia [7].

Endoscopy plays an important role in the diagnosis and management of IBD. It can help to establish the diagnosis, exclude diseases of other etiologies, and define the extent and severity of mucosal inflammation. Ileocolonoscopy is also being increasingly used to monitor the course of disease and optimize the therapeutic management. It is also indispensable in the surveillance for mucosal dysplasia or neoplasia. Altogether, the endoscopist plays a pivotal role in the overall management of IBD patients and pro-

vides essential input regarding the best therapeutic approach. In this review, we focus on the endoscopic therapy of patients with IBD and provide an outlook on future developments.

Endoscopic Therapy of IBD-Related Strictures

Dilatation is most useful in anastomotic strictures in Crohn's disease patients (fig. 1–3), but can also be undertaken in colonic strictures. To date, no uniform classification system has been established for IBD-related strictures. Paine and Shen [8] proposed a classification system that includes the etiology, number, degree, shape, length, location, and associated conditions of strictures. It has been estimated that approximately 25% of Crohn's disease patients have had at least 1 small bowel stricture, and 10% have had at least 1 colonic stricture that led to significant complications. Most of these patients will also require at least 1 stricture-related surgery during their lifetime [9].

Endoscopic assessment and biopsy sampling of the stricture is recommended to exclude possible malignancy, especially in the setting of ulcerative colitis where a stricture should be considered malignant until proven otherwise. If the stricture cannot be thoroughly characterized, surgical resection should always be considered.

Surgical therapy of IBD-related strictures is well established; however, it is regularly associated with adverse events and disease recurrence.

A recent systematic review and meta-analysis looked upon the safety and efficacy of strictureplasty in Crohn's disease [10]. A total of 1,112 patients who underwent 3,259 strictureplasties were identified. After jejunoleal strictureplasty, including ileocolonic strictureplasty, septic complications occurred in 4% of patients. Overall, surgical recurrence was 23%, and the 5-year recurrence rate after strictureplasty was 28%. Importantly, recurrence occurred at non-strictureplasty sites in 90% and at site-specific sites in 3%, respectively. 2 patients developed adenocarcinoma.

Apart from surgical interventions, endoscopic management strategies often offer alternative treatment options. Endoscopic therapy of IBD-related strictures includes dilation therapy, local injection of steroids, needle-knife stricturotomy, and endoscopic stent placement [8].

Endoscopic dilation is routinely performed using through-the-scope (TTS) balloons. No technical standards have yet been approved. Hassan et al. [11] evaluated the efficacy and safety of endoscopic dilation in Crohn's disease patients in a systematic review. Overall, 13 studies including 347 patients were reviewed. The technical success rate was 86% with a long-term clinical efficacy of 58% during a mean follow-up of 33 months. Major complications occurred in 2% of patients. Of note, a stricture length ≤ 4 cm was associated with a surgery-free outcome. Patients in 5 studies were dilated to 18 mm, in 6 studies to 20 mm, and in 2 studies to 25 mm.

A recent study including 65 patients evaluated the long-term outcome of endoscopic dilation (12–18 mm TTS balloon) therapy for small-bowel strictures in Crohn's patients [12]. The short-term

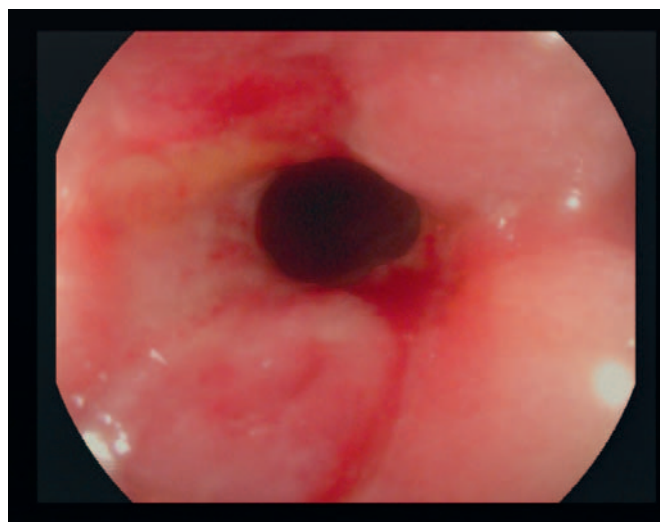


Fig. 1. Anastomotic stricture in a Crohn's disease patient.

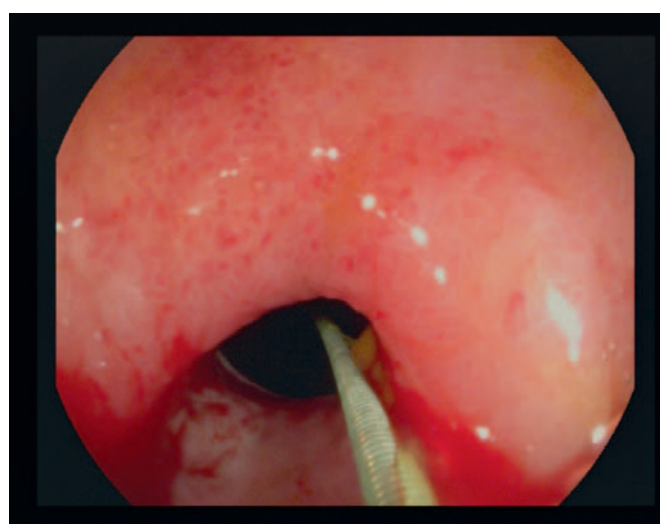


Fig. 2. A guide wire is passed through the stenosis and placed in its center.

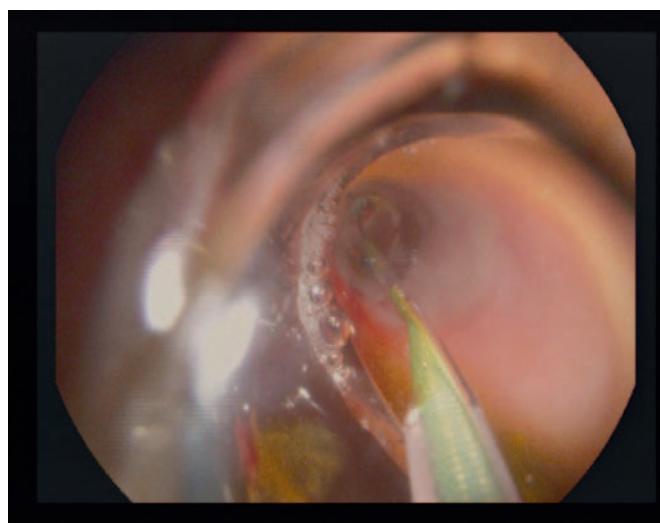


Fig. 3. Balloon dilatation of the anastomotic stricture.

success rate was 80% while complications occurred in 9% of patients. 26% of patients underwent surgery during the observation period of this study.

Whether or not a combined approach of endoscopic dilatation therapy followed by injection of steroids into the stricture may improve patient outcome, is currently unclear, with some studies reporting beneficial effects and others reporting a trend towards a worse outcome [13, 14].

Endoscopic needle-knife stricturotomy was recently introduced as a novel technique for the treatment of ileocolonic and ileal pouch strictures [8]. Preliminary results suggest that this technique is safe, effective, and less expensive compared to surgical approaches, and additional data are highly anticipated.

Only limited data is available regarding endoscopic stent placement for Crohn's disease-related strictures. Various small studies, evaluating both biodegradable and self-expandable metal stents, report favorable outcomes and adequate safety [15, 16]. The stents are normally placed over a guidewire under fluoroscopic guidance and direct endoscopic visualization. Rejchrt et al. [15] reported on 11 patients treated with biodegradable stents. Endoscopic insertion was successful at the first attempt in all patients except one. Early stent migration was seen in 3 patients, and might be reduced by endoscopic suturing devices or the use of the over-the-scope clip [17, 18]. Loras et al. [16] placed 25 stents in 17 patients with stenosis smaller than 8 cm in the colon and ileocolonic anastomosis. Stents were maintained for an average of 28 days, and treatment was effective in 65% of patients after a mean follow-up of 60 weeks.

Endoscopic Therapy of IBD-Related Fistulas

Development of fistulas is common in Crohn's disease patients. Hellers et al. [19] described perianal fistulas in 12% of patients with ileal disease, 15% with ileo-colonic disease, 41% with colonic disease sparing the rectum, and 92% of patients with rectal and colonic Crohn's disease. According to an AGA Technical Review, fistulas are divided into simple and complex types. Complex fistulas usually cause discomfort and are proximal to the dentate line [20]. Endoscopic treatments of fistulas include injection of various substances into the fistula ideally resulting in local inflammation, fibrin extravasation, and tissue adhesion. Hackert et al. [21] described 5 cases treated with local doxycycline instillation. Fistula closure after a single injection of doxycycline was observed in 4 out of 5 patients within 2 days. In 1 patient, injection had to be repeated to achieve closure of the fistula. Drain removal was possible within 4 days after instillation in all patients, and no complications occurred. Other injection agents include highly concentrated sugars (e.g. 50% dextrose) and even honey [8].

Furthermore, fibrin glue is used in order to achieve fistula regression although results are inconsistent [22, 23]. One early study evaluated success rates of endoscopic treatment of postoperative fistulas resistant to conservative management. 2–4 ml of reconstituted fibrin glue were injected through a catheter. The mean healing time was 16 days, and a mean of 2.5 sessions per patient were

required. Complete sealing of fistulas was achieved in 87% of cases, and no complications were encountered. One of the sealed fistulas reopened within the follow-up period (between 2 months and 3 years) [24]. Another study included 42 patients with complex anal fistulas treated with fibrin glue injection [23]. Initially, most patients had closure of the fistula but recrudescence was common. Durable healing was achieved in 31% of patients. Median follow-up for successfully healed fistulas was 26 months. The authors concluded that despite its low success rate fibrin glue treatment should still be considered as a first-line endoscopic treatment for patients with complex anal fistulas because of its low morbidity and the relative simplicity of the procedure.

More recent studies have evaluated endoscopic injection of stem cells into the fistulous tract. One open-labeled, single-arm clinical trial included 24 patients with a follow-up period of 24 weeks. Overall, 56% of patients achieved complete closure of the treated fistula, 69% showed a reduction in the number of draining fistulas, and 30% presented with complete closure of all existing fistula tracts. Treatment-related adverse events did not indicate any clinical safety concerns after 6 months of follow-up [25]. Another multicenter, randomized, single-blinded, add-on clinical trial included 200 patients with complex cryptoglandular perianal fistulas [26]. Patients were randomized to receive stem cell treatment, stem cell treatment plus fibrin glue, or fibrin glue alone after closure of the internal opening. After 24–26 weeks, the healing rates were 39% (stem cell treatment alone), 43% (stem cell treatment plus fibrin glue), and 37% (fibrin glue alone). At 1 year, the healing rates were 57, 52, and 37%, respectively. No statistically significant differences were found when the 3 groups were compared, and no serious adverse events were reported. Additional studies evaluating the response to endoscopically delivered stem cells are highly anticipated.

Toxic Megacolon

Endoscopic treatment of toxic megacolon in patients with ulcerative colitis is restricted. The recent ASGE (American Society for Gastrointestinal Endoscopy) guideline on endoscopy in the diagnosis and treatment of IBD states that full colonoscopy is contraindicated in these patients [27]. Single historical case reports describe endoscopic colonic decompression and placement of colonic tubes in affected patients [28, 29]. However, adequate surgical therapy is of crucial importance in these patients and should not be delayed by use of endoscopic techniques.

Endoscopic Therapy of Dysplastic Lesions in IBD

The risk of developing neoplasia leading to colorectal cancer (CRC) is significantly increased in ulcerative colitis and colonic Crohn's disease [7, 30]. Results of a population-based study from Sweden estimated that the overall risk of colorectal cancer in IBD was 95 cases per 100,000 population [31]. Recent data indicate that

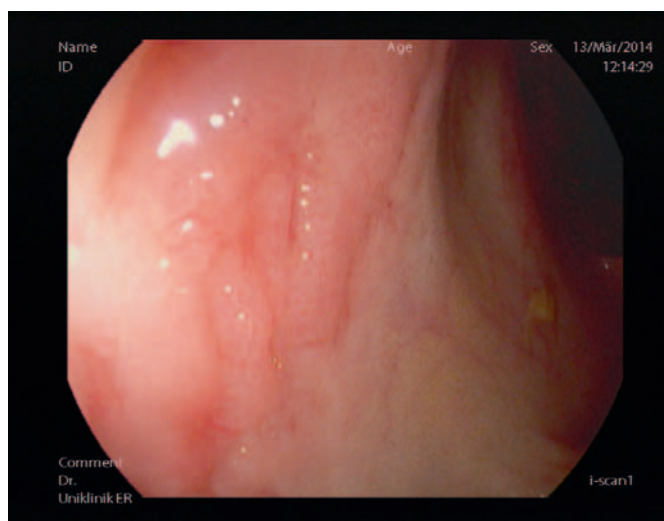


Fig. 4. Endoscopic appearance of a lesion suspected to be a DALM in a patient with long-standing ulcerative colitis.

the risk of CRC in ulcerative colitis patients appears to have decreased over time [32–34]. It remains unclear, however, if this is the result of improved medical therapies and dysplasia surveillance.

The overall risk is related to the duration and anatomic extent of the disease [35, 36]. Moreover, ulcerative colitis patients with concomitant primary sclerosing cholangitis (PSC) have an increased risk for CRC compared to those without PSC [33].

It is the general consensus that CRC in IBD is preceded by the occurrence of intraepithelial neoplasia (formerly termed dysplasia). The detection of intraepithelial neoplasia, indicative of an enhanced risk of CRC, therefore provides the rationale for endoscopic surveillance procedures in IBD patients. Correspondingly, surveillance colonoscopy is unequivocally recommended by many gastroenterology and endoscopic societies for diagnosing intraepithelial neoplasia and cancer in IBD patients [27, 37, 38]. Nevertheless, until now, no randomized controlled studies have shown a reduced risk of CRC development with the use of surveillance colonoscopy in IBD patients. However, there have been cohort studies that have demonstrated improved survival in IBD patients undergoing surveillance colonoscopy [39]. The main aim of surveillance programs in IBD is to detect early dysplastic alterations. Dysplastic alterations of the intestinal mucosa in IBD patients may occur in flat or raised mucosal lesions and are differentiated by the terms DALM (dysplasia-associated lesion or mass) (fig. 4) and ALM (adenoma-like mass) [40–42]. The differentiation between colitis-associated intraepithelial neoplasia and sporadic adenoma is often quite challenging, especially if only biopsy specimen have been obtained [43, 44]. The presence of surrounding inflammation and thus epithelial regeneration further impedes the ability to diagnose the presence of intraepithelial neoplasia [45].

Dysplastic mucosal areas are often difficult to recognize by endoscopy, as these lesions often appear flat or only slightly elevated above the level of the mucosa. The timely detection of dysplasia is of vital importance in IBD, as concurrent CRC is common in these patients. One review presented data showing that high- or low-

grade dysplasia was associated with CRC at immediate colectomy in 13 out of 40 patients [46]. Further studies demonstrated that in approximately 40% of IBD patients with a biopsy-based diagnosis of high-grade intraepithelial neoplasia, the corresponding surgical gut specimen showed invasive adenocarcinoma [47, 48]. In low-grade intraepithelial neoplasia, the prevalence of carcinoma in the surgical specimen has historically been described to be up to 19% [49]. More recent data point out a significantly lower prevalence of carcinoma in previously described low-grade intraepithelial neoplasia [50]. There is currently no reliable method of predicting the outcome of mucosal intraepithelial neoplasia in IBD patients. Furthermore, the histopathological analysis of biopsy samples regarding the diagnosis of intraepithelial neoplasia and its grading is associated with high intraobserver variation [51]. The diagnosis of intraepithelial neoplasia therefore warrants a second opinion by another experienced pathologist to ensure correct diagnosis and subsequent therapeutic approaches.

Study data indicate that in 50–80%, colitis-associated neoplastic lesions are not visible upon endoscopy [46]. It was subsequently reported that at least 33 non-targeted jumbo-forceps biopsies have to be taken to exclude dysplasia in colonic mucosal biopsies with 90% confidence [40]. An international consensus conference agreed in 2005 that a minimum of 32 mucosal biopsies should be taken during each surveillance colonoscopy by obtaining 4-quadrant biopsies every 10 cm.

Separate jars should be used for each quartet, and in addition, areas of mucosal irregularity should be biopsied [52].

To reduce the apparent risk of sampling error in cancer surveillance of IBD patients, new endoscopic imaging techniques were introduced including chromoendoscopy, magnification endoscopy, and confocal laser endomicroscopy [53].

In 2003, Kiesslich et al. [54] conducted the first study of dye-based chromoendoscopy in ulcerative colitis patients. 165 patients with long-standing disease were randomized at a 1:1 ratio to undergo conventional colonoscopy or colonoscopy coupled with chromoendoscopy using 0.1% methylene blue. In the chromoendoscopy group, significantly more intraepithelial neoplasias were detected compared to the conventional colonoscopy group (32 vs. 10; $p = 0.003$). Other studies tested indigo carmine as a topical dye for surveillance colonoscopies in ulcerative colitis patients. In one study, long-standing ulcerative colitis patients received both random and directed biopsies followed by spraying of the entire mucosa with 0.1% indigo carmine and subsequent biopsy of any new found lesions. There was a strong trend towards statistically increased dysplasia detection following dye spraying (7/100 patients vs. 2/100 patients; $p = 0.06$). The targeted biopsy protocol detected dysplasia in significantly more patients than the non-targeted protocol (7/100 patients vs. 0/100 patients; $p = 0.02$). Additionally, the targeted biopsy protocol with pancolonic chromoendoscopy required fewer biopsies than taking multiple non-targeted biopsies (157 vs. 2,904 biopsies) [55].

As dye-based chromoendoscopy is associated with additional costs and is a time-consuming procedure, dye-less chromoendoscopy (also called virtual chromoendoscopy) has been developed,

including narrow band imaging (NBI; Olympus, Tokyo, Japan), Fujinon intelligent color enhancement (FICE; Fujinon, Tokyo, Japan), and i-Scan™ (Pentax, Tokyo, Japan).

NBI is based on optical filters within the light source of the endoscope, which narrow the bandwidth of spectral transmittance. This high-resolution endoscopic technique enhances the fine structure of blood vessels and the mucosal surface. FICE and i-Scan use an endoscopic image from the video processor and reconstruct virtual images in real time resulting in improved contrast when depicting capillary patterns and enhancement of the mucosal surface [53, 56].

NBI can currently not be recommended as an alternative for surveillance colonoscopies in patients with IBD, as it has not demonstrated a benefit in the detection of dysplasia in comparison to chromoendoscopy. In 1 study that compared the performance of NBI with chromoendoscopy, 44 patients with colitis of 8 years or greater disease duration underwent screening colonoscopy with NBI, followed immediately by chromoendoscopy. It could be shown that chromoendoscopy identified more lesions than NBI (131 vs. 102, $p < 0.001$); however, most were non-dysplastic. NBI also detected fewer dysplastic lesions as compared with chromoendoscopy (20 vs. 23, $p = 0.18$) [57].

Confocal laser endomicroscopy was introduced allowing real-time in vivo imaging of the gastrointestinal mucosa at 1,000-fold magnification, thereby providing an optical biopsy [58]. One randomized controlled trial assessed the value of combined chromoendoscopy (0.1% methylene blue) and endomicroscopy for in vivo diagnosis of intraepithelial neoplasia in ulcerative colitis patients [59]. 153 patients with long duration of ulcerative colitis and present clinical remission were randomized at a 1:1 ratio to undergo conventional colonoscopy or chromoendoscopy with endomicroscopy. In the combined group, 4.75-fold more neoplasias were detected compared to conventional colonoscopy alone ($p = 0.005$). Furthermore, 50% less biopsies were required ($p = 0.008$). If only circumscribed lesions would have been biopsied, the total number of biopsy specimens could have been reduced by more than 90%. Overall, endomicroscopy predicted the presence of neoplastic changes with high sensitivity, specificity and accuracy (94.7, 98.3 and 97.8%, respectively).

Macroscopically flat or raised lesions without proper delineation to the surrounding mucosa, especially if they occur in long-standing ulcerative colitis patients, are mostly diagnosed as DALM and carry a high risk of progression to CRC. DALM are moreover frequently associated with synchronous or metachronic neoplasia. Whereas non-adenoma-like DALMs often represent an indication for colectomy, sporadic adenomas which are similar to those observed in non-IBD patients may be removed by standard polypectomy, even if they occur in an area histologically involved with colitis. From a clinical perspective, the endoscopic resectability of a lesion is more important than whether it is thought to be a sporadic adenoma or a DALM. One essential point is that it must be possible to endoscopically remove the entire lesion, be it DALM or ALM.

Several studies have shown that ALMs can be successfully removed using standard polypectomy procedures, with only little risk

of subsequent malignancy on follow-up investigations [60–62]. Vieth et al. [63] showed that the diagnosis of an adenoma based on biopsy material from a patient with ulcerative colitis must be followed by endoscopic resection in order to confirm the diagnosis and to exclude colitis-associated intraepithelial neoplasia. The group could show that 2.3% of patients developed a colitis-associated carcinoma during the follow-up period of 6 years. Importantly, these carcinomas were located in a segment of the colon other than that bearing the primary endoscopically resected adenoma.

In a retrospective study with 525 ulcerative colitis patients, a total of 110 neoplastic areas were detected in 56 patients. 85 (77.3%) of the lesions were macroscopically visible on colonoscopy. 50 (89.3%) patients had macroscopically detectable neoplasia, and 6 (10.7%) had macroscopically invisible lesions. The frequency of cancer in patients who underwent endoscopic resection of a neoplasm did not differ from that for the surveillance population as a whole (irrespective of whether the lesion was thought to be an adenoma or a DALM). Conversely, a high proportion of unresectable lesions harbored cancer [64].

In summary, optimal surveillance strategies for IBD patients should be based on regular surveillance intervals. Colonoscopic surveillance should start after 8 years in patients with pancolitis, and 15 years in patients with colitis involving the left colon. 4 random biopsy specimens every 10 cm from the entire colon should be taken with additional samples of suspicious areas. Chromoendoscopy with targeted biopsies is an alternative and recommendable approach. Surveillance colonoscopies should be performed every 1–2 years. The finding of carcinoma or high-grade dysplasia in random biopsies is an indication for colectomy. If intraepithelial neoplasia is present in random biopsy specimens, especially if multifocal, colectomy should similarly be recommended. A dysplastic mass that cannot be removed endoscopically, or is associated with dysplasia elsewhere in the colon, is an indication for total colectomy. If an adenomatous lesion with intraepithelial neoplasia was resected endoscopically, surveillance colonoscopy should be performed within 6 months.

Management of Complications

In general, endoscopy in IBD patients is more hazardous as compared to the general population. Navaneethan et al. [65] determined the prevalence of colonic perforation during colonoscopy among IBD patients, and assessed its risk factors by obtaining patient data from the Nationwide Inpatient Sample. Colonic perforation occurred in 1% of IBD hospitalizations and in 0.6% of controls without IBD ($p = 0.0001$). The risk of colonic perforation in the IBD group was significantly higher than the control group. Older age, female gender, and therapeutic endoscopic dilation were independent risk factors for perforation while colonoscopic biopsy, polypectomy, and the presence of comorbidities did not increase the risk of perforation. In general, the endoscopic armamentarium used to treat complications in IBD is the same as is used in non-IBD patients [66]. However, the chronic inflammation and fibrosis

of the tissue can sometimes impede endoscopic injection therapies and hemoclip application. Therefore, close collaboration between the gastroenterologist and the surgeon is of paramount importance for optimal patient outcome.

Acute major gastrointestinal bleeding is uncommon in IBD. Most cases are due to Crohn's disease, without a predilection for site of involvement [67]. Injection and sclerotherapy can be employed in Crohn's disease bleeding from a discrete site. One study showed that hemorrhagic forms of Crohn's occur in quiescent disease in two-thirds of cases [68]. An endoscopic approach may be suggested as first-line therapy in the majority of patients, although surgery is required in less than half of the cases during initial hospitalization, and recurrent hemorrhage should be an appropriate indication for surgery [67].

Endoscopic Molecular Imaging

Endoscopic molecular imaging is based on in vivo visualization and characterization of disease-specific perturbations at the cellular and molecular level [69]. This novel approach has been the subject of an increasing number of preclinical and clinical trials, and has recently also been introduced into the field of IBD. It could be demonstrated that molecular imaging in vivo with a fluorescent antibody was able to predict therapeutic response to subsequent biological treatment. As anti-tumor necrosis factor (TNF) antibodies suppress immune responses in Crohn's disease patients by binding to membrane-bound TNF (mTNF)-expressing mucosal cells, in vivo visualization of these cells via fluorescent anti-TNF antibodies was used to predict therapeutic efficacy of these agents. A Good Manufacturing Practice-conform fluorescent anti-TNF

antibody was topically applied to the inflamed mucosa of Crohn's disease patients and displayed using confocal laser endomicroscopy. It could be shown that patients with high amounts of mTNF-positive cells showed significantly higher short-term response rates at week 12 (92%) after the initiation of anti-TNF therapy compared to patients with low amounts of mTNF-positive cells (15%) [70]. These results indicate that molecular imaging with fluorescent antibodies is emerging as a potential approach for identifying responders to therapy and thus enabling a more individualized therapeutic approach. Further studies in this field are warranted. Another possible application of in vivo endoscopic molecular imaging procedures in IBD patients might be the detection of local dysplasia in mucosal inflammation. In this regard, molecular targets have to be defined that are exclusively expressed by dysplastic lesions but not by surrounding inflammation. A fitting probe directed at the target might then be topically applied to the mucosa and visualized by an appropriate endoscopic device. Safety issues and regulatory hurdles must of course be carefully addressed before the respective molecular probes can be used in vivo in human patients.

Acknowledgement

This research was supported by the Emerging Fields Initiative of the Friedrich-Alexander University Erlangen-Nuremberg.

Disclosure Statement

None of the authors have any conflicts of interest related to this article/work to declare.

References

- Podolsky DK: Inflammatory bowel disease. *N Engl J Med* 2002;347:417–429.
- Strober W, Fuss I, Mannon P: The fundamental basis of inflammatory bowel disease. *J Clin Invest* 2007;117:514–521.
- Neurath MF: Cytokines in inflammatory bowel disease. *Nat Rev Immunol* 2014;14:329–342.
- Loftus EV Jr: Clinical epidemiology of inflammatory bowel disease: incidence, prevalence, and environmental influences. *Gastroenterology* 2004;126:1504–1517.
- Baumgart DC, Sandborn WJ: Inflammatory bowel disease: clinical aspects and established and evolving therapies. *Lancet* 2007;369:1641–1657.
- Ott C, Schölmerich J: Extraintestinal manifestations and complications in IBD. *Nat Rev Gastroenterol Hepatol* 2013;10:585–595.
- Bernstein CN, Blanchard JF, Kliever E, Wajda A: Cancer risk in patients with inflammatory bowel disease: a population-based study. *Cancer* 2001;91:854–862.
- Paine E, Shen B: Endoscopic therapy in inflammatory bowel diseases (with videos). *Gastrointest Endosc* 2013;78:819–835.
- Chang CW, Wong JM, Tung CC, Shih IL, Wang HY, Wei SC: Intestinal stricture in Crohn's disease. *Intest Res* 2015;13:19–26.
- Yamamoto T, Fazio VW, Tekkis PP: Safety and efficacy of strictureplasty for Crohn's disease: a systematic review and meta-analysis. *Dis Colon Rectum* 2007;50:1968–1986.
- Hassan C, Zullo A, De Francesco V, Ierardi E, Giustini M, Pitidis A, Taggi F, Winn S, Morini S: Systematic review: endoscopic dilatation in Crohn's disease. *Aliment Pharmacol Ther* 2007;26:1457–1464.
- Hirai F, Beppu T, Takatsu N, Yano Y, Ninomiya K, Ono Y, Hisabe T, Matsui T: Long-term outcome of endoscopic balloon dilation for small bowel strictures in patients with Crohn's disease. *Dig Endosc* 2014;26:545–551.
- Brooker JC, Beckett CG, Saunders BP, Benson MJ: Long-acting steroid injection after endoscopic dilation of anastomotic Crohn's strictures may improve the outcome: a retrospective case series. *Endoscopy* 2003;35:333–337.
- East JE, Brooker JC, Rutter MD, Saunders BP: A pilot study of intrastricture steroid versus placebo injection after balloon dilatation of Crohn's strictures. *Clin Gastroenterol Hepatol* 2007;5:1065–1069.
- Rejchrt S, Kopacova M, Brozik J, Bures J: Biodegradable stents for the treatment of benign stenoses of the small and large intestines. *Endoscopy* 2011;43:911–917.
- Loras C, Pérez-Roldan F, Gornals JB, Barrio J, Igea F, González-Huix F, González-Carro P, Pérez-Miranda M, Espinós JC, Fernández-Bañares F, Esteve M: Endoscopic treatment with self-expanding metal stents for Crohn's disease strictures. *Aliment Pharmacol Ther* 2012;36:833–839.
- Kantsevov SV, Bitner M: Esophageal stent fixation with endoscopic suturing device (with video). *Gastrointest Endosc* 2012;76:1251–1255.
- Mudumbi S, Velazquez-Aviña J, Neumann H, Kyanam Kabir Baig KR, Mönkemüller K: Anchoring of self-expanding metal stents using the over-the-scope clip, and a technique for subsequent removal. *Endoscopy* 2014;46:1106–1109.
- Hellers G, Bergstrand O, Ewerth S, Holmström B: Occurrence and outcome after primary treatment of anal fistulae in Crohn's disease. *Gut* 1980;21:525–527.
- Sandborn WJ, Fazio VW, Feagan BG, Hanauer SB; American Gastroenterological Association Clinical Practice Committee: AGA technical review on perianal Crohn's disease. *Gastroenterology* 2003;125:1508–1530.
- Hackert T, Werner J, Loos M, Büchler MW, Weitz J: Successful doxycycline treatment of lymphatic fistulas: report of five cases and review of the literature. *Langenbecks Arch Surg* 2006;391:435–438.

- 22 Del Rio P, Dell'Abate P, Soliani P, Ziegler S, Arcuri M, Sianesi M: Endoscopic treatment of esophageal and colo-rectal fistulas with fibrin glue. *Acta Biomed* 2005; 76:95–98.
- 23 Loungnarath R, Dietz DW, Mutch MG, Birnbaum EH, Kodner IJ, Fleshman JW: Fibrin glue treatment of complex anal fistulas has low success rate. *Dis Colon Rectum* 2004;47:432–436.
- 24 Rábago LR, Ventosa N, Castro JL, Marco J, Herrera N, Gea F: Endoscopic treatment of postoperative fistulas resistant to conservative management using biological fibrin glue. *Endoscopy* 2002;34:632–638.
- 25 De la Portilla F, Alba F, García-Olmo D, Herrerías JM, González FX, Galindo A: Expanded allogeneic adipose-derived stem cells (eASCs) for the treatment of complex perianal fistula in Crohn's disease: results from a multicenter phase I/IIa clinical trial. *Int J Colorectal Dis* 2013;28:313–323.
- 26 Herrerías MD, García-Arranz M, Guadalajara H, De-La-Quintana P, García-Olmo D; FATT Collaborative Group: Autologous expanded adipose-derived stem cells for the treatment of complex cryptoglandular perianal fistulas: a phase III randomized clinical trial (FATT 1: fistula Advanced Therapy Trial 1) and long-term evaluation. *Dis Colon Rectum* 2012;55:762–772.
- 27 Leighton JA, Shen B, Baron TH, Adler DG, Davila R, Egan JV, Faigel DO, Gan SI, Hirota WK, Lichtenstein D, Qureshi WA, Rajan E, Zuckerman MJ, VanGuilder T, Fanelli RD; Standards of Practice Committee, American Society for Gastrointestinal Endoscopy: ASGE guideline: endoscopy in the diagnosis and treatment of inflammatory bowel disease. *Gastrointest Endosc* 2006;63:558–565.
- 28 Banez AV, Yamanishi F, Crans CA: Endoscopic colonic decompression of toxic megacolon, placement of colonic tube, and steroid colonolysis. *Am J Gastroenterol* 1987;82:692–694.
- 29 Hoashi T, Tsuda S, Yao T, Ichimaru T, Nakahara T, Okamoto T, Futami K, Arima S, Iwashita A: A case of ulcerative colitis with toxic megacolon, successfully treated with colonoscopic decompression (Article in Japanese). *Nihon Shokakibyō Gakkai Zasshi* 1991;88:91–95.
- 30 Canavan C, Abrams KR, Mayberry J: Meta-analysis: colorectal and small bowel cancer risk in patients with Crohn's disease. *Aliment Pharmacol Ther* 2006;23: 1097–1104.
- 31 Eaden JA, Abrams KR, Mayberry JF: The risk of colorectal cancer in ulcerative colitis: a meta-analysis. *Gut* 2001;48:526–535.
- 32 Söderlund S, Brandt L, Lapidus A, Karlén P, Broström O, Löfberg R, Ekblom A, Askling J: Decreasing time-trends of colorectal cancer in a large cohort of patients with inflammatory bowel disease. *Gastroenterology* 2009;136:1561–1567.
- 33 Jess T, Simonsen J, Jørgensen KT, Pedersen BV, Nielsen NM, Frisch M: Decreasing risk of colorectal cancer in patients with inflammatory bowel disease over 30 years. *Gastroenterology* 2012;143:375–381.
- 34 Ananthakrishnan AN, Cagan A, Cai T, Gainer VS, Shaw SY, Churchill S, Karlson EW, Murphy SN, Kohane I, Liao KP: Colonoscopy is associated with a reduced risk for colon cancer and mortality in patients with inflammatory bowel diseases. *Clin Gastroenterol Hepatol* 2015;13:322–329.
- 35 Rutter MD, Saunders BP, Wilkinson KH, Rumbles S, Schofield G, Kamm MA, Williams CB, Price AB, Talbot IC, Forbes A: Thirty-year analysis of a colonoscopic surveillance program for neoplasia in ulcerative colitis. *Gastroenterology* 2006;130:1030–1038.
- 36 Beaugerie L, Srceck M, Seksik P, Bouvier AM, Simon T, Allez M, Brixi H, Gornet JM, Altwegg R, Beau P, Duclos B, Bourreille A, Faivre J, Peyrin-Biroulet L, Fléjou JF, Carrat F; CESAME Study Group: Risk of colorectal high-grade dysplasia and cancer in a prospective observational cohort of patients with inflammatory bowel disease. *Gastroenterology* 2013;145:166–175.
- 37 Farraye FA, Odze RD, Eaden J, Itzkowitz SH, McCabe RP, Dassopoulos T, Lewis JD, Ullman TA, James T 3rd, McLeod R, Burgart LJ, Allen J, Brill JV; AGA Institute Medical Position Panel on Diagnosis and Management of Colorectal Neoplasia in Inflammatory Bowel Disease: AGA medical position statement on the diagnosis and management of colorectal neoplasia in inflammatory bowel disease. *Gastroenterology* 2010;138:738–745.
- 38 Annese V, Daperno M, Rutter MD, Amiot A, Bossuyt P, East J, Ferrante M, Götz M, Katsanos KH, Kießlich R, Ordás I, Repici A, Rosa B, Sebastian S, Kucharzik T, Eliakim R; European Crohn's and Colitis Organisation: European evidence based consensus for endoscopy in inflammatory bowel disease. *J Crohns Colitis* 2013;7:982–1018.
- 39 Velayos FS, Loftus EV Jr, Jess T, Harmsen WS, Bida J, Zinsmeister AR, Tremaine WJ, Sandborn WJ: Predictive and protective factors associated with colorectal cancer in ulcerative colitis: a case-control study. *Gastroenterology* 2006;130:1941–1949.
- 40 Ullman T, Odze R, Farraye FA: Diagnosis and management of dysplasia in patients with ulcerative colitis and Crohn's disease of the colon. *Inflamm Bowel Dis* 2009;15:630–638.
- 41 Lodenkemper C: Diagnostic standards in the pathology of inflammatory bowel disease. *Dig Dis* 2009;27: 576–583.
- 42 Odze RD: Adenomas and adenoma-like DALMs in chronic ulcerative colitis: a clinical, pathological, and molecular review. *Am J Gastroenterol* 1999;94:1746–1750.
- 43 Nagasaki K, Iizuka B, Ishii F, Miyazaki J, Fujimori T: Colonoscopic diagnosis of dysplasia and early cancer in longstanding colitis. *J Gastroenterol* 1995;30:36–39.
- 44 Riddell RH, Goldman H, Ransohoff DF, Appelman HD, Fenoglio CM, Haggitt RC, Ahren C, Correa P, Hamilton SR, Morson BC, et al: Dysplasia in inflammatory bowel disease: standardized classification with provisional clinical applications. *Hum Pathol* 1983;14: 931–968.
- 45 Odze RD: Pathology of dysplasia and cancer in inflammatory bowel disease. *Gastroenterol Clin North Am* 2006;35:533–552.
- 46 Bernstein CN, Shanahan F, Weinstein WM: Are we telling patients the truth about surveillance colonoscopy in ulcerative colitis? *Lancet* 1994;343:71–74.
- 47 Connell WR, Lennard-Jones JE, Williams CB, Talbot IC, Price AB, Wilkinson KH: Factors affecting the outcome of endoscopic surveillance for cancer in ulcerative colitis. *Gastroenterology* 1994;107:934–944.
- 48 Nugent FW, Haggitt RC, Gilpin PA: Cancer surveillance in ulcerative colitis. *Gastroenterology* 1991;100: 1241–1248.
- 49 Desaint B, Legendre C, Florent C: Dysplasia and cancer in ulcerative colitis. *Hepatogastroenterology* 1989; 36:219–226.
- 50 Lim CH, Dixon MF, Vail A, Forman D, Lynch DA, Axon AT: Ten year follow up of ulcerative colitis patients with and without low grade dysplasia. *Gut* 2003; 52:1127–1132.
- 51 Dixon MF, Brown LJ, Gilmour HM, Price AB, Smeeton NC, Talbot IC, Williams GT: Observer variation in the assessment of dysplasia in ulcerative colitis. *Histopathology* 1988;13:385–397.
- 52 Itzkowitz SH, Present DH; Crohn's and Colitis Foundation of America Colon Cancer in IBD Study Group: Consensus conference: colorectal cancer screening and surveillance in inflammatory bowel disease. *Inflamm Bowel Dis* 2005;11:314–321.
- 53 Neumann H, Neurath MF, Mudter J: New endoscopic approaches in IBD. *World J Gastroenterol* 2011;17: 63–68.
- 54 Kiesslich R, Fritsch J, Holtmann M, Koehler HH, Stolte M, Kanzler S, Nafe B, Jung M, Galle PR, Neurath MF: Methylene blue-aided chromoendoscopy for the detection of intraepithelial neoplasia and colon cancer in ulcerative colitis. *Gastroenterology* 2003;124:880–888.
- 55 Rutter MD, Saunders BP, Schofield G, Forbes A, Price AB, Talbot IC: Pancolonic indigo carmine dye spraying for the detection of dysplasia in ulcerative colitis. *Gut* 2004;53:256–260.
- 56 Neumann H, Fry LC, Bellutti M, Malfertheiner P, Mönkemüller K: Double-balloon enteroscopy-assisted virtual chromoendoscopy for small-bowel disorders: a case series. *Endoscopy* 2009;41:468–471.
- 57 Efthymiou M, Allen PB, Taylor AC, Desmond PV, Jayasakera C, De Cruz P, Kamm MA: Chromoendoscopy versus narrow band imaging for colonic surveillance in inflammatory bowel disease. *Inflamm Bowel Dis* 2013;19:2132–2138.
- 58 Neumann H, Kiesslich R, Wallace MB, Neurath MF: Confocal laser endomicroscopy: technical advances and clinical applications. *Gastroenterology* 2010;139: 388–392.
- 59 Kiesslich R, Goetz M, Lammersdorf K, Schneider C, Burg J, Stolte M, Vieth M, Nafe B, Galle PR, Neurath MF: Chromoscopy-guided endomicroscopy increases the diagnostic yield of intraepithelial neoplasia in ulcerative colitis. *Gastroenterology* 2007;132:874–882.
- 60 Engelskjær M, Farraye FA, Odze RD: Polypectomy may be adequate treatment for adenoma-like dysplastic lesions in chronic ulcerative colitis. *Gastroenterology* 1999;117:1288–1294.
- 61 Mönkemüller K, Neumann H, Malfertheiner P, Fry LC: Advanced colon polypectomy. *Clin Gastroenterol Hepatol* 2009;7:641–652.
- 62 Odze RD, Farraye FA, Hecht JL, Hornick JL: Long-term follow-up after polypectomy treatment for adenoma-like dysplastic lesions in ulcerative colitis. *Clin Gastroenterol Hepatol* 2004;2:534–541.
- 63 Vieth M, Behrens H, Stolte M: Sporadic adenoma in ulcerative colitis: endoscopic resection is an adequate treatment. *Gut* 2006;55:1151–1155.
- 64 Rutter MD, Saunders BP, Wilkinson KH, Kamm MA, Williams CB, Forbes A: Most dysplasia in ulcerative colitis is visible at colonoscopy. *Gastrointest Endosc* 2004;60:334–339.
- 65 Navaneethan U, Parasa S, Venkatesh PG, Trikudananthan G, Shen B: Prevalence and risk factors for colonic perforation during colonoscopy in hospitalized inflammatory bowel disease patients. *J Crohns Colitis* 2011;5: 189–195.
- 66 Makkar R, Bo S: Colonoscopic perforation in inflammatory bowel disease. *Gastroenterol Hepatol (N Y)* 2013;9:573–583.
- 67 Belaiche J, Louis E, D'Haens G, Cabooter M, Naegels S, De Vos M, Fontaine F, Schurmans P, Baert F, De Reuck M, Fiasse R, Holvoet J, Schmit A, Van Outryve M: Acute lower gastrointestinal bleeding in Crohn's disease: characteristics of a unique series of 34 patients. *Belgian IBD Research Group. Am J Gastroenterol* 1999;94:2177–2181.
- 68 Pardi DS, Loftus EV Jr, Tremaine WJ, Sandborn WJ, Alexander GL, Balm RK, Gostout CJ: Acute major gastrointestinal hemorrhage in inflammatory bowel disease. *Gastrointest Endosc* 1999;49:153–157.
- 69 Atreya R, Goetz M: Molecular imaging in gastroenterology. *Nat Rev Gastroenterol Hepatol* 2013;10:704–712.
- 70 Atreya R, Neumann H, Neufert C, Waldner MJ, Billmeier U, Zopf Y, Willma M, App C, Münster T, Kessler H, Maas S, Gebhardt B, Heimke-Brinck R, Reuter E, Dörje F, Rau TT, Uter W, Wang TD, Kiesslich R, Vieth M, Hannappel E, Neurath MF: In vivo imaging using fluorescent antibodies to tumor necrosis factor predicts therapeutic response in Crohn's disease. *Nat Med* 2014;20:313–318.