

Comaneci-Assisted Coiling as a Treatment Option for Acutely Ruptured Wide Neck Cerebral Aneurysm: Case Series of 118 Patients

Alexander Sirakov, MD ^{*}
 Krasimir Minkin, MD, PhD [†]
 Marin Penkov, MD ^{*}
 Kristian Ninov, MD [†]
 Vasil Karakostov, MD, PhD [†]
 Stanimir Sirakov, MD, PhD ^{*}

^{*}Radiology Department, UH St Ivan Rilski, Sofia, Bulgaria; [†]Neurosurgery Department, UH St. Ivan Rilski, Sofia, Bulgaria

Correspondence:

Stanimir Sirakov, MD, PhD
 UH St Ivan Rilski,
 Radiology Department,
 Bul. Akad. Ivan Geshov 15,
 Sofia, Bulgaria 1431.
 Email: ssirakov@bsunivvers.com

Received, August 3, 2019.

Accepted, March 19, 2020.

Published Online, May 26, 2020.

© Congress of Neurological Surgeons 2020.

This is an Open Access article distributed under the terms of the Creative Commons Attribution-NonCommercial-NoDerivs licence (<http://creativecommons.org/licenses/by-nc-nd/4.0/>), which permits non-commercial reproduction and distribution of the work, in any medium, provided the original work is not altered or transformed in any way, and that the work is properly cited. For commercial re-use, please contact journals.permissions@oup.com

BACKGROUND: Wide-necked cerebral aneurysms in the setting of acute subarachnoid hemorrhage (SAH) remain difficult to treat with endovascular methods despite recent progress in the neuroendovascular field.

OBJECTIVE: To evaluate the effectiveness and safety of the Comaneci device (Rapid Medical, Israel) in endovascular coil embolization of acutely ruptured, wide-necked sidewall, or bifurcation cerebral aneurysms.

METHODS: We retrospectively reviewed 45 anterior communicating artery, 24 internal carotid artery, 21 middle cerebral artery bifurcation, 15 anterior cerebral artery, and 13 posterior circulation aneurysms, which were treated using Comaneci-assisted coil embolization from August 2017 to January 2019. We evaluated procedural complications, clinical outcomes, and mid-term angiographic follow-up. Immediate and 90 d-clinical outcome and radiological follow-up were obtained in all patients.

RESULTS: Comaneci-assisted coil embolization was performed in 118 acutely ruptured aneurysms. The technique was carried out successfully in all cases. Simultaneous application of 2 separated Comaneci devices was performed in 8/118 cases (6.77%). Periprocedural thromboembolic complications related to the device were seen in 7/118 cases (5.93%) and severe vasospasm of the parent artery after manipulation of the Comaneci device occurred in 5/118 cases (4.2%). The procedural-related morbidity rate was 2.54%, and there was no procedural related mortality. Among the available survivors, angiographic follow-ups were obtained at 3 and 6 mo, and complete aneurysmal obliteration was confirmed in 81/112 (72.3%) and 75/112 (66.9%) cases, respectively. Mid-term follow-up reviewed total recanalization rate of 14.28%.

CONCLUSION: Comaneci-assisted embolization of wide-necked intracranial aneurysms in patients presenting with acute SAH is associated with high procedural safety and adequate occlusion rates. Furthermore, dual antiplatelet therapy can be safely avoided in this patient group.

KEY WORDS: Bifurcation aneurysms, Wide-necked aneurysms, Comaneci device, Endovascular remodeling, Coil embolization

Neurosurgery 87:1148–1156, 2020

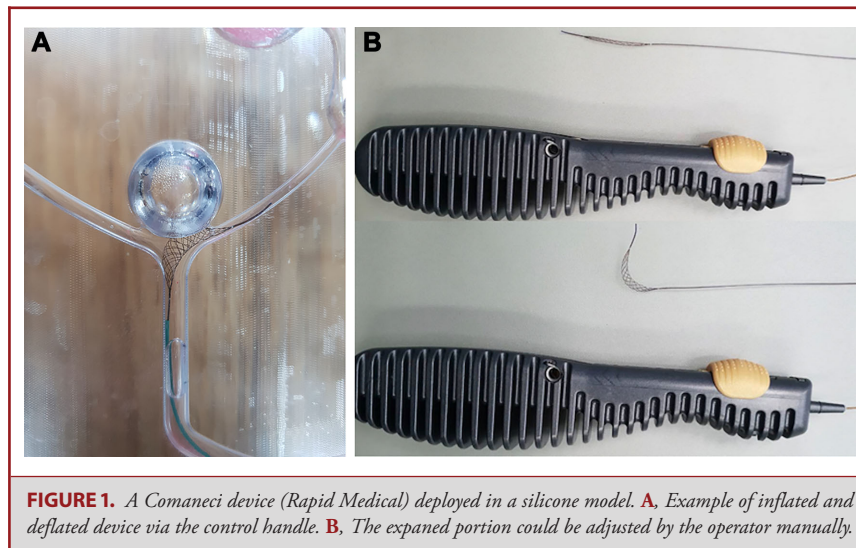
DOI:10.1093/neuros/nyaa200

www.neurosurgery-online.com

Endovascular embolization procedures for the treatment of intracranial aneurysms have been evolving over the past 2 decades.¹ The indications for endovascular treatment of aneurysms have expanded as new advanced techniques, and innovative adjunctive devices are being introduced. Wide-necked

bifurcation aneurysms, however, represent a subset for which simple coiling embolization is often not a feasible treatment option.² The morphology of these aneurysms, especially in cases where the origins of the parent vessels are incorporated in the broad neck of the aneurysm, prohibits the use of standard coiling techniques

ABBREVIATIONS: **ACA**, anterior cerebral artery; **AcomA**, anterior communicating artery; **aSAH**, acute subarachnoid hemorrhage; **BAC**, balloon-assisted coiling; **DAP**, dual antiplatelet therapy; **DSA**, digital subtraction angiography; **ICA**, internal carotid artery; **MCA**, middle cerebral artery; **mRS**, modified Ranking scale; **RR**, Raymond-Roy; **SAC**, stent-assisted coiling; **SAH**, subarachnoid hemorrhage



and may require assistance of some adjunctive devices such as stents and/or balloon microcatheters.^{3,4} The inherent technical challenges associated with endovascular treatment of this subgroup of aneurysms have led to the ongoing development of wide-neck aneurysm-specific neck-bridging devices, balloon microcatheters, and the off-label use of flow diversion.⁵⁻⁸

Permanent placement of a stent in the intracranial vessel requires the use of prolonged double antiplatelet therapy.^{9,10} This still remains controversial in acutely ruptured aneurysms due to the higher percentage of thromboembolic and hemorrhagic complications.¹¹⁻¹³ On the other hand, the presence of double antiplatelet therapy is relatively contraindicated due to the possible need of following operative procedures during hospitalization.¹⁴ Hence, it would be ideal to avoid permanent stent placement when possible.¹⁵

In the present retrospective analysis, we report our results in terms of safety and effectiveness using the Comaneci device (Rapid Medical, Israel) for endovascular embolization of 118 wide-neck acutely ruptured aneurysms.

METHODS

STROBE guidelines were followed for the collection and reporting of data.¹⁶

Ethical Approval

All procedures performed in the studies involving human participants were in accordance with the ethical standards of the institutional and/or national research committee and with the 1964 Helsinki Declaration and its later amendments or comparable ethical standards.

Informed Consent

Informed consent was obtained from all individual participants included in the study.

Characteristics of the Comaneci Devices

The Comaneci device (Rapid Medical) has a compliant radiopaque mesh composed of 12 nitinol wires mounted on a 182-cm-core wire. The distal end of the device consists of a 7-mm flexible tip, allowing for gentle and safe navigation. The cell size of the device measures 1.33 mm² at the nominal diameter of 3.0 mm (Figure 1).¹⁷ There are 3 versions of the device available: Comaneci and Comaneci Petit made compatible and released via a 0.021-inch microcatheter and the Comaneci 17, which is delivered via a 0.017-inch microcatheter. The inflation and deflation of the device's mesh can be adjusted manually by the operator via a slider button at the control handle.

Patient Population and Indications for Treatment

The institutional review board of our hospital approved a retrospective review of the interventional database records. We retrospectively identified all patients treated in the acute phase of subarachnoid hemorrhage (aSAH) with temporary stent-assisted embolization using a Comaneci device from August 2017 to January 2019. All patients with a diagnosis of an aSAH due to ruptured intracranial aneurysm, the decision regarding the indications for treatment, and the most favorable method of treatment were conducted by a multidisciplinary team of experienced interventional neuroradiologist and microvascular neurosurgeon. In each case, multiple factors were considered such as the morphological characteristics of the aneurysm and the parent vessel, as well as the clinical condition of the patient.

The indications for treatment with the Comaneci device were defined as a ruptured saccular aneurysm with a dome-to-neck ration of <2 or a neck diameter of >4 mm or complex bifurcation aneurysms with present parent vessel incorporation at the level of the neck.

All patients or their legal representatives were informed about the procedure according to the local institutional policy. Written informed consent was obtained from every patient. The patients' demographics, clinical status, morphology of aneurysms, and medical history related to intracranial aneurysms were obtained. Evaluation concerned the Comaneci deployment success, technical and clinical complications, and degree of aneurysm occlusion, which were recorded by the Raymond-Roy (RR) occlusion scale.¹⁸

Endovascular Procedure

Every procedure was performed under general anesthesia and using a femoral or distal transradial approach in a dedicated biplane neuroangiography suite. Approximately two-thirds of the lesions were accessed through the right distal radial artery. Intraprocedural anticoagulation was initiated right after the insertion of the introducer sheath with a bolus dose of 50 IU/kg, followed by continuous heparin infusion to maintain an activated clotting time between 250 and 300 s during the procedure. Following a roadmap angiography, the first microcatheter with an internal diameter of 0.0165 inches was advanced over a microwire inside the target aneurysm. Partial deployment of the first coil was made in order to anchor the microcatheter inside the sac. The selected Comaneci device was inserted into a second microcatheter and then navigated to an optimal position. The neck-bridging mesh of the device was deployed across the aneurysmal neck by cautiously retracing the microcatheter while maintaining the wire of the Comaneci fixated. The control grip handle of the device allows the operator to manually “inflate” the device until the desired expansion is achieved. The radiopacity of the braided mesh is high enough to easily distinguish if there is any possible interaction between the inserted coils and the device itself. Under high-resolution fluoroscopic control and right before the detachment of the last finishing coil, the Comaneci device was slowly “deflated.” Once solid and stable coil basket inside the aneurysmal dome was confirmed, the neck-bridging device was carefully inserted back into the microcatheter and safely removed from the target artery. This technique was successfully carried out in all patients.

Antiplatelet and Anticoagulation Regimen

In this series, no dual-antiplatelet medication was assigned to any of the treated patients. Intravenous heparin 50 IU/kg was administered right after the introducing sheath was deployed. The flushing bags for all microcatheters used contained 5000 IU of heparin per liter.

Clinical and Imaging Follow-up Schedule

The neurological assessments at discharge, and 3-mo and the 6-mo control examinations were performed by a neurologist or a certified stroke nurse by means of the modified Ranking scale (mRS). Shifts from 0 to 2 of the modified scale were considered as a good treatment outcome. Digital subtraction angiography (DSA) assessment of the aneurysmal occlusion was performed at the end of each intervention as well as on each control angiography, ie, at 3 and 6 mo after the treatment. The simplified Raymond aneurysmal occlusion scale was used to clarify the aneurysmal status, where recanalization was defined as either neck remnant filling or aneurysmal perfusion noted on each radiological examination. Records were made of all generic and procedural-related complications at a follow-up of 6 mo.

Statistical Analysis

Data collection was performed using IBM SPSS Statistics, Version 22 (Armonk, New York). In descriptive analysis, categorical variables were presented as percentages and absolute numbers, and continuous variables were presented as the mean and range.

RESULTS

Patients and Aneurysm and Clinical Characteristics

A total of 118 patients were treated with Comaneci device (Rapid Medical)-assisted coiling between August 2017 and

January 2019 (Figure 2). The mean age of the patients was 55.4 yr (range 29-79); there were 73 (61.9%) female and 45 (38.1%) male. All patients treated in our series presented with aSAH. A total of 115 (88.9%) patients harbored de novo ruptured aneurysms and 13 (11.1%) patients had experienced SAH after a re-rupture earlier in their life. None of the treated patients had previous endovascular treatment. Details of the patients and aneurysm characteristics are shown in Table 1.

All of the treated aneurysms (118/118 [100%]) were of saccular morphology and distributed among the following locations: 45 aneurysms of the anterior communicating artery, 15 aneurysms of the anterior cerebral artery, 21 aneurysms at the level of the bifurcation of the middle cerebral artery, 24 side wall aneurysms of the internal carotid artery, and 13 posterior circulation aneurysms. The mean aneurysm size was 6.2 ± 4.1 mm (range from 2.6-17.3 mm) with a mean neck size of 4.31 ± 3.1 mm (range 2.1-8.6 mm). Of the 118 patients, 75 (63.5%) were transferred from hospitals, located in other cities. Pretreatment World Federation of Neurosurgical Societies grade 1 was noted in 58/118 patients (49.15%), 35 patients (29.66%) had a score of 2, 16 patients (13.55%) had a score of 3, and 9 patients (7.62%) had a score of 4. All patients with score of 4 were presented with extended SAH Fisher score of IV.

Technical and Angiographic Results

Procedural details are summarized in Table 2. Safe navigation and complete deployment across the aneurysmal neck were successfully performed in all cases (Figure 3). Simultaneous application of 2 separated Comaneci devices was carried out in 8/118 cases (6.77%). Insertion and complete withdrawal of the device were performed in all cases without any events. In 3/118 (2.54%) cases, we noted insufficient neck coverage caused by undersizing of the Comaneci device selected by the main operator due to planning and measurement errors. In one single case, the Comaneci device migrated proximally during expansion and its distal tip “moved forward” to a danger proximity to the aneurysm neck. The stent was afterward successfully withdrawn into the microcatheter and completely redeployed across the aneurysmal neck. In the remaining 114 cases, the Comaneci-assisted coil embolization was performed as planned. The visualization of the device’s radiopaque mesh and its distal tip was evaluated subjectively by the operator. Excellent visualization was observed in the majority of the cases 81/118 (68.6%), “good” visualization in 35/118 cases (29.6%), and “low” in 2 cases (1.69%). No stretching of the parent vessels was observed once the device was deployed. We assume that the braided cell nature of the device allows maximum conformity with the target artery vessel and helps avoiding any possible interaction between the coils and the mesh of the device at the level of the aneurysmal neck. Arterial side branches were covered by the device’s mesh in 28/118 cases (23.7%); all of the branches remained patent at the end of the procedure. The mean time of continuous and complete inflation of the Comaneci device in our series was 390 s (6 min and 30 s), ranging from 180 to 900 s.

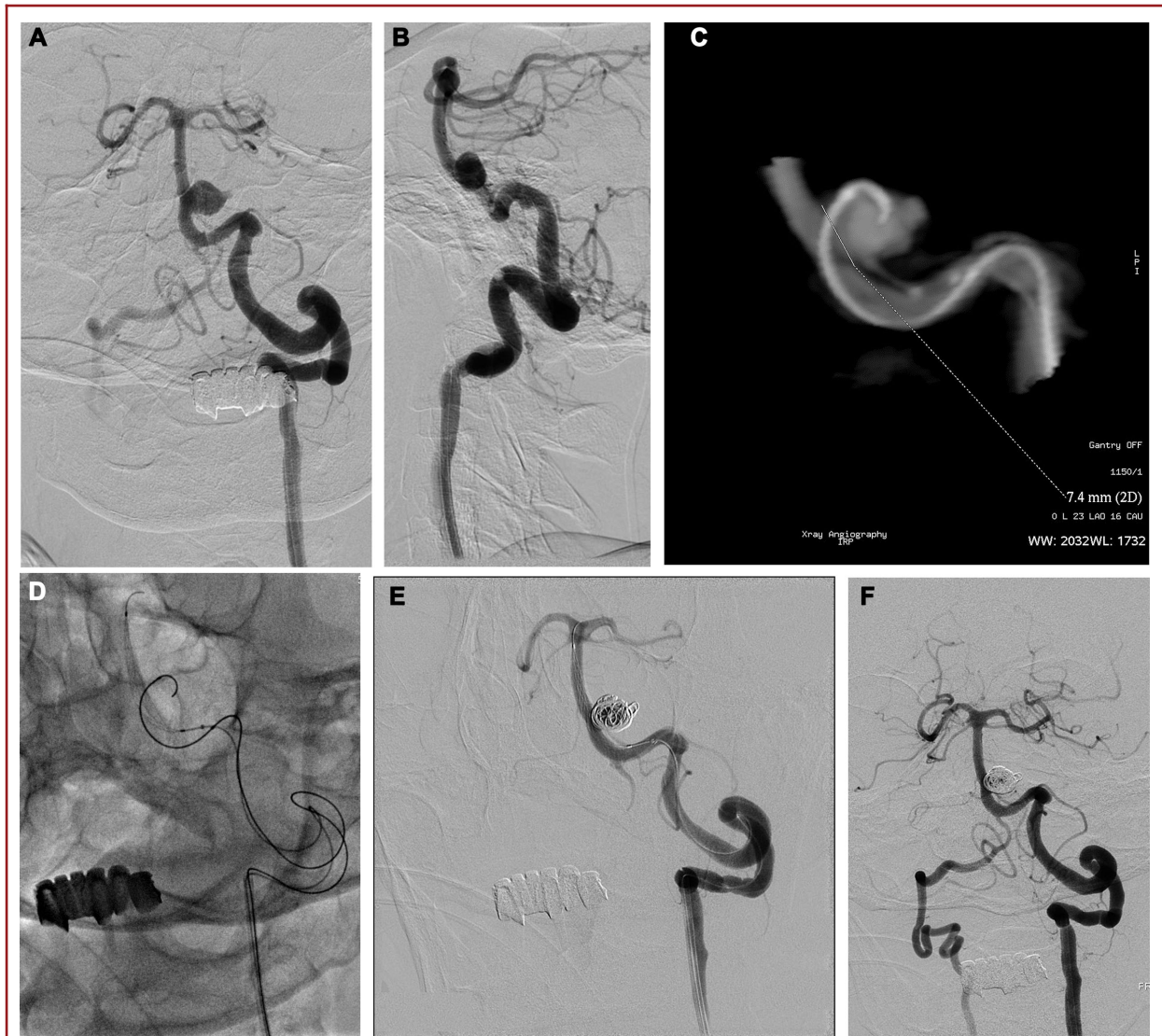

FIGURE 2. An acutely ruptured basilar aneurysm. Diagnostic DSA **A** demonstrating the wide-necked basilar artery (BA) saccular **B** aneurysm. Note the presence of a small lobuli arising from the aneurysmal apex. 3D rotational angiography **C** revealed the width of the aneurysmal neck measured approximately 7.4 mm in diameter. Coil occlusion of a BA aneurysm, assisted by a Comaneci device to achieve temporary neck bridging **D** (note the radiopacity of the device's mesh and the distal tip). The device allowed a dense coil occlusion of the aneurysm including the neck. The Comaneci device was fully deployed for 7 min without compromising of the hemodynamic or any distal embolic complication **E** and **F**.

Complications

All procedure-related complications were documented in our series. Major complications were defined as transient or permanent neurological deficits or death. Functional outcome was evaluated by the mRS. Unfavorable outcome was defined as mRS score >2.

The periprocedural thromboembolic complications related to the device were seen in 7/118 cases (5.93%). In these cases, small thrombus formation across the distal part of the device and emboli in the distal vascular distribution of the parent vessel were noted.

After injection of a total of 10 mg Reopro abciximab), the thrombi dissolved in all cases, and normal flow was observed in the distal territories. However, these events lead to permanent neurological deficit in 3 patients.

Vascular sequelae in terms of severe vasospasm of the parent artery occurred after complete withdrawal of the Comaneci in 5/118 cases (4.2%). According to our experience, this may be due to possible overexpansion of the mesh and flanking of the distal tip of the device. Following superselective infusion of nimodipine, the disturbance in the normal intraluminal blood flow in all

TABLE 1. Baseline Patients and Aneurysmal Characteristics

Characteristics	Value (n = 118)
Age (yr)	55.4 years (range 29-79)
Mean time to assessment (h)	24.5 h
Mean admission GCS	12.7 (range 7-15)
Mean admission Fisher scale	2.4 (range I-IV)
Mean admission WFNS grade	1.4 (range 1-4)
Mean admission H&H grade	1.5 (range 1-4)
Number of patients with EVD placement after treatment	21 (17.79%)
Sex	
Female	73 (61.9%)
Male	45 (38.1%)
Patients transferred from outside hospitals	75/118 (63.5%)
Lesion localization	
Anterior circulation	105 (88.9%)
Internal carotid artery	24 (20.33%)
• Clinoid	4 (3.4%)
• Ophthalmic segment	8 (6.7%)
• Posterior communicating artery	7 (5.9%)
• Terminus	5 (4.2%)
Anterior communicating artery	45 (38.1%)
Anterior cerebral artery	15 (12.7%)
Middle cerebral artery	21 (17.79%)
Posterior circulation	13 (11.01%)
Basilar artery	5 (4.2%)
Posterior cerebral artery	1 (0.8%)
Supracerebellar artery	4 (3.4%)
Posterior inferior cerebellar artery	3 (2.5%)
Aneurysmal morphology	
Saccular	118 (100%)
Fusiform	0
Dissecting	0
Aneurysmal size (mm)	6.2 ± 4.1 (range from 2.6-17.3 mm)
Small (<10 mm)	83 (70.3%)
Large (≥10 and <20 mm)	34 (28.8%)
Giant (≥20 mm)	1 (0.8%)
Neck width (mm)	4.3 ± 3.1 mm (range 2.1-8.6 mm).
Dome-to-neck ratio	1.3 ± 0.5
Proximal parent artery diameter (mm)	2.8 ± .11
Distal parent artery diameter (mm)	3.1 ± 0.6

EVD, external ventricular drain; WFNS, World Federation of Neurosurgical Societies.

patients was resolved. No evidence of vessel perforation was observed in our series. There were no further major ischemic or hemorrhagic events within the first 30 d after treatment. The overall procedural-related morbidity rate during the first clinical follow-up was 2.54% (3/118).

Immediate and Follow-up Radiological/Clinical Results

Immediate and complete aneurysm occlusion on the postembolization angiography was recorded in 83/118 or 70.3% of the patients compared to 32/118 with a neck remnant and 3/118 with aneurysm remnant.

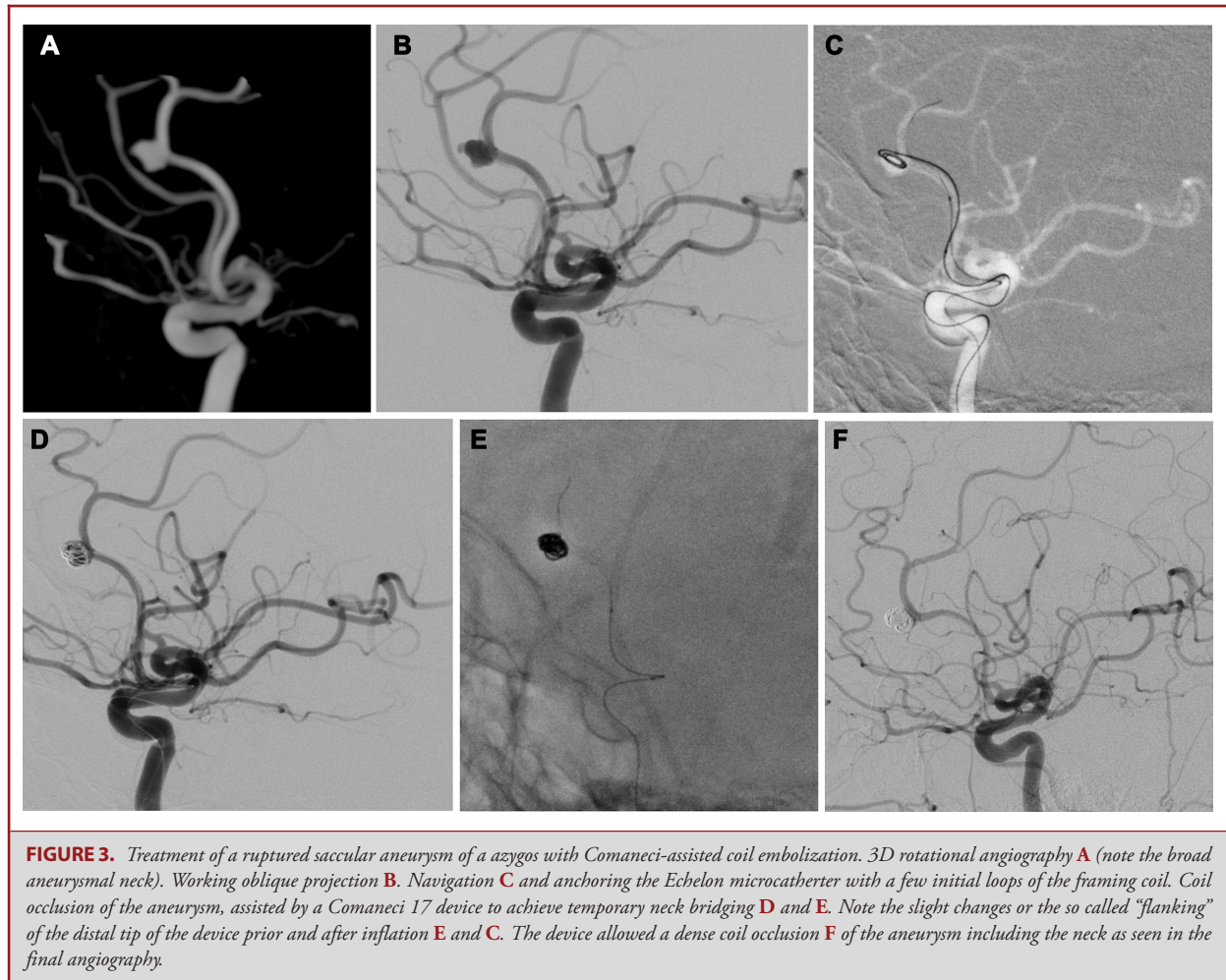
TABLE 2. Summarized Procedural and Technical Details

Characteristics	Value (n = 118)
Double antiplatelet therapy assigned	0 (0%)
Successful deployment and manipulation	118 (100%)
Total number of used Comaneci devices	126
■ Comaneci 17	94 (74.6%)
■ Comaneci petit	11 (8.73%)
■ Comaneci 21	21 (16.6%)
Sufficient neck coverage	115 (97.4%)
Insufficient neck coverage	3 (2.54%)
Covered proximal side branches	28 (23.7%)
Patent proximal side branches at the end	100%
Inflation/deflation maneuvers of the device	504 ± 108
Total inflation time of the device	390 s ranging from 180 to 900
Visibility	
■ Low	2 (1.69%)
■ Good	35 (29.6%)
■ Excellent	81 (68.6%)
Device related complications	11 (8.73%)
■ Thromboembolic	7 (5.93%)
■ Parent vessel rupture	
■ Aneurysmal rupture	
■ Iatrogenic vasospasm	5 (4.2%)
Symptomatic complications	3 (2.54%)
Procedural-related morbidity	3 (2.54%)
Procedural-related mortality	0
Overall rate of good neurological outcome	112 (100%) or 100% of the survivors

The first DSA follow-up was available at a mean of 81.1 d for 112/118 patients. Complete aneurysm occlusion at 3-mo-follow-up was observed in 81/112 patients (72.3%). For the remaining 31/112 patients (27.67%), a stable neck remnant was noted in 18/112 (16.07%)—RR class II. Of the 112 patients, 13 (11.6%) showed signs of aneurysmal recanalization in terms of decrease in the RR classification.

Second DSA follow-up examination at 6-mo was performed at a mean of 165.1 d in 112/118 patients. Complete aneurysmal obliteration was noted in 75/112 patients (66.9%). After comparing the angiographic at 3-mo and 6-mo follow-up examinations, a progressive aneurysmal recanalization was noted in 19/112 patients (16.94%). Stable and unchanged RR class II was documented in 18/112 patients (33.03%), resulting in a total recanalization rate of 14.28%. Following embolization via either a flow redirecting device or an additional coil embolization was scheduled for all 37 patients. Third- and six-month aneurysm occlusion rates are presented in Table 3.

The all-cause mortality rate in our series was 5% (5/118), none of which were intervention related. Clinical 6-mo follow-up data were available for all the survivors. Of the 112 patients, 87 had an mRS score of 0. Among the survivors, 3 of the 118 patients suffered permanent motor aphasia. A summary of the study's agenda is illustrated in Figure 4.



DISCUSSION

Key Results and Interpretation

In this study, we performed retrospective analysis on data from 118 patients with acutely ruptured wide-necked aneurysms who were treated with Comaneci-assisted coiling (Rapid Medical). To our best knowledge, this is the largest series of Comaneci-assisted coiling in acute setting without dual antiplatelet therapy (DAP). Our results show that Comaneci-assisted coiling is a feasible, safe, and effective option for the treatment of ruptured wide-neck aneurysms. Furthermore, we were able to show that this technique is also possible with the smallest version of the device Comaneci'17, which is designed especially for distally located aneurysms. Contrary to the other available series, we did not use any antiplatelet therapy, thus theoretically reducing the risk of any hemorrhagic complications related to intraprocedural rupture of the aneurysm or vessel wall damage. Any subsequent surgical interventions such as external ventricular drain placement

or decompressive craniectomy in our series were favored by the absence of DAP.

Temporary stent-assisted coiling (SAC) technique is a relatively novel method, which has been already described by previously conducted case series but the data regarding this particular device remain insufficient.¹⁹⁻²⁴

The radiological outcome in our report implies that Comaneci-assisted coiling can be performed relatively safe with satisfactory complication rate. We managed to achieve an acceptable immediate occlusion rate RR I in 83/118 or 70.3% of the cases regardless of the dome-to-neck ratio and the localization of the aneurysm. In terms of occlusion rates at follow-up examinations, we believe a complete obliteration rate of 72.3% to be rather satisfying and comparable with those reported in the literature results. The occlusion rates in our series are more comparable with those reported in stent assistance rather and balloon remodeling.²⁵⁻²⁷ Follow-up occlusion rates for stent-assisted coiling of

TABLE 3. Treatment-Related Angiographic Outcomes and Results

Variables	Values (n = 118)
Immediate aneurysm occlusion	
Raymond-Roy scale	
■ Class I	83 (70.3%)
■ Class II	32 (27.1%)
■ Class III	3 (2.54%)
Angiographic outcomes at 3-mo follow-up (mean 81.1 d)	Patients among the survivors n = 112
Raymond-Roy scale	
■ Class I	81 (72.3%)
■ Class II	18 (16.07%)
■ Class III	13 (11.6%)
Angiographic outcomes at 6-mo follow-up (mean of 165.1 d)	
Raymond-Roy scale	
■ Class I	75/112 (66.9%).
■ Class II	18/112 (33.03%)
■ Class III	19/112 (16.94%)
Aneurysm recanalization	
■ Recanalization among anterior circulation	11
■ Recanalization among posterior circulation	5
Total recanalization rate	14.28%
Mean size of reanalyzed vs nonreanalyzed aneurysm	9 ± 2.4 vs 6 ± 1.12
Retreated aneurysms	37 (33.03%)

both ruptured and unruptured wide-necked aneurysms range from 56.5% to 90%.²⁸⁻³⁰

The recurrence rates of 8.9% observed at 3-mo follow-up and 5.3% at 6-mo follow-up result in total recanalization rate of 14.28%. Compared to permanent stent-assisted coiling, recanalization after Comaneci-assisted embolization seems to be non-inferior. Published recanalization rates for SAC range between 5.3% and 23% with recent meta-analyses suggesting overall rates of 13.3% and 16.2%.^{31,32}

The complication rate, possibly related, directly related, or indirectly related to the device, was 10.1% (12/118). The reported results are relatively low considering the changes in coagulation activities and cerebral vasospasm due to the presence of aSAH. There was no procedure-related mortality in our series.

Technical difficulties in terms of insufficient neck coverage and migration of the device occurred in 4/118 cases or 3.3%. Other technical complications such as microcatheter or device entrapment nor damage of the mesh were not observed.

The endovascular management of ruptured wide-necked cerebral aneurysms in the setting of SAH is very challenging. In terms of efficacy, the placement of flow diverter stent or other endoluminal adjunctive devices might lead to higher rates of complete occlusion in the long term.³³⁻³⁵ The use of an intraluminal device in the acute setting is, however, a major concern due to the mandatory use of DAPT. Because of that, the stent placement is generally considered as a backup option in acutely

ruptured cerebral aneurysms as its safety still remains controversial. Due to these limitations, balloon-assisted coiling (BAC) is still the preferred alternative technique in order to avoid the need of DAPT.³⁶ The technique is reported to have higher rate of adequate postoperative occlusion than standard coiling with comparable safety.³⁷ Inflated across the aneurysmal neck the balloons causes complete occlusion of the normal blood flow through the parent vessel during coil embolization and thus may lead to increased frequency of intraprocedural ischemic or thromboembolic complications, especially in association with the pathological changes in coagulation and fibrinolytic status in patients with SAH. Another potential limitation of BAC is the navigability of balloon across the target aneurysm when they are present in a distal or tortuous anatomy. Due to these limitations, we believe that temporary stent assistance for aneurysm coiling could have the advantages of BAC without flow disruption. This is the main reason behind our decision to employ Comaneci-assisted coiling in terms of temporary stent assistance. A potential drawback of temporary SAC would be the lack of protection offered by a balloon in the case of unexpected intraprocedural aneurysmal rupture or vessel perforation contrary.

Limitations

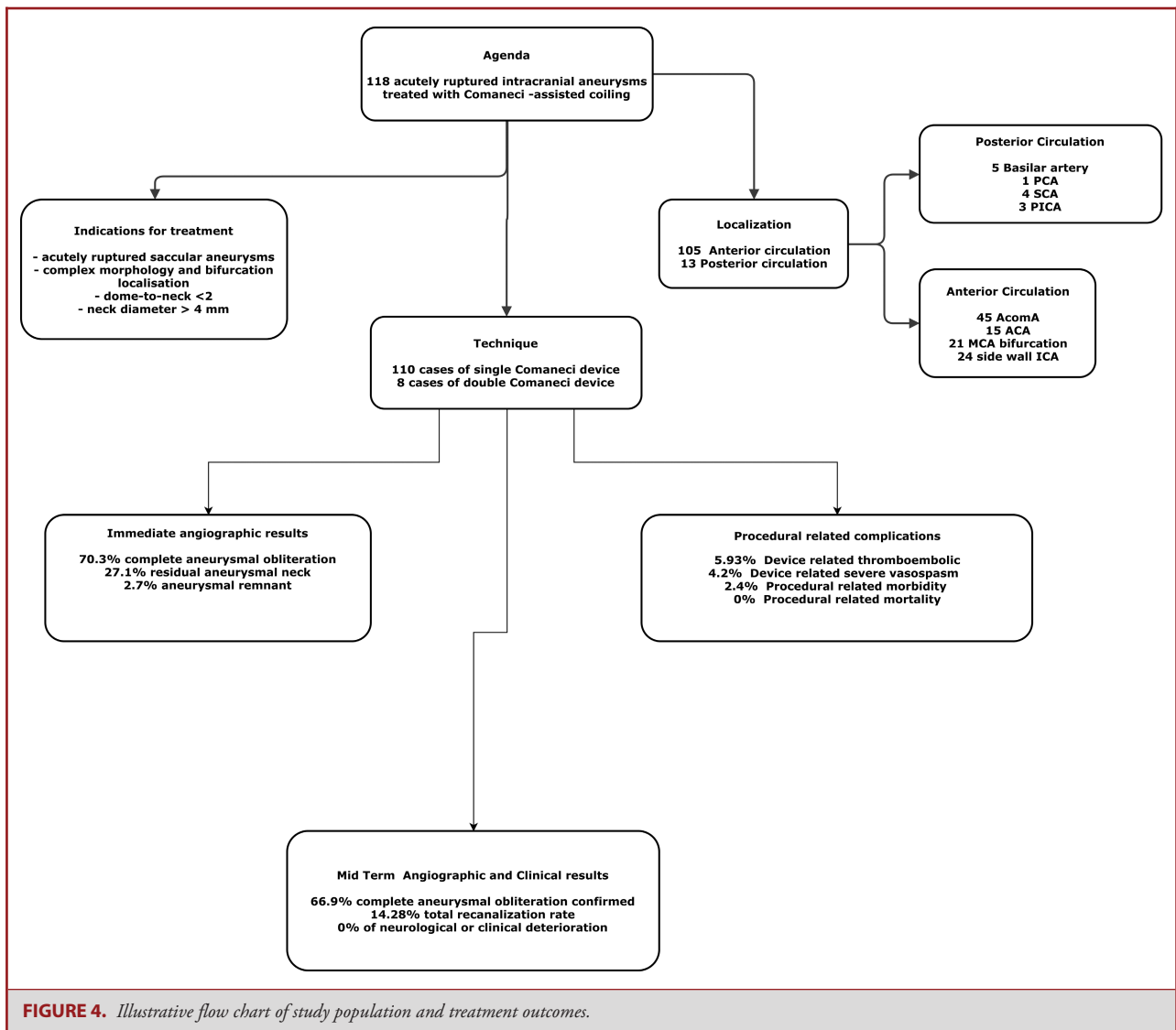
Our study has several limitations, most importantly the retrospective, single-arm and single center design. The might have led to possible selection bias because the patients were not prospectively randomized to different treatment modalities available for ruptured wide-necked aneurysm. The technical results are limited by the authors' individual experience. Furthermore, the relatively short duration of follow-up may have led us to underestimate recanalization rate. As such, our study results should be interpreted with common sense as the results may not be widely applicable to general practice. On the other hand, being the largest series of this technique so far, our results represent the best available evidence regarding the safety and efficacy of this device in the acute setting of SAH.

CONCLUSION

Comaneci-assisted coiling is a feasible and safe way to treat acutely ruptured wide-neck aneurysms with favorable safety profile and acceptable rate of late recurrence, comparable with previously reported data on different treatment modalities available in similar settings. The major advantage of this device is that it could be applied in ruptured case scenario without the need of antiplatelet therapy. However, long-term follow-up data are needed in order to address the safety considerations and significance of this device.

Disclosures

The authors have no personal, financial, or institutional interest in any of the drugs, materials, or devices described in this article.



REFERENCES

- Seibert B, Tummala RP, Chow R, Faridar A, Mousavi SA, Divani AA. Intracranial aneurysms: review of current treatment options and outcomes. *Front Neurol.* 2011;2:45.
- Eskey CJ, Meyers PM, Nguyen TN, et al. Indications for the performance of intracranial endovascular neurointerventional procedures: a scientific statement from the American Heart Association. *Circulation.* 2018;137(21):e661-e689.
- Frösen J. *The Pathobiology of the Saccular Cerebral Artery Aneurysm Rupture and Repair. A Clinicopathological and Experimental Approach* [thesis]. Helsinki, University of Helsinki; 2006.
- Piotin M, Blanc R. Balloons and stents in the endovascular treatment of cerebral aneurysms: vascular anatomy remodeled. *Front Neurol.* 2014;5:41.
- Raymond J, Guilbert F, Roy D. Neck-Bridge device for endovascular treatment of wide-neck bifurcation aneurysms: initial experience. *Radiology.* 2001;221(2):318-326.
- Patel PD, Chalouhi N, Atallah E, et al. Off-label uses of the pipeline embolization device: a review of the literature. *Neurosurg Focus.* 2017;42(6):E4.
- Khattak YJ, Sibaie AA, Anwar M, Sayani R. Stents and stent mimickers in endovascular management of wide-neck intracranial aneurysms. *Cureus.* 2018;10(10):e3420.
- Sharafeldin A, Hasan M, El-Hawwary M, El-Shrif A, El-Shandawily M, Al-Bialy M. Stents technique for endovascular management of intracranial aneurysms. *Egypt J Hosp Med.* 2018;72(4):4283-4291.
- Almekhlafi MA, Goyal M. Antiplatelet therapy prior to temporary stent-assisted coiling. *Am J Neuroradiol.* 2014;35(10):E6-E6.
- Bodily KD, Cloft HJ, Lanzino G, Fiorella DJ, White PM, Kallmes DF. Stent-assisted coiling in acutely ruptured intracranial aneurysms: a qualitative, systematic review of the literature. *Am J Neuroradiol.* 2011;32(7):1232-1236.
- Ebihara T, Kinoshita K, Utagawa A, et al. Changes in coagulative and fibrinolytic activities in patients with intracranial hemorrhage. In: Hoff JT, Keep RF, Xi G, Hua Y, eds. *Brain Edema XIII.* Vol. 96. Vienna: Springer-Verlag; 2006: 69-73.
- Chung J, Lim YC, Suh SH, et al. Stent-assisted coil embolization of ruptured wide-necked aneurysms in the acute period: incidence of and risk factors for periprocedural complications. *J Neurosurg.* 2014;121(1):4-11.

13. Ho MJ, Görlicke SL, Mummel P, Mönninghoff C, Wrede K, Wanke I. Stent-assisted treatment of ruptured intracranial aneurysms in the acute phase: a single center experience. *eNeurologicalSci*. 2018;10:31-36.
14. Mahaney KB, Chalouhi N, Viljoen S, et al. Risk of hemorrhagic complication associated with ventriculoperitoneal shunt placement in aneurysmal subarachnoid hemorrhage patients on dual antiplatelet therapy. *J Neurosurg*. 2013;119(4):937-942.
15. Ryu C-W, Park S, Shin HS, Koh JS. Complications in stent-assisted endovascular therapy of ruptured intracranial aneurysms and relevance to antiplatelet administration: a systematic review. *Am J Neuroradiol*. 2015;36(9):1682-1688.
16. von Elm E, Altman DG, Egger M, et al. The Strengthening of Observational Studies in Epidemiology (STROBE) statement: guidelines for reporting observational studies. *Int J Surg*. 2014;12(12):1495-1499.
17. Gupta R, Kolodgie FD, Virmani R, Eckhouse R, Comaneci neck bridging device for the treatment of cerebral aneurysms. *J Neurointerv Surg*. 2016;8(2):181-185.
18. Roy D, Milor G, Raymond J. Endovascular treatment of unruptured aneurysms. *Stroke*. 2001;32(9):1998-2004.
19. Almekhlafi MA, Hockley A, Wong JH, Goyal M. Temporary solitaire stent neck remodeling in the coiling of ruptured aneurysms. *J Neurointerv Surg*. 2013;5(suppl 3):iii76-iii78.
20. Sanal B, Nas OF, Hacikurt K, Hakyemez B, Erdogan C. Retrievable stent-assisted coiling technique using a solitaire stent: treatment of pancreaticoduodenal artery aneurysm associated with celiac artery occlusion. *Vasc Endovasc Surg*. 2016;50(2):84-87.
21. Zumofen DW, Sahasrabudhe N, Riina HA, et al. Temporary stent scaffolding during aneurysm coiling. *J Clin Neurosci*. 2014;21(5):852-854.
22. Heo HY, Ahn JG, Ji C, Yoon WK. Selective temporary stent-assisted coil embolization for intracranial wide-necked small aneurysms using solitaire AB retrievable stent. *J Korean Neurosurg Soc*. 2019;62(1):27-34.
23. Fischer S, Weber A, Carolus A, Drescher F, Götz F, Weber W. Coiling of wide-necked carotid artery aneurysms assisted by a temporary bridging device (Comaneci): preliminary experience. *J Neurointerv Surg*. 2017;9(11):1039-1097.
24. Lawson ALD, Chandran A, Puthuran M, Goddard T, Nahser H, Patankar T. Initial experience of coiling cerebral aneurysms using the new Comaneci device. *BMJ Case Rep*. 2015;2015:bcr2015011726.
25. Ten Brinck MFM, de Vries J, Bartels RHMA, Grotenhuis JA, Boogaarts HD. NeuroForm atlas stent-assisted coiling: preliminary results. *Neurosurgery*. 2019;84(1):179-189.
26. Cagnazzo F, Cappucci M, Lefevre P-H, et al. Treatment of intracranial aneurysms with self-expandable braided stents: a systematic review and meta-analysis. *Am J Neuroradiol*. 2018;39(11):2064-2069.
27. Cagnazzo F, Limbucci N, Nappini S, et al. Y-Stent-Assisted coiling of wide-neck bifurcation intracranial aneurysms: a meta-analysis. *Am J Neuroradiol*. 2019;40(1):122-128.
28. Feng M, Wen W, Feng Z, Fang Y, Liu J, Huang Q. Endovascular embolization of intracranial aneurysms: to use stent(s) or not? systematic review and meta-analysis. *World Neurosurg*. 2016;93:271-278.
29. King B, Vaziri S, Singla A, Fargen KM, Mocco J. Clinical and angiographic outcomes after stent-assisted coiling of cerebral aneurysms with enterprise and neuroform stents: a comparative analysis of the literature. *J Neurointerv Surg*. 2015;7(12):905-909.
30. Alurkar A, Karanam LS, Nayak S, Oak S. Stent-assisted coiling in ruptured wide-necked aneurysms: a single-center analysis. *Surg Neurol Int*. 2012;3(1):131.
31. Phan K, Huo YR, Jia F, et al. Meta-analysis of stent-assisted coiling versus coiling-only for the treatment of intracranial aneurysms. *J Clin Neurosci*. 2016;31:15-22.
32. Fiorella D, Albuquerque FC, Deshmukh VR, McDougall CG. Usefulness of the neuroform stent for the treatment of cerebral aneurysms: results at initial (3-6-mo) follow-up. *Neurosurgery*. 2005;56(6):1191-1202.
33. Ten Brinck MFM, Jäger M, de Vries J, et al. Flow diversion treatment for acutely ruptured aneurysms. *J Neurointerv Surg*. 2020;12(3):283-288.
34. Goertz L, Dorn F, Kraus B, et al. Safety and efficacy of the derivo embolization device for the treatment of ruptured intracranial aneurysms. *J Neurointerv Surg*. 2019;11(3):290-295.
35. AlMatter M, Aguilar Pérez M, Hellstern V, et al. Flow diversion for treatment of acutely ruptured intracranial aneurysms: a single center experience from 45 consecutive cases. *Clin Neuroradiol*. published online: November 4, 2019. (doi:10.1007/s00062-019-00846-5).
36. Gill BJA, Ellis JA, Meyers PM. Balloon- and stent-assisted endovascular occlusion of intracranial aneurysms. In: Gandhi CD, Prestigiacomo CJ, eds. *Cerebrovascular and Endovascular Neurosurgery*. Cham: Springer International Publishing; 2018:293-305.
37. Wang F, Chen X, Wang Y, et al. Stent-assisted coiling and balloon-assisted coiling in the management of intracranial aneurysms: a systematic review & meta-analysis. *J Neurol Sci*. 2016;364:160-166.