

A Case of a Pregnant Woman With Primary Aldosteronism and Superimposed Preeclampsia Treated With Esaxerenone

Kaoru Yamashita,¹ Satoshi Morimoto,¹  Yuko Inoue,¹ Kiyotaka Hirata,¹ Shihori Kimura,¹ Yasufumi Seki,¹  Kanako Bokuda,¹ Daisuke Watanabe,¹ and Atsuhiko Ichihara¹

¹Department of Endocrinology and Hypertension, Tokyo Women's Medical University, 8-1 Kawada-cho, Shinjuku-ku, Tokyo 162-8666, Japan

Correspondence: Satoshi Morimoto, MD, PhD, Department of Endocrinology and Hypertension, Tokyo Women's Medical University, 8-1 Kawada-cho, Shinjuku-ku Tokyo 162-8666, Japan. Email: morimoto.satoshi@twmu.ac.jp.

Abstract

During pregnancy, there is no established treatment for idiopathic hyperaldosteronism (IHA), the most common form of primary aldosteronism due to bilateral adrenal hyperplasia. Here, we report the case of a pregnant patient with IHA who was successfully treated with esaxerenone, a nonsteroidal mineralocorticoid receptor (MR) antagonist. A 39-year-old woman was diagnosed with IHA and commenced on nifedipine 20 mg daily because she desired to be pregnant. After 1 year, she became pregnant. Her blood pressure was well controlled until 34 weeks of gestation when her home blood pressure became elevated up to 140/90 mmHg. Although the dose of nifedipine was increased to 80 mg daily, her blood pressure increased to 151/97 mmHg, and urinary test showed proteinuria of 2+ in 35 weeks of gestation. She was diagnosed with superimposed preeclampsia (SPE) and additionally treated with esaxerenone. Her blood pressure decreased to 120-140/98-100 mmHg and the proteinuria improved to \pm . A successful cesarean section at 37 weeks resulted in the delivery of a healthy baby boy. Her blood pressure was well controlled although esaxerenone was discontinued 2 weeks after the delivery. This is the first case of a pregnant woman who was safely treated with esaxerenone despite being a female at advanced maternal age who had been diagnosed with IHA and developed SPE. Further studies are needed to investigate the efficacy and safety of nonsteroidal selective MR antagonist in similar pregnant patients with IHA to establish better treatment strategy for these patients.

Key Words: primary aldosteronism, mineralocorticoid receptor antagonist, superimposed preeclampsia

Hypertensive disorders of pregnancy (HDP), the main causes of maternal and fetal morbidity and mortality, affect about 10% of pregnancies in the United States [1]. Superimposed preeclampsia (SPE) [2, 3], a risk factor for adverse maternal and perinatal outcomes (including preterm delivery, small-for-gestational age neonates, neonatal intensive care unit admissions, and pulmonary edema) develops in 20% to 50% of chronic hypertension (CH) pregnancies [4, 5].

Primary aldosteronism (PA) is one of the most frequent causes of secondary hypertension. The excess aldosterone not only causes hypertension but also arteriosclerosis, kidney injury, cardiac fibrosis, and cardiovascular diseases [6-9]. In addition, the prevalence of PA among 18- to 40-year-old women is as high as 7.4% [10]. Despite the high prevalence of PA among these women in the reproductive age group, there is no established treatment for pregnant patients with PA. Here, we describe the first case of a pregnant woman who was safely and effectively treated with esaxerenone, a nonsteroidal mineralocorticoid receptor (MR) antagonist, despite being an elderly pregnant woman who had been diagnosed with idiopathic hyperaldosteronism (IHA) and had developed SPE.

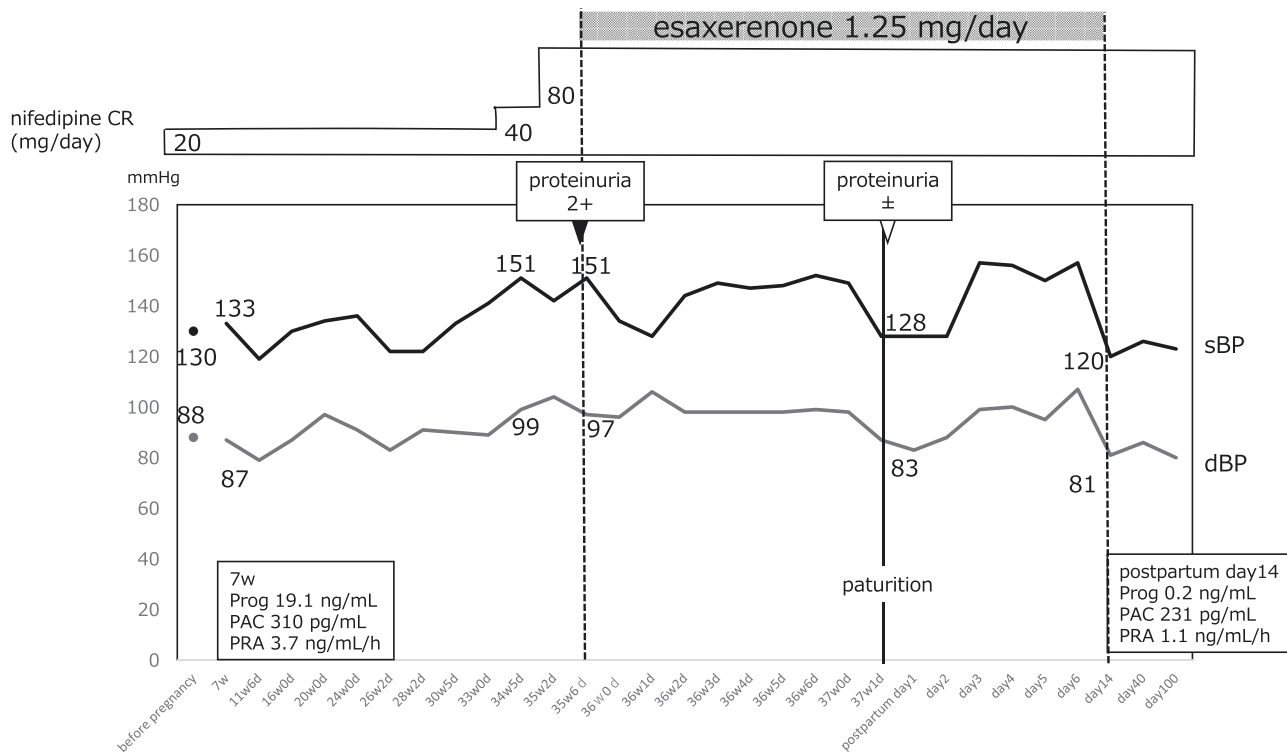
Case Presentation

A 39-year-old woman was referred to our outpatient clinic for hypertension with high plasma aldosterone concentration.

Her plasma aldosterone concentration was 204 pg/mL (radioimmunoassay) and plasma renin activity was 1.2 ng/mL/h at the time of referral. She was diagnosed with PA since the saline-loading test for PA was positive [2]. She had no hypokalemia and computed tomography scans showed no adrenal tumors. Adrenal vein sampling indicated overproduction of aldosterone in both adrenal glands leading to the diagnosis of IHA (Table 1). Due to her desire to be pregnant, we commenced her on nifedipine controlled release (CR) 20 mg daily, in expectation of the drug's strong and long-lasting antihypertensive effects; thus, her blood pressure became well controlled (Fig. 1). After 1 year, she conceived. She was maintained on nifedipine for her antihypertensive treatment after obtaining informed consent, because nifedipine is not allowed for pregnant women before 20 weeks of gestation in Japan. Her blood pressure was well controlled until 34 weeks of gestation, when her home blood pressure became elevated up to 140/90 mmHg. Despite an increased dose of nifedipine CR to 80 mg daily, the maximum dose permitted in Japan, her blood pressure remained elevated up to 151/97 mmHg, and urinary test showed proteinuria of 2+ in 35 weeks of gestation. She was then diagnosed with SPE and additionally treated with 1.25 mg of esaxerenone daily (after obtaining informed consent because this drug had no data of safety on pregnant woman) and admitted to our hospital. Her blood pressure decreased to 120-140/98-100 mmHg, and her proteinuria

Table 1. Adrenal vein sampling

Measurement	Left adrenal	Right adrenal	Inferior vena cava
Aldosterone, pg/mL	37 900	49 500	242
Cortisol, mcg/dL	656	609	10.8
Cortisol-corrected aldosterone	57.8	81.3	22.4
Selectivity index	56.4	60.7	—
Lateralization index	1.4	0.7	—

**Figure 1.** Clinical course of the patient. Abbreviations: CR, controlled release; dBp, diastolic blood pressure; PAC, plasma aldosterone concentration; PRA, plasma renin activity; Prog, progesterone; sBP, systolic blood pressure.

improved to \pm . A successful cesarean section at 37 weeks resulted in the delivery of a healthy baby boy. Esaxerenone was discontinued 2 weeks after delivery, because she was eager to breastfeed the baby and no safety data of esaxerenone in breastfeeding woman was available. Her blood pressure has been well controlled by nifedipine CR 80 mg daily even after 100 days of postpartum.

Discussion

Here we report the first case of a pregnant woman who was treated with esaxerenone. By using esaxerenone, the SPE condition was improved and she successfully delivered a healthy boy at full term without any complications.

HDP increases the risk of both maternal and neonatal morbidity and mortality, and 20% to 50% of pregnant women with CH develop SPE, which has higher risk for preterm delivery, small-for-gestational age neonates, neonatal intensive care unit admissions, and pulmonary edema than HDP [2-5]. Most guidelines defy HDP as blood pressure $\geq 140/90$ mmHg, but treatment thresholds and treatment targets are various [11]; the American College of Obstetricians and Gynecologists ad-

vocates the treatment target for HDP with CH to be $\geq 160/105$ mmHg, treatment target 120-159/80-109 mmHg [12], National Institute for Health and Care Excellence advocates treatment target for SPE $\leq 135/85$ mmHg [13]. Our patient had already started taking nifedipine CR before pregnancy, and the dose was increased to the maximum due to the increased blood pressure during pregnancy. After she developed SPE, esaxerenone treatment was started, and her blood pressure elevation was improved. In pregnancy, the renin-angiotensin-aldosterone system is dynamically activated. Oversecretion of estrogen elevates the plasma renin activity 4-fold at 8 weeks of gestation and up to 7-fold at delivery, to increase aldosterone secretion, compared to that in the nonpregnant state [14]. By activating renin-angiotensin-aldosterone system, sodium retention and circulating plasma volume are increased. However, blood pressure is lowered by vasodilatory effects of increased progesterone, which is secreted from the corpus luteum until 10 weeks of gestation and, afterwards, from the placenta. This competitively inhibits aldosterone [15] and decreases angiotensin type 1 receptor sensitivity [16].

The prevalence of PA is reported to be as high as 7.4% in women aged 18 to 40 years [10]. In pregnant patients

with PA, blood pressure is increased due to several mechanisms. Luteinizing hormone receptor and gonadotropin-releasing hormone receptor are abnormally expressed in some aldosterone-producing adenomas (APA) and are activated by human chronic gonadotropin, which is overproduced to increase aldosterone production during pregnancy. In addition, progesterone secretion, which counteracts aldosterone, decreases 1 to 3 weeks prior to parturition [17]. It may be possible that this is applied to our patient, because her blood pressure surged 35 weeks of gestation. Despite the high probability of blood pressure elevation in pregnant patients with PA, there is no gold standard treatment for pregnant patients with PA. Adrenalectomy for APA is recommended before conception while antihypertensive drugs, α -methyl dopa and β -blockers that have good safety profiles, are recommended during pregnancy [18]. In Japan, although nifedipine is contraindicated in pregnant women before 20 weeks of gestation (Japanese interview form of nifedipine CR tablets), in addition to hydralazine and labetalol, nifedipine is recommended during pregnancy, according to the PA management guideline [19]. In addition, nifedipine is not contraindicated and is rather referred to as one of the recommended antihypertensive drugs for treating HDP in guidelines from the United States and United Kingdom, as well as other countries [11, 20, 21]. Therefore, we continued nifedipine CR administration after obtaining informed consent. Despite the administration of the maximum dose of nifedipine, her blood pressure remained elevated, and she was diagnosed with SPE. Because she had PA, MR antagonists were expected to be more effective than other antihypertensive agents such as α -methyl dopa, hydralazine, and β -blockers in lowering her blood pressure because the mechanism of her blood pressure surge in the third trimester was considered to be, at least in part, due to increase of aldosterone secretion.

The renin-angiotensin system is essential for fetal development. Angiotensinogen knockout mice show frequent neonatal death with renal abnormality [22, 23]. In humans, angiotensin II type 1 receptor blockers and angiotensin-converting enzyme inhibitors are known for their fetal toxicities [24, 25]; therefore, these are contraindicated in pregnant women [26]. A case report of an infant boy who developed ambiguous genitalia was reported. The mother had been treated with spironolactone, a steroidal MR antagonist with an antagonistic and agonistic action on the androgen and progesterone receptor, respectively, until 5 weeks of gestation [27]. This finding was probably due to the antagonist effect on the androgen receptor of the fetus. Another case report described an uneventful pregnancy and delivery under treatment with eplerenone, a steroidal but more specific MR antagonist, after 27 weeks of gestation in a woman with APA [28]. Normal prenatal development has been shown in MR knockout mice [29]. Therefore, there are no definite data indicating that the MR antagonistic action itself has fetal toxicity. Esaxerenone is a novel, nonsteroidal, and highly selective MR antagonist without antagonistic actions on glucocorticoid receptors, androgen receptors, or progesterone receptors [30]. It has higher MR-binding affinity than spironolactone or eplerenone [31]. There have been no reports of the use of this agent in pregnant women. However, no teratology was reported in pregnant rats and rabbits treated with this agent [32]. For these reasons, we administered esaxerenone to our pregnant patient with PA, who developed SPE after 35 weeks of

gestation, when the fetal organs were already fully developed. Thus, her blood pressure was lowered and proteinuria was improved, and she was delivered of a healthy boy.

Conclusion

This is the first case of a pregnant woman who was treated with esaxerenone. By using esaxerenone, the SPE condition was improved, and she was delivered of a healthy boy at full term without any complications. This case provided extremely important information that esaxerenone is effective in lowering blood pressure in a pregnant patient with PA and may be safely used in pregnant women, at least at the late stage of pregnancy. Further studies are needed to investigate the efficacy and safety of nonsteroidal selective MR antagonist in similar pregnant patients with PA to establish better treatment strategy for these patients.

Acknowledgments

We would like to thank the ward staff and doctors who provided quality care for the patient enrolled in this study. We thank Editage (www.editage.com) for English language editing.

Conflict of Interest

S.Morimoto and A. Ichihara received lecture fees from Daiichi Sankyo Co., Ltd.

Data Availability

Data sharing is not applicable to this article because no datasets were generated or analyzed during the current study.

References

1. Creanga AA, Syverson C, Seed K, Callaghan WM. Pregnancy-related mortality in the United States, 2011-2013. *Obstet Gynecol.* 2017;130(2):366-373. doi:10.1097/AOG.0000000000002114
2. Wilkerson RG, Ogunbode AC. Hypertensive disorders of pregnancy. *Emerg Med Clin North Am.* 2019;37(2):301-316. doi:10.1016/j.emc.2019.01.008
3. Sibai B, Lindheimer M, Hauth J, et al. Risk factors for preeclampsia, abruptio placentae, and adverse neonatal outcomes among women with chronic hypertension. *N Engl J Med.* 2022;339(10):667-671.
4. Rezk M, Gamal A, Emara M. Maternal and fetal outcome in de novo preeclampsia in comparison to superimposed preeclampsia: a two-year observational study. *Hypertens Pregnancy.* 2015;34(2):137-144. doi:10.3109/10641955.2014.982329
5. Valent AM, Defranco EA, Allison A, et al. Expectant management of mild preeclampsia versus superimposed preeclampsia up to 37 weeks. *Am J Obstet Gynecol.* 2015;212(4):515.e1. doi: 10.1016/j.ajog.2014.10.1090
6. Weber KT, Brilla CG. Pathological hypertrophy and cardiac interstitium: fibrosis and renin-angiotensin-aldosterone system. *Circulation.* 1991;83(6):1849-1865. doi:10.1161/01.cir.83.6.1849
7. Nishiyama A, Yao L, Nagai Y, et al. Possible contributions of reactive oxygen species and mitogen-activated protein kinase to renal injury in aldosterone/salt-induced hypertensive rats. *Hypertension* 2004;43(4):841-848. doi:10.1161/01.HYP.0000118519.66430.22
8. Kishimoto S, Matsumoto T, Oki K, et al. Microvascular endothelial function is impaired in patients with idiopathic hyperaldosteronism. *Hypertens Res.* 2018;41(11):932-938. doi:10.1038/s41440-018-0093-6

9. Savard S, Amar L, Plouin PF, Steichen O. Cardiovascular complications associated with primary aldosteronism: a controlled cross-sectional study. *Hypertension*. 2013;62(2):331-336. doi:10.1161/HYPERTENSIONAHA.113.01060
10. Camelli S, Bobrie G, Postel-Vinay N, Azizi M, Plouin P, Amar L. LB01.11: prevalence of secondary hypertension in young hypertensive adults. *J Hypertens*. 2015;33:e47. doi:10.1097/01.hjh.0000467473.21331.70
11. Garovic VD, Dechend R, Easterling T, et al. Hypertension in pregnancy: diagnosis, blood pressure goals, and pharmacotherapy: a scientific statement from the American Heart Association. *Hypertension*. 2022;79(2):E21-E41.
12. Roberts JM, August PA, Bakris G, Barton JR, Bernstein IM, Druzin ML, Gaiser RR, Granger JP, Jeyabalan A, Johnson DD, et al. Hypertension in pregnancy: report of the American college of obstetricians and gynecologists' task force on hypertension in pregnancy. *Obstet Gynecol*. 2013;122:1122-1131. doi:10.1097/01.AOG.0000437382.03963.88
13. National Institute for Health and Care Excellence. Hypertension in pregnancy: diagnosis and management: NICE guideline [NG133]. Accessed June 10, 2022. <https://www.nice.org.uk/guidance/ng133/chapter/Recommendations#management-of-chronic-hypertension-in-pregnancy>
14. Morton A. Primary aldosteronism and pregnancy. *Pregnancy Hypertens*. 2015;5(4):259-262.
15. Ledoux F, Genest J, Nowaczynski W, Kuchel O, Lebel M. Plasma progesterone and aldosterone in pregnancy. *Can Med Assoc J*. 1975;112(8):943-947.
16. Gant NF, Daley GL, Chand S, Whalley PJ, MacDonald PC. A study of angiotensin II pressor response throughout primigravid pregnancy. *J Clin Invest*. 1973;52(11):2682-2689.
17. Connor ML, Sanford LM, Howland BE. Saliva progesterone throughout the menstrual cycle and late pregnancy. *Can J Physiol Pharmacol*. 1982;60(3):410-413.
18. Riestler A, Reincke M. Mineralocorticoid receptor antagonists and management of primary aldosteronism in pregnancy. *Eur J Endocrinol*. 2015;172(1):R23-R30.
19. Naruse M, Katabami T, Shibata H, et al. Japan Endocrine Society Clinical practice guideline for the diagnosis and management of primary aldosteronism 2021. *Endocr J*. 2022;69(4):327-359. doi:10.1507/endocrj.EJ21-0508
20. National Institute for Health and Care Excellence. Hypertension in pregnancy: diagnosis and management. *Am J Obs Gynecol*. 2010;77(1):S1-S22.
21. Queensland Health. Queensland clinical guidelines: maternity and neonatal clinical guideline. 2017. Accessed June 10, 2022. https://www.health.qld.gov.au/__data/assets/pdf_file/0034/139948/g-hdp.pdf
22. Tanimoto K, Sugiyama F, Goto Y, et al. Angiotensinogen-deficient mice with hypotension. *J Biol Chem*. 1994;269(50):31334-31337.
23. Kim HS, Krege JH, Kluckman KD, et al. Genetic control of blood pressure and the angiotensinogen locus. *Proc Natl Acad Sci U S A*. 1995;92(7):2735-2739.
24. Barr MJ, Cohen MMJ. ACE inhibitor fetopathy and hypocalvaria: the kidney-skull connection. *Teratology*. 1991;44(5):485-495.
25. Serreau R, Luton D, Macher MA, Delezoide AL, Garel C, Jacqz-Aigrain E. Developmental toxicity of the angiotensin II type 1 receptor antagonists during human pregnancy: a report of 10 cases. *BJOG An Int J Obstet Gynaecol*. 2005;112(6):710-712.
26. Lovegrove E, Robson J, McGettigan P. Pregnancy protection and pregnancies in women prescribed ACE inhibitors or ARBs: a cross-sectional study in primary care. *Br J Gen Pract*. 2020;70(700):E778-E784.
27. Nohira T, Nakada T, Akutagawa O, et al. Pregnancy complicated with Bartter's syndrome: a case report. *J Obstet Gynaecol Res*. 2001;27(5):267-274.
28. Cabassi A, Rocco R, Berretta R, Regolisti G, Bacchi-Modena A. Eplerenone use in primary aldosteronism during pregnancy. *Hypertension*. 2012;59(2):e18-e19.
29. Berger S, Bleich M, Schmid W, et al. Mineralocorticoid receptor knockout mice: Pathophysiology of Na⁺ metabolism. *Proc Natl Acad Sci U S A*. 1998;95(16):9424-9429.
30. Duggan S. Esaxerenone: First global approval. *Drugs*. 2019;79(4):477-481.
31. Takahashi M, Ubukata O, Homma T, et al. Crystal structure of the mineralocorticoid receptor ligand-binding domain in complex with a potent and selective nonsteroidal blocker, esaxerenone (CS-3150). *FEBS Lett*. 2020;594(10):1615-1623.
32. Pharmaceuticals and Medical Devices Agency. [Esaxerenone]. Accessed November 19, 2021. <https://www.pmda.go.jp/PmdaSearch/iyakuDetail/GeneralList/2149049>