

Closed Rupture of Anterior Tibialis Tendon after Minor Injury without Medical History: A Surgical Repair

Aristeidis Vrettakos¹, Themistoklis Vampertzis¹, Theofanis Vavilis², Nikolaos Chaftikis³, Georgios Antonoglou¹, Stergios Papastergiou¹

Learning Point of the Article:

Anterior tibialis tendon rupture should always be included in the differential diagnosis of diminished foot dorsiflexion.

Abstract

Introduction: Closed rupture of the anterior tibial tendon is uncommon, with only a few cases being documented in literature. It usually happens in the forceful plantar flexion of the foot while in eversion and the simultaneous contraction of the anterior tibialis muscle.

Care Report: We present the case of a 65-year-old man with closed rupture of the tibialis anterior tendon after injury who was treated by primary surgical repair. The surgical technique as well as the rehabilitation protocol are described in detail.

Conclusion: Primary surgical reconstruction repair is indicated in younger, active individuals. It appears that early diagnosis and treatment provides the best clinical results, while delayed treatment usually requires the use of a tendon graft in combination with tendon transfers, giving inferior results compared to primary tendon repair.

Keywords: Anterior tibialis tendon, closed rupture, surgical treatment.

Introduction

Closed rupture of the tibialis anterior tendon is a rare clinical entity that usually appears in men between the 5th and 7th decades of life [1, 2]. Usually, the signs are not being assessed properly both by the patient and the physician [3].

The rupture is usually caused by a forced plantar flexion of the foot while being in eversion and simultaneous contraction of the anterior tibialis muscle [4]. In most cases, local degenerative tendinosis exists, either due to systemic diseases or local corticosteroid injections [5]. Secondary rupture of the tendon can occur in patients with rheumatoid arthritis and psoriatic tenosynovitis [6] and in patients suffering from gout, due to monosodium urate crystal deposition in tendons. In several cases, tendinopathy may be observed in patients with recent history of quinolone use commonly for urinary tract infections.

In all the cases mentioned above, the tendon may be ruptured, even after low-stress injury [7].

Case Report

A 65-year-old male patient presented at the outpatient clinic 4 days after a closed right foot injury. The injury was due to loss of step during a curb descent. The result of the injury was the immediate onset of pain in the mid foot and the ankle joint, with accompanying swelling and difficulty in walking. The patient had free medical history apart from a 2-week treatment with ciprofloxacin for chronic inflammation of the prostate 3 months before the injury. During clinical examination, the patient walked with the right drop foot. Furthermore, severe swelling and bruising under the medial malleolus were present. Dorsiflexion of the foot without resistance was possible to some

Access this article online

Website:
www.jocr.co.in

DOI:
10.13107/jocr.2019.v09.i04.1484

¹Department of Orthopaedic Surgery and Traumatology, Unit for Sports Medicine, Agios Pavlos General Hospital of Thessaloniki, Greece,

²Laboratory of Medical Biology-Genetics, Medical School, Aristotle University of Thessaloniki, Greece,

³Department of Orthopaedic Surgery and Traumatology, St. Luke's Hospital, Panorama, 55236, Thessaloniki, Greece.

Address of Correspondence:

Dr. Themistoklis Vampertzis,

Department of Orthopaedic – Unit for Sports Medicine, Agios Pavlos General Hospital of Thessaloniki, Ethnikis Antistaseos 161, Kalamaria, 55134 Thessaloniki, Greece.

E-mail: themisvamper@yahoo.com



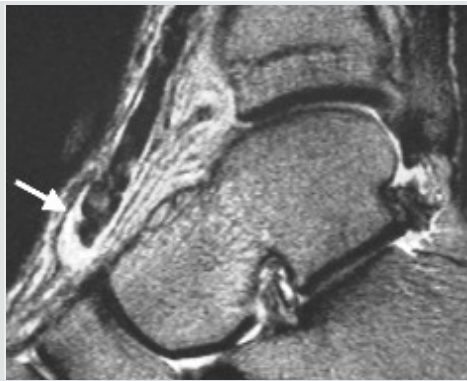

Figure 1: Magnetic resonance imaging scan of the patient's ankle joint. The proximal stub of the anterior tibial tendon can be seen (white arrow).

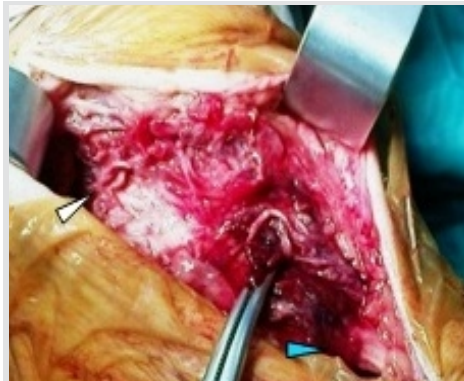


Figure 2: Photograph of the exposed proximal and distal stubs of the tibialis anterior tendon (white and blue arrow).

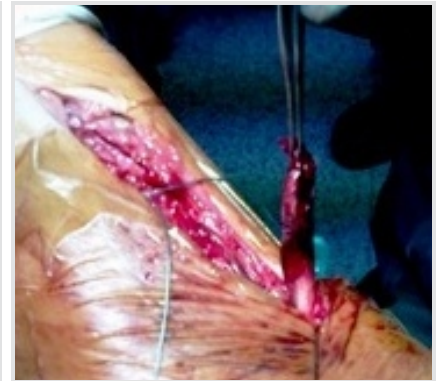

Figure 3: Photograph of the exposed central stub of the tendon after the placement of the bone anchor in the first sphenoid bone.

extent due to the contraction of the toe extensors, but heel walking on the right foot was impossible. Dorsiflexion with the foot in inversion was also impossible.

A gap was palpated along the course of the tibialis anterior tendon. The clinical diagnosis was rupture of the tendon of the anterior tibialis muscle. X-rays of the foot were normal, while the magnetic resonance imaging (MRI) scan confirmed the diagnosis (Fig. 1). The patient was relatively young (65 years old), active, and athletic (daily walks of 10 km); therefore, surgical treatment of the rupture was decided. The operation took place on the 9th post-traumatic day, after the swelling had subsided.

Under spinal anesthesia with the patient in supine position, an 8 cm incision was performed along the course of the tendon from the medial malleolus to the base of the first metatarsal. After partial opening of the tendon sheath of the tibialis anterior tendon, drainage of the hematoma was performed. The proximal stub of the tendon was found at the level of the ankle joint. The tendon was completely detached from its insertions (at the base of the first metatarsal– first cuneiform) (Fig. 2 and 3). With the foot in dorsiflexion and inversion, anchoring of the tendon on the first cuneiform bone was performed. Anchoring was performed with two 3mm bone anchors and Ethibond No. 2 sutures (Fig. 4). Reinforcing sutures were placed in the surrounding periosteum (Fig. 5). The patient's post-operative

course was free of complications.

The post-operative rehabilitation protocol included:

1. Application of a short leg cast for 4 weeks, without weight-bearing.
2. After the 4th week, the cast was removed and a lower leg splint of 90° fixed angle at the ankle joint was placed, which could be removed once per day for kinesiotherapy (passive mobilization from the neutral position to full dorsiflexion).
3. At 6 weeks partial weight-bearing and active movement of the foot was initiated.
4. The splint was removed in 8 weeks and the patient started to fully bear weight.
5. Three months after the operation, the patient returned to usual daily activities.

Discussion

Most ruptures of the insertion tendon of the anterior tibialis muscle are observed after torsional injuries of the ankle joint with plantar flexion of the forefoot. The initial intense pain and weakness of foot after the injury cause difficulty in full weight-bearing on the affected limb. Within 1 h from the injury, the patient's condition usually improves considerably so that he or she can move, but there is still difficulty in the dorsiflexion during the swing phase of gait. Foot drop is observed and the

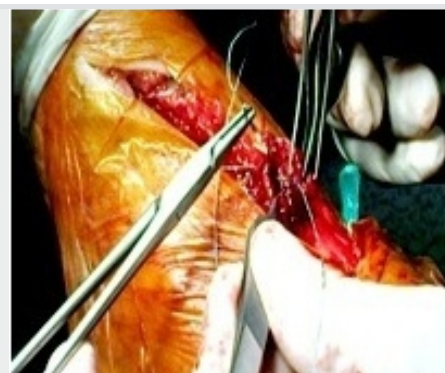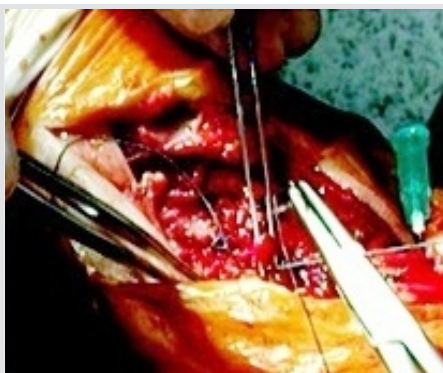


Figure 4: (a and b) Suturing of the tendon.

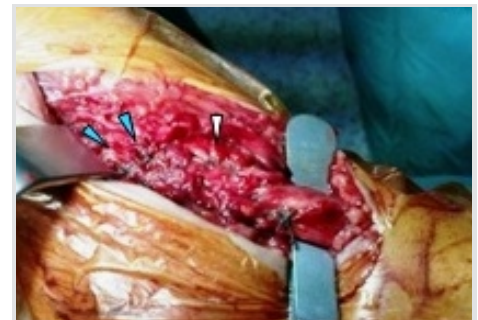

Figure 5: Completion of the suturing of the tendon, the blue arrows show the bone anchors and the white arrow points to the suturing of the periosteum.

patient hyper extends the toes in an effort to compensate for the deficit of the anterior tibialis muscle with the hallux and toes extensor muscles [8]. During clinical examination, in cases of complete rupture of the tendon, a gap can be palpated along the route of the tendon, while the proximal stub can be palpated at the level of the ankle joint. Swelling and bruising are usually observed in newly injured cases. In delayed cases, where the patients seek medical assistance several weeks after the injury, due to drop foot and since the acute symptoms have passed, care should be taken to exclude peroneal nerve paresis and chronic anterior compartment syndrome of the tibia [3].

The ultrasound and MRI, in particular, are very useful for confirming the diagnosis. In case of a total rupture, the MRI findings are as follows: Lack of the continuity of the tendon, thickening of the central portion of the tendon (due to shrinkage), and presence of sufficient quantity of fluid within the tendon sheath. In partial ruptures, abnormal signal can be observed along the tendon and sufficient amount of fluid within the tendon sheath [9]. Conservative treatment should be applied only in partial ruptures of the tendon in elderly patients with low demands and comorbidities that pose a high risk for surgical treatment [10]. Conservative treatment consists of applying a short leg cast for 6 weeks with the ankle joint in 90° of flexion and inversion. The long-term complications of conservative treatment are drop foot, acquired flatfoot and osteoarthritis of the subtalar joint [4].

In younger patients with higher demands, surgical treatment is preferred. The incision is slightly curved, along the tendon from the ankle joint level to the base of the first metatarsal. The tendon sheath is opened longitudinally, but with preservation of the part which lies below the transverse ligament, to ensure normal tendon motion and to avoid post-operative adhesions. If the distal stub is <1.5 cm long, end-to-end suturing should be avoided, and anchoring of the proximal stub to the first cuneiform and the base of the first metatarsal bone should be preferred. If this is not possible, then the proximal part of the tendon can be anchored to the navicular bone. In cases presented more than 3 weeks after injury, primary repair is almost always impossible [4, 11, 12]. In such cases, the possibilities are as follows:

- a. Transferring the tendon tibialis anterior muscle onto the extensor hallucis longus followed by transferring the insertion of extensor hallucis longus onto the first cuneiform (i.e., the insertion of tibialis anterior muscle).
- b. Tendon lengthening of tibialis anterior, whereby the tendon is first longitudinally and symmetrically split from its origin. The two divided tendon parts can be sutured side to side after sliding distally (5 cm), one of the two parts that have been released from its origin. The distal end of the foremost part is then

anchored onto the tibialis anterior insertion [13].

c. Use of a tendon graft from the tendon of the extensor of the fifth toe. In cases, where more than 3 months have passed from the injury, the results of surgical treatment cannot be predictable, as the anterior tibialis muscle has already undergone atrophy [14]. In literature, there is only one case of late (5 months post-injury) treated with tendon transfer of the extensor hallucis longus, with poor long-term results since the patient continued to have drop foot during walking.

Conclusion

As it is a rare clinical entity, rupture of anterior tibialis tendon can often be un- or mis-diagnosed. This is also due to the fact that it is not necessarily preceded by trauma. Nevertheless, an early diagnosis is essential as an early surgical repair is important for the quality of the clinical outcome in the long term. On the contrary, a delay in diagnosis and treatment is related to poor results. Particularly, in younger patients with higher demands (athletic, active), a quick resolution is crucial to sustain their level of daily activities. With delay in repair, loss of function and limitations in the range of motion (ROM) can be expected.

Indeed, as demonstrated by our case, during follow-up 10 months postoperatively, the patient had normal gait, strength of the tibialis anterior muscle was 5/5, and the patient was able to walk on his heels. ROM of the ankle joint showed a 5° plantar flexion lag. In the last follow-up, 25 months postoperatively, results were similar. The 5° deficiency in plantar flexion was the only permanent loss in the ROM, which, however, was not a setback for the patient who was able to return to his habits before the insult. There were no signs of edema and no pain was reported. The skin had physiologic coloration with no signs of ischemia.

The significance of this case is in the fact that the patient had a clear medical history and despite his 65 years, he had an active lifestyle. Literature reports that ruptures do occur in the absence of trauma but are often related to chronic treatment or disease. In our case, however, the rupture was a result of a minor injury in the absence of comorbidities.

Clinical Message

Despite being a rare clinical entity, a closed rupture of the anterior tibial muscle should always be a part of the differential diagnosis of drop foot with or without injury; as an early diagnosis followed by a surgical repair is essential for the favorable clinical outcome in cases of ruptures anterior tibialis tendon.

References

1. Kelm J, Anagnostakos K, Deubel G, Schliessing P, Schmitt E. The rupture of the tibial anterior tendon in a world class veteran fencer. *Sportverletz Sportschaden* 2004;18:148-52.
2. Bernstein RM. Spontaneous rupture of the tibialis anterior tendon. *Am J Orthop (Belle Mead NJ)* 1995;24:354-6.
3. Neuber M, Vennemann B, Brug E. Closed rupture of the tendon of the anterior tibial muscle. *Unfallchirurg* 1998;101:319-22.
4. Patten A, Pun WK. Spontaneous rupture of the tibialis anterior tendon: A case report and literature review. *Foot Ankle Int* 2000;21:697-700.
5. McMaster PE. Tendon and muscle ruptures. Clinical and experimental studies on time causes and location of subcutaneous ruptures. *J Bone Joint Surg* 1933;15:705-22.
6. Aydingöz U, Aydingöz O. Spontaneous rupture of the tibialis anterior tendon in a patient with psoriasis. *Clin Imaging* 2002;26:209-11.
7. Koenning H, Wirth CJ, Wegner U. Subcutaneous rupture of the tibialis anterior tendon. A case report. *Foot Ankle Surg* 1996;2:163-5.
8. Kashyap S, Prince R. Spontaneous rupture of the tibialis anterior tendon. A case report. *Clin Orthop Relat Res* 1987;216:159-61.
9. Gallo RA, Kolman BH, Daffner RH, Sciulli RL, Roberts CC, DeMeo PJ, et al. MRI of tibialis anterior tendon rupture. *Skeletal Radiol* 2004;33:102-6.
10. Markarian GG, Kelikian AS, Brage M, Trainor T, Dias L. Anterior tibialis tendon ruptures: An outcome analysis of operative versus nonoperative treatment. *Foot Ankle Int* 1998;19:792-802.
11. Kausch T, Rütt J. Spontaneous rupture of the tibialis anterior tendon: Review of the literature and case report. *Arch Orthop Trauma Surg* 1998;117:290-3.
12. Otte S, Klingler HM, Lorenz F, Haerer T. Operative treatment in case of a closed rupture of the anterior tibial tendon. *Arch Orthop Trauma Surg* 2002;122:188-90.
13. Wong MW. Traumatic tibialis anterior tendon rupture-delayed repair with free sliding tibialis anterior tendon graft. *Injury* 2004;35:940-4.
14. Van Acker G, Pigion F, Luitse J, Goslings C. Rupture of the tibialis anterior tendon. *Acta Orthop Belg* 2006;72:105-7.

Conflict of Interest: Nil

Source of Support: Nil

Consent: The authors confirm that Informed consent of the patient is taken for publication of this case report

How to Cite this Article

Vrettakos A, Vampertzis T, Vavilis T, Chaftikis N, Antonoglou G, Papastergiou S. Closed Rupture of Anterior Tibialis Tendon after Minor Injury without Medical History: A Surgical Repair. *Journal of Orthopaedic Case Reports* 2019 Jul-Aug; 9(4): 67-70.