

The Patient's Guide to Psoriasis Treatment. Part 2: PUVA Phototherapy

Benjamin Farahnik · Mio Nakamura · Rasnik K. Singh ·
Michael Abrouk · Tian Hao Zhu · Kristina M. Lee · Margareth V. Jose ·
Renee DaLovichio · John Koo · Tina Bhutani · Wilson Liao

Received: May 6, 2016 / Published online: July 29, 2016
© The Author(s) 2016. This article is published with open access at Springerlink.com

ABSTRACT

Background: PUVA treatment is photochemotherapy for psoriasis that combines psoralen with UVA radiation. Although PUVA is a very effective treatment option for psoriasis, there is an absence of patient resources explaining and demonstrating the process of PUVA. Studies

Enhanced content To view enhanced content for this article go to <http://www.medengine.com/Redeem/C9D4F0600C816B7E>.

B. Farahnik (✉)
College of Medicine, University of Vermont,
Burlington, VT, USA
e-mail: benjamin.farahnik@med.uvm.edu

M. Nakamura · K. M. Lee · M. V. Jose ·
R. DaLovichio · J. Koo · T. Bhutani · W. Liao
Department of Dermatology, Psoriasis and Skin
Treatment Center, University of California-San
Francisco, San Francisco, CA, USA

R. K. Singh
David Geffen School of Medicine at UCLA,
University of California-Los Angeles, Los Angeles,
CA, USA

M. Abrouk
School of Medicine, University of California-Irvine,
Irvine, CA, USA

T. H. Zhu
Keck School of Medicine, University of Southern
California, Los Angeles, CA, USA

have shown that patients who viewed videos explaining the treatment procedures for various medical conditions had a greater understanding of their treatment and were more active participants in their health.

Objective: To present a freely available online guide and video on PUVA treatment designed for patient education on PUVA.

Methods: The PUVA treatment protocol used at the University of California—San Francisco Psoriasis and Skin Treatment Center as well as available information from the literature was reviewed to design a comprehensive guide for patients receiving PUVA treatment.

Results: We created a printable guide and video resource that reviews the benefits and risks of PUVA, discusses the three types of PUVA (hand-foot soak, full body soak, and systemic), demonstrates the PUVA process, and provides practical tips for safe use.

Conclusion: Online media and video delivers material in a way that is flexible and often familiar to patients. This new format is beneficial for prospective patients planning to undergo PUVA treatment, health-care providers, and trainees who want to learn more about this treatment.

Keywords: Guide; OxSORALEN®; Patient education; Phototherapy; Psoralen; Psoriasis; PUVA; Ultraviolet A; UVA

INTRODUCTION

Psoriasis is one of the most common chronic inflammatory skin conditions, affecting 3–4% of the adult US population [1]. Untreated psoriasis can reduce social, occupational, and overall well-being [2]. Despite the availability of topical, oral, and systemic treatments, many patients with psoriasis, especially those with moderate-to-severe generalized psoriasis, are not adequately treated with an effective, long-term treatment regimen [3].

PUVA, or psoralen plus ultraviolet A (UVA) radiation, is one of the oldest, most effective treatments for psoriasis. It is also known as photochemotherapy, as it combines the use of psoralens, a group of plant-derived compounds that make the skin more sensitive to light, and exposure of skin to a source of high-intensity, long-wavelength, ultraviolet (UV) light. UV light is a type of light given off by the sun's rays and can be divided into UVC (200–280 nm), UVB (280–320 nm), and UVA (320–400 nm). Both UVA and UVB are used for phototherapy today. Sunlight has been utilized throughout centuries to treat various skin conditions, with one Indian medical text from 1500 BC describing a treatment combining herbs (likely containing psoralens) and natural sunlight to treat a vitiligo-like skin condition [4]. Researchers first noticed that UV light has an interesting effect of delaying the rapid growth of skin cells in people with psoriasis. They then demonstrated the effectiveness of topical psoralens followed by UVA light in clearing psoriatic plaques in 1974, though

research was done as early as 1970 for the treatment of vitiligo [5].

PUVA is used to treat a range of skin diseases in addition to psoriasis, including eczema, vitiligo, mycosis fungoides, prurigo nodularis, and graft-versus-host disease [6]. PUVA is exceptionally effective. It has been shown to reduce the Psoriasis Area and Severity Index by 75% or more (PASI-75) in 80% of patients, which is comparable to many of the biologic medications available today [7]. This makes PUVA particularly useful as a second-line agent when topical medications or UVB phototherapy have failed. As PUVA does not affect the immune system, it may be a more appropriate therapy for some patients compared to other oral and systemic treatments, which can have the potential to cause immune suppression [7].

As part of PUVA therapy, psoralen methoxsalen may be applied topically or taken orally prior to exposure to UVA light. At the University of California–San Francisco (UCSF) Psoriasis and Skin Treatment Center, a specific formulation of methoxsalen called OxSORALEN® Ultra (Valeant Pharmaceuticals North America LLC, Bridgewater, NJ, USA) is used as it has better bioavailability compared to other formulations of methoxsalen. There are three types of PUVA therapy: systemic PUVA (methoxsalen taken orally), hand and foot soak PUVA (methoxsalen dissolved in water for hand/foot soaking), and bath PUVA (methoxsalen dissolved in a bath tub for whole body soaking). All three forms of PUVA may be administered in an outpatient setting, such as a specialized dermatologic clinic, and patients may schedule their visits at their convenience.

PUVA treatment is administered over the long term in two separate phases: an initial

clearing phase and a maintenance phase. For each method of PUVA, during the initial clearing phase, patients will be treated two to three times weekly, with a minimum of 48 h in between each session. A general estimate for clearance is 25–30 treatment visits, or within 9–15 weeks [8–10]. However, this estimate will vary based on diagnosis, severity of disease, patient compliance with phototherapy treatments, and the overall treatment regimen. When it is determined that the psoriasis is 95% clear, the patient will be placed on a maintenance schedule for continuing treatment. During the maintenance schedule, the optimal dosing of light will be held constant and the frequency of treatments will be steadily decreased to as low as once per month [8, 11]. Ultimately, patients can discontinue PUVA treatments if in stable remission. Patients can return to PUVA treatments at the clearing schedule should they experience a flare of the psoriasis.

The initial dosing of UV radiation at the UCSF Psoriasis and Skin Treatment Center is based on the patient's skin color and reaction to sun exposure, also known as a Fitzpatrick skin type, and will be determined by the medical team. The initial dose exposure is generally within 0.5–6 J/cm² and may increase by 0.5–2.5 J/cm² [11]. Throughout the treatment, the medical team may adjust the dosing based on the control of disease, skin redness, or burns to maximize the safety and effectiveness of light treatment. Furthermore, the medical team may suggest a combination treatment consisting of PUVA with topical vitamin D analogs, topical corticosteroids, topical retinoids, oral retinoids, or other systemic medications [11–13]. Of note, however, cyclosporine and methotrexate are typically not used in conjunction with PUVA therapy [11, 12].

We will now describe important safety considerations, the flow of treatment, appropriate skin care, and possible side effects of PUVA therapy.

METHODS

We reviewed the PUVA therapy treatment protocol used at the UCSF Psoriasis and Skin Treatment Center. We also performed an English language literature search using Pubmed including the key words “PUVA”, or “Oxsoralen” or “psoralens” and “phototherapy” or “UVA” or “ultraviolet A”, to identify relevant articles to design a comprehensive guide for patients receiving PUVA treatment.

This article does not involve any new studies of human or animal subjects performed by any of the authors. All photos are printed with the consent of the subject(s).

RESULTS AND DISCUSSION

Overview

Every PUVA therapy treatment visit will involve the patient, as well as a coordinated care team consisting of nurses, support staff, and/or doctors. The first portion of PUVA treatment, involving methoxsalen (Oxsoralen Ultra), will be undertaken by the patient and the second portion, involving UVA radiation, will be administered by the nurse. Methoxsalen will be prescribed by the physician and patients should have the prescription filled prior to starting PUVA treatment. Patients receiving oral systemic PUVA should set aside at least 15 min for each appointment, while patients receiving hand and foot soak PUVA or bath PUVA should set aside at least 45 min (Table 1).

Table 1 Overview of PUVA phototherapy

Three types of PUVA therapy: systemic PUVA (taken orally), hand and foot soak PUVA, and bath PUVA
Initial frequency of 2–3 sessions per week
Appointments last between 15–45 min
Minimum 48-h interval between each session
Clearance rates around 80%, typically requiring 25–30 sessions
Oxsoralen Ultra prescription must be filled prior to the first treatment visit
Administered in 2 separate phases: clearing phase and maintenance phase

PUVA psoralen plus ultraviolet A

Safety Precautions

It is essential for the nursing staff and physicians to be aware of all current patient medications, including herbs and supplements, and any new prescriptions prior to and during the course of PUVA treatment, as some medications or supplements may photosensitize the skin. In such cases, the UVA dose will be reduced accordingly. The medical team should also be made aware of any history of skin cancer prior to starting phototherapy treatments, as PUVA may increase the risk of skin cancer. As UVA exposure to the eyes can cause cataracts [11], goggles are required while in the light box. However, important to note is that cataracts have only been observed in animal studies, while studies following human PUVA patients have found no increased risk of cataracts when proper eye protection is used [14]. Furthermore, if no disease is present on the face, a towel is used to cover the face. Men receiving UVA light should use proper genital shielding to reduce the risk of genital skin cancer. Finally, PUVA

Table 2 Safety precautions for PUVA phototherapy

Disclosure of all current medications, herbs, and supplements
Disclosure of any history of skin cancer
Eye examinations required prior to PUVA therapy and annually thereafter
Eye protection with goggles
Face shielding with towel
Male genital coverage with cone or towel ^a
Will not be used during pregnancy

PUVA psoralen plus ultraviolet A

^a Unless an exception has been granted

should not be used in pregnant women, and women who become pregnant while on PUVA will need to stop their treatment. Contraception is recommended to women of childbearing age who wish to continue PUVA treatments (Table 2).

Flow of Treatment

Every patient receiving UVA light therapy will check in at the front desk and gather all necessary supplies, including goggles, a gown, towels, and genital covering for men. Patients receiving hand and foot soak PUVA or bath PUVA should also get a measuring cup and additional towels. Prior to stepping into the UVA light box, patients receiving the three different types of PUVA will follow three different protocols, as described below.

For systemic PUVA treatment, patients must take methoxsalen by mouth 75 min prior to each of their scheduled appointment times. Methoxsalen may be taken at home or anywhere the patient feels comfortable, so long as it is taken 75 min prior to entering the light box. The dose of methoxsalen is modified

for each patient based on individual body weight, at a ratio of 0.4–0.6 mg/kg of weight. Each patient should follow the specific instructions written on the prescription (Table 3a).

For hand and foot soak PUVA, patients will use their measuring cup to mix 10 mg of methoxsalen with 2 quarts of warm water for just hands or feet, or 20 mg of methoxsalen with 4 quarts of warm water for both hands and feet (the exact mixture ratio may vary; each patient should follow the specific instructions written on the prescription). Water can come from a warm water sink or can be microwaved. Mixing the methoxsalen with warm water will cause the pill to dissolve and the solution will turn into a light aquamarine color. It is helpful if the nurse demonstrates this process during the initial treatment visits. The nurse will want to examine the hands and feet prior to soaking in solution to determine a proper light dose. After making the solution, the affected areas on the hands and/or feet will be soaked within the solution for 30 min prior to light exposure. After soaking, the solution should be discarded into the sink and hands and feet dried prior to returning to the nurses' station for the UVA treatment. Patients should only dry, not rinse off, after soaking (Table 3b; Fig. 1).

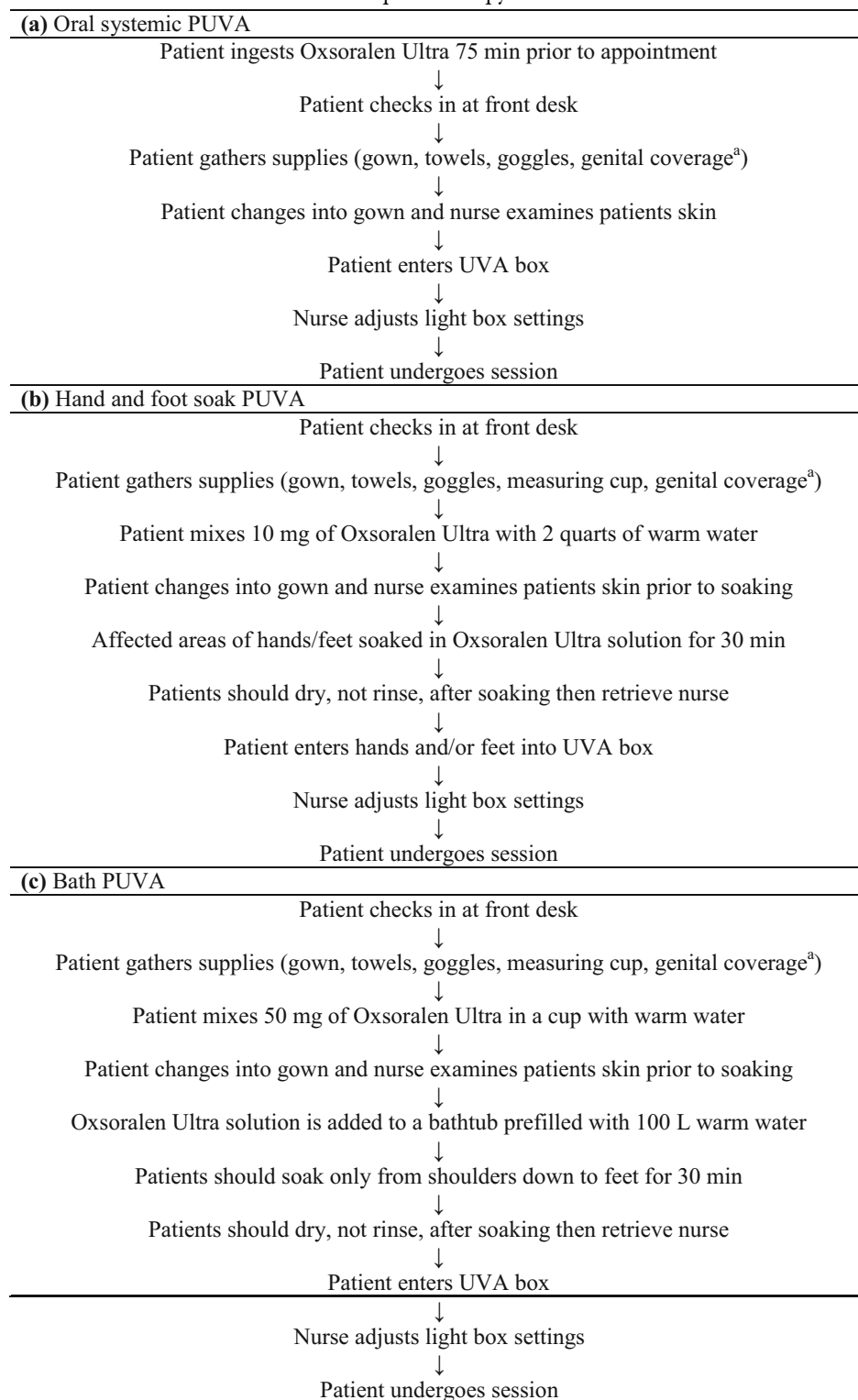
Bath PUVA involves soaking in a bathtub for 30 min prior to light exposure. Patients will dissolve 50 mg of methoxsalen in a measuring cup filled with hot water. The solution should be mixed until an aquamarine-colored solution is formed. This solution will then be added to a bathtub that is prefilled with 100 L of warm water. Nursing staff will demonstrate this process during the initial treatment visits. The nurse will want to examine the skin prior to soaking in solution to determine a proper light dose. Timers will be available in each bathroom, so that patients may be able to time their soak for 30 min. It is important to note that soaking

in the tubs should only be done from the shoulders down to the feet. The face should never be soaked. After soaking for 30 min, patients should carefully step out of the bath and dry off without showering off the bath solution. Patients may then drain the solution and notify the nursing staff that they are ready for the light box treatment (Table 3c; Fig. 2).

Once patients are ready for the light treatment, they will be guided by the nurses to the UVA light box. Patients treated with hand and foot soak PUVA will be using a specialized light box that accommodates only the hands and/or feet. Those being treated with systemic or bath PUVA will step into a whole body light box. After making sure that all safety precautions are followed, including goggles and genital shielding, the nurse may wrap the patient's face in a towel. The nurse will position the patient in a way that will maximize light penetration and this position will be maintained during the entire light treatment to clear the disease effectively and prevent burns. The nurse will then set the light settings according to the patient's needs. Light will shine on the patient for several seconds to minutes depending on the patient's individual dose. While in the light box, it is important for patients to keep their eyes closed and goggles on, and bulbs should not be touched. Following the UVA light treatment, the patient may return to the dressing room to get dressed and the treatment session is complete. At each subsequent treatment session, the dose of light (duration of light treatment) will be adjusted depending on the patient's reaction to the previous treatment session.

Post-phototherapy Skin Care

It is important to take good care of the skin after each treatment session. Methoxsalen can cause

Table 3 Flow of treatment for PUVA phototherapy

PUVA Psoralen plus ultraviolet A

^a Genital coverage may be required for male patients unless an exception has been granted

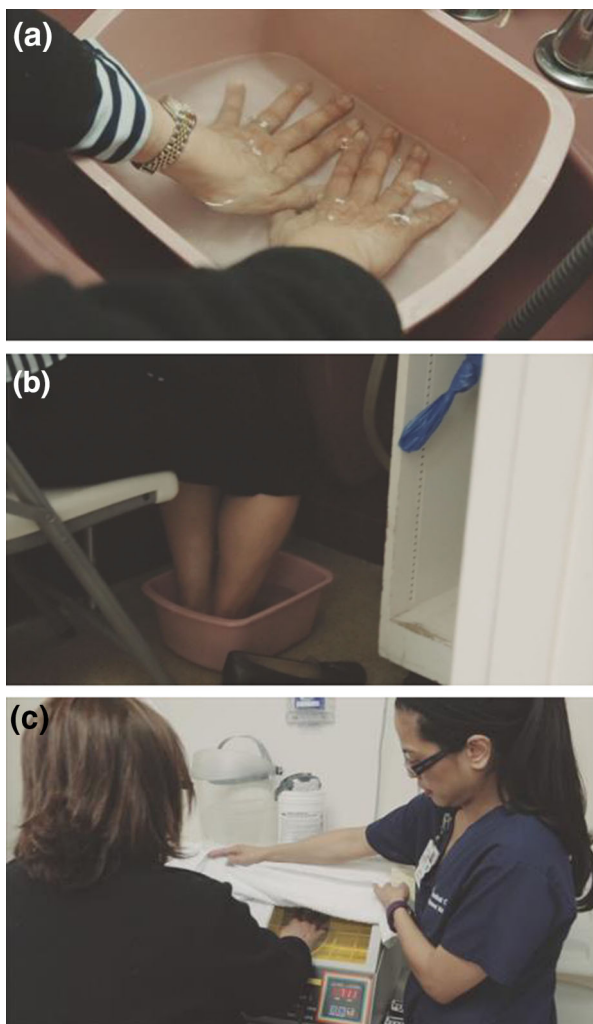


Fig. 1 Hand and foot soak PUVA treatment procedure

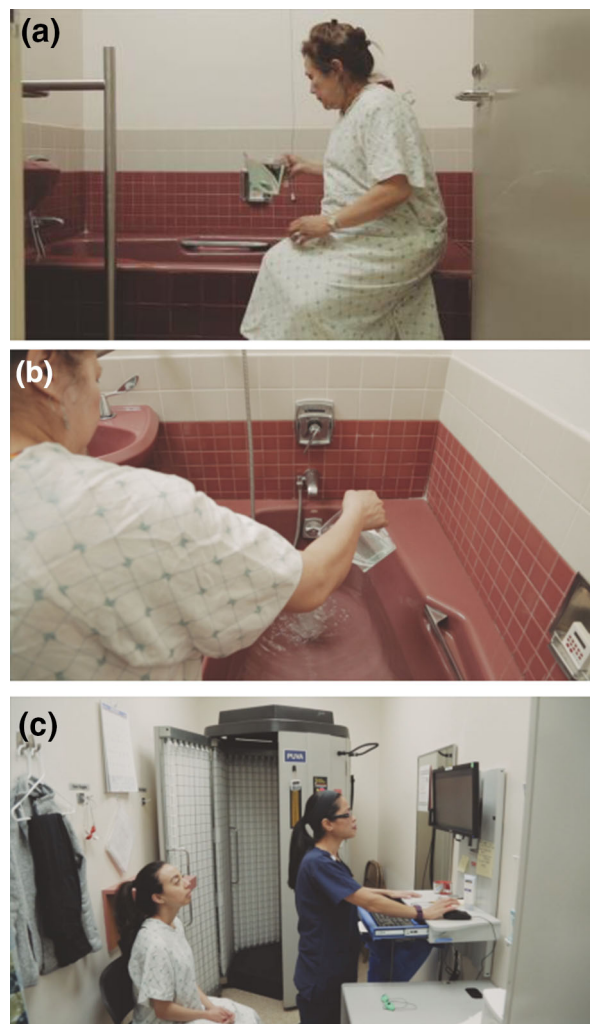


Fig. 2 Bath PUVA treatment procedure

the skin to become more sensitive to light and, therefore, patients are more susceptible to sunburn. Patients should avoid exposure to sunlight, even through window glass, for 24 h after treatment with PUVA. Patients should apply sunscreen with Sun Protection Factor (SPF) of 15 or above to any sun-exposed skin for at least 24 h after PUVA treatment. Sunscreen should be reapplied every 1.5 h if outdoors. Patients should also use moisturizers and lotions on the affected areas at least twice daily as part of their routine skin care regimen.

Care should be taken to avoid scrubbing the skin, as any trauma or breakdown of the skin can potentially cause worsening of psoriasis in a process called the Koebner phenomenon. Patients should limit makeup and nail polish on areas receiving treatment to allow full light penetration. While perfume and colognes are fine when applied to clothes, they should not be applied to skin, as some of the chemicals may be photosensitizing and may increase the risk of burning during PUVA treatment. Lastly, it is important to limit sunbathing during the

Table 4 Post-phototherapy skin care for PUVA phototherapy

Avoid exposure to sunlight and use sunscreen of SPF 15 or higher for at least 24 h after PUVA

Moisturize skin twice daily and frequently in between treatments

Avoid scrubbing skin hard or tearing off skin

Limit nail polish and makeup on areas receiving treatment

Avoid perfumes and colognes directly on skin

Avoid sunbathing during the clearing stage of PUVA treatment

PUVA psoralen plus ultraviolet A, *SPF* sun protection factor

clearing stage of PUVA treatment to reduce the risk of sunburn, which can interfere with the PUVA treatment regimen (Table 4).

Side Effects

There are some risks and possible side effects of PUVA treatment. Some of the potential short-term side effects include burning, itching, and pigmentation of the skin. Burns, which often appear as redness, tenderness, and blistering, may start 24–72 h after treatment in up to 10% of patients during the clearance phase [15]. For mild burns, a topical corticosteroid cream or ointment may be applied as directed. Mild itching is common and can usually be relieved with topical emollients. A moderate-to-deep tan may develop while on treatment, but often fades 6–8 weeks after stopping treatment. Nausea is the most common side effect unique to systemic PUVA and may be reduced by taking methoxsalen with protein, milk, or a full meal.

Long-term risks of PUVA treatment include cataracts, skin aging changes, and skin cancer. Cataracts are considered a theoretical risk, as

Table 5 Side effects of PUVA phototherapy

Side effect	Signs/symptoms
Short term	
Burning	Redness, tenderness, tightness, blistering Noticeable 24–72 h after treatment
Itching	Usually mild and relieved with emollients
Nausea	Unique to oral systemic PUVA Reduced by consuming Oxsoalene Ultra with protein, milk, or full meal
Tanning	Skin darkening
Long term	
Photoaging	Coarseness, wrinkling, laxity, increased fragility, freckling
Cataracts	Blurry vision, as though looking through frosted glass Theoretical risk that has not been confirmed in humans with proper eye protection
Non-melanoma and melanoma skin cancers	Unusual shaped growths or lumps may appear to grow quickly over time Genital skin cancer possible, but prevented with shielding

PUVA psoralen plus ultraviolet A

studies on humans with proper eye protection have not confirmed an increase in the risk of cataracts with UVA exposure [14]. Skin aging changes may include dryness, wrinkling, and freckling, which may disappear after treatment is stopped, though freckling may persist indefinitely. PUVA can lead to an increased risk of non-melanoma and melanoma skin cancers, particularly among light-skinned individuals and those who have previously received X-rays or Grenz rays [16]. The risk of genital skin cancer

may also be increased, but may be prevented with proper shielding (Table 5) [17].

CONCLUSIONS

PUVA treatment is a very effective and safe treatment option for patients whose psoriasis is not well controlled on topical therapies alone. PUVA may also be a viable option for patients who have failed UVB therapy. PUVA requires patient compliance with consistent treatments for 9–15 weeks to achieve maximal results. When administered and monitored properly, PUVA can help patients safely achieve clearance and in many cases provide long-lasting remission. The effectiveness of PUVA is comparable to some of the most effective biologic agents available today for the treatment of moderate-to-severe psoriasis. It is our hope that this guide can serve as a valuable resource for patients considering or preparing for PUVA treatment and the health-care providers who treat these patients.

ACKNOWLEDGMENTS

We would like to thank Tim Sarmiento for producing, directing, and editing the educational video that accompanies this manuscript. We would also like to thank the amazing staff and nurses from the UCSF Psoriasis and Skin Treatment Center for inspiring and helping to make the video possible. We thank Olivia Chen for her help reviewing the Spanish translation of the accompanying video. No funding or sponsorship was received for publication of this article. All named authors meet the International Committee of Medical Journal Editors (ICMJE) criteria for authorship for this manuscript, take responsibility for the integrity

of the work as a whole, and have given final approval for the version to be published.

Disclosures. John Koo is a speaker for AbbVie, Leo, and Celgene, and conducts research for Amgen, Janssen, Novartis, Photomedex, Galderma, Pfizer, and Merck. Tina Bhutani is an advisor for Cutanea and conducts research for Abbvie, Janssen, and Merck. Wilson Liao conducts research for Abbvie, Janssen, Novartis, and Pfizer, and receives funding from the NIH (R01AR065174, U01AI119125). John Koo, Tina Bhutani, and Wilson Liao have no stocks, employment, or board memberships with any pharmaceutical company. Benjamin Farahnik, Mio Nakamura, Michael Abrouk, Tian Hao Zhu, Rasnik K. Singh, Kristina M. Lee, Margareth V. Jose, and Renee DaLovich have nothing to disclose.

Compliance with Ethics Guidelines. This article does not involve any new studies of human or animal subjects performed by any of the authors. All photos are printed with the consent of the subject(s).

Open Access. This article is distributed under the terms of the Creative Commons Attribution-NonCommercial 4.0 International License (<http://creativecommons.org/licenses/by-nc/4.0/>), which permits any noncommercial use, distribution, and reproduction in any medium, provided you give appropriate credit to the original author(s) and the source, provide a link to the Creative Commons license, and indicate if changes were made.

REFERENCES

1. Rachakonda TD, Schupp CW, Armstrong AW. Psoriasis prevalence among adults in the United States. *J Am Acad Dermatol.* 2014;70(3):512–6.

2. Feldman SR, Malakouti M, Koo JY. Social impact of the burden of psoriasis: effects on patients and practice. *Dermatol Online J*. 2014;20(8):1.
3. Lebwohl MG, Bachelez H, Barker J, Girolomoni G, Kavanaugh A, et al. Patient perspectives in the management of psoriasis: results from the population-based Multinational Assessment of Psoriasis and Psoriatic Arthritis Survey. *J Am Acad Dermatol*. 2014;70(5):871.
4. Diels J, Arissian L. *Lasers: the power and precision of light*. London: Wiley-VCH; 2011.
5. Baker H. PUVA therapy for psoriasis. *J R Soc Med*. 1984;77(7):537–9.
6. Parrish JA, Fitzpatrick TB, Tanenbaum L, Pathak MA. Photochemotherapy of psoriasis with oral methoxsalen and longwave ultraviolet light. *N Engl J Med*. 1974;291(23):1207–11.
7. Lim HW, Silpa-archa N, Amadi U, Menter A, Van Voorhees AS, Lebwohl M. Phototherapy in dermatology: a call for action. *J Am Acad Dermatol*. 2015;72(6):1078–80.
8. Melski JW, Tanenbaum L, Parrish JA, Fitzpatrick TB, Bleich HL. Oral methoxsalen photochemotherapy for the treatment of psoriasis: a cooperative clinical trial. *J Invest Dermatol*. 1977;68(6):328–35.
9. Photochemotherapy for psoriasis. A clinical cooperative study of PUVA-48 and PUVA-64. *Arch Dermatol*. 1979;115(5):576–9.
10. Wolff KW, Fitzpatrick TB, Parrish JA, Gschnait F, Gilchrist B, et al. Photochemotherapy for psoriasis with orally administered methoxsalen. *Arch Dermatol*. 1976;112(7):943–50.
11. Schneider LA, Hinrichs R, Scharffetter-Kochanek K. Phototherapy and photochemotherapy. *Clin Dermatol*. 2008;26(5):464–76.
12. Racz E, Prens EP. Phototherapy and photochemotherapy for psoriasis. *Dermatol Clin*. 2015;33(1):79–89.
13. Al Hothali GI. Review of the treatment of mycosis fungoides and Sézary syndrome: a stage-based approach. *Int J Health Sci*. 2013;7(2):220–39.
14. Malanos D, Stern RS. Psoralen plus ultraviolet A does not increase the risk of cataracts: a 25-year prospective study. *J Am Acad Dermatol*. 2007;57(2):231–7.
15. Morison WL, Marwaha S, Beck L. PUVA-induced phototoxicity: incidence and causes. *J Am Acad Dermatol*. 1997;36(2 Pt 1):183–5.
16. Stern RS. The risk of squamous cell and basal cell cancer associated with psoralen and ultraviolet A therapy: a 30-year prospective study. *J Am Acad Dermatol*. 2012;66(4):553–62.
17. Stern RS, Bagheri S, Nichols K. The persistent risk of genital tumors among men treated with psoralen plus ultraviolet A (PUVA) for psoriasis. *J Am Acad Dermatol*. 2002;47(1):33–9.