

Repairing Facial Fractures with Interrupted Maxillary-mandibular Arches by Computer-assisted Reverse Planning Model Surgery

Chien-Chung Chen, MD*†
 Ching-Hsiang Yang, MD‡
 Yu-Jen Chang, DDS, MSS§
 Cheng-Chun Wu, MD‡
 Li-Ren Chang, MD*†
 Jui-Pin Lai, MD‡

Background: Management of comminuted facial fractures with maxillary-mandibular arch interruption is difficult, resulting in inadequate bone reduction and malocclusion. Traditionally, a good quality dental splint is helpful, but difficult to obtain in acute trauma. We apply a computer-assisted design and three-dimensional printing technology to improve splint fabrication and utilization, thus facilitating restoration of dental occlusion and facial fracture.

Methods: We retrospectively reviewed patients who suffered from facial fractures with interruption of the maxillary-mandibular arches. We developed the “computer-assisted reverse planning and three-dimensional printing model surgery” algorithm and applied it in selected patients. An occlusal splint was created as a surgical guide to enhance the maxilla-mandibular unit repair by taking care of the bone reduction and occlusion. All included patients were followed up to assess the functional outcome and patients suitable for this method.

Results: From Jan 2015 to Aug 2020, 10 patients (eight men and two women) with comminuted facial fractures were included. The average time of surgery was 9.2 days. The average follow-up time was 8.6 months. There was no patient who needed major revision to correct malocclusion or facial asymmetry.

Conclusions: A computer-assisted design splint decreases intraoperative inaccuracies and difficulty in comminuted maxillo-mandibular fractures. It is a useful and reliable alternative. Collaboration with an experienced engineer and patient selection are indispensable in delivering successful outcomes. Patients who have more than three bone fragments in a single dental arch or more than four bone fragments in the entire maxillary-mandibular unit appear to be excellent candidates for this method. (*Plast Reconstr Surg Glob Open* 2022;10:e4149; doi: 10.1097/GOX.0000000000004149; Published online 21 February 2022.)

INTRODUCTION

The maxillo-mandibular unit (MMU) is fundamental in the reconstruction of the mid-third and lower-third facial structure.^{1,2} However, management of comminuted

facial fracture remains challenging. Following a multisegmented fracture of the maxilla or mandible, the facial width, dental arch form, and pre-morbid occlusion are difficult to restore. Fractured bone reduction does not adequately restore the pre-morbid arch form and facial width, leading to discrepancies between dental occlusion and bone fracture reduction.

Splint-assisted reduction has been proposed in patients with unstable and segmented maxillary or mandibular dental arch fractures,^{3,4} facilitating dental arch formation, occlusion, and fracture reduction. However, traditional dental splinting requires quality dental impression, which may be very difficult to obtain in an acute illness setting. Lack of a real fracture surface on the traditional dental cast also ultimately affects the accuracy of the occlusal splint.³⁻⁵

The aim of this study was to investigate the use of a novel computer-assisted reverse planning and 3D printed model surgery to improve occlusal splint fabrication. Computer-assisted design (CAD) and 3D printing

From the *Department of Plastic and Reconstructive Surgery, E-DA Hospital, Kaohsiung, Taiwan; †College of Medicine, I-Shou University, Kaohsiung, Taiwan; ‡Department of Plastic and Reconstructive Surgery, Kaohsiung Chang Gung Memorial Hospital and Chang Gung University College of Medicine, Kaohsiung, Taiwan; and §Department of Orthodontic Department, Kaohsiung Chang Gung Memorial Hospital and Chang Gung University College of Medicine, Kaohsiung, Taiwan.

Received for publication October 23, 2021; accepted January 4, 2022.

Copyright © 2022 The Authors. Published by Wolters Kluwer Health, Inc. on behalf of The American Society of Plastic Surgeons. This is an open-access article distributed under the terms of the [Creative Commons Attribution-Non Commercial-No Derivatives License 4.0 \(CCBY-NC-ND\)](https://creativecommons.org/licenses/by-nc-nd/4.0/), where it is permissible to download and share the work provided it is properly cited. The work cannot be changed in any way or used commercially without permission from the journal.

DOI: 10.1097/GOX.0000000000004149

Disclosure: The authors have no financial interest to declare in relation to the content of this article.

techniques have revolutionized craniofacial surgery.^{6,7} We aimed to demonstrate their utility for treating acute comminuted facial fractures in the production of an accurate and reliable occlusal splint, treatment outcome examination, and eligible patient population selection.

PATIENTS AND METHODS

Patient Selection

We carried out a retrospective review of records from two medical institutions between January 2015 and August 2020. All patients with comminuted maxillary and mandibular fractures treated using CAD and 3D printing models for surgical planning were included. Edentulous patients, patients with gunshot injury, and those who lacked fine image quality or adequate long-term follow-up were excluded. This study was approved by the institutional review board of the E-DA hospital.

Computer-assisted Reversed Planning and 3D Printed Model Surgery

Each patient underwent computed tomography (CT) before the surgery. Digital Imaging and Communications in Medicine (DICOM) data were processed using the software (Mimics, Materialist NV, Leuven, Belgium) to create a 3D virtual facial bone structure. Each fracture fragment was well segmented to eliminate possible metallic artifacts from the teeth (Fig. 1). Following this, a plaster model bearing the maxillary and mandibular segments was created using a 3D printer. These printed “mock” fragments were assembled and restored to their anatomical positions, according to the bone fracture lines and dental occlusion. These assembled fragments were fixed with dental wax to obtain a 3D model of the MMU. We digitally scanned the model back into the 3D virtual facial bone structure to check for condyle position, facial profile, and symmetry. Orthodontists ensured that the occlusion was functional. Dental wax fixation allowed readjustments to be made on the model. Once the final relative position of the maxilla and mandible was determined, an occlusal splint was made according to the model (Fig. 2). During the operation, the occlusal splint served as a guide to restore the maxillary and mandibular arches (Fig. 3). Finally, the reduced MMU served as a reference for the reduction of the rest of the face, based on general principles. If the patient encountered a condylar or subcondylar fracture, an open reduction and internal fixation would be performed routinely. We kept intermaxillary fixation with an elastic rubber band for 2 weeks after the surgery. All the patients were followed up at our plastic and orthodontic clinics to assess wound conditions, stability of bone reduction, occlusion, and masticatory function.

RESULTS

From January 2015 to August 2020, 10 patients (eight men and two women) with comminuted facial fractures were included in the study. Their mean age was 27 years (range 18–47 years). Eight patients had comminuted

Takeaways

Question: How to obtain quality occlusal splint and management of acute comminuted maxillo-mandibular fractures?

Findings: Through a retrospective review of records, we selected 10 patients who had undergone comminuted maxillary and mandibular fracture treatment, virtually designed and printed occlusal splints, which served as guides for surgical correction of the entire face. We found out that the models decreased intraoperative inaccuracies and improved aesthetic appearance.

Meaning: Computer-assisted reverse planning model surgery decreases intraoperative inaccuracies in the reduction of difficult comminuted maxillo-mandibular fractures.

panfacial fractures, and two patients had comminuted maxillary and palatal fractures. Eight of the patients had dental injuries and massive tooth loss (Table 1). The average time from injury to operation was 9.2 days

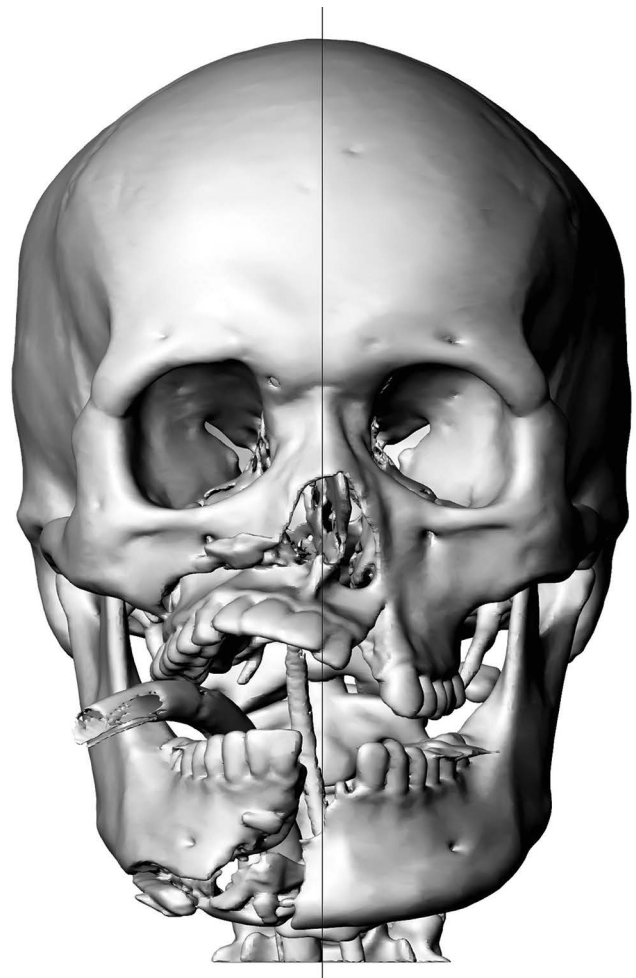


Fig. 1. Computerized tomography data was well segmented and eliminated artifact from teeth.

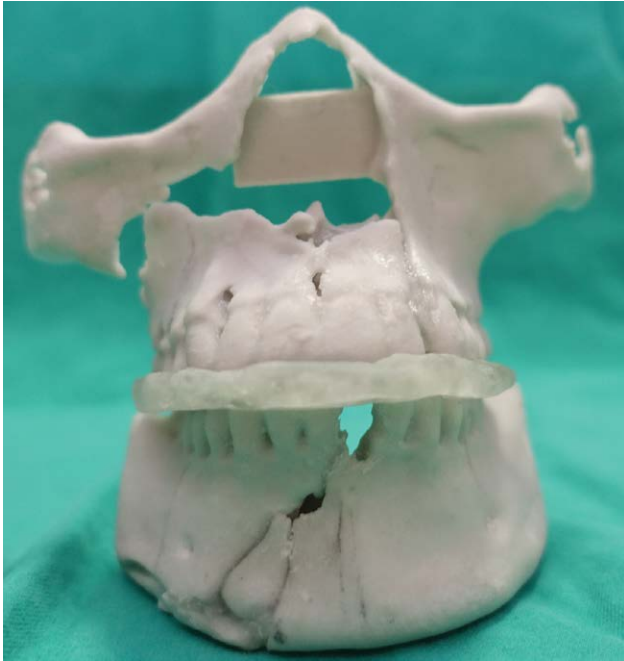


Fig. 2. Three-dimensional printed bone segments were assembled to complete the MMU structure, then occlusal splint is made according to this model.

(range 4–15 days), and the time to create a model for each patient ranged from 4–7 days. The average number of total arch bone fragments was 4.7 (range 3–7 pieces) (Table 2). The average follow-up time was 8.6 months (range 6–13 months). After six months of follow-up, no patient needed orthognathic surgery to correct malocclusion or facial asymmetry. We did not encounter a delayed union or malunion in this study. Two patients received orthodontic treatment for better aesthetic dentition (Table 3). Minor wound infections were noted in two patients and were treated successfully by minor debridement and antibiotics.

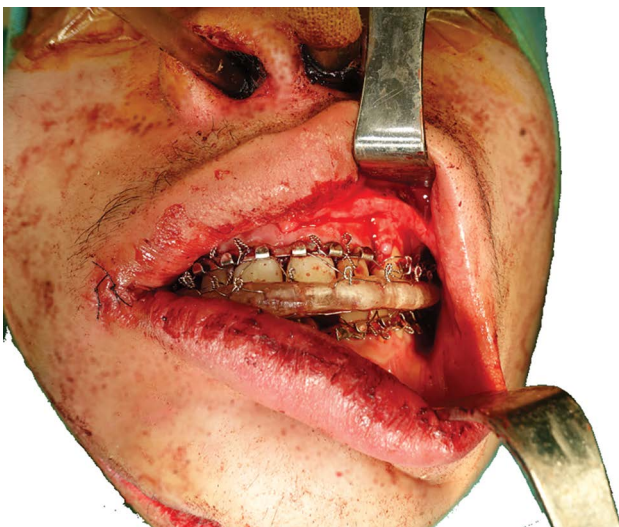


Fig. 3. Occlusal splint is applied with arch bar as a guide to complete the maxillary and mandible unit reduction.

Case Presentation

Case I

A 22-year-old man, victim of a road accident, suffered from multiple traumas and comminuted facial fractures (Fig. 1). We prepared a 3D printed model and an occlusal splint. The 3D printed teeth bearing fracture segments provided a real 3D structure without a soft tissue envelope, which overcame the visual limitation in real surgery (Fig. 2). We arranged the occlusal splint while awaiting management of his associated trauma; thus, treatment timing was not delayed. Fracture repair was performed on the 11th day of hospitalization. The occlusal splint allowed complete simultaneous reduction of the maxillary and mandibular arches. The well-fixed MMU structure provided a stable 3D base for other facial fracture repairs. At 6 months post operation, the CT scan showed good bone union, facial symmetry (Fig. 4), and stable occlusion, matching almost exactly with the preoperative 3D model design (Fig. 5). The patient was followed up for 7 months without further complications or secondary surgery.

Case II

A 19-year-old patient, victim of a road accident, suffered a comminuted mid-facial fracture with multiple segmental maxillary arch fractures (Fig. 6). The traditional dental impression was encumbered with multiple missing teeth, gingival mucosal lesions, and alveolar bone exposure (Fig. 7). Resetting the pre-morbid occlusion was not our primary goal because this case involved multiple missing teeth. We prepared an occlusal splint to provide the stable dental arch and proper dental alignment for further dental treatment. The splint was designed based on the best maxillary fracture reduction, facial width control, and better relative mandibular position. An occlusal splint provided dental arch support and surgical guide during the maxillary bone reduction and maintained postoperative stability. The gingival and palatal mucosae were treated without interference from the occlusal splint (Fig. 8). We achieved good facial symmetry and bone union without secondary surgery (Fig. 9A). The patient opted for further orthodontic and prosthodontic treatments (Fig. 9B).

DISCUSSION

In panfacial fracture management, controversy still exists in the sequencing of fixation. Bottom-top or top-bottom operative sequence cannot apply to all situations and should depend on patient presentation.⁹ No matter which sequence is followed, the stable MMU restoration provides 3D fundamentals for further facial reconstruction and stable mastication function.^{1,2} However, in severe comminuted facial fractures, where maxillary and mandibular arches are interrupted, there are no reliable dental templates or bone references to restore the MMU.

The mandible symphysis can be used as the starting point in panfacial fracture repair because of its strength and relatively simpler fractures in panfacial injuries.¹⁰ The larger bone mass and relatively simple fracture pattern are more reliable guides for anatomic reduction than the maxilla. However, without reference to the complete

Table 1. Fracture Types, Dental Injury, and Interval from Injury to Surgery

No.	Age	Gender	Fracture Site		Teeth Loss	Interval† (d)
			Mandible	Midface*		
1	22	Man	Bil. Subcondylar	LeFort I+II,	+	10
2	38	Man	Symphysis	Palate type III	+	10
3	47	Man	Right subcondylar	LeFort I+II+palate type I	+	8
4	27	Woman	Symphysis	LeFort I+ left zygoma +palate type I	-	10
5	22	Man	Bil condylar head, Symphysis	LeFort I+ II+NOE+right zygoma+palate type III	+	11
6	19	Man	—	Maxilla fx+palate type I	+	4
7	18	Man	Parasymphysis	LeFort I+II,	-	9
8	30	Woman	Bil condylar,	Palate type III	+	10
9	24	Man	Angle, body	LeFort I+II+III, Palate type I	+	15
10	24	Man	Bilateral condylar fx, symphysis	LeFort I, Palate type III	+	5
			Parasymphysis	LeFort I+II / palate type III	+	

*Chen's palatal fracture classification.⁸

†Interval: time from injury to operation day.

maxillary arch form, inadequate reduction of the lingual surface of the mandible causes widening of the gonion in the transverse dimension.

Chen et al proposed a maxillary trans-molar wiring method to adjust the maxilla width to the mandible when setting the MMU back to the premorbid position in the sagittal split maxilla fracture.⁸ However, in a comminuted palatal-alveolar fracture, it is difficult to achieve precise anatomic reduction with wiring in multiple fragile maxillary segments.⁸ The splint-assisted method was proposed as a guide to assist bone reduction by positioning the teeth in the splint.³ The splint design mimics the premorbid occlusion prepared before the surgery by re-assembling post-traumatic cast segments of the maxillary and mandibular

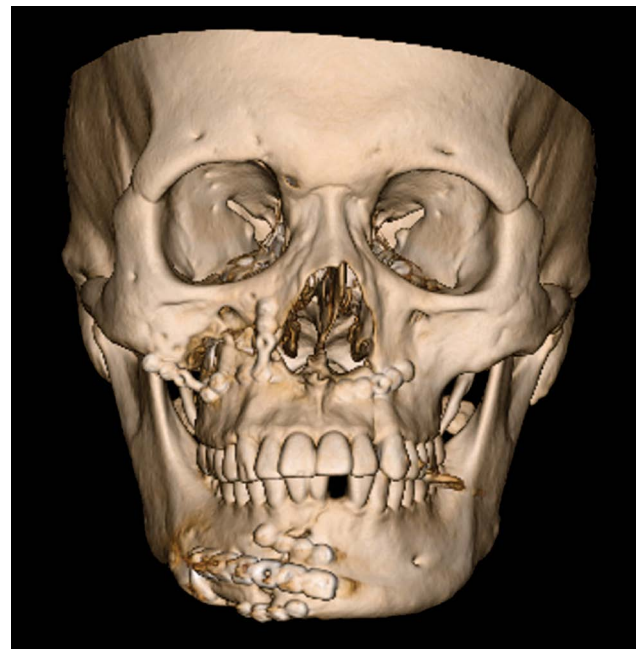

Fig. 4. Computerized tomography 6 months later.

Table 2. Fragments over Teeth Bearing MMU

Case No.	No. Fragments of MMU*		
	Mandible	Midface	Total
1	2	3	5
2	3	2	5
3	3	3	6
4	No fracture	3	3
5	2	2	4
6	No fracture	3	3
7	2	2	4
8	4	3	7
9	2	3	5
10	2	3	5

*Fragment of MMU: fragment over teeth bearing part of maxilla-mandibular bone.

Table 3. Follow-up Periods and Complications

Case No.	Follow-up Time (mo)	Need Orthodontic Treatment	Need OGS*	Complication
1	9	+	-	-
2	8	-	-	-
3	6	-	-	-
4	8	-	-	-
5	7	-	-	Wound infection
6	13	+	-	-
7	8	-	-	-
8	7	-	-	Wound infection
9	13	-	-	-
10	7	-	-	-

*OGS: Orthognathic surgery.

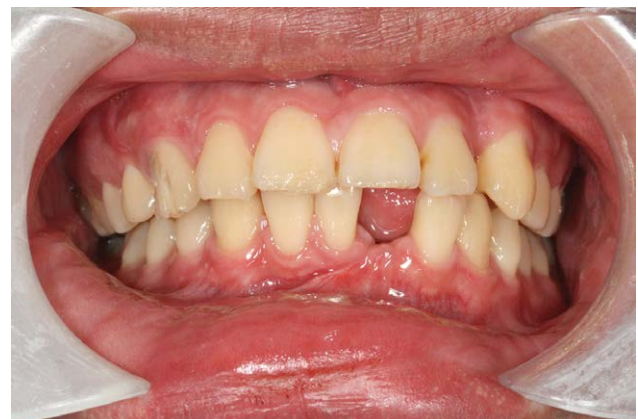

Fig. 5. Stable occlusion 6 months after the operation.

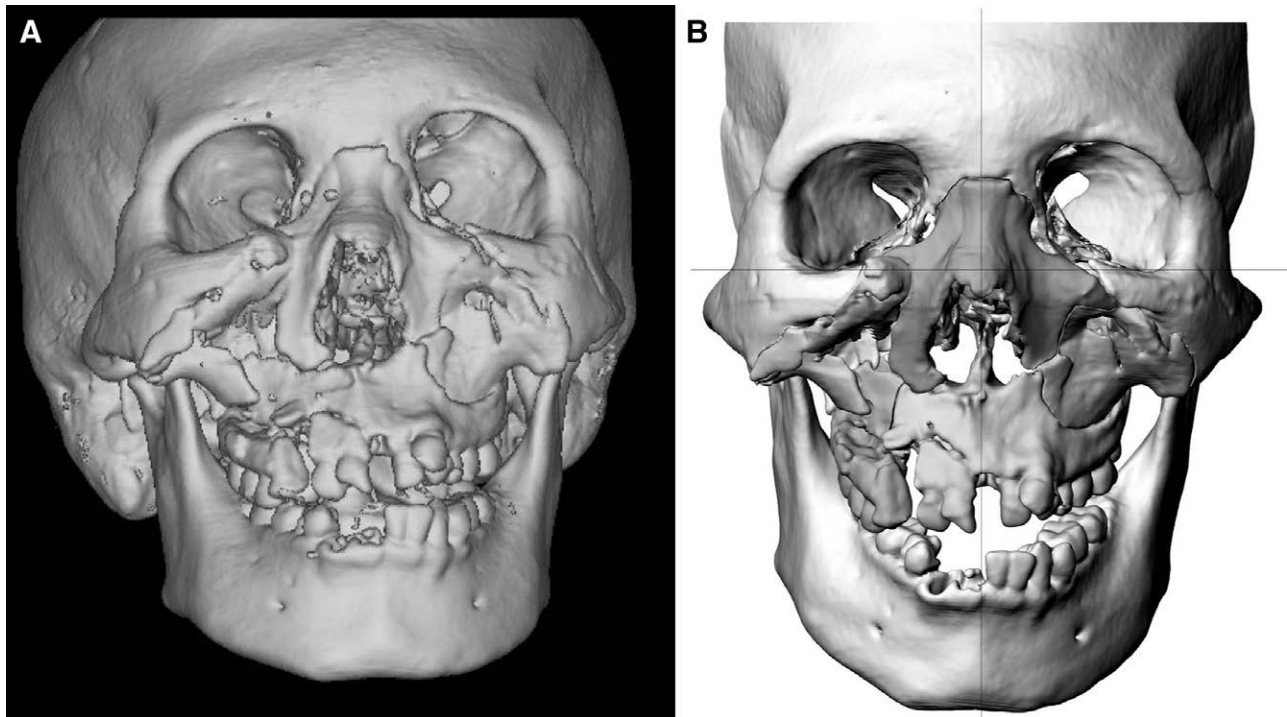


Fig. 6. Computerized tomography scan data was transformed and segmented by software. A, Preoperation computerized tomography, showing comminuted mid-facial fracture with segment maxilla dental arch. B, Fracture pieces were well segmented by the software.

arches. However, precision of the splints made from traditional dental impressions is not always reliable or feasible, possibly because of the difficult production processes and numerous intraoral complications due to severe trauma.¹¹ The subsequent dental cast and model surgery would not be reliable, rendering a suboptimal splint. In comminuted palatal-alveolar fracture, there are still high complications and malocclusion rates even with splint assistance.^{8,12,13}

Technologies such as CAD and 3D printing have been widely applied in craniofacial reconstruction to provide good facial symmetry and functional outcomes in most difficult clinical cases. Life-sized 3D printed anatomical models

and customized designed surgical prostheses or guides can be created to assist planning and surgery. Optic oral scan provides high-resolution dental images and improves accuracy of the digital splint manipulation. Virtual simulation surgical planning and 3D printed surgical guides have superseded traditional 2D planning, improving surgical precision and satisfaction, and shortening operation time.¹⁴⁻¹⁸

Tepper et al and Kongsong et al completely reduced the entire MMU reduction virtually, and manufactured the occlusal splint as a surgical guide.^{11,19} Compared with our method, it seems simpler and more environmentally friendly. However, the movement and rotation of the bone segment to fit the irregular fracture surface is very difficult. Achieving proper virtual reduction necessitates high-quality image data acquisition, fine segmentation, and a good software engineer. The variability can result in large discrepancies between the virtual simulation and actual surgery. Compared with Tepper et al, our technique allows intuitive fragment adjustment with real haptic tactile feedback and importantly, adjustment of maximum inter-cusp dental contact to achieve pre-morbid occlusion.

The 3D printed “mock” fragments of the maxilla and mandible were life-sized, direct vision without the skin and soft tissue. This simulation overcame the real-life intraoperative challenge of reduction due to inadequate visualization of the entire 3D structure of the fracture fragments. Sometimes, when dealing with a comminuted fracture segment with multiple teeth missing, the most optimal position is a compromise between the bone structure and teeth contact, as in case II. This trial-and-error adjustment preoperatively relieves intraoperative stress for the surgeon and saves operating time.

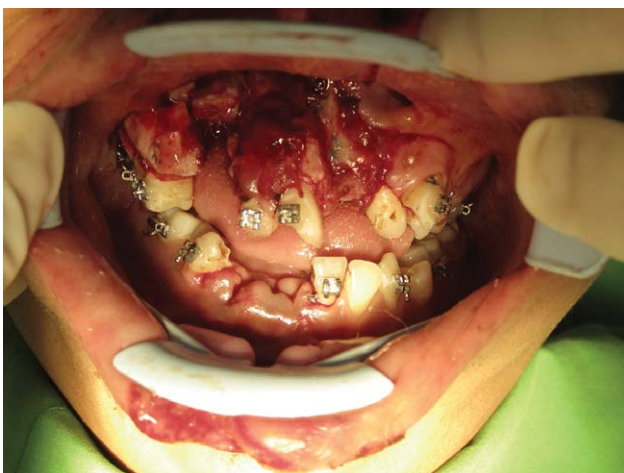


Fig. 7. Poor oral condition with missing teeth, mucosal injury, and bone exposure.

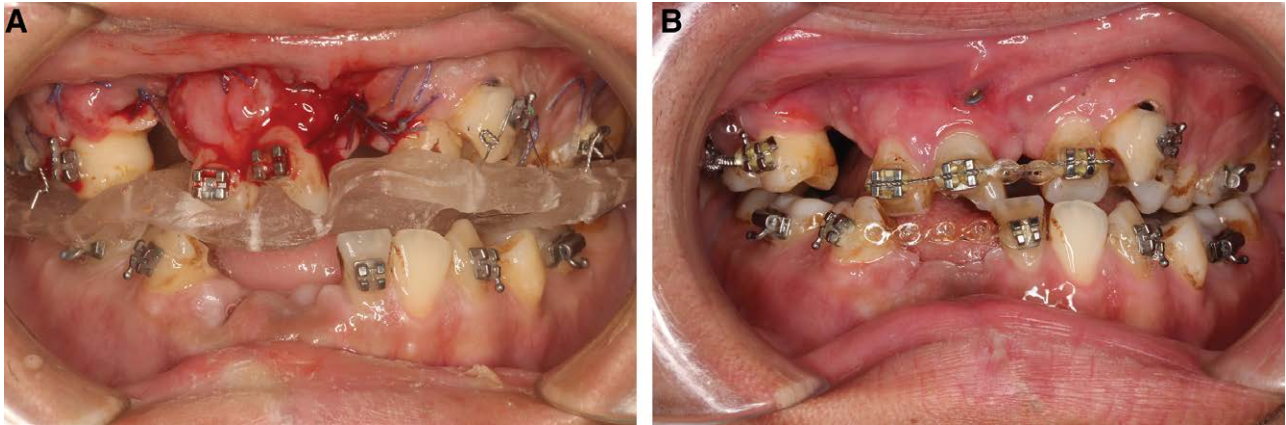


Fig. 8. Occlusal splint serves as a surgical guide and decreases mucosa complication. A, Occlusal splint could provide good support and surgical guide during bone reduction and fixation. B, Gingiva mucosa can be well repaired and protected, decreasing wound complication post operation.

There are some different concepts of the splint design in our study compared with the orthognathic surgery or other reconstruction with stable jaw and good dentition. Facing the complicated traumatic oral environment, we could not have high-resolution dental images, such as dental impression or optic oral scan. We did not replace the dental image from medical CT scan. Preoperation fitness of the occlusal splint was not possible either. We picked up the suitable cases, for which fine CT image of the teeth is available after hard work by a computer engineer. The occlusion setting in such a severe segmented dental arch injury should be compromised between the best inter-cusp dental contact and bone reduction. The goal is to provide a good facial symmetry, profile, stable dental arch, and proper dental alignment for further dental treatment. The use of CAD and 3D printing in the management of acute facial fractures does not delay surgical timing, as presurgical procedures can be done immediately after the CT scan is obtained. In our clinical setting, presurgical CAD and 3D printing algorithms can

be completed within 1 week. This allows ample time for the treatment or stabilization of the associated trauma. The average time between admission and definite facial bone surgery in this series was 9.2 days. There were no CAD or 3D printing-related delays.

All our patients had stable occlusion and easy oral mucosa wound care, with neither fistulas nor severe complications. A high wound complication rate (9%–42%) has been reported in complicated palatal fractures treated with the traditional splint method.^{8,10,11} CAD splints provided stable occlusion and bone reduction, following the rigid bone fixation. This could reduce the possibility of prolonging intermaxillary fixation and decreasing oral mucosal complications. In some cases, we used the orthodontic bracket instead of the traditional arch bar or tooth wiring method. It prevented further gingival mucosa injury in trauma patients, and provided an alternative choice, as multiple teeth were missing. There would be no adequate teeth to wire the arch bar to the dental arch of the maxilla or mandible.

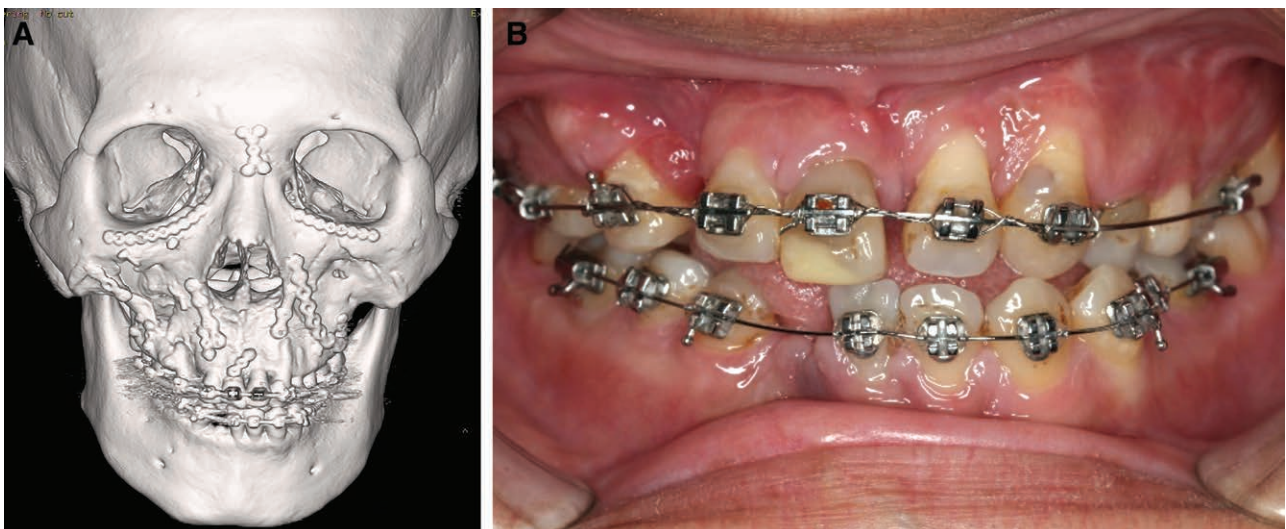


Fig. 9. Postoperative follow-up. A, Computerized tomography 6 months later. B, Patient received orthodontic treatment to enhance the dental morphology.

To our knowledge, this is the largest series of complete treatment algorithms for complicated facial fractures with interrupted maxillary and mandibular arches. However, our technique had some limitations. Firstly, we need a fine cut (<1 mm) CT scan and the elimination of intraoral metallic artifacts using software manipulation. Cooperation with experienced engineers and learning curves is important. Secondly, extra computer-designed and 3D printer models incurred additional healthcare costs for patients. Finally, some errors between the virtual simulation and real conditions were possible in the whole process. We suggest applying only suitable patients. Based on our limited experience of 10 cases, we recommend using our method for patients with more than three bone fragments in one dental arch or more than four bone fragments in the entire MMU. Lack of a control group was another limitation in this study. Further study is needed to make a more comparative conclusion and validate this claim.

CONCLUSIONS

Computer-assisted reverse planning model surgery decreases intraoperative inaccuracies in the reduction of difficult comminuted maxillo-mandibular fractures. It is a useful and reliable alternative, delivering good surgical outcomes and shortening the surgical time. Collaboration with an experienced software engineer and proper patient choice are indispensable to ensure more effective practice.

Jui-Pin Lai, MD

No.123, Ta Pei Rd.
Niaosong Dist.
Kaohsiung City 833
Taiwan

E-mail: benjplai@yahoo.com

REFERENCES

- Manson PN, Clark N, Robertson B, et al. Subunit principles in midface fractures: the importance of sagittal buttresses, soft-tissue reductions, and sequencing treatment of segmental fractures. *Plast Reconstr Surg*. 1999;103:1287–306; quiz 1307.
- Manson PN, Clark N, Robertson B, et al. Comprehensive management of pan-facial fractures. *J Craniomaxillofac Trauma*. 1995;1:43–56.
- Konaş E, Tunçbilek G, Kayıkçıoğlu A, et al. Splint-assisted reduction of comminuted or complex maxillofacial fractures. *J Craniofac Surg*. 2011;22:1471–1475.
- Cohen SR, Leonard DK, Markowitz BL, et al. Acrylic splints for dental alignment in complex facial injuries. *Ann Plast Surg*. 1993;31:406–412.
- Chidylo SA, Jacobs JS. Applications of dental splints with regard to modern techniques of rigid fixation. *J Craniofac Surg*. 1994;5:136–141.
- Gerstle TL, Ibrahim AMS, Kim PS, et al. A plastic surgery application in evolution: three-dimensional printing. *Plast Reconstr Surg*. 2014;133:446–451.
- Jacobs CA, Lin AY. A new classification of three-dimensional printing technologies: systematic review of three-dimensional printing for patient-specific craniomaxillofacial surgery. *Plast Reconstr Surg*. 2017;139:1211–1220.
- Chen CH, Wang TY, Tsay PK, et al. A 162-case review of palatal fracture: management strategy from a 10-year experience. *Plast Reconstr Surg*. 2008;121:2065–2073.
- Massenburg BB, Lang MS. Management of panfacial trauma: sequencing and pitfalls. *Semin Plast Surg*. 2021;35:292–298.
- Yang R, Zhang C, Liu Y, et al. Why should we start from mandibular fractures in the treatment of panfacial fractures? *J Oral Maxillofac Surg*. 2012;70:1386–1392.
- Kongsong W, Sittitavornwong S. Utilization of virtual surgical planning for surgical splint-assisted comminuted maxillomandibular fracture reduction and/or fixation. *Craniomaxillofac Trauma Reconstr*. 2020;13:334–341.
- Moss WJ, Kedarisetty S, Jafari A, et al. A review of hard palate fracture repair techniques. *J Oral Maxillofac Surg*. 2016;74:328–336.
- Hendrickson M, Clark N, Manson PN, et al. Palatal fractures: classification, patterns, and treatment with rigid internal fixation. *Plast Reconstr Surg*. 1998;101:319–332.
- Chang EI, Jenkins MP, Patel SA, et al. Long-term operative outcomes of preoperative computed tomography-guided virtual surgical planning for osteocutaneous free flap mandible reconstruction. *Plast Reconstr Surg*. 2016;137:619–623.
- Roser SM, Ramachandra S, Blair H, et al. The accuracy of virtual surgical planning in free fibula mandibular reconstruction: comparison of planned and final results. *J Oral Maxillofac Surg*. 2010;68:2824–2832.
- Brucoli M, Boffano P, Pezzana A, et al. The use of optical scanner for the fabrication of maxillary obturator prostheses. *Oral Maxillofac Surg*. 2020;24:157–161.
- Chen Z, Mo S, Fan X, et al. A meta-analysis and systematic review comparing the effectiveness of traditional and virtual surgical planning for orthognathic surgery: based on randomized clinical trials. *J Oral Maxillofac Surg*. 2021;79:471.e1–471.e19.
- Naran S, Steinbacher DM, Taylor JA. Current concepts in orthognathic surgery. *Plast Reconstr Surg*. 2018;141:925e–936e.
- Tepper OM, Sorice S, Hershman GN, et al. Use of virtual 3-dimensional surgery in post-traumatic craniomaxillofacial reconstruction. *J Oral Maxillofac Surg*. 2011;69:733–741.