

Diagnostic Value of Cytokeratin 34 beta E12 (Ck34βE12) and α-Methylacyl-CoA racemase (AMACR) Immunohistochemical Expression in Prostatic Lesions

Ikram A. Hasan¹ , Hiba Ahmed Gaidan¹ , Methaq Mueen Al-kaabi^{1*} 

1. Pathology and Forensic Medicine Department, College of Medicine, Mustansiriyah University, Baghdad, Iraq

KEYWORDS

Immunohistochemistry,
Ck34βE12,
AMACR,
Prostatic carcinoma,
BPH
Scan to discover online



Main Subjects:
Uro pathology

Received 06 Sep 2019;
Accepted 10 April 2020;
Published Online 21 May 2020;

 [10.30699/ijp.2020.113544.2229](https://doi.org/10.30699/ijp.2020.113544.2229)

ABSTRACT

Background & Objective: Some prostatic lesions contain small suspicious foci for prostatic carcinoma in which the morphological features are equivocal. Two immunohistochemical markers namely, cytokeratin 34 beta E12 (Ck34βE12) and α-Methylacyl-CoA racemase (AMACR), were evaluated in these lesions for a definitive diagnosis and avoiding misdiagnosis or overdiagnosis of prostatic carcinoma.

Methods: A total of 90 paraffin embedded blocks of prostatic tissue were selected and categorized into three groups as follows: 50 cases of benign prostatic hyperplasia (BPH), 20 cases of prostatic carcinoma, and 20 cases of benign prostatic lesions with suspicious foci labeled as ASAP (atypical small acinar proliferation) that occupy not more than 5% of the lesion. These cases were revised for histopathological diagnosis and stained with two immunohistochemical markers: Ck34βE12 and AMACR.

Results: While 92.9% of BPH were positive for Ck34βE12, 96% of prostatic carcinoma were negative for this marker ($P=0.0001$). Regarding AMACR, 92.9% of BPH cases were negative, but 92% of prostatic carcinoma cases were positive for this marker ($P=0.0001$). Out of 20 cases of BPH, 15 cases containing suspicious foci showed Ck34βE12+/AMACR- (diagnosis: benign), but 5 cases were Ck34βE12-/AMACR+, for which the diagnosis changed to prostatic carcinoma ($P=0.04$).

Conclusion: Immunohistochemical staining with Ck34βE12 and AMACR improved the diagnostic performance and increased confidence level for establishing definite diagnosis in cases with suspicious foci, in which the morphological features were equivocal. This could help to avoid misdiagnosis or overdiagnosis of prostatic carcinoma that would eventually improve the management of the patient and subsequently the prognosis.

Corresponding Information: Methaq Mueen Al-kaabi; Pathology and Forensic Medicine Department, College of Medicine, Mustansiriyah University, Baghdad, Iraq Email: dr.methaq.mueen@uomustansiriyah.edu.iq

Copyright © 2020. This is an open-access article distributed under the terms of the Creative Commons Attribution- 4.0 International License which permits Share, copy and redistribution of the material in any medium or format or adapt, remix, transform, and build upon the material for any purpose, even commercially.

Introduction

Prostate carcinoma is considered the most common cancer among males and is the second cause of cancer related deaths in men in the US. It is usually seen in men over 50 years of age (1). Prostatic carcinoma is less common in developing countries, though its incidence and mortality rate is rising (2).

In Iraq, the incidence of prostatic carcinoma in males was 3.3% of all new diagnosed cases of cancer in 2008 (3), while in 2015, the incidence rate increased to 6.5% (4).

Diagnosis of prostatic carcinoma depends on clinical, radiological, and serological markers like prostatic specific antigen (PSA); however, many factors affect PSA level like inflammation, infection, medication, cystoscopy, and colonoscopy (5,6).

Since the diagnosis of prostatic carcinoma often leads to radiation therapy or surgery with the associated morbidity, histopathologists are under very intense pressure to avoid overdiagnosis of prostatic carcinoma (7). The histopathological diagnosis of prostatic adenocarcinoma is based mainly on combination of architectural and cytological features of microscopic examination for sections that are stained with hematoxylin and eosin.

Major diagnostic criteria are infiltrative pattern of glandular growth, absence of basal cells, and nuclear atypia like nucleomegaly. In addition, some minor criteria include intraluminal mucin that is wispy and blue, amorphous pink secretion, mitoses, intraluminal crystalloids, prostatic intraepithelial neoplasia of high grade in the adjacent area, amphophilic cytoplasm, and hyperchromatic nuclei (8). Immunohistochemical

examination is an important ancillary method in the diagnosis of prostatic carcinoma, especially in prostatic needle biopsies that contain atypical glandular proliferation of limited amounts (9).

With major effort in the early detection of prostatic carcinoma by massive screening of men, there is high number of small foci of carcinoma seen in specimens of prostatic needle biopsies; and this is considered as one of the major diagnostic challenges in histopathology due to the presence of benign mimickers (10).

Basal layer encircled benign lesions, while it is absent in malignant glands; therefore, basal cell markers like p63, Ck34 β E12, and CK5/6 are used to highlight basal cells in benign lesions and to aid in differentiating them from other malignant lesions in challenging cases (11,12).

The major limitation of using negative markers is the discontinuous or patchy presence of basal cells in the benign glands. As the result, negative staining of Ck34 β E12 in some glands that are suggestive of cancer is not a proof of their malignancy because benign glands may not show uniform positivity with this marker (13).

Moreover, α -Methylacyl-coenzyme A racemase (AMACR or p504s) is a novel marker that is positive in malignant epithelial prostatic carcinoma cell (4,15). AMACR is susceptible to variability of staining because of the effect of immunohistochemical techniques by formalin fixation with loss of patchy staining in the benign glands. This makes the interpretation of atypical benign glands on the base of negative stain findings difficult to appreciate (16). This might be related to high false results or misdiagnosis of histological mimickers of carcinoma such as PIN of high grade or atrophic acini that shows negative false staining (10).

To confirm the diagnosis, using AMACR in association with negative markers such as Ck34 β E12 and p63 have been shown to be helpful when small atypical glands are seen on routine hematoxylin and eosin (H & E) staining (10).

The major limitation of using negative markers is the discontinuous or patchy presence of basal cells in the benign glands. So, negative staining of Ck34 β E12 in some glands that are suggestive of cancer is not proof of their malignancy because benign glands may not show uniform positivity with this marker (17).

AMACR is susceptible to variability in staining because of the effect of immunohistochemical techniques by formalin fixation with loss of patchy staining in the benign glands. This makes the interpretation of atypical benign glands on the base of negative stain findings difficult to appreciate (18). This may contribute to high false results or misdiagnosis of histological mimickers of cancer such as prostatic intraepithelial neoplasm PIN of high grade or atrophic acini that shows negative false staining (9).

The aim of the current study is to evaluate the expression of these two markers in different benign and malignant prostatic lesions and their significance in differentiation between them.

Materials and Methods

In this retrospective study, a total of 90 formalin-fixed paraffin embedded prostatic tissue blocks, retrieved from the archives of histopathology department of teaching laboratories of Al-Yarmouk and Al-Karama Teaching Hospitals in Baghdad, Iraq were included in the period between July 2016 and July 2018. The blocks were collected after obtaining the approval of the related Ethical Committee. These blocks include different sampling procedures including 17 needle biopsies, 63 transurethral resection of prostate (TURP) cases, and 10 simple prostatectomy cases. Clinicopathological parameters like age, histopathological diagnosis grade, stage of prostatic carcinoma, and all other information were obtained from the available histopathological reports.

Depending on the initial diagnosis, blocks were divided into two groups: 70 benign prostatic hyperplasia (BPH) cases and 20 prostatic adenocarcinoma cases.

From each block, three sections were taken with five micrometer thickness for each. The first one was examined by H&E staining and the histopathological diagnosis was revised by three histopathologists; then they were subdivided into three groups as follows: benign prostatic tissue (50 cases), malignant prostatic tissue (20 cases), and those with suspicious foci of malignancy (20 cases).

Most of those with suspicious foci labeled as atypical small acinar proliferation (ASAP) that consist of small, crowded gland occupying less than 5% of the biopsy. These lesions lack cytological and architectural features of frank prostatic carcinoma but raise the possibility of one of prostatic carcinoma mimics.

The second and third slides of each case were stained immunohistochemically with Ck34 β E12, while the third slide was stained by AMACR.

The immunohistochemical method was conducted briefly as follows: from each block, 5 micrometer section was applied on a positively charged slide. The sections were deparaffinized in xylene (2 changes for 10 min each) and rehydrated in decreasing graded of ethanol and distilled water (2 changes of 100% ethanol for 5 min each, then 2 changes in 95%, then in 70%, and lastly 30% before putting them in distilled water). Antigen retrieval solution (PathnSitu MERS multi epitope retrieval solution) was used by microwave for 20 min, then the solution was allowed to cool for 10 min. The next step was transferring the slides to distilled water. Peroxidase block solution was applied for 5 min and TBS was washed. After that, protein blocker solution was added then the primary antibody was applied, CK34BE12 (Abcam with dilution 1:500 incubate overnight) while third slides of each case were

stained with AMACR (PathnSitu Biotechnologies India clone 13H4 rabbit monoclonal dilution 1:50) and incubated for 1 hour at room temperature.

A secondary antibody conjugated with horseradish peroxidase (HRP) was added to the slides and incubated at room temperature for 30 minutes then the slides were washed with TBS. Chromogen substrate was added and incubated for 5 minutes and the excess was removed using TBS washing. The slides then were counterstained with hematoxylin for 1-3 minutes and then were washed by tap water. The slides are subjected for dehydration using graded alcohol (95% and 100% ethanol).

The positive and negative control were included in every run. For Ck34βE12, the basal cells layer of normal prostatic glands in prostatectomy specimen serve as good internal control while normal epidermis was used as the external positive control. Regarding AMACR, prostatic carcinoma was regarded as positive control. Technically negative controls were used by making sections of the same specimens and omitting the primary antibody from the staining protocol. The evaluation and interpretation of immunohistochemical slides were done in a blinded manner without prior knowledge about the clinical data.

Scoring of the immunohistochemically stained slides was performed by three independent histopathologists according to the following criteria (Immunohistochemical evaluation for Ck34βE12):

The brownish cytoplasmic staining of basal layer is regarded as positive and graded as below: negative (0%). Mild if <5%, moderate if between 5%-75% and strong if >75% (19).

The brownish cytoplasmic staining of basal layer is regarded as positive and graded as below: if <5% as mild, if 5%-75% as moderate, and if >75% as strong (19).

AMACR

Positive staining appears as circumferential dark diffuse or granular cytoplasmic of luminal epithelial layer. Positive percentage was graded from 0+ to 3+ as follows: 0% cells (negative), 1-10% cells (mild, 1+), 11-50% cells (moderate, 2+), and >51% cells (strong, 3+). Adjacent glands that are benign should not show more than partial and weak (noncircumferential) staining. Negative staining means no staining or weak focal staining (11).

Statistical Analysis

Statistical analysis was performed using SPSS version 24 (SPSS Inc., Chicago, Ill., USA). Pearson Chi-square test was also used. P-value<0.05 was regarded as significant and P-value<0.001 as highly significant.

Results

A total of 90 cases of prostatic lesions were included in this study (70 BPH cases and 20 prostatic carcinoma cases). The mean age of patients was 63 years (age range: 52-80 years). The immunohistochemistry results were as follows (Table 1):

Ck34βE12

BPH: 65 (92.9%) cases were positive (Figure 1) and only 5 (7.1%) cases that showed suspicious foci were negative for this marker.

For the positive cases: 51 (72.8%) cases showed strong staining, 7 (10%) cases demonstrated moderate staining, and 7 (10%) cases revealed mild staining.

Prostatic Carcinoma:

Most cases (24 (96%)) were negatively stained and only one positive case (4%) was mildly stained.

Table 1. The immunohistochemical staining pattern for Ck34βE12 and AMACR in BPH and prostatic carcinoma.

Immunohistochemical markers (IHC)	Prostatic Carcinoma (n= 25)	Benign prostatic hyperplasia) BPH (n=70)	P-value
Ck34βE12			
Positive	1 (4%)	65 (92.9%)	0.0001 *
Strong	0	51 (72.9%)	
Moderate	0	7 (10%)	
Mild	1 (4%)	7 (10%)	
Negative (0%)	24 (96%)	5 (7.1%)	
AMACR			
Positive	23 (92%)	5 (7.1%)	0.0001*
Strong	17 (68%)	1 (1.4%)	
Moderate	5 (20%)	4 (5.7%)	
Mild	1 (4%)	0	
Negative	2 (8%)	65 (92.9%)	

*Significant difference between proportions using Pearson Chi-square test at 0.05 level.
AMACR: α -Methylacyl-coenzyme A racemase

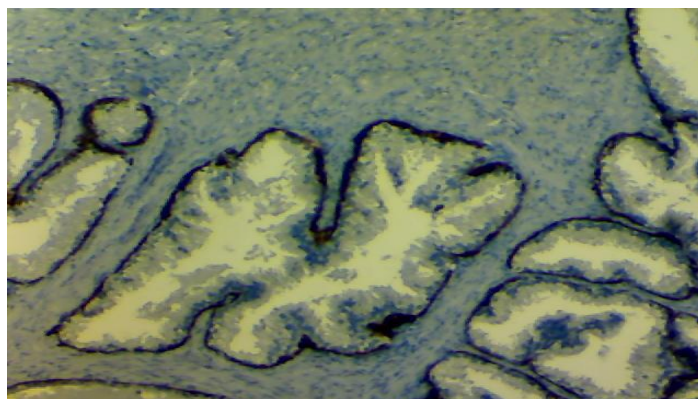


Fig. 1. Photomicrograph of benign prostatic hyperplasia (BPH) with positive staining by Ck34βE12 seen as cytoplasmic brownish pigment in peri-glandular basal layer.

AMACR

BPH

Most cases (67 (95.7%)) were negatively stained and only three cases (4.3%) were positively stained with mild intensity. In contrast, the prostatic carcinoma cases showed 21 (92%) positive cases, of which 17 (68%) cases showed strong staining (Figure 2), three cases showed moderate intensity (Figure 3), and only one case showed mild intensity (Table 1).

Regarding BPH with suspicious foci, after immunohistochemical staining, the diagnosis changed from benign to malignant in 5 cases. Accordingly, the total benign cases was 65 and the malignant cases was 25.

In our study, 20 cases of BPH contained suspicious foci of ASAP. After immunohistochemical staining, it was revealed that 15 cases showed Ck34βE12+/AMACR-; so the diagnosis remained as BPH. But 5 cases showed Ck34βE12-/AMACR+ and the diagnosis changed to prostatic carcinoma; this change was statistically significant ($P=0.04$) (Table 2).

Suspicious cases: in five cases of BPH, the diagnosis after immunohistochemical staining changed from benign to malignant; 4 of these cases were intensely stained with AMACR and one case with intermediate staining for this marker, while they were stained negatively with Ck34βE12.

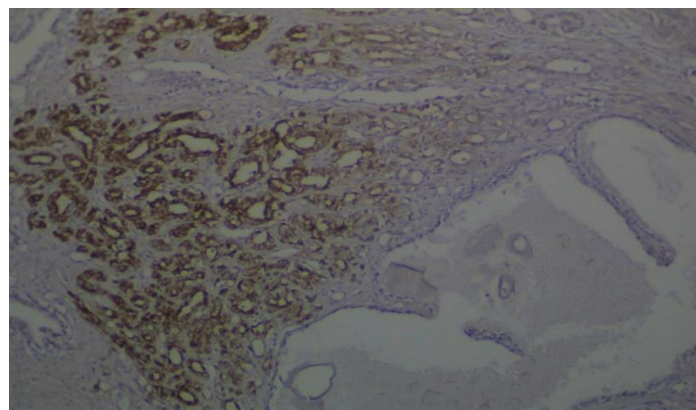


Fig. 2. Photomicrograph showing suspicious area for prostatic carcinoma in a background of benign prostatic hyperplasia (BPH). This area showed strongly positive expression with α-Methylacyl-coenzyme A racemase (AMACR) in the left side while the surrounding benign glands on the right showing negative staining (IHC; AMACR; X200).

Table 2. The diagnosis of suspicious foci before and after immunohistochemistry using Ck34βE12 and AMACR.

Diagnosis of suspicious foci before immunohistochemical staining	Diagnosis after immunohistochemical staining with
BPH 50	BPH (Benign) 65 Ck34βE12+ve and AMACR-ve.
BPH with suspicious foci of malignancy 20	0
Prostatic carcinoma 20	Malignant 25 Ck34βE12 -ve and AMACR +ve.

AMACR: α -Methylacyl-coenzyme A racemase

BPH: benign prostatic hyperplasia.

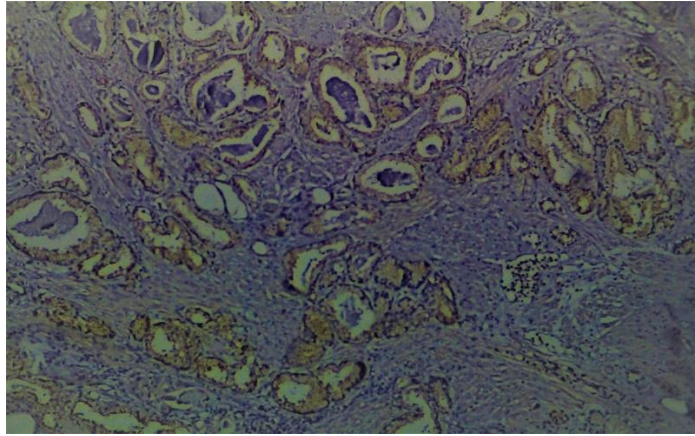


Fig. 3. Photomicrograph showing cytoplasmic staining of malignant prostatic glands in moderate expression with α -Methylacyl-coenzyme A racemase (IHC; AMACR)(X200)

Discussion

Prostatic carcinoma is regarded as the commonest cause of malignancy and the second cause of death in males in Western countries (1). But this type of cancer is relatively uncommon in Iraq and is ranked the sixth among males (4). Screening of PSA significantly increases the number of small needle biopsies that contain challenging morphology such as atypical glands and small foci that suggest the diagnosis of carcinoma (11). In routine work, prostatic biopsies contain many histological mimickers for prostatic carcinoma like atrophy, adenosis, basal cell hyperplasia, post atrophic hyperplasia, nephrogenic adenoma, radiation atypia, Cowper's glands, and seminal vesicles. Prostatic biopsies occasionally contain atypical foci of proliferation that reveal some but not all the features of malignancy. These foci have many terms like atypical foci; suspicious or ASAP show insufficient architectural and cytological atypia to make definite diagnosis of malignancy (20).

Regarding Ck34βE12, most previous studies showed presence of this marker in the basal layer of benign gland as continuous cytoplasmic circumferential pattern of staining and lack or discontinuous weak staining in malignant cases. In our study, Ck34βE12 highlighted basal cells in 92.9% of cases of BPH, 72.9% of which showed intense cytoplasmic staining; but only one case (4%) showed weak discontinuous staining for this marker. This was close to the results of other studies conducted by Deepika *et al.*, Shah *et al.*, Lakhtakia *et al.*, and Kotakidou *et al.* (21,22,23,24).

Negative immunohistochemical staining seen in 7.1% of BPH cases can possibly be explained by the fact that CK markers are sensitive to formalin and loss of immunoreactivity can occur in prolonged fixation in formalin; so the interpretation of negative staining should be considered cautiously.

The explanation for weak discontinuous expression of this marker in only one malignant case is that early invasive carcinoma may possibly retain basal cell layer or due to outpouching of some glands from HGPIN or flat PIN (11).

Regarding AMACR immunohistochemical staining, AMACR is found in premalignant high grade prostatic intraepithelial neoplasia (HGPIN) lesions and prostatic carcinoma cases as compared to benign ones (25,26,27).

Overexpression of AMACR is considered as an early change in prostatic carcinogenesis and it is regarded as a marker for malignant transformation (16).

The results of our study demonstrated that most of prostatic carcinoma cases (84%) were positively stained intensely, while only 4.3% of BPH cases showed low grade staining. So, there is a significant difference ($P=0.0001$); this was in agreement with the study of Rashed *et al.* (28).

The presence of AMACR in BPH cases found in our study has already been reported in some previous studies like (26,27), which reported 4-21% of BPH cases as positive.

Although AMACR is an important immunohistochemical diagnostic marker for prostatic carcinoma, it has many limitations. So, it is important to use AMACR in combination with appropriate morphological changes and basal cell marker like Ck34βE12 (21).

Regarding benign cases that show suspicious foci (ASAP), our results showed that the diagnosis changed in 5 cases (25%) from benign to malignant after using these 2 immunohistochemical markers; this change was statistically significant ($P=0.04$). This finding suggests that combination of AMACR and Ck34βE12 can increase confidence level for establishing definite diagnosis in cases with suspicious foci in which the morphological features are equivocal.

Conclusion

Immunohistochemical staining with the AMACR and Ck34βE12 could improve the diagnostic

performance and also increase the confidence level for establishing definite diagnosis in cases with suspicious foci, in which the morphological features are equivocal. This could help to avoid misdiagnosis or overdiagnosis of prostatic carcinoma, and would eventually improve the management of patients, and subsequently the prognosis.

Acknowledgements

The authors would like to thank Mustansiriyah University (www.uomustansiriyah.edu.iq) Baghdad - Iraq for its general support in the present work.

Conflict of Interest

The authors declared that there is no conflict of interest regarding the publication of this article.

References

- <https://www.cancer.net/cancer-types/prostate-cancer/statistics> 2019
- Haas GP, Delongchamps N, Brawley OW, Wang CY, de la Roza G. The worldwide epidemiology of prostate cancer: perspectives from autopsy studies. *Can J Urol*. 2008 Feb;15(1):3866.
- Iraq Ministry Department of vital statistic 2008 report.
- Annual report of Iraqi cancer registry 2015
- Rezakhaniha B, Arian Pour N, Siroosbakhat S. Effect of Cystoscopy on Prostate-Specific Antigen, New Words about Old Subject. *Iran J of Cancer Prevent*.2010;3(4):190-195.
- Sirousbakht S, Rezakhaniha B. Effect of Colonoscopy on Prostate-Specific Antigen; New Words about an Old Subject, *Int J Cancer Manag*. 2018 ; 11(7):e68919. [[DOI:10.5812/ijcm.68919](https://doi.org/10.5812/ijcm.68919)]
- Epstein JI, Herawi M. Prostate needle biopsies containing prostatic intraepithelial neoplasia or atypical foci suspicious for carcinoma: implications for patient care. *J Urol*. 2006 Mar;175(3):820-34. [[DOI:10.1016/S0022-5347\(05\)00337-X](https://doi.org/10.1016/S0022-5347(05)00337-X)]
- Engelman MD, Mundim FG, Grande RM, Carvalho LR, Ridolfi FM. Immunohistochemistry contribution to the diagnosis of prostate cancer. *J Bras Patol Med Lab*. 2012 Aug;48(4):273-80. [[DOI:10.1590/S1676-24442012000400008](https://doi.org/10.1590/S1676-24442012000400008)]
- Brustmann H. p40 as a basal cell marker in the diagnosis of prostate glandular proliferations: a comparative immunohistochemical study with 34betaE12. *Pathol Res Int*. 2015;2015. [[DOI:10.1155/2015/897927](https://doi.org/10.1155/2015/897927)] [[PMID](#)] [[PMCID](#)]
- Jiang Z, Li C, Fischer A, Dresser K, Woda BA. Using an AMACR (P504S)/34βE12/p63 cocktail for the detection of small focal prostate carcinoma in needle biopsy specimens. *Am J of Clin Pathol*. 2005 Feb 1;123(2):231-6. [[DOI:10.1309/1G1NK9D8GFNB792L](https://doi.org/10.1309/1G1NK9D8GFNB792L)] [[PMID](#)]
- Kumaresan K, Kakkar N, Verma A, Mandal AK, Singh SK, Joshi K. Diagnostic utility of α-methylacyl CoA racemase (P504S) & HMWCK in morphologically difficult prostate cancer. *Diag Pathol*. 2010 Dec;5(1):83. [[DOI:10.1186/1746-1596-5-83](https://doi.org/10.1186/1746-1596-5-83)] [[PMID](#)] [[PMCID](#)]
- Shah RB, Zhou M, LeBlanc M, Snyder M, Rubin MA. Comparison of the basal cell-specific markers, 34βE12 and p63, in the diagnosis of prostate cancer. *Am J Surg Pathol*. 2002 Sep 1;26(9):1161-8. [[DOI:10.1097/0000478-200209000-00006](https://doi.org/10.1097/0000478-200209000-00006)] [[PMID](#)]
- Luo J, Zha S, Gage WR, Dunn TA, Hicks JL, Bennett CJ, Ewing CM, Platz EA, Ferdinandusse S, Wanders RJ, Trent JM. α-Methylacyl-CoA racemase: a new molecular marker for prostate cancer. *Cancer Res*. 2002 Apr 15;62(8):2220-6.
- Varma M, Jasani B. Diagnostic utility of immunohistochemistry in morphologically difficult prostate cancer: review of current literature. *Histopathology*. 2005 Jul;47(1):1-6. [[DOI:10.1111/j.1365-2559.2005.02188.x](https://doi.org/10.1111/j.1365-2559.2005.02188.x)] [[PMID](#)]
- Jiang Z, Wu CL, Woda BA, Iczkowski KA, Chu PG, Tretiakova MS, Young RH, Weiss LM, Blute Jr RD, Brendler CB, Krausz T. Alpha-methylacyl-CoA racemase: a multi-institutional study of a new prostate cancer marker. *Histopathology*. 2004 Sep;45(3):218-25. [[DOI:10.1111/j.1365-2559.2004.01930.x](https://doi.org/10.1111/j.1365-2559.2004.01930.x)] [[PMID](#)]
- Ozgun T, Atik E, Hakverdi S, Yaldiz M. The expressions of AMACR and iNOS in prostate adenocarcinomas. *Pakistan journal of medical sciences*. 2013 Apr;29(2):610. [[DOI:10.12669/pjms.292.2813](https://doi.org/10.12669/pjms.292.2813)] [[PMID](#)] [[PMCID](#)]
- Wojno KJ, Epstein JI. The utility of basal cell-specific anti-cytokeratin antibody (34 beta E12) in the diagnosis of prostate cancer. A review of 228 cases. *Am J Surg Pathol*. 1995 Mar;19(3):251-60. [[DOI:10.1097/0000478-199503000-00002](https://doi.org/10.1097/0000478-199503000-00002)] [[PMID](#)]
- Amin MB, Tamboli P, Varma M, Srigley JR. Postatrophic hyperplasia of the prostate gland: a detailed analysis of its morphology in needle biopsy specimens. *Am J Surg Pathol*. 1999 Aug 1;23(8):925-31. [[DOI:10.1097/0000478-199908000-00010](https://doi.org/10.1097/0000478-199908000-00010)] [[PMID](#)]
- Wang W, Sun X, Epstein JI. Partial atrophy on prostate needle biopsy cores: a morphologic and immunohistochemical study. *Am J Surg Pathol*. 2008 Jun 1;32(6):851-7. [[DOI:10.1097/PAS.0b013e31815a0508](https://doi.org/10.1097/PAS.0b013e31815a0508)] [[PMID](#)]
- Srigley JR. Benign mimickers of prostatic adenocarcinoma. *Modern pathology*. 2004 Mar;17(3):328-48. [[DOI:10.1038/modpathol.3800055](https://doi.org/10.1038/modpathol.3800055)] [[PMID](#)]
- Jain D, Gupta S, Marwah N, Kalra R, Gupta V, Gill M, Jain N, Lal S, Sen R. Evaluation of role of alpha-methyl acyl-coenzyme A racemase/P504S and high molecular weight cytokeratin in diagnosing prostatic lesions. *J Cancer Res Therapeut*. 2017 Jan 1;13(1):21. [[DOI:10.4103/0973-1482.206239](https://doi.org/10.4103/0973-1482.206239)] [[PMID](#)]
- Shah RB, Zhou M, LeBlanc M, Snyder M, Rubin MA. Comparison of the basal cell-specific markers, 34βE12 and p63, in the diagnosis of prostate cancer. *Am J Surg Pathol*. 2002 Sep 1;26(9):1161-8. [[DOI:10.1097/0000478-200209000-00006](https://doi.org/10.1097/0000478-200209000-00006)] [[PMID](#)]
- Lakhtakia R, Bharadwaj R, Kumar VK, Mandal P, Nema SK. Immunophenotypic characterization of benign and malignant prostatic lesions. *Med J Armed Forces Ind*. 2007 Jul 1;63(3):243-8. [[DOI:10.1016/S0377-1237\(07\)80145-6](https://doi.org/10.1016/S0377-1237(07)80145-6)]

24. Kotakidou R, Lakis S, Papamitsou T, Mavridou M, Koutsou A, Baggeas P. Diagnostic utility of immunohistochemical marker 34βe12 (keratin 903) in prostate pathology. *Aristotle University Medical Journal*. 2007;34(3):31-6.
25. Kaić G, Tomasović-Lončarić Č. α-Methylacyl-CoA racemase (AMACR) in fine-needle aspiration specimens of prostate lesions. *Diagnostic Cytopathology*. 2009 Nov;37(11):803-8. [DOI:10.1002/dc.21103] [PMID]
26. Jiang Z, Woda BA, Rock KL, Xu Y, Savas L, Khan A, Pihan G, Cai F, Babcook JS, Rathanaswami P, Reed SG. P504S: a new molecular marker for the detection of prostate carcinoma. *Am J Surg Pathol*. 2001 Nov 1;25(11):1397-404. [DOI:10.1097/00000478-200111000-00007] [PMID]
27. Luo J, Zha S, Gage WR, Dunn TA, Hicks JL, Bennett CJ, Ewing CM, Platz EA, Ferdinandusse S, Wanders RJ, Trent JM. α-Methylacyl-CoA racemase: a new molecular marker for prostate cancer. *Cancer Res*. 2002 Apr 15;62(8):2220-6.
28. Rashed HE, Kateb I. Evaluation of minimal prostate cancer in needle biopsy specimens using AMACR (P504S), P63 and KI67. *Marsland Press*. 2012;9:12-21.

How to Cite This Article

Hasan, I., Gaidan, H., Al-kaabi, M. Diagnostic Value of Cytokeratin 34 beta E12 (Ck34βE12) and α-Methylacyl-CoA racemase (AMACR) Immunohistochemical Expression in Prostatic Lesions. *Iranian Journal of Pathology*, 2020; 15(3): 232-238. doi: 10.30699/ijp.2020.113544.2229