

# Saccular pseudoaneurysm of the left common carotid artery in an adolescent: Management with a covered stent

Laurent Van Camp, Werner Budts<sup>1</sup>, Geert Maleux

Departments of Radiology and <sup>1</sup>Congenital Cardiology, University Hospitals Leuven, Leuven, Belgium

## ABSTRACT

**An adolescent patient with a previous history of surgical repair for interrupted aortic arch type B presented with an asymptomatic, saccular pseudoaneurysm of the proximal, common left carotid artery, identified on a follow-up magnetic resonance angiography of the thoracic large vessels. The pseudoaneurysm was successfully excluded with a covered stent. Clinical and radiological follow-up after 2 years was uneventful.**

**Keywords:** Adolescent, aneurysm, common carotid artery, covered stent

## INTRODUCTION

Aneurysm of the common carotid artery is a rare entity in the adolescent population.<sup>[1]</sup> The etiology can be congenital, traumatic, inflammatory, or mycotic. The common, internal, or external carotid artery can be involved, and treatment consists of surgical resection with or without vascular reconstruction. Exclusion of the aneurysm with coils or plugs and associated occlusion of the primary vessel can be performed if neurologically tolerated. Recently, a few case reports<sup>[2,3]</sup> and small series<sup>[4]</sup> in the adult population describe the successful endovascular exclusion of mycotic carotid artery aneurysms using a covered stent.<sup>[5]</sup>

## CASE REPORT

An 18-year-old male was followed up in the Department of Congenital Cardiology with an elaborate cardiac history, including a prenatally diagnosed interrupted aortic arch type B, associated with hypoplasia of the ascending aortic arch, atrial septal defect, and perimembraneous ventricular septal defect. The aortic interruption was located between the left common carotid artery and the left subclavian artery and was surgically repaired during the neonatal period; the aortic arch was anastomosed

by the interposition of an 8 mm Gore-Tex graft at the origin of the left common carotid artery. In addition, at the age of 16 years, a pericardial patch was sown into the ascending aorta to facilitate growth and to prevent another episode of left-sided hemiparesis; the patch extended into the proximal left common carotid artery. Follow-up magnetic resonance angiography of the heart and thoracic large vessels 2 years later identified a saccular pseudoaneurysm of the proximal, left common carotid artery with a diameter of 17 mm [Figure 1], associated with recoarctation at the repair site. Owing to the rapid growth of the pseudoaneurysm over last 2 years, a decision was made to exclude the pseudoaneurysm by an endovascular approach. The patient was uploaded with aspirin 80 mg and clopidogrel 75 mg daily. Under general anesthesia, an 8 French (F) sheath was introduced in the right common femoral artery. The left common carotid artery was catheterized, and after intravenous injection of 5000 IU of heparin, a 7 F guiding catheter (Softip XF, Boston Scientific, Natick, MA, USA) was navigated into the left common carotid artery over a stiff guidewire (Amplatz 0.035 inch, Cook Medical, Bjaeverskov, Denmark) [Figure 2a]. No cerebroprotection device was used. An

This is an open access article distributed under the terms of the Creative Commons Attribution-NonCommercial-ShareAlike 3.0 License, which allows others to remix, tweak, and build upon the work non-commercially, as long as the author is credited and the new creations are licensed under the identical terms.

**For reprints contact:** reprints@medknow.com

**How to cite this article:** Van Camp L, Budts W, Maleux G. Saccular pseudoaneurysm of the left common carotid artery in an adolescent: Management with a covered stent. *Ann Pediatr Card* 2018;11:83-5.

Access this article online	
<p>Quick Response Code:</p> 	<p>Website:</p> <p><a href="http://www.annalspc.com">www.annalspc.com</a></p>
	<p>DOI:</p> <p>10.4103/apc.APC_56_17</p>

**Address for correspondence:** Prof. Geert Maleux, Department of Radiology, University Hospitals Leuven, Herestraat 49, 3000 Leuven, Belgium.

E-mail: geert.maleux@uzleuven.be

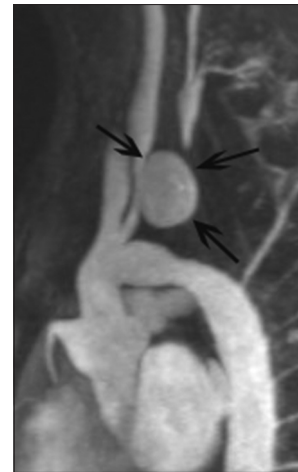expanded-polytetrafluoroethylene (e-PTFE)-covered balloon expandable stent (Atrium, Maquet, Rastatt, Germany) with a length of 38 mm was dilated up to 8 mm diameter [Figure 2b]. Completion carotid angiography revealed a fully patent stent completely excluding the (pseudo) aneurysm [Figure 2c]. Finally, an e-PTFE-covered balloon-expandable stent (Covered CP Stent, NuMED Inc., NY, USA) was placed in the aortic recoarctation and postdilated with a 14 mm diameter high-pressure angioplasty balloon catheter (Atlas, BARD Inc., Tempe, AZ, USA) resulting in a reduction of the systolic peak-to-peak pressure gradient from 23 to 7 mmHg over the stented segment. A closure device (Angio-Seal 8 F, St. Jude Medical, Minnetonka, MN, USA) was used to close the puncture site. The immediate postinterventional period was uneventful; in particular, no neurological event occurred. The patient was discharged the day after the procedure and was treated with aspirin 80 mg and clopidogrel 75 mg daily for 3 months, followed by aspirin monotherapy.

Follow-up computed tomography angiography 6 months after the intervention showed a correctly positioned covered stent and complete exclusion of the (pseudo) aneurysm [Figure 3].

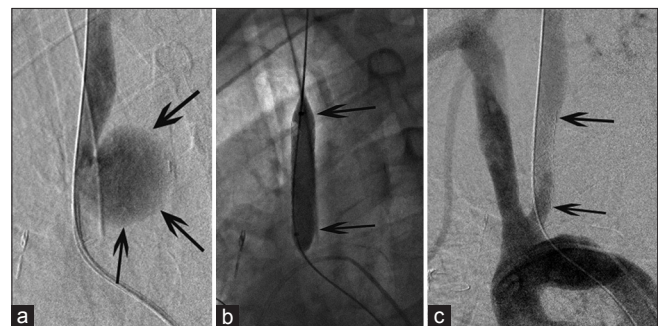
## DISCUSSION

Extracranial aneurysm of the carotid artery is a rare finding in children and adolescents.<sup>[1]</sup> The etiology can be congenital or the result of inflammatory and mycotic conditions.<sup>[3,4]</sup> Rarely, it might be traumatic in origin and should than be considered as pseudoaneurysm.<sup>[6]</sup> In the presented case, a congenital origin could be excluded as the lesion was identified at the age of 18 years and previous radiological examinations were negative for aneurysmal degeneration; inflammatory or mycotic etiology was also very unlikely as the patient did not present with inflammatory or infectious parameters based on clinical and laboratory evaluation. It seems most likely that the patient presented with a pseudoaneurysm related to the previous aortic surgery; the time interval between pericardial patch surgery and aneurysm detection was 2 years. Other factor in favor of a sequela of previous surgery is the location of the (pseudo) aneurysm. The proximal left common carotid artery is located very close to the surgical aortic anastomosis with inserted pericardial patch between the ostium of the left common carotid and left subclavian artery. Finally, the radiological presentation of an asymmetric, saccular aneurysm is typical for a posttraumatic (iatrogenic) vascular lesion.

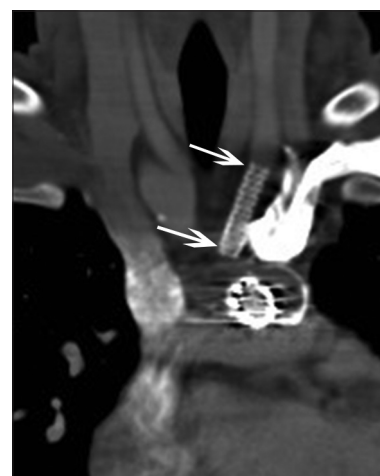
The standard treatment of extracranial carotid aneurysms and pseudoaneurysms is surgical resection, which is associated with good long-term patency rates of the treated vessels.<sup>[1]</sup> However, to avoid thoracotomy,



**Figure 1:** Contrast-enhanced magnetic resonance angiography showing a large, saccular (pseudo) aneurysm (arrows) of the proximal, left common carotid artery



**Figure 2:** (a) Selective left, common carotid angiography through the guiding catheter confirms the saccular (pseudo) aneurysm (arrows). (b) Expansion of the expanded-polytetrafluoroethylene-covered stent (arrows) in the proximal, left common carotid artery. (c) Flush aortography through pigtail catheter in the aortic arch demonstrates a fully patent-covered stent (arrows) completely excluding the (pseudo) aneurysm



**Figure 3:** Follow-up contrast-enhanced computed tomography showing the patent-covered stent (white arrows); the (pseudo) aneurysm is not visible anymore

we performed a percutaneous, transcatheter approach with use of a covered stent. Catheter-directed, successful

exclusion with a covered stent of extracranial carotid artery aneurysms has been described in mycotic,<sup>[3,4]</sup> traumatic,<sup>[1]</sup> and postdissection<sup>[7]</sup> cases in the adult population. In line with other reports on the use of stents in the carotid circulation,<sup>[8]</sup> the patient was up-loaded with dual antiplatelet therapy to avoid posttreatment in stent thrombosis.

## CONCLUSION

We presented a rare case of a pseudoaneurysm of the proximal left common carotid artery in an adolescent, potentially developed after surgical insertion of a pericardial patch. The pseudoaneurysm was successfully excluded with percutaneous insertion of a covered stent. Follow-up was uneventful.

### Financial support and sponsorship

Nil.

### Conflicts of interest

There are no conflicts of interest.

## REFERENCES

1. Pourhassan S, Grotemeyer D, Fokou M, Heinen W, Balzer K, Ramp U, *et al.* Extracranial carotid arteries aneurysms in children: Single-center experiences in 4 patients and review of the literature. *J Pediatr Surg* 2007;42:1961-8.

Van Camp, *et al.*: Covered stent in the left common carotid artery

2. Koenigsberg RA, Urrutia V, McCormick D, Alani F, Ryu D, Nair B, *et al.* Endovascular treatment of a left carotid artery “Bowtie” pseudoaneurysm with a covered Wallgraft stent. *J Neuroimaging* 2003;13:362-6.
3. Gralla J, Brekenfeld C, Schmidli J, Caversaccio M, Do DD, Schroth G, *et al.* Internal carotid artery aneurysm with life-threatening hemorrhages in a pediatric patient: Endovascular treatment options. *J Endovasc Ther* 2004;11:734-8.
4. Shah H, Gemmete JJ, Chaudhary N, Pandey AS, Ansari SA. Acute life-threatening hemorrhage in patients with head and neck cancer presenting with carotid blowout syndrome: Follow-up results after initial hemostasis with covered-stent placement. *AJNR Am J Neuroradiol* 2011;32:743-7.
5. Li Z, Chang G, Yao C, Guo L, Liu Y, Wang M, *et al.* Endovascular stenting of extracranial carotid artery aneurysm: A systematic review. *Eur J Vasc Endovasc Surg* 2011;42:419-26.
6. Szeto WY, Fairman RM, Acker MA, Skelly CL, Augoustides JG, McGarvey M, *et al.* Emergency endovascular deployment of stent graft in the ascending aorta for contained rupture of innominate artery pseudoaneurysm in a pediatric patient. *Ann Thorac Surg* 2006;81:1872-5.
7. Heye S, Maleux G, Vandenberghe R, Wilms G. Symptomatic internal carotid artery dissecting pseudoaneurysm: Endovascular treatment by stent-graft. *Cardiovasc Intervent Radiol* 2005;28:499-501.
8. De Rango P. Dual antiplatelet therapy after carotid stenting: Lessons from ‘big brother’. *Eur J Vasc Endovasc Surg* 2015;49:621-2.