

# Superior versus anteroinferior plating of displaced midshaft clavicular fracture in patients older than 60 years

Minpeng Lu<sup>1</sup>, Hao Qiu<sup>2</sup>, Xin Zhou<sup>2</sup>,  
Cody S Lee<sup>3</sup>, Dianming Jiang<sup>4</sup>, Jing Dong<sup>1</sup>  
and Zhengxue Quan<sup>4</sup>

## Abstract

**Objective:** To compare superior versus anteroinferior plating for displaced midshaft clavicular fracture in elderly patients.

**Methods:** We retrospectively compared the functional result, parameters, and perioperative course of displaced midshaft clavicular fracture in 42 patients >60 years treated with a 3.5-mm reconstruction plate placed superiorly versus anteroinferiorly.

**Results:** Groups were similar with regard to age, sex, bone mineral density, cause of injury, and fracture pattern. The superiorly-plated group had a significantly longer operation time and greater blood loss, complications and implant prominence. Constant scores were significantly higher for the anteroinferiorly-plated group than the superiorly-plated group at 3 months postoperatively; however, there was no difference between groups at final follow-up.

**Conclusion:** While both anteroinferior and superior plate placement are safe and effective for displaced midclavicular fractures in patients >60 years, the anteroinferior approach involves less operation time, blood loss, complications and implant prominence, and enables faster return to normal activities.

## Keywords

Clavicular fractures, reconstruction plate, superior/anteroinferior plating

Date received: 29 April 2016; accepted: 11 January 2017

<sup>1</sup>Department of Orthopaedic Surgery, People's Hospital of Chongqing Banan District, Chongqing, China

<sup>2</sup>Department of Orthopaedic Surgery, Yongchuan Hospital of Chongqing Medical University, Chongqing, China

<sup>3</sup>Pritzker School of Medicine, University of Chicago, Chicago, IL, USA

<sup>4</sup>Department of Orthopaedic Surgery, The First Affiliated Hospital of Chongqing Medical University, Chongqing, China

### Corresponding author:

Jing Dong, Department of Orthopaedic Surgery, People's Hospital of Chongqing Banan District, Chongqing, China.  
Email: [tokyo2024@126.com](mailto:tokyo2024@126.com)



## Introduction

Among the most prevalent adult fractures are clavicular fractures, 80% of which are midshaft fractures.<sup>1,2</sup> Most midshaft clavicular fractures occur in men younger than 25 years old; however, these fractures also commonly occur in patients older than 60 years.<sup>3</sup> As the aging population continues to grow, midshaft clavicular fractures in the elderly population have gained significant attention. A variety of methods have been described for treating midshaft clavicular fractures in older patients, such as nonsurgical treatment, Knowles Pin and plate fixation.<sup>4</sup> One advantage of using plate fixation for treatment of clavicular fractures is the ability to obtain firm anatomical reduction, rendering it a safe and reliable surgical approach.<sup>5</sup> Traditionally, the plate is placed superiorly for displaced midshaft clavicular fractures because of its demonstrated biomechanical advantage.<sup>6</sup> However, in recent years, anteroinferior plating of midshaft clavicular fractures has been supported by few complications and early recovery of shoulder function, highlighting its potential advantages over traditional treatment.<sup>7</sup> For elderly patients with midshaft clavicular fracture, operative treatment becomes more difficult because of the increased risks of fixation failure and wound complication. To our knowledge, there have been no reports comparing the results of superior and anteroinferior approaches for treatment of displaced midshaft clavicular fractures in patients older than 60 years using a 3.5 mm reconstruction plate.

The purpose of this study was to compare the clinical results of treatment using a 3.5 mm reconstruction plate placed superiorly versus anteroinferiorly for displaced midshaft clavicular fracture in patients older than 60 years.

## Patients and methods

### Patients

This retrospective study was approved by the Institutional Review Board of First

Affiliated Hospital of Chongqing Medical University, and all aspects of the study comply with the Declaration of Helsinki. As this was a retrospective study, the data were analysed anonymously and patient care was not affected by the study. Patients were selected from inpatient data from the time period between January 2009 and December 2011 at our hospital according to the following criteria: 1) the patient sustained a transverse, short oblique, or simple comminuted fresh displaced midshaft clavicular fracture; 2) the fracture was closed and unilateral; 3) the patient was 60 years or older; 4) the patient had no associated injuries; 5) the patient was treated surgically using open reduction and internal fixation with a 3.5 mm reconstruction plate; 6) and the patient underwent regular follow-up for at least 18 months postoperatively. The patients were divided into two groups according to the approach used to place the reconstruction plate – superior versus anteroinferior. The choice of fixation method was at the discretion of the surgeon and was not randomized.

### Operative technique

After brachial plexus anaesthesia, patients were placed in the supine position. Using the fracture site as the centre point, an incision to expose the fracture site was made parallel to the superior or inferior border of the clavicle, depending on the placement position of the reconstruction plate. The fracture was reduced and fixed with the 3.5 mm reconstruction plate. Each reconstruction plate was pre-bent to the shape of the clavicle. For comminuted fractures, temporary stabilization was achieved using a 0.8-mm wire before permanent plate fixation. To obtain maximum fixation strength, at least three screws were used on each side of the fracture site. In cases of comminuted fracture, autologous bone grafting using iliac crest was implemented to prevent nonunion.

The use of autologous bone grafting for the treatment of comminuted fracture was at the discretion of the surgeon in charge, and was based on previous experience and outcomes related to the probability of fracture non-union in elderly patients.

### *Postoperative care and outcome evaluation*

Patients with bone mineral density (BMD) loss ( $T < -1.0$ ) were given conventional anti-osteoporosis treatment (including calcium supplementation, vitamin D, and alendronate). The shoulder was protected with an arm sling for 4 to 6 weeks postoperatively. After proper evaluation, the sling was removed and active range of motion exercises were started. Radiographs were routinely taken of all patients at 3, 6, 12, and 18 months postoperatively. Radiographic union was defined as the absence of a fracture gap on radiography, and clinical union was defined as the absence of pain at the fracture site during shoulder exercise.

Data regarding operative measurements (blood loss, operative time), postoperative measurements (arm sling protection time, time to union) and patient performance (length of hospital stay, time to return to pre-injury activity level, Constant Shoulder scores<sup>8</sup>) of the two groups were recorded.

### *Statistical analysis*

The data are presented as  $n$  (%) or mean  $\pm$  SD, and the statistical analysis was performed using SPSS 17.0 for Windows (SPSS Inc., Chicago, IL, USA). The data were analysed by  $\chi^2$  test, Student's  $t$  test, or Fisher's exact test, depending on the distribution. The level of significance was set at  $P \leq 0.05$ .

## **Results**

On the basis of the previously described inclusion criteria, the records of 42 patients

were included in this study. There were 25 female and 17 male patients ranging in age from 60 to 75 years; 22 patients were in the superiorly-plated group and 20 in the anteroinferiorly-plated group. Table 1 presents a summary of the demographic characteristics of the patients in each group. Both groups were similar in age, sex distribution, BMD, cause of injury, fracture pattern, and autologous bone grafting rate (Table 1). The two groups were also similar in length of hospital stay (Table 2).

Compared with the anteroinferiorly-plated group, the superiorly-plated group had a significantly longer mean operative time ( $P=0.016$ ), and greater mean blood loss ( $P=0.002$ ; Table 2). Clinically, the mean Constant score of the superiorly-plated group was significantly lower than that of the anteroinferiorly-plated group at the 3-month postoperative follow-up ( $P=0.038$ ; Table 2); however, the mean Constant scores were similar at final follow-up (Table 2). There was no significant difference between groups regarding mean follow-up period and mean time to fracture union (Table 2). Implant prominence was reported by a significantly greater proportion of patients in the superiorly-plated group than in the anteroinferiorly-plated group (Table 2). A greater proportion of the superiorly-plated group had returned to previous activity levels at 3 months postoperatively than the anteroinferiorly-plated group ( $P=0.029$ ; Table 2); however, the proportion of patients that had returned to previous activity level after 18 months was similar in both groups. In the superiorly-plated group, complications consisted of shoulder pain in 13.6%, motion limitation in 13.6%, fracture malunion in 9.1%, and screw loosening in 4.5% (Table 2). In the anteroinferiorly-plated group, shoulder pain was observed in 5.0%, and motion limitation was noted in 10.0% (Table 2); however, plate failure and screw loosening were not observed. There were no cases of wound

**Table 1.** Demographic data of patients older than 60 years with midshaft clavicular fracture treated with a 3.5-mm reconstruction plate placed superiorly or anteroinferiorly.

Parameter	Superior (n = 22)	Anteroinferior (n = 20)	P-value
Age (yr)	64.1 ± 3.2	65.7 ± 4.1	0.176
Male/Female	9:13	8:12	0.952
Bone mineral density (T score)			0.634
T ≥ -1.0	6	5	
-2.5 < T < -1.0	8	10	
T ≤ -2.5	8	5	
Cause (%)			0.939
Slip down	10 (45)	10 (50)	
Fall down	2 (9)	3 (15)	
Traffic accidents	8 (36)	5 (25)	
sports injury	1 (4.5)	1 (5)	
Miscellaneous	1 (4.5)	1 (5)	
Concomitant disease			
Diabetes	4	3	1.000
Hypertension	6	5	1.000
Other cardiac	2	3	0.656
Respiratory	5	6	0.730
Renal diseases	1	0	1.000
Liver diseases	1	2	0.598
Heavy smoker	4	5	1.000
Fracture Patterns			0.826
Transverse fractures	4	3	
Oblique & spiral fractures	10	11	
Comminuted fractures	8	6	
Interval from injury to operation (d)	7.64 ± 2.50	7.25 ± 1.74	0.576
Autogenous bone graft	8	6	0.403

infection, neurovascular damage, or refracture in either group (Table 2).

All fractures demonstrated healing, both clinically and radiographically (Figures 1, 2).

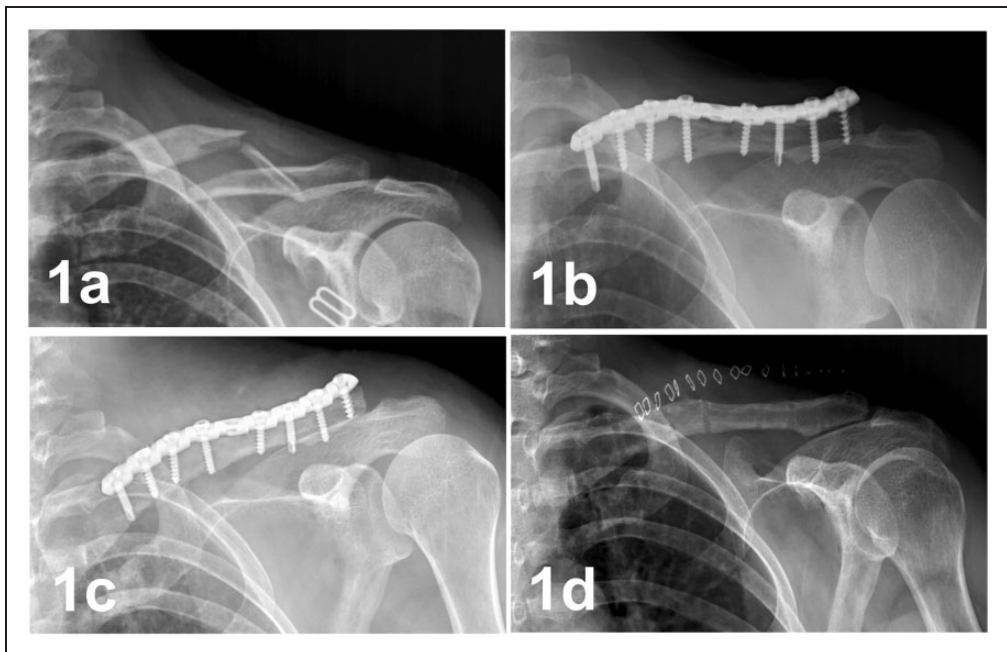
## Discussion

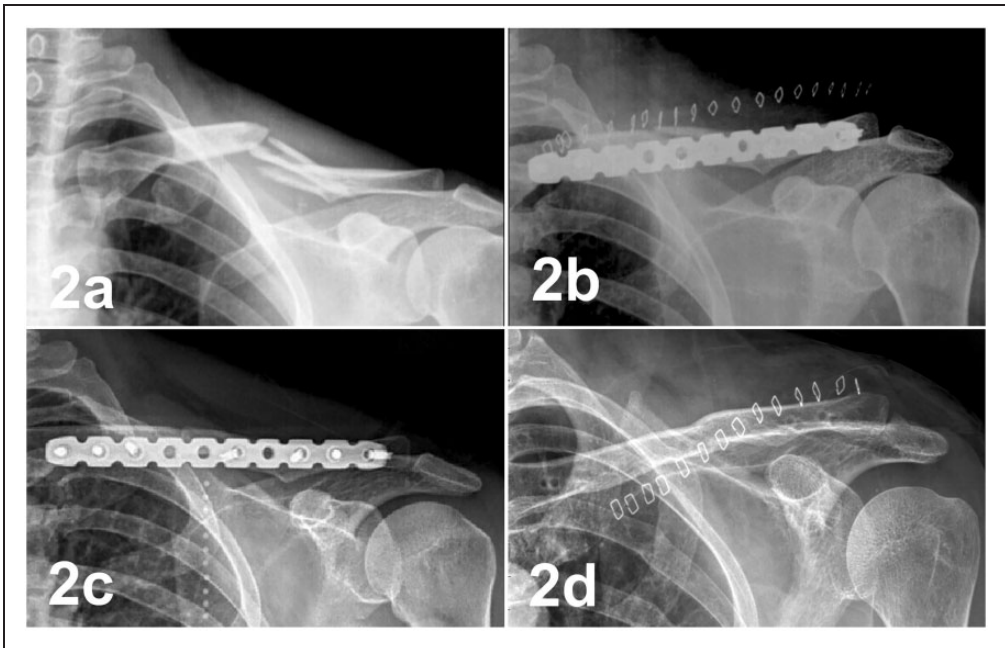
It is common for clavicular fractures in elderly patients to be treated conservatively and nonoperatively. However, many recent studies have found that the nonunion rate of displaced midshaft clavicular fractures in conservatively-treated elderly patients is significantly large.<sup>9,10</sup> A recent meta-analysis revealed that in the treatment of midshaft clavicular fracture, surgery with fixation

plates was associated with lower incidences of nonunion and fewer complications compared with nonoperative treatment.<sup>11-13</sup> Among the surgical methods used by orthopedic surgeons for the treatment of midshaft clavicular fractures, plate fixation continues to be the most popular because of its safe and reliable outcomes.<sup>5,14,15</sup> However, the optimal surgical approach for plating of midshaft clavicular fracture remains controversial. In elderly patients, the debate regarding which approach to use is complicated by the added risk of fixation failure due to osteopenic bone. In the current study, we compared the clinical results of midshaft clavicular fracture in patients older than

**Table 2.** Clinical results of patients older than 60 years with midshaft clavicular fracture treated with a 3.5-mm reconstruction plate placed superiorly or anteroinferiorly.

Parameter	Superior (n = 22)	Anteroinferior (n = 20)	P-value
Hospital stay (d)	16.18 ± 5.65	15.70 ± 4.86	0.770
Blood loss (mL)	105.91 ± 30.96	78.00 ± 23.53	0.002
Operative time (min)	83.73 ± 20.65	67.55 ± 21.04	0.016
Time to union (wk)	21.18 ± 7.24	23.60 ± 7.47	0.293
Constant scores at 3-months postoperative follow-up	69.95 ± 11.15	77.55 ± 11.75	0.038
Constant scores at the final follow-up	90.32 ± 12.88	94.50 ± 11.25	0.271
Average follow-up (months)	26.32 ± 7.02	25.15 ± 5.35	0.551
Implant prominence	12 (54.54%)	4 (20.00%)	0.021
Implant removal	7	3	0.360
Return to previous activity in 3 months	8 (36.36%)	14 (70.00%)	0.029
Return to previous activity in 18 months	18 (81.82%)	18 (90.00%)	0.753
Complication			0.033
Pain	3	1	
Motion limitation	3	2	
Metal loosening	1	0	
malunion	2	0	
Weather sensitivity	1	0	

**Figure 1.** Example of a case. A 63-year-old female with left midshaft clavicular fracture was treated with a 3.5-mm reconstruction plate placed superiorly. **a** Preoperative radiograph. **b** Radiograph taken in the immediately postoperative period showing good fracture reduction. **c** Radiograph taken at 15 months postoperatively showing bone union. **d** Radiograph taken after plate removal at 15 months postoperatively.



**Figure 2.** Example of a case. A 62-year-old female with left midshaft clavicular fracture was treated with a 3.5-mm reconstruction plate placed anteroinferiorly. **a** Preoperative x-ray. **b** Radiograph taken in the immediately postoperative period showing good fracture reduction. **c** Radiograph taken at 18 months postoperatively showing bone union. **d** Radiograph taken after plate removal at 19 months postoperatively.

60 years treated surgically with a 3.5 mm reconstruction plate placed superiorly or anteroinferiorly.

Our study demonstrated the safety of both the anteroinferior and superior approaches for treating displaced midshaft clavicular fractures in patients older than 60 years using a fixation plate. While both approaches are seen as safe and clinically successful, the advantages of the anteroinferior plating method over the superior approach included shorter operative time, less blood loss, and fewer associated complications. The Constant scores were significantly higher in the anteroinferiorly-plated group than in the superiorly-plated group at 3 months postoperatively; however, there was no significant difference between groups regarding the Constant scores at final follow-up. Additionally, a significantly greater proportion of the anteroinferiorly-plated group

was able to resume previous activities of daily living within 3 months postoperatively compared with the superiorly-plated group.

In elderly fracture patients, the most common complications are nonunion and fixation failure. Pai et al.<sup>16</sup> reported on midclavicular fractures in 35 patients with an average age of 66.3 years treated with a nonlocking plate (superiorly plated) and found there was one case of nonunion (2.9%) and four cases of plate loosening (11.4%). Lee et al.<sup>9</sup> also reported on midclavicular fractures in 30 patients with a mean age of 56.7 years treated with a nonlocking plate (superiorly plated) and found there was one case of nonunion (3.3%) and two cases of implant failure (6.7%). The major complication in the study by Lee et al.<sup>9</sup> was plate and screw loosening due to poor bone quality. In our study, nonunion was not found in either group.

However, there were two cases of malunion (9.1%), one case of implant failure (4.5%), and one case of screw loosening (4.5%) in the superiorly-plated group; this case of screw loosening could have been due to BMD loss ( $T < -1.0$ ) preoperatively, leading to poor bone quality, and/or due to noncompliance with postoperative orders. In contrast, there was no malunion or implant failure in the anteroinferiorly-plated group. These findings parallel the reports of recent biomechanical studies and highlight the advantages of the anteroinferior approach to treatment. Partal et al.<sup>17</sup> found that anteroinferior placement of the reconstruction plate provides a more stable construct in bending rigidity compared with plates placed superiorly. Favre et al.<sup>18</sup> reported that anteroinferior placement of the reconstruction plate induced deformation modes similar to the intact clavicle, while superior placement of the reconstruction plate induced deformation modes that were non-physiological, indicating that anteroinferior placement was less likely to fail during normal physiological loading. We believe that anteroinferior placement of the reconstruction plate can provide more rigid fixation in osteopenic bone, which will minimize fixation failure.

The incidence of fixation failure and rate of nonunion, whether anteroinferiorly- or superiorly-plated, was lower in our study than in previous studies.<sup>9,16</sup> This could potentially be explained by our relatively conservative rehabilitation program. The optimal duration of postoperative immobilization for clavicular fracture is controversial, with the literature recommending postoperative immobilization for 2 to 6 weeks.<sup>19,20</sup> Our institution chose to implement an immobilization period of 4 to 6 weeks, compared with previous studies that implemented immobilization periods of 1 to 2 weeks<sup>16</sup> and 2 to 4 weeks<sup>9</sup>. We believe that the incidence of fixation failure was lower in our study due to the longer immobilization

time. In addition to our rehabilitation protocol, we consider that our lower rate of fixation failure could be due to conventional anti-osteoporosis treatment given to patients with BMD loss. While BMD was not measured at final follow-up, it is assumed that the patients' bone quality improved after anti-osteoporosis treatment, which could have led to a decrease in the incidence of fixation failure. Finally, in cases of comminuted fractures, we used autologous bone grafting from the iliac to minimize the risk of nonunion.

Our results indicate that the anteroinferior plating method was accompanied by fewer cases of implant prominence compared with the superior plating approach. Similarly, Formaini et al.<sup>21</sup> compared anteroinferior plating with superior plating of displaced midshaft clavicular fractures and found that superior plating led to an increased rate of patient-reported implant prominence and prompted more requests for implant removal.

With regard to operative time, we found that the anteroinferiorly-plated group required less time than the superiorly-plated group. There are two possible explanations for this result. First, patients often assume the supine position and not the beach chair position in the perioperative period in China. In the supine position, the anteroinferior aspect of the clavicle is located in the centre of the surgical field, which is more convenient for surgery. Second, in the anteroinferiorly-plated group, the screws are safely directed posterosuperiorly, away from vulnerable infraclavicular structures, which reduces the surgeon's concerns regarding iatrogenic injury and saves time. Also, the anteroinferiorly-plated group had less operative blood loss than the superiorly-plated group. Understandably, less blood loss is associated with shorter operative time, and it is believed that shorter operative time and less operative blood loss reduce the overall risks of surgery and anaesthesia.

This study had some limitations. First of all, the number of cases is small, and the study was done at a single centre. Additionally, the study design was retrospective and not randomized. Finally, the BMD was not evaluated at final follow-up. Therefore, the curative effect for treatment of midshaft clavicular fractures in patients older than 60 years using a 3.5 mm reconstruction plate placed superiorly or anteroinferiorly should be tested in a large, prospective study in the future. Nevertheless, this study highlights the benefits of using the anteroinferior approach to plate displaced midshaft clavicular fracture in patients older than 60 years.

### Declaration of conflicting interest

The authors declare that they have no competing interests concerning this article.

### Funding

The Project Foundation of Chongqing Municipal Education Committee No. KJ1500232.

### References

- Altamimi SA and McKee MD. Canadian Orthopaedic Trauma Society. Nonoperative treatment compared with plate fixation of displaced midshaft clavicular fractures. Surgical technique. *J Bone Joint Surg Am* 2008; 90(Suppl 2 Pt 1): 1–8.
- Werner SD, Reed J, Hanson T, et al. Anatomic relationships after instrumentation of the midshaft clavicle with 3.5-mm reconstruction plating: an anatomic study. *J Orthop Trauma* 2011; 25: 657–660.
- Pecci M and Kreher JB. Clavicle fractures. *Am Fam Physician* 2008; 77: 65–70.
- Ban I, Branner U, Holck K, et al. Clavicle fractures may be conservatively treated with acceptable results - a systematic review. *Dan Med J* 2012; 59: A4457.
- Zlowodzki M, Zelle BA, Cole PA, et al. Treatment of acute midshaft clavicle fractures: systematic review of 2144 fractures: on behalf of the evidence-based orthopaedic trauma working group. *J Orthop Trauma* 2005; 19: 504–507.
- Iannotti MR, Crosby LA, Stafford P, et al. Effects of plate location and selection on the stability of midshaft clavicle osteotomies: a biomechanical study. *J Shoulder Elbow Surg* 2002; 11: 457–462.
- Kloen P, Werner CM, Stufkens SA, et al. Anteroinferior plating of midshaft clavicle nonunions and fractures. *Oper Orthop Traumatol* 2009; 21: 170–179.
- Constant CR and Murley AH. A clinical method of functional assessment of the shoulder. *Clin Orthop Relat Res* 1987; 160–164.
- Lee YS, Lin CC, Huang CR, et al. Operative treatment of midclavicular fractures in 62 elderly patients: knowles pin versus plate. *Orthopedics* 2007; 30: 959–964.
- Robinson CM, Court-Brown CM, McQueen MM, et al. Estimating the risk of nonunion following nonoperative treatment of a clavicular fracture. *J Bone Joint Surg Am* 2004; 86-A: 1359–1365.
- Xu J, Xu L, Xu W, et al. Operative versus nonoperative treatment in the management of midshaft clavicular fractures: a meta-analysis of randomized controlled trials. *J Shoulder Elbow surg* 2014; 23: 173–181.
- Kong L, Zhang Y and Shen Y. Operative versus nonoperative treatment for displaced midshaft clavicular fractures: a meta-analysis of randomized clinical trials. *Arch Orthop Trauma Surg* 2014; 134: 1493–1500.
- Wijdicks FJ, Van der Meijden OA, Millett PJ, et al. Systematic review of the complications of plate fixation of clavicle fractures. *Arch Orthop Trauma Surg* 2012; 132: 617–625.
- Canadian Orthopaedic Trauma Society. Nonoperative treatment compared with plate fixation of displaced midshaft clavicular fractures. A multicenter, randomized clinical trial. *J Bone Joint Surg Am* 2007; 89: 1–10.
- Poigenfurst J, Rappold G and Fischer W. Plating of fresh clavicular fractures: results of 122 operations. *Injury* 1992; 23: 237–241.
- Pai HT, Lee YS and Cheng CY. Surgical treatment of midclavicular fractures in the



- elderly: a comparison of locking and non-locking plates. *Orthopedics* 2009; 32.
17. Partal G, Meyers KN, Sama N, et al. Superior versus anteroinferior plating of the clavicle revisited: a mechanical study. *J Orthop Trauma* 2010; 24: 420–425.
  18. Favre P, Kloen P, Helfet DL, et al. Superior versus anteroinferior plating of the clavicle: a finite element study. *J Orthop Trauma* 2011; 25: 661–665.
  19. Jeray KJ. Acute midshaft clavicular fracture. *J Am Acad Orthop Surg* 2007; 15: 239–248.
  20. Eiff MP. Management of clavicle fractures. *Am Fam Physician* 1997; 55: 121–128.
  21. Formaini N, Taylor BC, Backes J, et al. Superior versus anteroinferior plating of clavicle fractures. *Orthopedics* 2013; 36: e898–e904.