

Self-injection of intravenous carbolic acid and multiorgan failure

Supradip Ghosh

Abstract

Intravenous self-injection of phenol resulting in multi-organ failure is reported. The case is discussed, because of the unique nature of exposure to phenol and rapid involvement of multiple organ systems including the central nervous, pulmonary, renal and hematological systems.

Keywords: Acute Respiratory Depres Syndrome, central nervous system depression, intravascular hemolysis, intravenous phenol, renal failure

Access this article online

Website: www.ijccm.org

DOI: 10.4103/0972-5229.125437

Quick Response Code:



Introduction

Phenol (Carbolic acid) is widely used as a household insecticide. Poisoning by ingestion of phenol or by accidental inhalation and absorption from skin is well described in the literature. Predominant toxicity of phenol is due to its strong corrosive effect. We describe a unique case of intravenous phenol poisoning resulting in multi-organ failure, admitted recently in our intensive care unit (ICU).

Case Report

A 48-year-old male, pharmacist by occupation was found lying unconscious on the floor of his chemist shop with a 50 cc syringe partially filled with carbolic acid (household phenol) by his side. He was immediately rushed to the emergency department of our hospital. On inquiry, his wife said that he was staying aloof for past 1 week. He was otherwise healthy and was not on any regular medication. There was no history of smoking or alcohol intake.

On examination, he was irritable, but still following simple command like showing tongue when asked for. His extremities were cold. He was pale but not icteric. He had tachycardia (heart rate 116/min, regular) with blood pressure of 86/56 mmHg. He was tachypnic with a respiratory rate of 40/min. No abnormality was detected in respiratory system and abdominal examination. He was moving all four limbs spontaneously and there was no apparent cranial nerve deficit. His left forearm was swollen with evidence of thrombophlebitis extending up to the arm [Figure 1]. Random Blood Glucose was 95 mg/dl. Initial blood gas revealed hypoxia, lactic acidosis and respiratory alkalosis with a compensated pH (pH 7.35, PO₂ 75.9 mmHg, on 12 L O₂ by mask, PCO₂ 33.1 mmHg, HCO₃ 17.8 mmol/L, lactate 5.2 mmol/L). Electrocardiogram was unremarkable except sinus tachycardia. Echocardiogram showed prominent Right Atrium with mild Tricuspid Regurgitation (estimated Pulmonary Artery Systolic Pressure 37 mmHg); Inferior Vena Caval diameter of 12 mm with large respiratory variation; no wall motion abnormality and global ejection fraction EF 55%.

After an initial fluid bolus of 1000 ml Normal Saline (NS) over half an hour and 500 ml × 2 of NS over next one and a half hour, he was continued on NS 100 ml/h with intermittent boluses of Furosemide. Oxygen supplementation with 40% Venturi Mask was started

From:

Department of Critical Care Medicine, Fortis-Escorts Hospital, Neelam Bata Road, NIT, Faridabad, Haryana, India

Correspondence:

Dr. Supradip Ghosh, Department of Critical Care Medicine, Fortis-Escorts Hospital, Neelam Bata Road, NIT, Faridabad - 121 001, Haryana, India.
E-mail: ghshovan@rediffmail.com

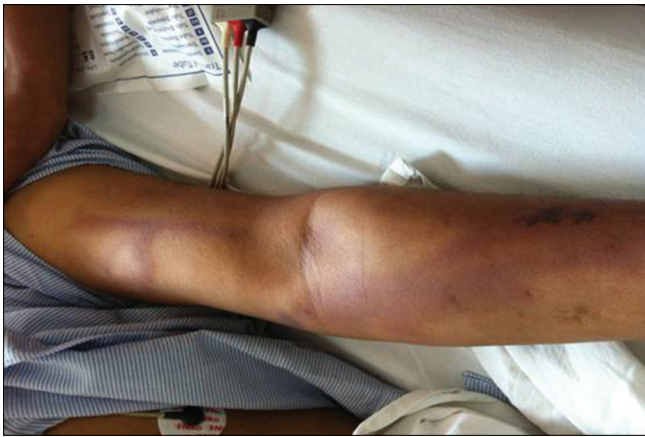

Figure 1: Extensive thrombophlebitis in the left forearm and arm

to maintain Oxygen saturation SpO_2 above 92%. He was also given other supportive therapy in the form of intravenous Pantoprazole as stress ulcer prophylaxis and Ondansetron. After 2 h in the ICU, he had improvement in blood pressure, normalization of serum lactate level (2.3 mmol/L) and sensorium. He confessed to the self-injection of intravenous phenol. He also revealed that he tried to consume "All Out" liquid (Mosquito repellent containing 1.6% Pyrethrin) but immediately vomited out. At this time, he was oliguric and progressively more tachypneic with worsening oxygenation status. Chest X-ray showed bilateral patchy infiltrate [Figure 2]. Initial laboratory investigations revealed normal complete blood count; high blood urea nitrogen (21.1 mg/dl) and S Creatinine 2 mg/dl with normal electrolytes; deranged liver function test (S Bilirubin 3.02 mg/dl, direct Bilirubin 0.14 mg/dl, aspartate aminotransferase AST 211 U/L, alanine aminotransferase ALT 95 U/L, alkaline phosphate ALP 95 U/L, lactate dehydrogenase LDH 2574 U/L); normal serum Amylase; deranged coagulation parameters partial thromboplastin time 63.7 min, control 26 min and prothrombin time 27.8 min, control 12.4 min); high creatine phosphokinase (447 U/L). Urine analysis showed hemoglobinuria and proteinuria 3+. After an initial trial of noninvasive ventilation for half an hour, he was intubated and started on mechanical ventilation support with low tidal volume strategy.

After 6 h, he was still oliguric with 45 ml of dark urine [Figure 3] (Total intake 3500 ml). There was evidence of intravascular hemolysis with low serum Haptoglobin. His G-6PD level was normal. Abdominal ultrasonography examination was unremarkable. Hemodialysis was initiated in view of oliguria persistent metabolic acidosis and probable fluid overload. On day 2 he developed thrombocytopenia (platelet count 100,000/dl). In the

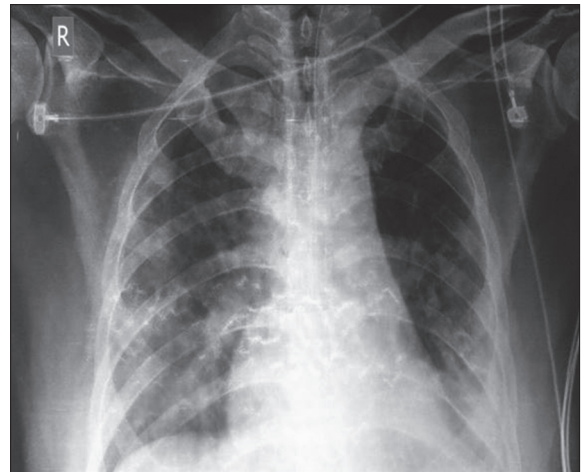


Figure 2: Initial chest X-ray showing bilateral infiltrate

subsequent days in the ICU his hypoxia improved but he continued to remain anuric. He was successfully weaned off the ventilator on day 4. On day 5 he was shifted to the ward on oxygen supplementation with 4 L O_2 by nasal prong (maintaining SpO_2 of 95%), still anuric on daily hemodialysis. On day 14, he was discharged from the hospital with normalization of all parameters except kidney function. He was advised 3 times a week maintenance hemodialysis, at discharge. His kidney function tests normalized over the subsequent 8 weeks of follow-up.

Discussion

Phenol is a hydroxybenzene obtained from coal tar oil fractional distillation. Phenol and its derivatives like chloroxylenol (Dettol), dinitrophenol and pentachlorophenol are highly toxic compounds. Other than the local corrosive effects systemic manifestations are also described. Systemic effects can involve all organ systems including the cardiovascular, respiratory, renal, central nervous, and hematological.^[1]

CNS depression is a known complication of phenol poisoning. In a 5 years retrospective review of 96 cases of phenol poisoning (both oral and dermal exposure), 11 out of 14 patients with oral exposure developed rapid onset CNS depression.^[2] None of these patients with CNS depression had seizures. CNS depression is probably a direct effect of phenol. Though the patient did not have any visible seizure activity or tongue bite or incontinence of urine and stool, subclinical seizure activity cannot be ruled out with absolute certainty as the cause of altered sensorium. The patient gave history of ingestion of Pyrethrin and Pyrethrin/Pyrethroid intoxication is known to produce seizure activity including status epilepticus.^[3]

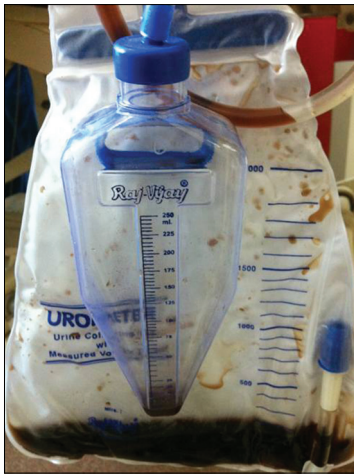

Figure 3: Dark urine

Presence of hypoxia at admission and initial chest X-ray showing bilateral infiltrate strongly favors the diagnosis of ARDS in our patient. Normal caliber of the inferior vena cava with significant respiratory variation on admission makes fluid overload unlikely. Acute respiratory failure and acute kidney injury following inadvertent injection of higher concentration of phenol (89% instead of 6% of 10 cc phenol) for chronic pain relief was described in a case report.^[4] The authors have also described evidence of hemolysis, high creatine phosphokinase value and lactic acidosis in the patient.

Indirect bilirubinemia, high Lactate Dehydrogenase, presence of hemoglobinuria and low serum Haptoglobin level confirm the presence of intravascular hemolysis. Intravascular hemolysis is a well-known complication of phenol poisoning.^[5] In a recent case report, phenol induced hemolytic anemia lasting more than 2 weeks and requiring 4 units of blood transfusion was described.^[6] The authors postulated that the direct effect of phenol on the energy storage of Red Blood Cells results in membrane instability leading to hemolysis. Also, phenol may produce Heinz bodies and contribute to hemolysis.^[6]

The persistent oliguria and renal dysfunction despite the quick reversal of shock (the serum lactate level was normalized within 2 h of hospital admission), makes direct effect of phenol on the kidneys as the likely cause

of renal failure in our patient. Intravascular hemolysis and hemoglobinuria might have contributed to the renal failure. Minimal elevation of CPK (447 U/L) makes Rhabdomyolysis as a significant contributor to renal failure unlikely. Possible mechanisms of renal injury by phenol are damage to the renal tubular epithelial cells by free radical intermediates of phenol and inability of the epithelial cells to form enough reduced glutathione to clear the phenol intermediates.^[7]

Exposure to phenol with resulting toxicity is very common. But the present case is interesting for its unique route of exposure to phenol and the rapid progression to multiple organ failure. The rapidity of organ failure is attributable to direct parenteral administration of the toxin thereby bypassing the of first pass metabolism in the liver and intestines.

Acknowledgment

I sincerely acknowledge the contributions of my colleagues in the Departments of Critical Care Medicine and Internal Medicine and the nursing staff in the Intensive Care Unit, Fortis-Escorts Hospital, Faridabad in the clinical management of the case.

References

1. Bruce RM, Santodonato J, Neal MW. Summary review of the health effects associated with phenol. *Toxicol Ind Health* 1987;3:535-68.
2. Spiller HA, Quadrani-Kushner DA, Cleveland P. A five year evaluation of acute exposures to phenol disinfectant (26%). *J Toxicol Clin Toxicol* 1993;31:307-13.
3. Ghosh S, Ahlawat A, Rai KK, Arora A. An unusual cause of status epilepticus. *Indian J Crit Care Med* 2009;13:106-7.
4. Gupta S, Ashrith G, Chandra D, Gupta AK, Finkel KW, Guntupalli JS. Acute phenol poisoning: A life-threatening hazard of chronic pain relief. *Clin Toxicol (Phila)* 2008;46:250-3.
5. Hassan AB, Seligmann H, Bassan HM. Intravascular haemolysis induced by pentachlorophenol. *Br Med J (Clin Res Ed)* 1985;291:21-2.
6. Santa N, Bhagyawati S, Jeetenkumar T, Motu T, Lokeshwar Kh, Singh MK. Phenol-induced hemolytic anemia. *J Ind Acad Clin Med* 2003;4:174-5.
7. Li Y, Bentzley CM, Tarloff JB. Comparison of para-aminophenol cytotoxicity in rat renal epithelial cells and hepatocytes. *Toxicology* 2005;209:69-76.

How to cite this article: Ghosh S. Self-injection of intravenous carbolic acid and multiorgan failure. *Indian J Crit Care Med* 2014;18:43-5.

Source of Support: Nil, **Conflict of Interest:** None declared.