

Low Back Pain in Patients with Lumbar Spinal Stenosis —Hemodynamic and electrophysiological study of the lumbar multifidus muscles

Yoshihito Sakai¹⁾, Sadayuki Ito¹⁾, Tetsuro Hida²⁾, Kenyu Ito²⁾, Hiroyuki Koshimizu¹⁾ and Atsushi Harada¹⁾

1) Department of Orthopaedic Surgery, National Center for Geriatrics and Gerontology, Japan

2) Department of Orthopaedic Surgery, Nagoya University School of Medicine, Japan

Abstract:

Introduction: Several studies have demonstrated improvement in low back pain (LBP) after decompression surgery for lower extremity symptoms in lumbar spinal stenosis (LSS); however, the influence of neuropathic disorders on LBP is uncertain. Aim of this study is to identify the features of motion-induced and walking-induced LBP in patients with LSS and to assess whether neuropathic LBP develops.

Methods: In total, 234 patients with LSS including L4/5 lesion were asked to identify their LBP. Subjects were classified into three groups: walking-induced LBP that aggravated during walking (W group), motion-induced LBP that aggravated during sitting up (M group), and no LBP (N group). Cross-sectional areas of the dural sac, lumbar multifidus, and the erector spinae were measured. Intramuscular oxygenation was evaluated with near-infrared spectrophotometer. Surface electromyography (EMG) and mechanomyography (MMG) were performed on the lumbar multifidus. Morphological, hemodynamic, and electrophysiological differences in the onset of LBP were evaluated.

Results: The prevalence of W, M, and control groups was 31.2%, 32.1%, 36.8%, respectively. Concordance between the laterality of LBP and leg symptoms including pain and numbness was 86.3% in the W group and 47.0% in the M group. Dural sac area was lower in the W group than in the M and control groups. In the hemodynamic evaluation, the oxygenated hemoglobin level was significantly lower in the W group than in the M and N groups. In electrophysiological evaluation of lumbar multifidus, the mean power frequency in EMG was significantly higher in the W group than in the N group. Amplitude in MMG was significantly lower in the W group than in the N group.

Conclusions: Neurologic disturbance in patients with LSS may be attributed to “neuropathic LBP.” Neuropathic multifidus disorder plays a role in walking-induced LBP.

Keywords:

low back pain, neuropathic pain, lumbar spinal stenosis, hemodynamic, electrophysiological study, lumbar multifidus muscle

Spine Surg Relat Res 2017; 1(2): 82-89
dx.doi.org/10.22603/ssrr.1.2016-0016

Lumbar spinal stenosis (LSS) is a degenerative disorder defined as a narrowing of the spinal canal, resulting in lower extremity disability and neurogenic intermittent claudication caused by entrapment and compression of cauda equina and/or nerve roots. Typically, when walking, patients with LSS stoop forward due to leg pain, numbness, and weakness. Low back pain (LBP), a symptom in nearly all patients with LSS, often presents particularly in the earlier stages of the disorder¹⁾. The presence of LBP is of less practical importance for diagnosing LSS than are leg symptoms. Degenera-

tive LSS is defined as a clinical syndrome of gluteal and/or lower extremity pain and/or fatigue, which may occur with or without back pain²⁾. In contrast, several studies have demonstrated significant improvement in LBP after posterior decompression surgery for lower extremity symptoms in LSS^{3,4)}. Jolles et al. suspected that the extended lumbar spine after decompression surgery reduced LBP⁴⁾. However, the influence of decompression on LBP is uncertain, and greater back pain is associated with a significantly worse outcome after decompression⁵⁾. It is well documented that paraspin-

Corresponding author: Yoshihito Sakai, jsakai@ncgg.go.jp

Received: October 28, 2016, Accepted: December 20, 2016

Copyright © 2017 The Japanese Society for Spine Surgery and Related Research

denervation occurs in subjects with LSS^{6,7}); however, the relationship between lumbar paraspinal denervation and LBP remains unclear. Thus, the occurrence of “neuropathic LBP” is still not well appreciated. As with the intermittent claudication seen in the patients with LSS, “motion-induced intermittent LBP” by walking and/or maintaining an upright standing position can be elicited by back muscle dysfunction⁸). While patients with LSS frequently present walking-induced LBP and are asymptomatic at rest, it remains unclear whether these LBPs are explicable as a neurogenic disorder, as well as intermittent claudication. Physiological analysis of LBP accompanied with LSS is not previously reported. In this study, we investigated the features of walking-induced LBP in patients with LSS as a marker for neuropathic LBP.

Materials and Methods

In this prospective study, all patients (n=234; 129 men and 105 women, mean age 72.6 ± 6.9 years) were enrolled consecutively, between 2011 and 2014, at a single institution (National Center for Geriatrics and Gerontology). The enrolled patients were planned to undergo surgery for LSS including L4/5 lesion, because of their leg pain and/or numbness. All patients were asked to identify their LBP, according to the criteria present above: walking-induced intermittent LBP that aggravated during walking and was silent at rest (W group), motion-induced LBP that aggravated during sitting up from bed or in the sitting position (M group), and no LBP (N group). When the patients had both walking and motion-induced LBP, greater type of induced pain was adopted. Moreover, patients completed visual analogue scales (VASs; 0-10) for LBP and leg pain. They also completed a validated Japanese version of the Roland Morris Disability Questionnaire (RDQ)⁹, and Euroqol quality of life scale (EQ-5D)¹⁰ that comprises a health state classification (health problems by severity in five domains). Patients with motor weakness of the lower extremities and history including previous back surgery were excluded from this study. Ethical approval was granted by the institutional review board, and all patients provided written informed consent.

Nerve involvement classification in LSS¹¹

The impairment patterns in LSS were classified into cauda equine type, radicular type, and mixed type. Cauda equine type is characterized by numbness and burning sensation in the bilateral legs, associated with urinary dysfunction. The most significant manifestation of radicular type is unilateral leg pain and/or numbness that may lead to neurologic intermittent claudication when patients are standing or walking.

X-ray image analysis

Antero-posterior and lateral X-ray images of the spine were taken. The lumbar scoliosis and lordosis angle by Cobb method between the superior edge of L1 and S1, S1

inclination angle, the presence of spondylolisthesis (anterior slip >3 mm), and the lumbar range of motion defined as the difference in lumbar lordosis angle between flexion and extension were measured.

Magnetic resonance imaging (MRI) analysis

Axial T2-weighted slices at L1/2 and L4/5 were obtained to measure the cross-sectional area of the dural sac, the lumbar multifidus and the erector spinae muscles for each level. Paraspinal muscle cross-sectional areas for both the right and left side were added together for each subject. Vertebral endplate degeneration was evaluated according to Modic change¹²).

Hemodynamic evaluation of the lumbar multifidus

Intramuscular oxygenation was evaluated noninvasively using a near-infrared spectrophotometer (NIRS; NIRO-120[®], Hamamatsu Photonics K.K., Hamamatsu, Japan). The probe, combined with a light transmission fiber and two detectors, was positioned with a bandage on the left posterior aspect of the lumbar multifidus muscle at the level of L4/5. The lumbar spine was extended gradually 30° backward and forward for 15 s each and oxygenated hemoglobin (Oxy-Hb) increase in the lumbar multifidus during lumbar extension and decrease during flexion were evaluated¹³). Oxy-Hb was evaluated as relative changes ($\mu\text{mol/L}$) from differences between lumbar extension/flexion and baseline at resting position. The accuracy and reliability of the NIRS were confirmed by 10 measurements made on five healthy males, and the intraclass correlation coefficients of Oxy-Hb were 0.950 as considered being highly satisfactory.

Electrophysiological study

Surface electromyography (EMG; WEB-9500, Tokyo, Japan) and mechanomyography (MMG; MPS110, MEDI SENS. Inc., Tokyo, Japan) were evaluated simultaneously on the right posterior aspect of the lumbar multifidus muscle at the level of L4/5, in parallel with NIRS measurement in a similar manner. The lumbar spine was extended gradually 30° backward and forward for 15 s, and the EMG and MMG signals were analyzed with Trend Viewer software (KISSEI COMTEC CO., Nagano, Japan). Power spectrums were obtained using the fast Fourier transform, and the root mean square (RMS) and mean power frequency (MPF) were computed. MMG has been used to evaluate muscle function noninvasively, and signals are generated by lateral muscle fiber oscillations¹⁴). MMG has been defined as the recording of lateral oscillations of muscle fibers that occur during a contraction¹⁴), whereas the amplitude of the EMG signal reflects the number of active motor units and their firing rates¹⁵). The EMG signal was detected by a bipolar, Ag-AgCl surface electrode with 10 mm diameter, and MMG signal was detected by a transducer: an accelerometer with a frequency response of DC up to 1 kHz. The EMG and MMG signals were digitized at a sampling rate of 1,000 Hz, and were bandpass filtered at 20-500 Hz.

Table 1. Clinical Features of Each Group of Patients at Baseline Evaluation.

	W group (n=73)	M group (n=75)	N group (n=86)
Age (years)	73.1±7.2	72.5±7.2	72.3±6.5
Gender (male: female)	35/38	39/36	55/31
Height (cm)	155.3±8.9	156.1±9.4	158.3±8.3
Body weight (kg)	59.6±12.9	59.2±11.7	60.9±9.4
BMI	24.6±4.2	24.2±3.2	24.3±3.0
Systolic pressure (mmHg)	134.2±19.6	135.1±20.5	136.4±18.6
Smoking index	265.43±439.6	278.2±297.3	318.3±424.9
Diabetes (%)	36.9*	22.6	19.0
Duration of pain (weeks)	244.3±387.9	228.2±392.6	146.0±220.9
Hb	13.3±1.8	13.3±1.8	13.5±1.5
CPK	132.4±129.0	133.2±98.9	147.6±128.1
ABI	1.18±0.54	1.12±0.10	1.14±0.11
TBI	0.76±0.14	0.77±0.13	0.79±0.12
Clinical symptom			
VAS (LBP)	5.79±2.48***	4.73±2.81*	2.12±0.33
VAS (leg pain)	6.11±2.63	6.57±2.41	6.51±2.60
RDQ	14.1±4.4 [†]	13.8±5.5 [†]	3.0±0.7
EQ5D	0.55±0.13**	0.48±0.23	0.54±0.22
Concordance (%)	86.3 [†]	47.0	-
Radiographic findings			
Presence of slippage (%)	35.6	33.3	23.8
Lumbar scoliosis (L1-S1) (°)	5.3±6.1	4.3±3.5	5.2±6.0
Lordotic angle (L1-S1) (°)	32.8±13.3	31.6±13.4	34.7±12.2
Sacral inclination (°)	27.8±8.8	27.5±9.5	28.7±9.0
Lumar range of motion (°)	52.5±24.2	50.2±24.9	55.9±20.9

*p<0.05 (compared with N group)

**p<0.05 (compared with M group)

[†]p<0.01 (compared with N group)

W group: walking-induced intermittent low back pain, M group: motion-induced low back pain, N group: no low back pain

BMI: body mass index, Hb: hemoglobin, CPK: creatine phosphokinase, ABI: Ankle Brachial Pressure Index, TBI: Toe Brachial Pressure Index, VAS: visual analogue scale, RDQ: Roland Morris Disability Questionnaire, EQ5D: Euro QOL 5 dimension, Concordance: Concordance between the laterality of LBP and leg symptoms, including pain and numbness.

Statistics

The statistical analyses were performed using SPSS 12.0 (SPSS, Chicago, USA). All data were expressed as mean ± SD. Differences in NIRS, EMG, and MMG between the three groups were examined for statistical significance using one-way analysis of variance. A p-value <0.05 denoted the presence of a statistically significant difference. In the NIRS measurement, all data were corrected by thickness of fat tissue at the level of L4/5 on MRI.

Results

Clinical evaluations were performed by two spine surgeons (YS and AH). They revealed that 73 patients (31.2%) had walking-induced intermittent LBPs (W group), 75 (32.1%) had motion-induced LBPs (M group), and 86 (36.8%) had no LBPs (N group). There were no statistically significant differences between three groups in age, height, weight, blood pressure, smoking index, or blood chemistry

measurements including hemoglobin and creatine phosphokinase, and ankle and toe brachial pressure index. Diabetic patients were more numerous in the W group. No significant differences were seen in duration of back and/or leg pain among the three groups. VAS scores of LBP in the W group were significantly higher than those in the M group ($p < 0.05$); however, no significant differences were seen in VAS scores of leg pain among the three groups. There was no significant difference in the RDQ scores between the W and M groups; however, EQ5D in the M group was significantly lower than that in the W group ($p < 0.05$). The concordance between the laterality of LBP and leg symptoms including pain and numbness were 86.3% in the W group and 47.0% in the M group, with a significant difference ($p < 0.01$). There were no statistically significant differences between radiographic findings of the three groups (Table 1). There was no statistical significance in nerve involvement classification among the three groups; however, dural sac area (ratio of L4/5 to L1/2) on MRI was significantly lower in the W group than in the M and N groups ($p < 0.05$) (Fig. 1). In the

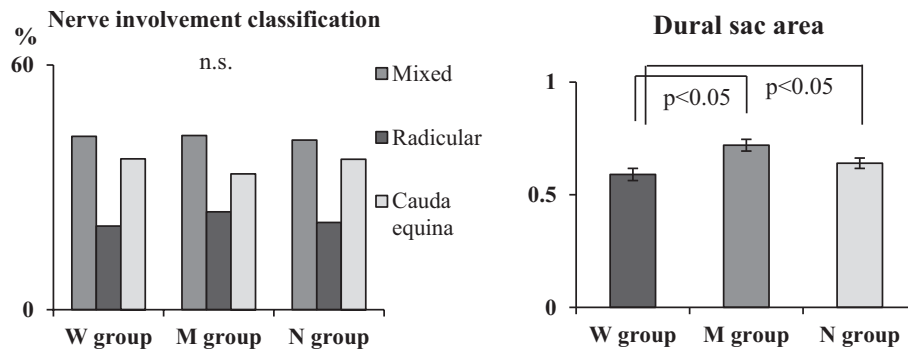


Figure 1. Nerve involvement classification and dural sac area in each group
 There is no statistical significance in nerve involvement classification among the three groups. Spinal canal area (ratio of L4/5 to L1/2) was significantly lower in the W group. ($p < 0.05$)

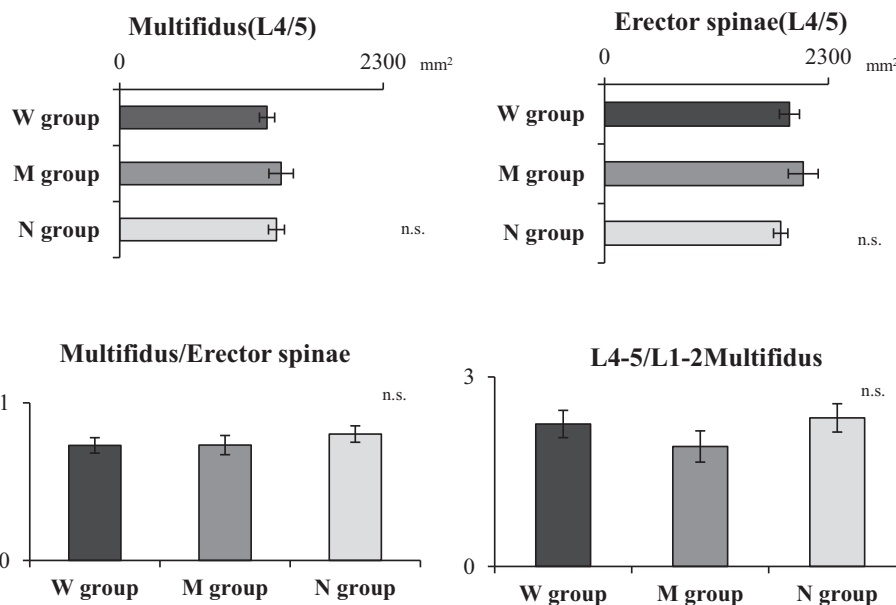


Figure 2. Comparison of the cross sectional area at the lumbar multifidus and erector spinae
 There is no significant difference in the cross sectional area at the lumbar multifidus and erector spinae among the three groups.

trunk muscle atrophy at the level of L4/5 measured by MRI, there was no significant difference in the cross sectional area at the lumbar multifidus and erector spinae among the three groups (Fig. 2). No significant difference was seen in degeneration of the end plate (Modic change) among the three groups (Fig. 3). In hemodynamic measurement using NIRS, relative change in oxy-Hb during lumbar extension was significantly lower in the W group compared with the M and N groups ($p < 0.01$; Fig. 4). In electrophysiological evaluation of the lumbar multifidus muscles, MPF in EMG during lumbar extension was significantly higher in the W group than in the N group ($p < 0.05$). RMS in MMG during lumbar extension was significantly lower in the W group than in the N group ($p < 0.01$; Fig. 5).

Discussion

LBP may present in nearly all patients with LSS with or without neurological claudication, particularly in the earlier stages of the disorder¹⁾. However, not only neuropathic LBP but also pathophysiology of LBP accompanied with LSS has been less studied. Amundsen et al. reported that LBP usually lasts before the start of pain in the legs, and their data concerning the presence of LBP related to various positions of the body and to ambulation revealed that LBP was most common, 76% during standing and 75% during walking¹⁶⁾. Kalichman et al. reported in the Framingham Study that the presence of absolute LSS evaluated by computed tomography was associated with LBP, with an odds ratio of 3.16¹⁷⁾. The present study revealed that LBP in surgical patients with LSS was seen in 63.2%, of which 67.9% developed it

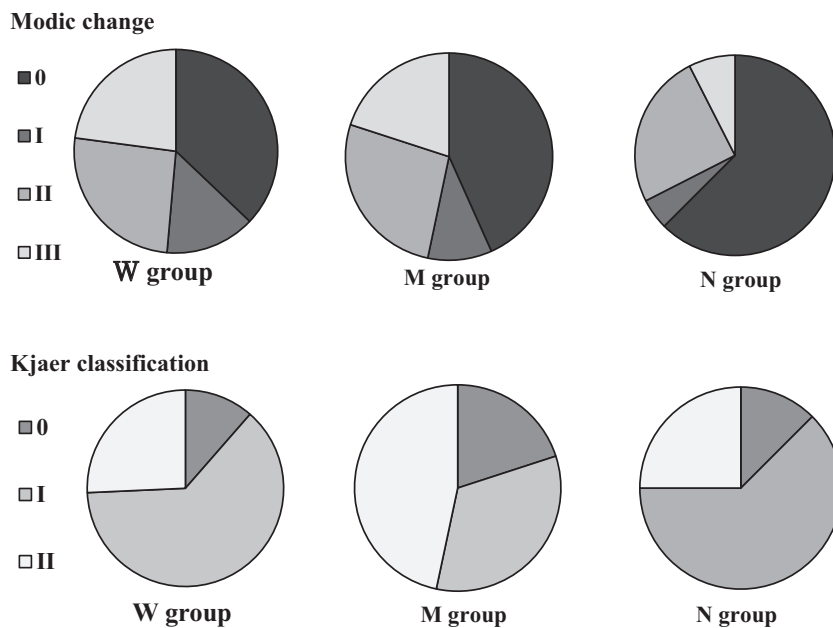


Figure 3. Degeneration of the end plate (Modic change) and fat degeneration of the lumbar multifidus (Kjaer classification) in MRI
 No significant difference was seen among the three groups, in degeneration of the end plate (Modic change) and in fat degeneration of the lumbar multifidus (Kjaer classification).

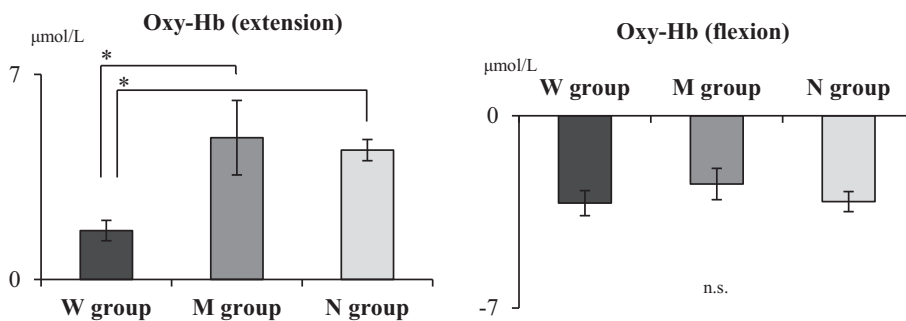


Figure 4. Hemodynamic change at the lumbar multifidus during lumbar extension and flexion using NIRS
 Relative change in oxy-Hb during lumbar extension was significantly lower in the W group compared with the M group and N group.
 NIRS, near-infrared spectroscopy; oxy-Hb, oxygenated hemoglobin; deoxy-Hb, deoxygenated hemoglobin. * $p < 0.01$.

during walking. Patients with LSS complain of discomfort and/or pain in the lower extremities as neurological claudication when walking, and consequently, LBP during walking may have potential for “neuropathic pain.” Takahashi et al. defined the LBP induced by walking and/or maintaining an upright standing position as “motion-induced intermittent LBP,” and it seemed that fatigue of the back muscles could be the generator in LBP⁸. Aoki et al. demonstrated using a new detailed VAS system that nonspecific LBP in elderly patients was present in motion, besides during standing and sitting¹⁸. Recently, LBP in motion was related to an increase in the nerve growth factor level in the intervertebral disc, which led to discogenic LBP¹⁹. Some authors reported that walking-induced LBP²⁰ and the LBP with the neuropathic

component²¹ had better response to pregabalin known as a therapeutic agent for neuropathic pain. Thus, previous investigations regarding differences in characteristics of LBP suggest the possibility of varying pathogenesis. Therefore, this study focused on neuropathic LBP and aimed to investigate the pathophysiological condition of the multifidus muscles. This muscle is innervated segmentally by the lumbar nerve roots and is important for elucidating the pathogenesis of walking-induced intermittent LBP, in contradiction to motion-induced LBP. Thus, there were no statistical differences between walking-induced and motion-induced LBP in atrophy and fatty degeneration of multifidus muscles, nor vertebral end plate degeneration. Concordance between the laterality of LBP and leg symptoms including pain and

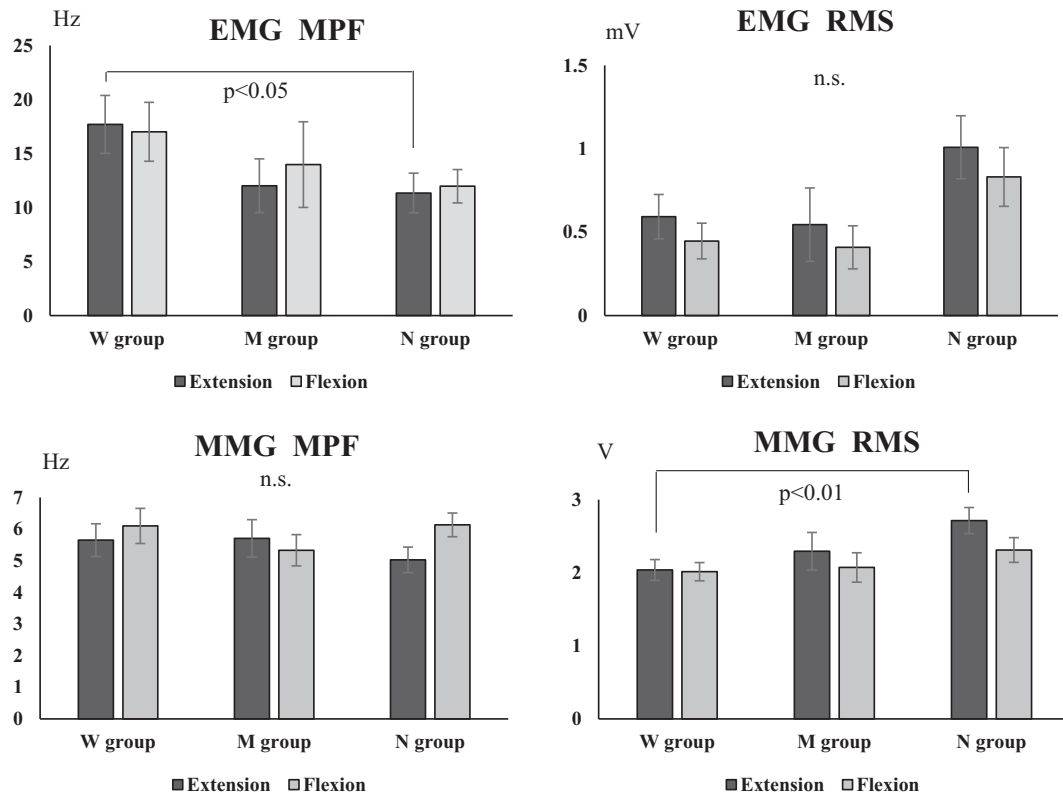


Figure 5. Electromyographical and mechanomyographical findings

MPF in EMG during lumbar extension was significantly higher in the W group than in the N group. RMS in MMG during lumbar extension was significantly lower in the W group than in the N group.

EMG, electromyography; MMG, mechanomyography; MPF, mean power frequency; RMS, root mean square.

numbness and hemodynamic decline of oxy-Hb in multifidus muscles was seen in walking-induced LBP. Thus, we suspected neuropathic LBP as the neurologic dysfunction caused by LSS affected hemodynamic change in multifidus muscles innervated by lumbar nerve roots.

Regarding insufficient blood supply in LBP, postmortem lumbar angiographic findings revealed that atherosclerotic lumbar arterial narrowing was related to a history of LBP for 3 months or longer²². Lumbar compartment syndrome of the paraspinal muscles has been proposed as an important role in the etiology of LBP^{23,24}. It is considered the cause of intermittent LBP during exercise²⁵ and lumbar flexion²⁶. Papers focused on hemodynamic aspects of the lumbar muscle related to LBP are sporadic. Recently, more studies are investigating the cause of LBP in terms of oxygen consumption and hemodynamics besides our previous study^{13,27,28}. Several clinical studies have tried to identifying whether oxygen consumption and dynamics change play an important role in the pathology of LBP at the level of paraspinal muscles. Regarding the differences in oxygen consumption at the lumbar muscle between healthy and LBP individuals, Kovac et al. suggested using NIRS that the patients with muscular LBP did not use the available oxygen during exercise and that there is an inability to consume oxygen due to mitochondrial damage caused by their muscle damage²⁷. Kell et al. investigated hemodynamics in healthy and

chronic LBP subjects using NIRS, and identified differences in paraspinal muscle blood flow and oxygenation responses during dynamic incremental work²⁸. However, whether the muscle blood flow impairment represents the cause of LBP or it is a secondary change due to LBP remains controversial. According to previous results, oxygenation does not always depend on intramuscular pressure^{29,30}, and therapeutically increased muscle blood flow has not been linked to LBP improvement³¹. In contrast, involvement of LBP in LSS has been reported with various results, from 66.2% to 95%^{4,16,32}. Kalinchman et al. demonstrated that the prevalence of absolute LSS was associated with LBP, with an odds ratio of 3.16¹⁷, and Kleinstück reported that greater back pain relative to leg pain at baseline was associated with a significantly worse outcome after lumbar decompression surgery for LSS⁵. The fact that decompression surgery for LSS improves not only the leg symptoms but also LBP provides the idea of neuropathic LBP that may be caused by ischemic nerves and blood flow disturbance^{3,4,33,34}. However, the pathophysiological mechanism of LBP accompanied with LSS has not been identified. The present study revealed that LBP including walking-induced intermittent and motion-induced LBP was seen in 63.2% of patients with LSS and no significant differences were seen among type of neural involvement in LSS (cauda equine, radicular, and mixed type). However, differences in the onset of LBP

showed that the concordance between the laterality of LBP and leg symptoms was significantly higher in walking-induced LBP than in motion-induced LBP. Furthermore, patients with walking-induced LBP showed narrower cross-sectional area of the dural sac in MRI, lower oxygenation in multifidus hemodynamic, and lower amplitude in MMG during lumbar extension. These results indicate that the multifidus dysfunction due to neurological involvement is responsible for clinical LBP manifestation in LSS. While the lumbar portion of erector spinae muscle is supplied by the lateral divisions of the L1-L4 dorsal rami, dorsally and laterally through the muscle³⁵, each fascicles in the lumbar multifidus is innervated by the medial branch of the dorsal ramus, with the same segmental number as the nerve³⁶. Namely, the major difference between lumbar multifidus and the erector spinae muscle is that the former is innervated by single nerve, whereas the latter by many nerves with segmental control. This means that neuropathic disorder with LSS at the level of L4/5 has potential for impairment of the lumbar multifidus at L4/5. Present study demonstrated that there are no significant differences in the paraspinal muscle cross-sectional areas, including the multifidus and erector spinae muscle, between both LBP groups. In the same time, patients with LSS with the walking-induced intermittent LBP revealed significantly lower relative change in oxy-Hb and amplitude in MMG during lumbar extension. Reduced oxygenation is thought to be caused by less circulation of the blood flow; however, low paraspinal muscle blood flow was regarded not as cause of LBP but result³¹. Thus, we considered that reduced multifidus contraction lead to decline the multifidus oxygenation as clinical feature in the walking-induced LBP. Study results in cross-sectional area of the muscle and dural sac on MRI indicated the reduced multifidus contraction is attributable to nerve compression but not muscle atrophy. In addition to these results, the concordance between the laterality of LBP and leg neuropathic symptoms suggests the possibility of neuropathic multifidus dysfunction as the cause of the walking-induced intermittent LBP.

The major limitation of the present study was that the subjects were patients with LBP with LSS and we had no control LBP subjects without neuropathic disorders. The main objective of this study was to evaluate neuropathic LBP by analyzing a limited number of patients with LBP with LSS; therefore, the results of the present study are not necessarily applicable to general, non-specific LBP. Moreover, measured side of hemodynamic and electrophysiological procedures was fixed on the back muscle. Thus, the results in differences seen in laterality of LBP were somewhat unconvincing. Further investigations may be expected to elucidate the pathogenesis of neuropathic LBP.

In summary, walking-induced intermittent LBP and motion-induced LBP in patients with LSS were seen in 31.2% and 32.1% of patients, respectively. In walking-induced intermittent LBP, concordance between the laterality of LBP and leg neuropathic symptoms and canal stenosis was significantly higher, while the oxygenation in the multi-

fidus muscle and muscle contraction was lower compared with motion-induced LBP. Neuropathic multifidus disorder is considered to play a role in LBP.

Conflicts of Interest: The authors declare that there are no conflicts of interest.

References

1. Verbiest H. Lumbar spine stenosis. 3d ed. Philadelphia: Saunders, 1990: 2805-55.
2. North American Spine Society Evidence-Based Clinical Guidelines for Multidisciplinary Spine Care: Diagnosis and treatment of degenerative lumbar spinal stenosis. NASS Evidence-Based Clinical Guidelines Committee. 2011. Available from: <http://www.spine.org/Pages/PracticePolicy/ClinicalCare/ClinicalGuidelines/Default.aspx>
3. McGregor AH, Hughes SP. The evaluation of the surgical management of nerve root compression in patients with low back pain: Part 1: The assessment of outcome. *Spine* 2002; 27(13): 1465-70.
4. Jolles BM, Porchet F, Theumann PN. Surgical treatment of lumbar spinal stenosis. Five-year follow-up. *J Bone Joint Surg Br* 2001; 83(7): 949-53.
5. Kleinstück FS, Grob D, Lattig F, et al. The influence of preoperative back pain on the outcome of lumbar decompression surgery. *Spine* 2009; 34(11): 1198-203.
6. Seppäläinen AM, Alaranta H, Soini J. Electromyography in the diagnosis of lumbar spinal stenosis. *Electromyogr Clin Neurophysiol* 1981; 21(1): 55-66.
7. Wilbourn AJ, Aminoff MJ. AAEM minimonograph 32: The electrodiagnostic examination in patients with radiculopathies. *American Association of Electrodiagnostic Medicine. Muscle Nerve* 1998; 21(12): 1612-31.
8. Takahashi I, Kikuchi S, Sato K, Iwabuchi M. Effects of the mechanical lord on forward bending motion of the trunk: Comparison between patients with motion-induced intermittent low back pain and healthy subjects. *Spine* 2007; 32(2): E73-8.
9. Sugimoto Y, Fukuhara S, Kukichi S, et al. Validation of the Japanese version of the Roland-Morris Disability Questionnaire. *J Orthop Sci* 2003; 8(4): 543-8.
10. EuroQoL Group. EuroQoL: A new facility for the measurement of health related quality of life. *Health Policy* 1990; 16: 196-208.
11. Kikuchi S, Hoshika I, Matui T. Neurogenic intermittent claudication in lumbar spine disease; part 1. *Orthop Surg* 1986; 37: 1429-38 (in Japanese).
12. Modic MT, Steinberg PM, Ross JS, Masaryk TJ, Carter JR. Degenerative disk disease: Assessment of changes in vertebral body marrow with MR imaging. *Radiology* 1988; 166(1): 193-6.
13. Sakai Y, Matsuyama Y, Ishiguro N. Intramuscular oxygenation of exercising trunk muscle in elderly persons. *J Lumbar Spine Disord* 2005; 11: 148-56.
14. Orizo C. Muscle sound: Bases for the introduction of a mechanomyographic signal in muscle studies. *Crit Rev Biomed Eng* 1993; 21(3): 201-43.
15. De Luca CJ. Use of the surface EMG signal for performance evaluation of back muscles. *Muscle Nerve* 1993; 16(2): 210-6.
16. Amundsen T, Weber H, Lilleås, et al. Lumbar spinal stenosis: Clinical and radiological features. *Spine* 1995; 20(10): 1178-86.
17. Kalichman L, Cole R, Kim DH, et al. Spinal stenosis prevalence and association with symptoms: The Framingham Study. *Spine J* 2009; 9(7): 545-50.
18. Aoki Y, Sugiura S, Nakagawa K, et al. Evaluation of nonspecific

- low back pain using a new detailed visual analogue scale for patients in motion, standing, and sitting: Characterizing nonspecific low back pain in elderly patients. *Pain Res Treat* 2012; 680496.
19. Aoki Y, Nakajima A, Ohtori S, et al. Increase of nerve growth factor levels in the human herniated intervertebral disc: can annular rupture trigger discogenic back pain? *Arthritis Res Ther* 2014; 16(4): R159.
 20. Sakai Y, Ito K, Hida T, Ito S, Harada A. Neuropathic pain in elderly patients with chronic low back pain and effects of pregabalin: A preliminary study. *Asian Spine J* 2015; 9(2): 254-62.
 21. Sakai Y, Ito K, Hida T, et al. Pharmacological management of chronic low back pain in older patients: a randomized controlled trial of the effect of pregabalin and opioid administration. *Eur Spine J* 2015; 24(6): 1309-17.
 22. Kauppila LI, Tallroth K. Postmortem angiographic findings for arterial supplying the lumbar spine: Their relationship to low-back symptoms. *J Spinal Disord* 1993; 6(2): 124-9.
 23. Carr D, Gilbertson L, Frymoyer J, Krag M, Pope M. Lumbar paraspinal compartment syndrome. A case report with physiologic and anatomic studies. *Spine* 1985; 10(9): 816-20.
 24. Peck D, Nicholls PJ, Beard C, Allen JR. Are there compartment syndromes in some patients with idiopathic back pain? *Spine* 1986; 11(5): 468-75.
 25. Styf J. Pressure in the erector spinae muscle during exercise. *Spine* 1987; 12(7): 675-9.
 26. Konno S, Kikuchi S, Nagaosa Y. The relationship between intramuscular pressure of the paraspinal muscles and low back pain. *Spine* 1994; 19(19): 2186-9.
 27. Kovacs KM, Marras WS, Litsky AS, Gupta P, Ferguson SA. Localized oxygen use of healthy and low back pain individuals during controlled trunk movement. *J Spinal Disord* 2001; 14(2): 150-8.
 28. Kell RT, Bhambhani Y. In vivo erector spinae muscle blood volume and oxygenation measures during repetitive incremental lifting and lowering in chronic low back pain participants. *Spine* 2006; 31(22): 2630-7.
 29. Kramer M, Dehner C, Völker HU, et al. Intramuscular pressure, tissue oxygenation and EMG fatigue measured during isometric fatigue-inducing contraction of the multifidus muscle. *Eur Spine J* 2005; 14(6): 578-85.
 30. Dupeyron A, Lecocq J, Vautravers P, Pélissier J, Perrey S. Muscle oxygenation and intramuscular pressure related to posture and load in back muscles. *Spine J* 2009; 9(9): 754-9.
 31. Sakai Y, Matsuyama Y, Nakamura H, et al. The effect of muscle relaxant on the paraspinal muscle blood flow: A randomized controlled trial in patients with chronic low back pain. *Spine* 2008; 33(6): 581-87.
 32. Konno S, Hayashino Y, Fukuhara S, et al. Development of a clinical diagnosis support tool to identify patients with lumbar spinal stenosis. *Eur Spine J* 2007; 16(11): 1951-7.
 33. Tsutsui S, Kagotani R, Yamada H, et al. Can decompression surgery relieve low back pain in patients with lumbar spinal stenosis combined with degenerative lumbar scoliosis? *Eur Spine J* 2013; 22(9): 2010-4.
 34. Jones AD, Wafai AM, Easterbrook AL. Improvement in low back pain following spinal decompression: observational study of 119 patients. *Eur Spine J* 2014; 23(1): 135-41.
 35. Bogduk N, Wilson AS, Tynan W. The lumbar dorsal rami. *J Anatomy* 1982; 134(2): 383-97.
 36. Macintosh JE, Valencia F, Bogduk N, Munro RR. The morphology of the human lumbar multifidus. *Clin Biomech* 1986; 1(4): 196-204.

Spine Surgery and Related Research is an Open Access article distributed under the Creative Commons Attribution - NonCommercial - NoDerivatives 4.0 International License. To view the details of this license, please visit (<https://creativecommons.org/licenses/by-nc-nd/4.0/>).