

# Asymptomatic Giant Aneurysm of the Left Anterior Descending Coronary Artery: A Case Report and Review of the Literature

Marija Bjelobrk, MD, PhD<sup>1,2\*</sup>, Slobodan Dodic, MD, PhD<sup>1,2</sup>, Tatjana Miljkovic, MD, PhD<sup>1,2</sup>, Golub Samardzija, MD, PhD<sup>1,2</sup>, Ilija Bjeljic, MD<sup>2</sup>, Dragana Dabovic, MD<sup>2</sup>, Biljana Dodic, MD, PhD<sup>3</sup>, Milenko Rosic, MD, PhD<sup>1,2</sup>, Mila Kovacevic, MD, PhD<sup>1,2</sup>, Aleksandar Redzek, MD, PhD<sup>1,2</sup>, Miklos Fabri, MD<sup>2</sup>

<sup>1</sup>University of Novi Sad, Faculty of Medicine, Novi Sad, Serbia.

<sup>2</sup>Institute of Cardiovascular Diseases Vojvodina, Clinic of Cardiology, Sremska Kamenica, Serbia.

<sup>3</sup>Educons University, Sremska Kamenica, Serbia.

Received 23 December 2019; Accepted 26 July 2020

## Abstract

The most common cause of coronary artery aneurysms is atherosclerosis, which is associated with over 50% of all aneurysms diagnosed in adults. Although patients can be asymptomatic throughout their lives, giant coronary artery aneurysms can manifest themselves as myocardial infarction, aneurysmal rupture, and sudden cardiac death as well. Herein, we describe an asymptomatic patient with numerous risk factors and a positive cardiopulmonary exercise test who was admitted to the cardiology clinic for coronary angiography. A giant coronary artery aneurysm (3.0×2.0 cm in diameter) in the left anterior descending coronary artery and significant stenosis in both left and right coronary arteries were found. After discussing possible treatment options, the hospital's heart team recommended the surgical resection of the aneurysm and double coronary artery bypass graft. Four years after the cardiac surgery, at the time of writing the current manuscript, the patient is still in good condition and with no symptoms.

*J Teh Univ Heart Ctr 2020;15(4):178-182*

**This paper should be cited as:** Bjelobrk M, Dodic S, Miljkovic T, Samardzija G, Bjeljic I, Dabovic D, Dodic B, Rosic M, Kovacevic M, Redzek A, Fabri M. Asymptomatic Giant Aneurysm of the Left Anterior Descending Coronary Artery: A Case Report and Review of the Literature. *J Teh Univ Heart Ctr 2020;15(4):178-182.*

**Keywords:** Coronary aneurysm; Atherosclerosis; Cardiac surgical procedures; Prognosis

## Introduction

Coronary artery aneurysms (CAAs) can be caused by atherosclerosis (accounting for 50% in adults), Kawasaki disease, polyarteritis nodosa, systemic lupus erythematosus, infection, trauma, dissection, angioplasty, and congenital

malformations.<sup>1</sup> Behçet's disease is also one of the possible causes of CAAs,<sup>2</sup> as are cocaine and the abuse of other drugs. Nonetheless, giant CAAs are very rare in that they occur in 0.02% of the general population.<sup>3</sup> By definition, giant CAAs are a localized luminal dilatation measuring quadruple the reference vessel diameter or diameters greater

\*Corresponding Author: Marija Bjelobrk, Teaching Assistant, University of Novi Sad, Faculty of Medicine Novi Sad, Serbia, Clinic of Cardiology, Institute of Cardiovascular Diseases Vojvodina, Put dr Goldmana 4, 21204 Sremska Kamenica, Serbia. Tel: +381 621704376. Fax: +381 214805700. E-mail: marija.bjelobrk@mf.uns.ac.rs.



than 8 mm in absolute values.<sup>4</sup> The therapy itself of giant CAAs, similar to the prognosis, is often a matter of dispute. If they are smaller in size, CAAs are likely to be resolved via percutaneous procedures; and if they are larger in dimension, cardiac surgery is the optimal solution. Since the therapy is still controversial, the optimal solution to this problem, to a major degree, depends on the experience and equipment of the hospital's heart team. In light of the aforementioned points, as well as the clinical presentation of our patient, prognostic factors, and possible complications, our case endorses the merits of a thorough clinical examination in an asymptomatic, albeit high-risk, patient managed with safe and effective old-fashioned cardiac surgery in the era of modern percutaneous coronary techniques.

## Case Report

Routine clinical assessments of a 76-year-old Caucasian man were performed in January 2015. The patient had several risk factors such as type 2 diabetes mellitus, arterial hypertension, type IIb hyperlipoproteinemia, and smoking without subjective symptoms. The patient's age and gender, combined with these risk factors, according to the Heart Score Chart for High-Risk Countries,<sup>5</sup> suggested a significant incidence (11%) of a fatal cardiovascular disease in the 10-year follow-up period. The pretest probability for the presence of myocardial ischemia was within the moderate range (54%).

Echocardiography was performed and indicated a preserved left ventricular ejection fraction and no valvular involvement. Mild concentric left ventricular hypertrophy (interventricular septal thickness at end-diastole and posterior wall thickness at end-diastole=12 mm) and first-degree diastolic dysfunction ( $E/e'_{av}=1.6$ ) were found. Owing to an intermediate probability of coronary artery disease, the patient underwent cardiopulmonary exercise testing on a cycle ergometer according to a 10-W ramp protocol. He reached almost a peak exercise respiratory exchange ratio (1.08), a peak heart rate of 98% of the age-predicted value, and a peak  $VO_2$  level of 19 mL/kg/min (80% of  $VO_2$  predicted). Cardiopulmonary exercise testing demonstrated good functional capacity but at peak load, ST-T segment changes occurred (horizontal ST-T segment depression up to -1.5 mm in  $V_4-V_6$  electrocardiography leads). Based on the electrocardiographic findings, the test was labeled as positive for myocardial ischemia.

Two months later, the patient was admitted for a scheduled selective coronary angiographic procedure, which showed the presence of a giant CAA (3.0×2.0 cm) in the proximal-medial segment, significant stenosis (>70%) in the proximal segment of the left anterior descending coronary artery, and significant stenosis in the medial-distal segment of the right coronary artery and its final branches (Figure 1).

The medical documentation was presented to the hospital's heart team members, who decided to perform surgical resection in the same hospitalization given the potential risk of not only aneurysmal rupture but also the future

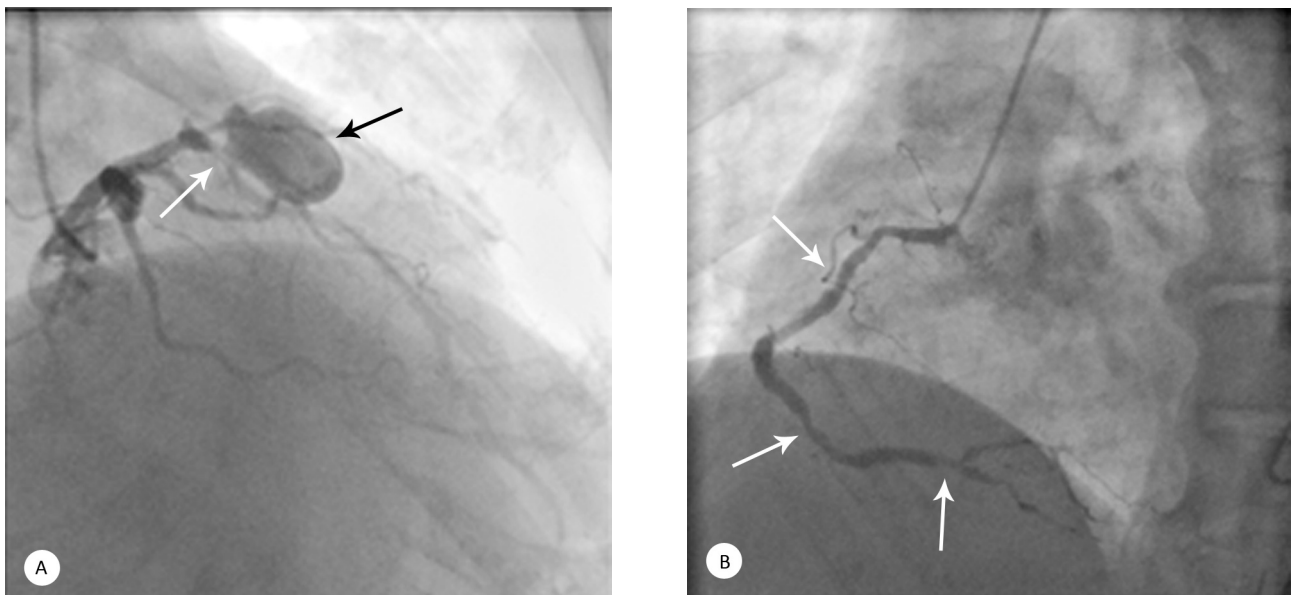


Figure 1. (Left) Selective coronary angiography of the left coronary artery in the right anterior oblique-cranial view, showing a giant coronary aneurysm (3.0×2.0 cm, black arrows) in the medial segment and significant (>70%) stenosis in the proximal segment of the left anterior descending coronary artery (white arrows)

(Right) Selective coronary angiography of the right coronary artery in the left anterior oblique view, showing significant (>70%) stenosis (white arrows) in the distal segment of the right coronary artery as well as its final branches (posterior descending artery and the posterolateral artery)

development of a serious ischemic coronary event. Double coronary artery bypass graft surgery (the right and left anterior descending coronary arteries) and aneurysmectomy, followed by venous patch plasty, were performed (Figure 2).

Fragments of the resected aneurysm were sent for histopathology examination (Figure 3), which confirmed the presence of a giant CAA with all the features of atherosclerosis in the blood vessel wall and the clinical suspicion of an atherosclerotic giant CAA. Further in-hospital course and clinical follow-up were complication-free.

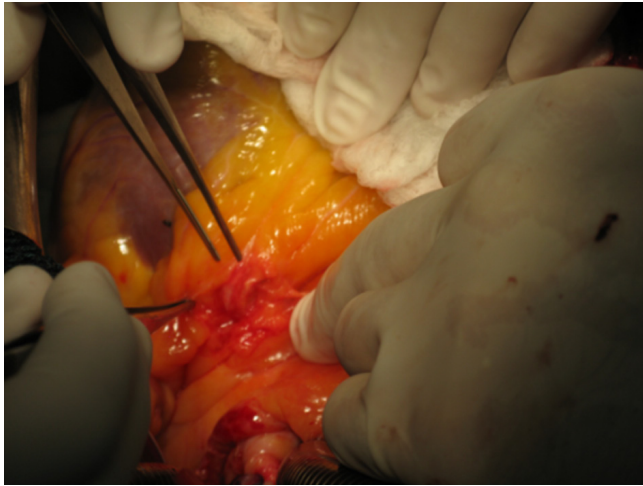


Figure 2. Preparation of the giant coronary aneurysm in the medial segment of the left anterior descending coronary artery during cardiac surgery

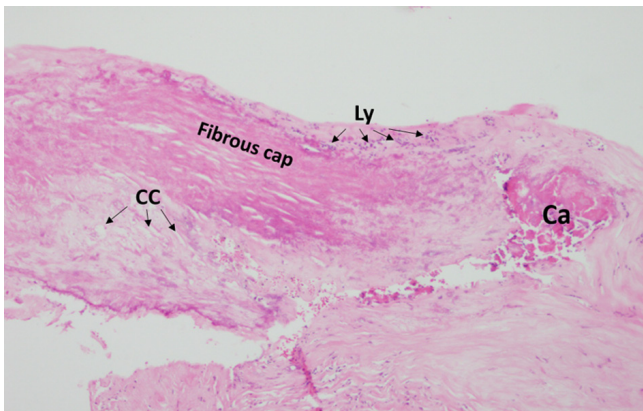


Figure 3. Microscopic findings (hematoxylin-eosin, magnification 40 $\times$ ), showing that the material consists of tissue fragments of the wall of the aneurysm with severe atherosclerotic changes, extensive fibrosis, cholesterol crystals (CC), focal calcification (Ca), and focal lymphocyte infiltrate (Ly)

After 8 months, a permanent pacemaker (Effecta DR, VDD mode, BIOTRONIK) was implanted due to syncope and conduction disorders observed during 24-hour Holter monitoring (Mobitz II). Four years later, at the time of writing the present manuscript, the patient is in good condition, with no symptoms, and is capable of handling physical strains

without problems.

## Discussion

Localized minor extensions of the coronary artery (dilated coronary artery), greater localized extensions (CAAs), and multiple sequential extensions (coronary artery aneurysms) are not very rare (0.3%–5%) in the general population.<sup>3</sup> Although the definitions of CAAs are somewhat different, CAAs can be considered relevant if there is a minimum extension in diameter of 1.5-fold compared with the adjacent normal segments. A giant CAA is a very rare finding (0.02% of the general population) and is defined as a diameter that exceeds that of the coronary artery by at least 4-fold or as a diameter that is at least 8.0 mm in absolute values.<sup>4</sup> The first pathological descriptions of CAAs came from the works of Morgagni (18th century),<sup>6</sup> while the first clinical presentation was mentioned in the works of Bourgon (19th century).<sup>7</sup>

There are significant geographical variations in the incidence of CAAs, underscoring the importance of genetic and environmental factors in their formation. In a study on 302 patients with Kawasaki arteritis, the incidence of CAAs was 10.3%, 6.9%, and 1.2%, respectively, in Asian, Caucasian, and African patients.<sup>8</sup> In a study conducted in India, the incidence of CAAs was significantly higher and accounted for between 10% and 12%, with an emphasis on genetic susceptibility and environmental impacts.<sup>9</sup> The incidence of CAAs is higher in males than in females (2.2% vs 0.5%). While CAAs can be seen at any age, cases associated with atherosclerosis usually occur later in life than those with congenital or inflammatory etiologies.<sup>10</sup> The right coronary artery is most often affected by aneurysms, with an incidence rate ranging between 40% and 70%. Depending on the study scrutinized, the left circumflex artery is affected in 23.4% of cases, while the incidence in the left anterior descending coronary artery is 32.3%.<sup>11</sup> The presence of CAAs in all 3 blood vessels or the common trunk (left main) is an extremely rare condition. CAAs of atherosclerotic and inflammatory etiologies are usually multiple and involve more than 1 coronary artery, while those with traumatic, dissected, and congenital etiologies usually involve only 1 coronary artery.<sup>12</sup> The most common cause of CAAs is atherosclerosis, which is associated with over 50% of all aneurysms diagnosed in adults.<sup>4</sup> Kawasaki arteritis is the most common cause of CAAs in children and the second most common cause in adults. CAAs occur in about 10% to 15% of patients during the acute phase of Kawasaki arteritis.<sup>13</sup> Takayasu arteritis is the primary systemic vasculitis that affects large blood vessels, mainly the aorta and its branches; and in fewer than 10% of such patients, CAAs are present.<sup>14</sup> Vasculitis in systemic lupus erythematosus, polyarteritis nodosa, and rheumatoid vasculitis can lead to the appearance of CAAs.<sup>4</sup>



The disorders of the connective tissue such as Marfan and vascular Ehlers–Danlos syndromes can also result in the occurrence of CAAs.<sup>15</sup> Bacterial infections, mycobacteria and fungi, syphilis, Lyme disease, septic embolism, and HIV infection are also possible causes of CAAs. Some drugs such as cocaine, protease inhibitors, and amphetamines can further potentiate the development of CAAs. Furthermore, there are individuals with a genetic predisposition to CAAs, which is usually associated with the 9p21 locus. This locus is also associated with an increased risk of developing aneurysms of the abdominal aorta and intracranial arteries.<sup>16</sup>

Even today, the prognosis of CAAs is still controversial.<sup>17</sup> CAAs may cause myocardial ischemia, coronary artery rupture, sudden cardiac death due to cardiac tamponade, local coronary thrombosis, and fistulae between the aneurysm and some of the cavities of the heart. The prognosis of these patients depends on the presence of possible complications. On the other hand, the aneurysm can remain asymptomatic and without any complications during the patient's life. The therapy itself, similar to the prognosis, is often a matter of dispute. In patients with Kawasaki disease, the cornerstone of the therapy is intravenous immunoglobulin. This therapy significantly reduces the percentage of CAAs in the general population. Recently, there have been attempts to treat CAAs with monoclonal antibodies (infliximab) against both tumor necrosis factor-alpha and interleukin-6 receptors (tocilizumab).<sup>18</sup> In asymptomatic elderly patients with atherosclerotic CAAs, some authors advocate conservative drug treatment with the administration of an anticoagulant or antiplatelet agents.<sup>19</sup> On the other hand, some authors recommend 3 types of invasive techniques: interventional obliteration with polytetrafluoroethylene (PTFE)-covered stents, especially in smaller CAAs (6–10 mm),<sup>20</sup> cardiac surgery ligature, or cardiac surgery resection.<sup>21</sup> A good solution, not least when the anatomy is adequate, is to use covered stents to isolate an aneurysm in order to prevent complications such as distal embolization. However, the disadvantages of covered stents such as restenosis and thrombosis could be overcome with endovascular coiling, although it takes skilled personnel due to the risk of aneurysmal rupture. Surgery is a good alternative, particularly if there is a giant CAA with a high risk of rupture and coexisting atherosclerosis. Generally speaking, the strategy for the treatment of giant CAAs should be individually tailored to each patient taking into account the clinical presentation; the size, location, and over-time expansion of the aneurysm, and the presence of the coexisting atherosclerosis of a giant CAA. The strategy also depends on the individual experience of the medical center in treating this anomaly.

## Conclusion

Giant CAAs occur very rarely, in less than 0.02% of the

general population. The treatment strategy is still open to debate and depends on the size and etiology of the aneurysm. In younger age, giant CAAs are usually a consequence of coronary vasculitis (Kawasaki disease) and should be treated with medical therapy. In adults, atherosclerosis is the most common cause of CAAs. Aneurysms that are less than 10 mm in diameter should be resolved via percutaneous procedures. Still, the optimal solution for giant CAAs associated with atherosclerosis is surgical treatment.

## Acknowledgments

The authors appreciate the technical assistance of Ms Ljiljana Pupic.

## References

1. Pahlavan PS, Niroomand F. Coronary artery aneurysm: a review. *Clin Cardiol* 2006;29:439-443.
2. Ozeren M, Dogan OV, Dogan S, Yucel E. True and pseudo aneurysms of coronary arteries in a patient with Behçet's disease. *Eur J Cardiothorac Surg* 2004;25:465-467.
3. Nichols L, Lagana S, Parwani A. Coronary artery aneurysm: a review and hypothesis regarding etiology. *Arch Pathol Lab Med* 2008;132:823-828.
4. Kato H, Sugimura T, Akagi T, Sato N, Hashino K, Maeno Y, Kazue T, Eto G, Yamakawa R. Long-term consequences of Kawasaki disease. A 10- to 21-year follow-up study of 594 patients. *Circulation* 1996;94:1379-1385.
5. Conroy RM, Pyörälä K, Fitzgerald AP, Sans S, Menotti A, De Backer G, De Bacquer D, Ducimetière P, Jousilahti P, Keil U, Njølstad I, Oganov RG, Thomsen T, Tunstall-Pedoe H, Tverdal A, Wedel H, Whincup P, Wilhelmsen L, Graham IM, SCORE project group. Estimation of ten-year risk of fatal cardiovascular disease in Europe: the SCORE project. *Eur Heart J* 2003;24:987-1003.
6. Morgagni GB. Founders of Modern Medicine: Giovanni Battista Morgagni (1682-1771). *Med Library Hist J* 1903;1:270-277.
7. Scott DH. Aneurysm of the coronary arteries. *Am Heart J* 1948;36:403-421.
8. Porcalla AR, Sable CA, Patel KM, Martin GR, Singh N. The epidemiology of Kawasaki disease in an urban hospital: does African American race protect against coronary artery aneurysms?. *Pediatr Cardiol* 2005;26:775-781.
9. Sharma SN, Kaul U, Sharma S, Wasir HS, Manchanda SC, Bahl VK, Talwar KK, Rajani M, Bhatia ML. Coronary arteriographic profile in young and old Indian patients with ischaemic heart disease: a comparative study. *Indian Heart J* 1990;42:365-369.
10. Doustkami H, Maleki N, Tavosi Z. Left Main Coronary Artery Aneurysm. *J Teh Univ Heart Ctr* 2016;11:41-45.
11. Jha NK, Ouda HZ, Khan JA, Eising GP, Augustin N. Giant right coronary artery aneurysm- case report and literature review. *J Cardiothorac Surg* 2009;4:18.
12. Mata KM, Fernandes CR, Floriano EM, Martins AP, Rossi MA, Ramos SG. Coronary artery aneurysms: an update. In: Lakshmanadoss U, ed. *Novel Strategies in Ischemic Heart Disease*. Rijeka: InTech; 2012. p. 381–404.
13. Dajani AS, Taubert KA, Gerber MA, Shulman ST, Ferrieri P, Freed M, Takahashi M, Bierman FZ, Karchmer AW, Wilson W. Diagnosis and therapy of Kawasaki disease in children. *Circulation* 1993;87:1776-1780.
14. Panja M, Sarkar C, Kar AK, Kumar S, Mazumder B, Roy S, Sinha DP, Sarkar NC. Coronary artery lesions in Takayasu's

- arteritis--clinical and angiographic study. *J Assoc Physicians India* 1998;46:678-681.
15. Melloy KT, Freeman LJ, Baldock C, Jowitt TA, Siegler V, Raynal BDE, Cain ST, Wess TJ, Shuttleworth CA, Kiely CM. Marfan syndrome-causing mutations in fibrillin-1 result in gross morphological alterations and highlight the structural importance of the second hybrid domain. *J Biol Chem* 2006;281:31854-31862.
  16. Helgadóttir A, Thorleifsson G, Magnusson KP, Grétarsdóttir S, Steinthorsdóttir V, Manolescu A, Jones GT, Rinkel GJE, Blankensteijn JD, Ronkainen A, Jääskeläinen JE, Kyo Y, Lenk GM, Sakalihasan N, Kostulas K, Gottsäter A, Flex A, Stefansson H, Hansen T, Andersen G, Weinsheimer S, Borch-Johnsen K, Jorgensen T, Shah SH, Quyyumi AA, Granger CB, Reilly MP, Austin H, Levey AI, Vaccarino V, Palsdóttir E, Walters GB, Jonsdóttir T, Snorradóttir S, Magnúsdóttir D, Gudmundsson G, Ferrell RE, Sveinbjörnsdóttir S, Hernesniemi J, Niemelä M, Limet R, Andersen K, Sigurdsson G, Benediktsson R, Verhoeven ELG, Teijink JAW, Grobbee DE. The same sequence variant on 9p21 associates with myocardial infarction, abdominal aortic aneurysm and intracranial aneurysm. *Nat Genet* 2008;40:217-224.
  17. Befeler B, Aranda MJ, Embi A, Mullin FL, El-Sherif N, Lazzara R. Coronary artery aneurysms: study of the etiology, clinical course and effect on left ventricular function and prognosis. *Am J Med* 1977;62:597-607.
  18. Nozawa T, Imagawa T, Ito S. Coronary-Artery Aneurysm in Tocilizumab-Treated Children with Kawasaki's Disease. *N Engl J Med* 2017;377:1894-1896.
  19. Khan IA, Dogan OM, Vasavada BC, Sacchi TJ. Nonatherosclerotic aneurysm of the left circumflex coronary artery presenting with accelerated angina pectoris: response to medical management--a case report. *Angiology* 2000;51:595-598.
  20. Eshthardi P, Cook S, Moarof I, Triller HJ, Windecker S. Giant coronary artery aneurysm: imaging findings before and after treatment with a polytetrafluoroethylene-covered stent. *Circ Cardiovasc Interv* 2008;1:85-86.
  21. Unic D, Mihaljevic T, Leacche M, Gasparovic H, Albert MA, Byrne JG. Surgical treatment of a large left-main coronary artery aneurysm. *Thorac Cardiovasc Surg* 2004;52:230-231.