

# Heart transplantation in the era of COVID-19 pandemic: delirium, post-transplant depression, and visitor restrictions; the role of liaison and inpatient psychosomatic treatment—a case report

Monika Sadlonova <sup>1,2,3,4\*</sup>, Birgit Gerecke <sup>1,5</sup>, Christoph Herrmann-Lingen <sup>2,3</sup>, and Ingo Kutschka <sup>1,3</sup>

<sup>1</sup>Department of Cardiovascular and Thoracic Surgery, University of Göttingen Medical Center, Robert-Koch-Str. 40, 37075 Göttingen, Germany; <sup>2</sup>Department of Psychosomatic Medicine and Psychotherapy, University of Göttingen Medical Center, Robert-Koch-Str. 40, 37075 Göttingen, Germany; <sup>3</sup>German Center for Cardiovascular Research (DZHK), Partner Site Göttingen, Germany; <sup>4</sup>Department of Psychiatry, Massachusetts General Hospital, Harvard Medical School, Boston, USA; and <sup>5</sup>Department of Cardiology and Pneumology, University of Göttingen Medical Center, Göttingen, Germany

Received 12 March 2021; first decision 3 June 2021; accepted 31 August 2021; online publish-ahead-of-print 9 September 2021

## Background

Heart transplant recipients show a high risk of developing major depression with an increased risk of post-transplant morbidity and mortality. Heart transplant specialists and patients face unprecedented challenges during the COVID-19 pandemic, which have enormous clinical implications such as the increased risk of COVID-19 as well as visitor restrictions with social isolation during the post-transplant inpatient treatment.

## Case summary

We present a case of a 64-year-old woman with end-stage heart failure caused by non-compaction cardiomyopathy who received an orthotopic heart transplant (OHT) without any intra-operative complications. Post-operatively, she showed acute psychotic symptoms in the intensive care unit (ICU) with improvement after switching intravenous tacrolimus treatment to an oral intake. Furthermore, the patient developed severe depressive symptoms with malnutrition and had a prolonged hospitalization. Standard medical care was complemented by intensive psychocardiological treatment to overcome the crisis.

## Conclusion

High complexity of the post-transplant management after OHT underlines the importance of multidisciplinary teamwork, involving heart transplant specialists and allied mental health professionals. This collaboration led to an excellent long-term result. Facing the COVID-19 pandemic, the hospital visitor policies may be scrutinized, carefully looking at the role of social isolation, post-operative experience in the ICU, and medical complications after OHT.

## Keywords

Heart transplantation • Post-transplant depression • Delirium • Visitor restrictions • COVID-19 pandemic • Case report

\* Corresponding author. Tel: +49-551-3966001, Fax: +49-551-3966002, Email: [monika.sadlonova@med.uni-goettingen.de](mailto:monika.sadlonova@med.uni-goettingen.de)

Handling Editor: Soren Skott-Schmiegelow

Peer-reviewers: Emilia D'Elia and Giulia Elena Mandoli

Compliance Editor: Matteo Parollo

Supplementary Material Editor: Anthony Paulo Sunjaya

© The Author(s) 2021. Published by Oxford University Press on behalf of the European Society of Cardiology.

This is an Open Access article distributed under the terms of the Creative Commons Attribution-NonCommercial License (<https://creativecommons.org/licenses/by-nc/4.0/>), which permits non-commercial re-use, distribution, and reproduction in any medium, provided the original work is properly cited. For commercial re-use, please contact [journals.permissions@oup.com](mailto:journals.permissions@oup.com)

## Learning points

- Early identification and treatment of acute psychotic symptoms and severe depression may have an impact on post-operative complications and length of hospital stay.
- Complexities of the post-transplant management after orthotopic heart transplant (OHT) show the importance of multidisciplinary teamwork involving heart failure and transplant specialists with allied mental health professionals, which may improve long-term results.
- Facing the COVID-19 pandemic, the hospital visitor policies should be reviewed carefully, looking at the role of social isolation, post-operative experience in the intensive care unit, and medical complications after OHT.

## Primary specialties involved other than cardiology

Psychosomatic Medicine and Psychotherapy, Cardiovascular Surgery.

## Introduction

Orthotopic heart transplantation (OHT) is an established treatment for patients with end-stage heart failure. During the coronavirus disease 2019 (COVID-19) pandemic, heart transplant specialists, and patients face unprecedented challenges, which have profound implications for patients on the waiting list and transplant recipients.<sup>1</sup>

To prevent an allograft rejection, immunosuppression with calcineurin inhibitors, such as tacrolimus, should be given to heart transplant recipients. However, calcineurin inhibitors are considered to be one of the main causes of neurological complications and acute psychotic disorder (APD) in transplant patients.<sup>2</sup> The use of corticosteroids may be an additional risk factor for the development of APD, and up to 14% of transplant recipients using corticosteroids manifest psychotic symptoms.<sup>3</sup>

In patients on a heart transplant waiting list, the prevalence of depressive disorders is almost 24% and further deterioration of depressive symptoms during the waitlisted period has been reported.<sup>4</sup> Pre-existing depression can persist into the post-transplant period and the estimated prevalence of depression after OHT amounts to 20–30%.<sup>5,6</sup> Depression after OHT seems to be a strong predictor of poor medication adherence and higher rates of hospitalization.<sup>4,7</sup> Moreover, depressed patients were 3.5 times more likely to be non-adherent to medication and showed a higher incidence of the first-year hospitalization, as well as higher numbers of admissions for infections.<sup>7</sup> Furthermore, depressed patients have an increased risk of mortality after OHT.<sup>8</sup> Early identification and treatment of depression in patients after OHT can lead to post-operative outcomes similar to non-depressed patients and decrease hospital utilization.<sup>9,10</sup> Dew et al.<sup>11</sup> recommended for the psychosocial evaluation of adult cardiothoracic transplant candidates, that the presence of the evaluator or their delegate is important during the selection meetings in order to discuss the psychosocial status and treatment strategies such as evidence-based interventions (both, pharmacological and

psychotherapeutic) in candidates with mental comorbidities. Bruschi et al.<sup>10</sup> recommended a multidisciplinary team approach to obtain excellent long-term results.

## Timeline

### Presentation

Indication	Non-compact cardiomyopathy with severely reduced systolic left ventricular function (ejection fraction = 10%), and NYHA Class III to ambulatory IV, INTERMACS IV to V was listed for heart transplantation in January 2020. In the psychosocial assessment before listing for orthotopic heart transplantation (OHT), moderate depressive symptoms were diagnosed and the patient was treated in the interdisciplinary psychocardiological outpatient clinic with psychotherapy and pharmacologic treatment with sertraline, showing an improvement of the depressive symptoms.
Day 0–OHT	On 9th March 2020, she received an orthotopic heart transplant without any intra-operative complications.
Day 2	Extubation with stable haemodynamics and good oxygenation.
Day 8	Thoracoscopy was performed for haematoma evacuation. In the next step, X-ray control showed no thoracic haematoma progression.
Day 8	Visits of patient's relatives were prohibited during the COVID-19 pandemic especially in patients with high risk of infection or immunosuppression from one day to the next.
Day 5–10	Acute psychotic symptomatic/productive delirium with optic hallucinations, disorientation, delusional symptoms, and agitation, possibly facilitated by the initial intravenous administration of tacrolimus which was then switched to oral administration. Treatment with haloperidol and quetiapine medication. On Day 10, the quetiapine medication could be discontinued. Daily treatment by the liaison psychosomatic consultant of the Department of Cardiovascular and Thoracic Surgery. Daily phone calls or video calls between the patient and her family were facilitated.
Day 28	Transvenous myocardial biopsy and an implantation of a dialysis catheter via the internal right jugular vein were performed.
Day 32	Diagnosis of severe post-transplant depression (major depressive disorder).

*Continued*

**Continued****Presentation**

Day 38	Biological left arm loop (Omniflow II, 6 mm) with connection to A. radialis and V. cephalica was implanted.
Day 70	Admission to the rehabilitation hospital.
Day 98	Discharge home from the rehabilitation hospital.
Day 123	Admission to the Department of Cardiovascular and Thoracic Surgery with the initiation of parenteral nutrition and dialysis treatment because of a strong weight loss at home up to a body mass index (BMI) of 15.3 kg/m <sup>2</sup> . The patient suffered from frequent vomiting and had severe diarrhoea, with deterioration of renal function requiring dialysis.
Day 130	Transfer to the inpatient psychocardiology ward at the Department for Psychosomatic Medicine and Psychotherapy in our Heart Centre.
Day 164	Discharge home in stable haemodynamic conditions and improved physical capacity, reduced depressive symptoms, and BMI of 18.1 kg/m <sup>2</sup> .

## Case presentation

The 64-year-old woman (*Timeline, Figure 1*) had been treated for heart failure with severely reduced ejection fraction (EF), caused by cardiomyopathy diagnosed after delivery of twins many years before. Furthermore, an atrial septal defect was closed by transcatheter intervention in 2010 and severe mitral valve insufficiency was treated with MitraClip® in 2018. In 2010, an implantable cardioverter-defibrillator was implanted for primary prophylaxis. In 2019, the patient reported being limited by shortness of breath and weakness. She received a heart failure guideline-directed pharmacological treatment, including bisoprolol, spironolactone, valsartan/sacubitril, and torsemide. In addition, the patient was treated with aspirin, pantoprazole, levothyroxine, and iodide. After a further decline of the EF to 10% with increased levels of NT-proBNP, as well as the progression of somatic symptoms, evaluation for an OHT was started in November 2019.

A psychosocial assessment of the evaluation for an OHT revealed moderate depression symptoms with increased scores for depressive symptoms in the Hospital Anxiety and Depression Scale (HADS-D = 14, the cut-off score is  $\geq 8$ ). After a detailed review of psychosocial aspects, the patient was not considered to be too mentally weak for an OHT. Nevertheless, following the psychosomatic recommendation, the patient was treated in our interdisciplinary psychocardiological outpatient clinic between November 2019 and February 2020, where she received psychotherapy and the antidepressant sertraline, a selective serotonin reuptake inhibitor. This led to an improvement of the depressive symptoms before OHT, and her eligibility for placement on a heart transplant waiting list was confirmed. Two of the outpatient appointments were made in the

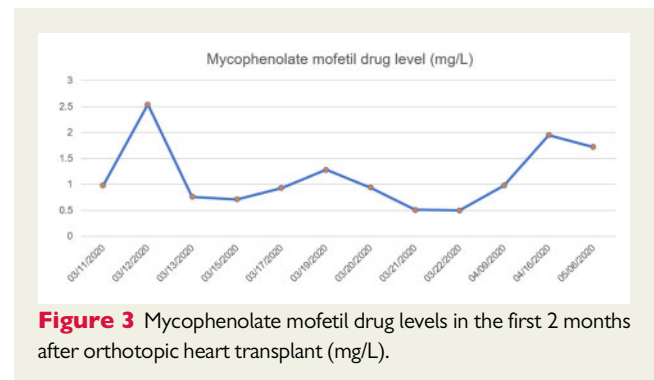
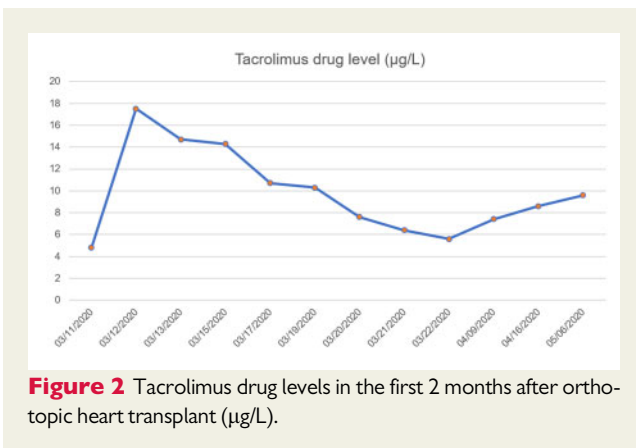
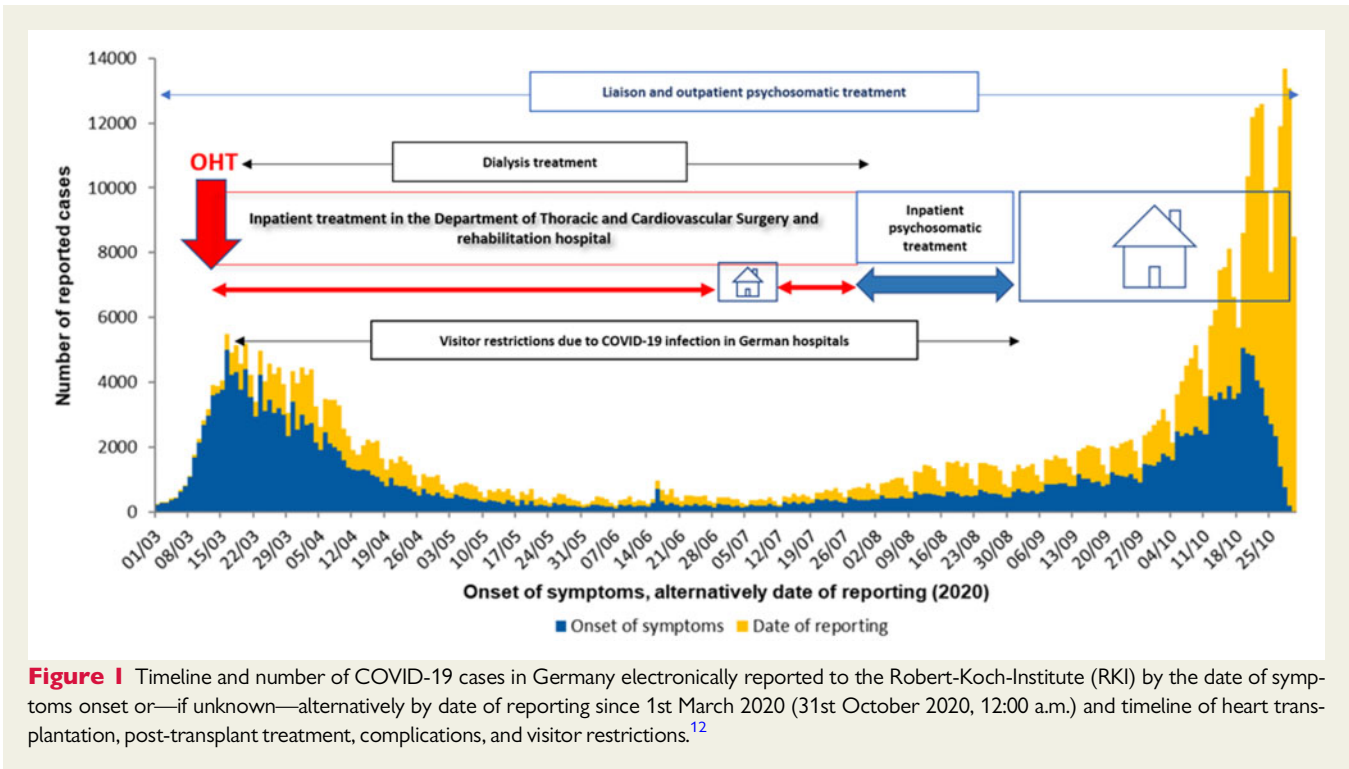
presence of the patient's husband with a focus on psychoeducation and emotional expression. During the time on the waiting list, the patient was afraid of potential complications, especially graft rejection.

On 9th March 2020, she received an OHT without any intra-operative complications. On Day 2, the patient could be extubated in stable cardiac and pulmonary conditions. Eight days after the OHT, a thoracoscopy was performed for haematoma evacuation. In the next step, an X-ray control showed no residual thoracic haematoma and an echocardiography revealed a normal global systolic function. We performed drug level-controlled immunosuppression with tacrolimus, mycophenolate mofetil, and prednisolone.

On Day 8, the visitor policies were changed in hospitals and nursing homes with visitor restrictions due to the transmission of the severe acute respiratory syndrome coronavirus 2 (SARS-CoV-2 or COVID-19) during the first wave of the COVID-19 pandemic, especially in patients with a high risk of COVID-19, including patients with immunosuppression. Overall, the German hospitals began to shut their doors to visitors and changed the visitor policy for several months following the decree of the Lower Saxony Ministry of Social Affairs, Health, and Equality. There were exceptions in the children's departments, in palliative care, and in the case of life-threatening complications in the intensive care units. In this case, with ongoing restrictions for the family to come to the ward, the team discussed the ethical aspects of the regulations. The fear of infection of the immunosuppressed patient and concurrently her need for familiar support were weighed against each other. In the interest of protecting the patient's life from a potentially lethal infection, the regulations prevailed in the decision.

During post-operative days 5 through 10, while on the intensive care unit (ICU) treatment, the patient developed delirium with acute psychotic symptoms such as optic hallucinations, disorientation, delusions, and agitation. At that time, she was treated intravenously with tacrolimus. The initial drug level of tacrolimus was measured to be 4.8 µg/L on Day 1 after OHT with an increase to 17.5 µg/L on Day 2, and a decrease to 14–15 µg/L over the following two days. Due to the patient's elevated tacrolimus drug levels and productive delirium, the tacrolimus administration was switched to an oral intake, reducing the tacrolimus drug level to 10 µg/L on Day 7 and 7.6 µg/L on Day 10 after OHT (*Figure 2*). The mycophenolate mofetil drug levels tended to be normal to low in drug monitoring (*Figure 3*). In addition, the patient initially received haloperidol. Under this medication, she developed pronounced early dyskinesia, so it was stopped immediately and biperiden was administered. Quetiapine was added complementary. There was a rapid improvement of the psychotic symptoms over the next two days. On Day 10, the quetiapine medication could be stopped. During the ICU treatment, the patient was seen daily by the psychosomatic liaison consultant (*Table 1*) of the Department of Cardiovascular and Thoracic Surgery who knew the patient from the pre-transplant psychotherapeutic treatment. Additionally, the patient's family was informed about the treatment on a daily basis and phone calls or video calls between the patient and her family were arranged.

Unfortunately, high dose post-operative immunosuppression led to further deterioration of pre-existing renal dysfunction and resulted in anuria with the need for dialysis. On Day 28, a transvenous myocardial biopsy and an implantation of a dialysis catheter via the



internal right jugular vein were performed. On Day 38, a biological left arm loop with connection to A. radialis and V. cephalica was implanted. On Day 40, the left upper arm shunt had to be revised and finally removed, due to recurrent shunt occlusion.

Over the course of the next few days, the patient developed a severe depressive episode, requiring frequent (nearly daily) supportive psychosomatic liaison treatments (Table 1). Treatment focused on strengthening resources, disease and transplant acceptance, coping with acute somatic events such as dialysis treatment or delirium, and separation from her family during the COVID-19 pandemic. Furthermore, the patient was motivated to cooperate with the therapeutic team concerning mobilization and nutrition. She could be mobilized and cardiopulmonary conditions stayed stable. On Day 70, we transferred the patient to a qualified rehabilitation hospital.

During rehabilitation, the renal function improved progressively and the dialysis treatment could be terminated.

Two weeks after being discharged from the rehabilitation hospital, a substantial weight loss to a body mass index (BMI) of  $15.3 \text{ kg/m}^2$  was observed. The patient suffered from frequent vomiting and had severe diarrhoea, with deterioration of renal function again requiring dialysis. She was admitted to our Department of Cardiovascular and Thoracic Surgery with the initiation of parenteral nutrition and dialysis treatment, which could be paused as the kidney function recovered. During the next three weeks, the patient's weight increased to a BMI of  $17.5 \text{ kg/m}^2$  under parenteral nutrition. We provided several stool analyses (for parasites, viruses, or bacteria, and occult bleeding), as well as a test on *Helicobacter pylori* with negative results. As a result of shared decision making, we refrained from a gastroscopy or colonoscopy (both were included in multidisciplinary screening before OHT). There was no somatic cause of the vomiting, diarrhoea, and

**Table 1 Psychosomatic treatment**

Intensive care unit: Delirium management with medication, coping with emotions after psychotic symptoms (shame, guilt, worries about losing control); coping with acute somatic events such as dialysis, focus on emotional expression by verbalizing emotional experience. During the visitor restrictions—dealing with separation from family and loneliness, regular phone calls with the family and motivation for video calls.

Intermediate care unit: Disease and transplantation acceptance, focus on motivational interviewing related to activation, mobilization and nutrition. Future-oriented interventions with formulation of recovery goals and feasible steps for the next weeks/months. Use of resource-oriented pictures and resource-activating questions, internal sources of strength (positive guiding principles, helpful cognitions, feel-good places) that promote psychological recovery.

Inpatient psychosomatic treatment: Psychotherapeutic treatment including psychodynamic, behavioural, and educational elements delivered as twice weekly individual and group psychotherapy, regular art therapy, body therapy including physiotherapy (each individually and in a group), daily walking groups, patient groups, and relaxation methods according to Jacobson (PR). Time-limited expositions to the home environment, regular nutrition plan, support by the patient group.

weight loss. However, the symptoms of nausea, loss of appetite, or diarrhoea might be common side effects of immunosuppression drugs, or other drugs. Furthermore, the differential diagnoses of a severe depressive episode, atypical anorexia, or post-traumatic stress disorder were considered as possible causes of the reported somatic symptoms. Therefore, an inpatient psychocardiological treatment on our interdisciplinary psychocardiology ward was initiated in order to clarify the differential diagnosis underlying the somatic symptoms and offer appropriate treatment.

After direct transfer from the Department of Cardiovascular and Thoracic Surgery, the 5-week inpatient psychocardiology treatment (Table 1) was based on an integrative multimodal approach with intensive psychotherapy, somatic diagnostics, and interdisciplinary treatment including regular visits by experts from the transplant team. The psychotherapeutic treatment included psychodynamic, behavioural, and educational elements in the form of twice a week individual and group psychotherapy, regular art therapy, body therapy including physiotherapy (each individually and in a group), daily walking groups, patient groups, and progressive relaxation (PR) training according to Jacobson.

Post-traumatic stress disorder could be ruled out during in-depth exploration since typical symptoms such as intrusion, nightmares, hyperarousal, and avoidance behaviour were not present. The depression improved significantly over the course of the stay, as the activation program was implemented both in psychotherapy and physiotherapy. The patient could increase her physical capabilities to walking tours with a walker. Time-limited expositions to the home environment could be carried out on weekends and appeared successful. Unfortunately, an effective short-term setback occurred

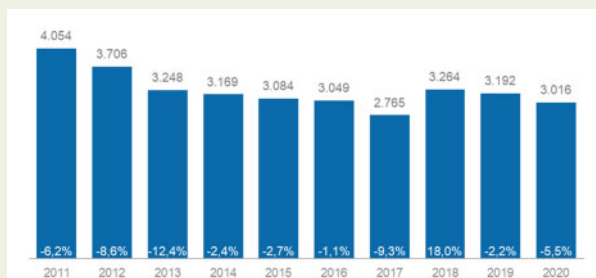
when the patient received the shocking message that her heart disease had been passed on to one of her grandchildren. The patient was able to reframe the information for herself in such a way that the early diagnosis of the heart disease in her grandchild will probably improve the prognosis. Based on a weight gain plan, the body weight was gradually increased to a BMI of 18.1 kg/m<sup>2</sup>. In addition, the patient benefitted from support from the patient group, in which she integrated herself well from the start and which especially helped her to master her goal of improving her physical strength. An important factor of the emotional and physical improvement seemed to be the stepwise activation and, in particular, the daily structuring through the overall package of therapeutic offers on the ward. In addition, the patient increasingly succeeded in communicating the fears and worries she had experienced during the early post-transplant period, in particular not being able to eat or drink anything again.

On Day 164 after OHT, the patient was discharged from the Department for Psychosomatic Medicine and Psychotherapy and has remained mentally and physically stable. The dialysis treatment was no longer indicated and she reached additional weight gain at home. The patient's discharge medication included tacrolimus, mycophenolate mofetil, prednisolone, aspirin, bisoprolol, ramipril, iodide, levothyroxine, pantoprazole, renavit multivitamin, cholecalciferol, and citalopram. The patient attends monthly appointments in our outpatient transplant clinic for electrocardiography, echocardiography, drug level monitoring of tacrolimus and mycophenolate mofetil, and other laboratory measurements. Furthermore, during these monthly appointments, the patient receives psychocardiological sessions with the psychosomatic liaison specialist (50 min sessions), the same specialist who provided the psychosomatic treatment before and after the patient's OHT. Additionally, we provided 15–30 min. multidisciplinary sessions with the husband to allow for time to answer all the questions and to support him during this difficult time. Moreover, the patient started psychotherapy (every 2 weeks). The patient still receives the pharmacological therapy with citalopram 20 mg. After recovery from acute renal failure, the patient attends nephrological visits (at the beginning once monthly, currently all 3 months) as well as regular visits with her primary care provider. Moreover, we provide regular myocardial biopsies.

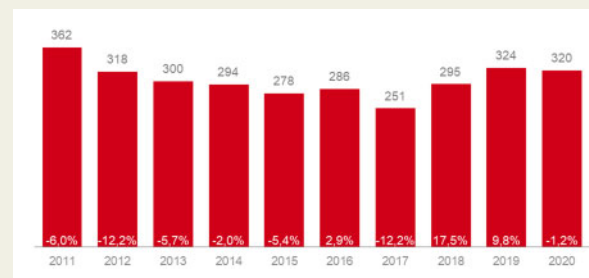
## Discussion

We report a case of a 64-year-old woman with a non-compaction cardiomyopathy receiving an orthotopic heart transplant during the COVID-19 pandemic with visitor restrictions, development of acute psychotic symptoms/delirium, and severe post-transplant depressive symptoms, including alarming weight loss. It is likely that inpatient treatment in the Department of Cardiovascular and Thoracic Surgery, including regular psychosomatic liaison consultation and inpatient treatment on the dedicated interdisciplinary psychocardiology ward within the Heart Centre, was the key to successful management of this extraordinary case.

During the COVID-19 pandemic, the visitor policies were changed in hospitals with visitor restrictions which required discussion of ethical considerations among the ICU team, as the obligation of non-maleficence and the principle of Beneficence conflicted. It was unclear whether the placed social and psychological burden could be justified



**Figure 4** Post-mortem donated organs in Germany. Percentage change from previous year, January to December 2020. Sources of the German Foundation of Organ Transplantation ('Deutsche Stiftung Organtransplantation' - DSO) with responsibility for coordinating organ donation in Germany.<sup>14</sup>



**Figure 5** Post-mortem donated hearts in Germany. Percentage change from previous year, January to December 2020. Sources of the German Foundation of Organ Transplantation ('Deutsche Stiftung Organtransplantation' - DSO) with responsibility for coordinating organ donation in Germany.<sup>14</sup>

by the physical benefits of infection protection. Obligations of non-maleficence are usually more stringent than obligations of beneficence and the formal regulations had to be observed.<sup>13</sup> The problem was to develop an effective but also tolerable and bearable protection and isolation strategy. Lack of sufficient social support is a relative contraindication to heart transplantation and better social support predicts better behavioural, psychological, and clinical outcomes, and thus plays an important protective role.<sup>11</sup> The COVID-19 pandemic has unique implications for heart transplant clinicians, patients on the waiting list, and transplant recipients. In Germany, the German Foundation of Organ Transplantation ('Deutsche Stiftung Organtransplantation' - DSO) reported only a minor decrease of post-mortem donated organs (-5.5%; *Figure 4*) and post-mortem donated hearts (-1.2%; *Figure 5*) in 2020.<sup>14</sup> On one side, for patients requiring an OHT during the COVID-19 pandemic, extra precautions should be taken to mitigate the risk of post-operative exposure.<sup>1</sup> On the other side, family participation and flexible visitor policy can be associated with reduced delirium in the ICU setting, improved long-term psychological recovery, decreased ICU stay, and improved patient experience.<sup>15</sup> Furthermore, a recent observational case showed an impact of hospital visitor policies on the post-operative experience during the COVID-19 pandemic. Patients in a Non-Visitor Cohort experienced greater isolation, delays in receiving medications, difficulties in getting out of bed, and a reduced consideration of discharge preferences in comparison to patients before visitor restrictions.<sup>16</sup>

Due to complications, our patient developed acute psychosis/delirium while in the ICU. After switching from intravenous tacrolimus to oral administration, the acute psychotic syndrome/delirium symptoms reduced and disappeared within a few days with additional treatment with quetiapine. Delirium is a common complication after cardiac surgery. In previous research, several pre-existing factors (e.g. older age, diabetes, preoperative depression, NYHA Class III or IV), as well as precipitating intra-operative and post-operative factors (length of ICU stay or mechanical ventilation) were identified.<sup>17</sup> Furthermore, several neurological complications were reported under immunosuppressive treatment with tacrolimus,

mycophenolate mofetil, and additionally prednisolone. Calcineurin inhibitors are considered to be one of the main causes of neurological complications and acute psychotic disorder (APD) in transplant patients. Tacrolimus causes serotonergic effects and inhibition of the N-methyl-D-aspartate receptor system. The neurotoxic effect of tacrolimus may be related to up-regulation of endothelin receptors, damage of the blood-brain barrier, and neuromodulatory systems.<sup>2,18</sup> In cases of liver transplant recipients with acute psychotic disorder, in less than 24 h after suspension of tacrolimus, all symptoms disappeared in both patients, making a causal relationship with tacrolimus likely.<sup>2</sup> In transplant recipients, the use of corticosteroids may be a risk for the development of APD, and up to 14% of transplant recipients using corticosteroids manifest psychotic symptoms. Termination of treatment with corticosteroid leads to symptom resolution in 2 weeks in 50% of patients and in 6 weeks in 90% of patients.<sup>3</sup> There is scarce evidence of neurological symptoms such as agitation, depression, insomnia, and headaches associated with the use of mycophenolate.<sup>19</sup>


Depression is common among patients both on the waiting list and post-transplant. Multiple studies have demonstrated increased morbidity and mortality in depressed patients after OHT.<sup>5-7</sup> In a study of 114 patients with OHT, 35.1% had pre-transplant depression and 26.3% had post-transplant depression. Patients with post-transplant depression within the first year were significantly more likely to have longer ICU (11.7 days vs. 7.8 days) and hospital stays (31.7 vs. 16.3 days), a higher 5-year mortality rate (30% vs. 9.5%), and a higher risk of acute rejection (10% vs. 0%).<sup>20</sup> In that study, pre-transplant depression did not impact cardiac outcomes, while post-transplant depression was significantly associated with a complicated course, suggesting the need for diagnosing and treating depression in patients after OHT.<sup>20</sup> In contrast to the latter findings, in a study of 102 consecutive OHT patients, the outcomes between patients with vs. without clinical depression did not differ in terms of survival, cardiac and infectious hospitalizations, and organ rejections.<sup>9</sup> In that study population, patients with depression were treated with antidepressant medication and/or psychotherapy either before OHT or within 1 year after OHT. It is worth noting that survival rates after OHT are higher among women than men, even though women

show more depression and worse functional ability early and later after OHT, and report using more negative coping styles but experiencing more satisfaction with social support.<sup>21</sup>

In the presented case report, dealing with end-stage heart failure before OHT, symptoms of delirium in the ICU as well as post-operative complications after OHT might have been potential triggers for the development of the reported severe depressive symptoms. In this context, the patient reported shame especially because of agitation, optic hallucinations, and disorientation while being treated in the ICU, and reduced self-reliance because of somatic complications. Furthermore, several complications (especially the renal failure with the need for dialysis) slowed mobilization and considerably delayed the discharge from the hospital to cardiac rehabilitation.

In conclusion, heart transplant patients show a higher risk of developing major depression with an increased risk of morbidity and mortality. Furthermore, post-transplant immunosuppressive treatment with tacrolimus or corticosteroids may cause neurological symptoms up to acute psychotic disorders or lead to acute delirium. A report summarizing 25 years of experience in the complexities of the management of post-transplant care shows how multidisciplinary teamwork involving heart failure experts and allied health professionals can lead to excellent long-term results.<sup>10</sup> Facing the COVID-19 pandemic, the hospital visitor policies should be reviewed carefully looking at the role of social isolation, post-operative experience in ICU, and medical complications after OHT.

## Lead author biography



Dr. Monika Sadlonova, is a research fellow at Massachusetts General Hospital (Cardiac Psychiatry Research Program) and Harvard Medical School. She graduated from the fellowship program in psychosomatic consultation-liaison service at the University of Göttingen Medical Centre in Germany in 2020, where she served as a staff physician in psychosomatic consultation-liaison service at the Department of Cardiovascular and

Thoracic Surgery (Prof. Kutschka) and co-investigator in multicentre TEACH trial (Prof. Herrmann-Lingen, 'Blended collaborative care in distressed patients with chronic CAD'). Her clinical and research interests fall within the areas of psychosomatic consultation-liaison service in the context of cardiac surgery and cardiology.

## Supplementary data

Supplementary material is available at *European Heart Journal—Case Reports* online.

**Slide sets:** A fully edited slide set detailing these cases and suitable for local presentation is available online as [Supplementary data](#).

**Consent:** The authors confirm that written consent for submission and publication of this case report including images and associated text has been obtained from the patient in line with COPE guidance.

**Conflict of interest:** none declared.

**Funding:** Time for this work was supported by the German Heart Foundation through a research scholarship (to Dr Sadlonova). We acknowledge support by the Open Access Publication Funds of the Göttingen University.

## References

- DeFilippis EM, Farr MA, Givertz MM. Challenges in heart transplantation in the era of COVID-19. *Circulation* 2020;**141**:2048–2051.
- de Sousa Arantes Ferreira G, de Conde Watanabe AL, Carvalho Trevizoli N, de Felipe Jorge FM, Ferreira Figueira AV, Fatima Couto C, et al. Tacrolimus-associated psychotic disorder: a report of 2 cases. *Transplant Proc* 2020;**52**:1350–1353.
- Gable M, Depry D. Sustained corticosteroid-induced mania and psychosis despite cessation: a case study and brief literature review. *Int J Psychiatry Med* 2015;**50**:398–404.
- Dew MA, Roth LH, Schulberg HC, Simmons RG, Kormos RL, Trzepacz PT et al. Prevalence and predictors of depression and anxiety-related disorders during the year after heart transplantation. *Gen Hosp Psychiatry* 1996;**18**:485–461.
- Petrucci L, Ricotti S, Michelini I, Vitulo P, Oggioni T, Cascina A et al. Return to work after thoracic organ transplantation in a clinically-stable population. *Eur J Heart Fail* 2007;**9**:1112–1119.
- Dew MA, Kormos RL, DiMartini AF, Switzer GE, Schulberg HC, Roth LH et al. Prevalence and risk of depression and anxiety-related disorders during the first three years after heart transplantation. *Psychosomatics* 2001;**42**:300–313.
- Delibasic M, Mohamedali B, Dobrilovic N, Raman J. Pre-transplant depression as a predictor of adherence and morbidities after orthotopic heart transplantation. *J Cardiothorac Surg* 2017;**12**:62.
- Zipfel S, Schneider A, Wild B, Löwe B, Jünger J, Haass M et al. Effect of depressive symptoms on survival after heart transplantation. *Psychosom Med* 2002;**64**:740–747.
- Okwuosa I, Pumphrey D, Puthumana J, Brown R-M, Cotts W. Impact of identification and treatment of depression in heart transplant patients. *Cardiovasc Psychiatry Neurol* 2014;**2014**:747293.
- Bruschi G, Colombo T, Oliva F, Botta L, Morici N, Cannata A et al. Heart transplantation: 25 years' single-centre experience. *J Cardiovasc Med (Hagerstown)* 2013;**14**:637–647.
- Dew MA, DiMartini AF, Dobbels F, Grady KL, Jowsey-Gregoire SG, Kaan A et al. The 2018 ISHLT/APM/AST/CCAC/STSW recommendations for the psychosocial evaluation of adult cardiothoracic transplant candidates and candidates for long-term mechanical circulatory support. *J Heart Lung Transplant* 2018;**37**:803–823.
- Robert Koch Institute. COVID-19 Situation Report. [https://www.rki.de/DE/Content/InfAZ/N/Neuartiges\\_Coronavirus/Situationsberichte/Okt\\_2020/2020-10-20-en.html](https://www.rki.de/DE/Content/InfAZ/N/Neuartiges_Coronavirus/Situationsberichte/Okt_2020/2020-10-20-en.html) (1st March 2021).
- Beauchamp TL, Childress JF. *Principles of Biomedical Ethics*. New York: Oxford University Press; 2019.
- German Foundation of Organ Transplantation. Statistics of organ transplantation in Germany. <https://dso.de/organspende/statistiken-berichte/organspende> (March 1st 2021).
- Munshi L, Evans G, Razak F. The case for relaxing no-visitor policies in hospitals during the ongoing COVID-19 pandemic. *Can Med Assoc J* 2021;**193**:E135–E137.
- Zeh RD, Santry HP, Monsour C, Sumski AA, Bridges JFP, Tsung A et al. Impact of visitor restriction rules on the postoperative experience of COVID-19 negative patients undergoing surgery. *Surgery* 2020;**168**:770–776.
- Chen H, Mo L, Hu H, Ou Y, Luo J. Risk factors of postoperative delirium after cardiac surgery: a meta-analysis. *J Cardiothorac Surg* 2021;**16**:113.
- Gok F, Zengin Eroglu M. Acute psychotic disorder associated with immunosuppressive agent use after renal transplantation: a case report. *Psychiatry Clin Psychopharmacol* 2017;**27**:314–316.
- Piotrowski PC, Lutkowska A, Tsiulski A, Karczewski M, Jagodziński PP. Neurologic complications in kidney transplant recipients. *Folia Neuropathol* 2017;**55**:86–109.
- La Rosa A, de Singer-Englar T, Hamilton MA, IsHak WW, Kobashigawa JA, Kittleson MM. The impact of depression on heart transplant outcomes: a retrospective single-center cohort study. *Clin Transplant* 2021;**35**:e14204.
- Hasan A, Kittleson MM. Heart transplantation in women. *Heart Fail Clin* 2019;**15**:127–135.