

Multi-modal 3D Simulation Makes the Impossible Possible

Ingrid M. Ganske, MD, MPA*

Noah Schulz, MSME†

Katie Livingston, ME†

Susan Goobie, MD, FRCPC‡

John G. Meara, MD, DMD, MBA*

Mark Proctor, MD§

Peter Weinstock, MD, PhD¶

Summary: B.Y. was born full term after a large vertex encephalocele was diagnosed prenatally. The unique challenge to repairing B.Y.'s encephalocele was a microcephalic skull and large proportion of likely functional extracranial brain tissue, which would need to be preserved. At Boston Children's Hospital, a simulation-based collaborative presurgical planning and rehearsal process, using both digital and 3D printed models, enabled successful technical completion and outcome of an otherwise inoperable case. (*Plast Reconstr Surg Glob Open* 2018;6:e1751; doi: 10.1097/GOX.0000000000001751; Published online 20 April 2018.)

B.Y. was prenatally diagnosed with a large vertex encephalocele. When he was born at full term, the complexity of the encephalocele was considered too high to operate. Although he was sent home with hospice care, he continued to thrive. His parents reported that other than his unwieldy head shape, which kept him immobile on his back, he behaved just like their older son.

B.Y.'s pediatrician recommended another opinion at Boston Children's Hospital, where he presented for evaluation at 5 months of age, weighing 6.85 kg. He had limited vision, but otherwise no seizures or other medical issues. On examination, he had a large encephalocele with good quality overlying skin and no leakage of cerebrospinal fluid. His head circumference was under the second percentile, with 20–30% of the brain contents and a large amount of fluid herniated into the encephalocele. Magnetic reso-

nance imaging showed a complex lesion, containing what appeared to be functional brain tissue.

The microcephaly and large amount of extracranial brain posed a unique challenge to reconstruction. Skull expansion would be required to accommodate the possibly functional brain tissue. Neurosurgery and plastic surgery expertise were combined with an on-site hospital-based simulator program—including simulation methodology, imaging, segmentation, mechanical engineering, 3D printing and design—to enable detailed surgical preplanning necessary to design, test, and practice multiple options without posing any harm to the patient. Although 3D models have been valuable tools in craniofacial procedures for decades,^{1–15} the unique collaboration between surgeons and a simulator program that could produce individualized 3D renderings provided a novel iterative process of physical and digital modeling to help make an otherwise impossible case possible.

*From the *Department of Plastic & Oral Surgery, Boston Children's Hospital and Harvard Medical School, Boston, Mass.; †Boston Children's Hospital Simulator Program (SIMPeds), Boston, Mass.; ‡Department of Anesthesiology, Critical Care, Perioperative, and Pain Medicine, Boston Children's Hospital and Harvard Medical School, Boston, Mass.; §Department of Neurosurgery, Boston Children's Hospital and Harvard Medical School, Boston, Mass.; and ¶Division of Critical Care, Department of Anesthesiology, Critical Care, Perioperative, and Pain Medicine, Boston Children's Hospital and Harvard Medical School, Boston, Mass.*

Received for publication October 16, 2017; accepted January 30, 2018.

Accepted for presentation at the International Society of Craniofacial Surgery annual conference, October 2017, Cancun, Mexico.

This study was approved by the Boston Children's Hospital international review board under IRB-P00022491.

Copyright © 2018 The Authors. Published by Wolters Kluwer Health, Inc. on behalf of The American Society of Plastic Surgeons. This is an open-access article distributed under the terms of the Creative Commons Attribution-Non Commercial-No Derivatives License 4.0 (CCBY-NC-ND), where it is permissible to download and share the work provided it is properly cited. The work cannot be changed in any way or used commercially without permission from the journal.

DOI: 10.1097/GOX.0000000000001751

SIMULATION METHODOLOGY

Models Created

An initial set of 3D digital models were created from segmentation of the head computed tomography study using Materialise Mimics (Materialise, Leuven Belgium) software. These models included B.Y.'s skull, brain parenchyma, and dura, and were printed using polymer-jet 3D printers to facilitate simulation of the surgical procedure (Fig. 1). Using volumetric analysis of the 3D model, the intracranial volume was estimated at 531 cc, and the extracranial brain volume was 105 cc; thus, an additional 100 cc of volume would need to be created to reposition the brain back into the skull (Fig. 1).

Initial Presurgical Revision (Physical Model)

Vertical osteotomies arranged over the parietal-occipital region were marked and cut to expand the volume

Disclosure: The authors have no financial interest to declare in relation to the content of this article. The Article Processing Charge was paid for by the authors.

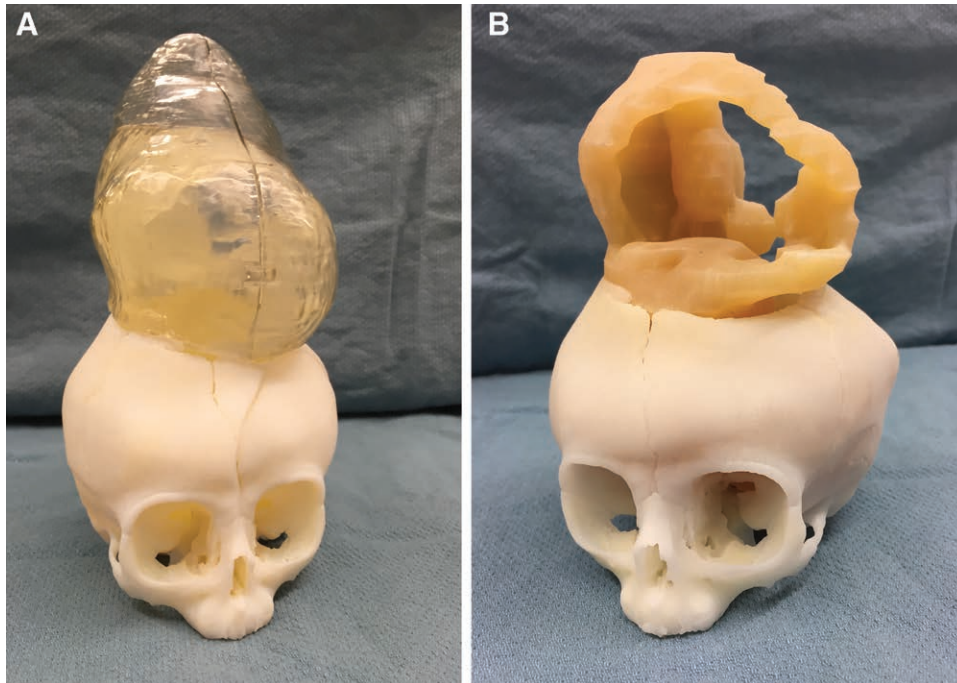


Fig. 1. Preoperative 3D models showing fluid and solid components of the encephalocele (A) and just the extracranial brain (B).

(Fig. 2). The cranial defect at the apex was expected to fill in with time, as has been demonstrated in previous pediatric cranial reconstruction.^{16–20} After making these cuts on the model, the segments were “out-fractured,” carefully bending them outward in a radial pattern.

Digital Revision and Volumetric Calculation

After the revised models were rescanned using CT, the resulting volumetric imaging was resegmented and digital volumetric models produced (Fig. 3). The out-fractured parietal-occipital segments were isolated from the anterior skull and positioned to estimate the resulting intracranial volume. To increase volume fur-

ther, 2 more osteotomies were created virtually along the parietal bones. Several other reconstructions were created in software, to roughly correlate rotational position of the barrel staves with resulting increases in intracranial volume.

INTRAOPERATIVE DETAILS

The preoperative planning process facilitated an efficient approach in the operating room. Following anesthetic preparation, he was repositioned safely into the prone position. The encephalocele was drained of approximately 300 ml of fluid. Through a coronal incision, the encephalocele was dissected free and the preplanned posterior osteotomies were created. A segment of brain tissue emanating from the right occipital area was independent of other attachments and therefore this completely disorganized nonfunctional brain tissue was excised. The remainder of the brain tissue was reducible into the expanded cranium. Due to the lack of normal brain architecture, there were no definable ventricles into which to place an external ventricular drain or shunt.

The out-fractured posterior segments demonstrated a tendency to collapse back together, thus 2 of the small parietal segments were removed and secured over the encephalocele defect to prevent reherniation.

As a rare and complex case, there is no average procedure time for comparison, but the 5-hour operative time was a perceived reduction in time, attributed to the presurgical planning and rehearsal. Blood loss was also minimized by the efficient approach; B.Y. was hemodynamically stable throughout, had a calculated blood loss of 125 ml and received 75 ml of packed red blood cells

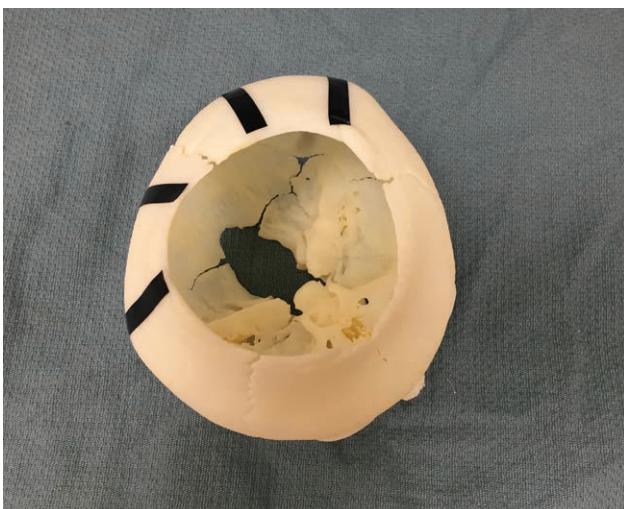


Fig. 2. 3D model for surgical preplanning with proposed osteotomies.

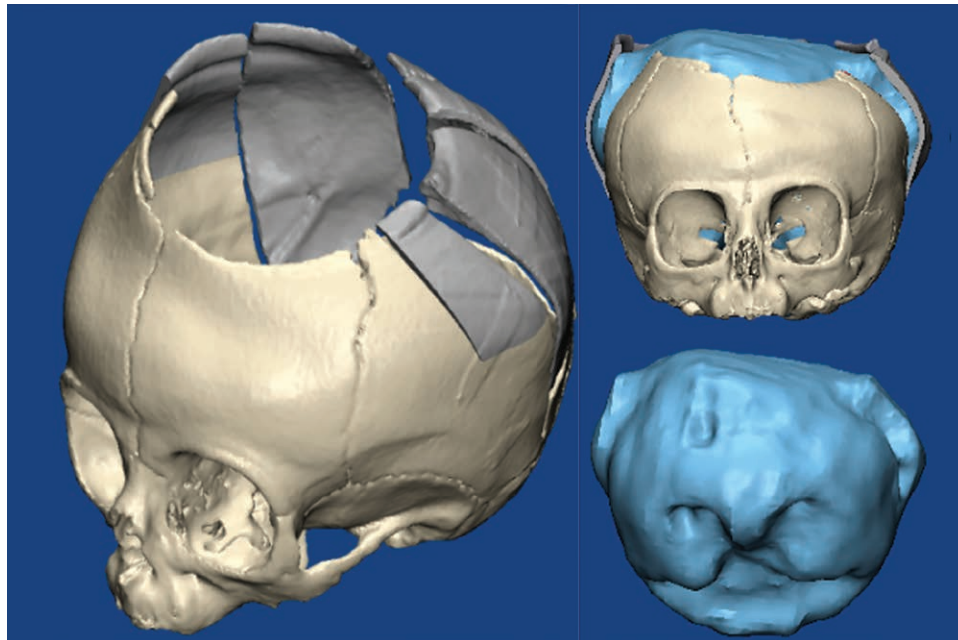


Fig. 3. Digital manipulation of model with additional osteotomies laterally (A) and volumetric analysis of digital model (B).

during the procedure. He required no further transfusion postoperatively. He was extubated and recovered in the intensive care unit.

POSTOPERATIVE COURSE

B.Y. recovered well initially, but after 48 hours, he became lethargic. Repeat imaging showed hydrocephalus, and he was taken back to the operating room for insertion of an external ventricular drain, which was later converted to a permanent shunt. His neurologic status improved back to baseline. He continues to take levetiracetam for seizure prophylaxis. B.Y. has been followed for 1 year without further postoperative complications. The potential risks of seizure, stroke, devastating neurologic injury, or death that had been discussed preoperatively were avoided (Fig. 4).

LIMITATIONS AND FURTHER FRONTIERS

Though informative, computer/screen-based digital planning remains limited by lack of physicality, highlighting the importance of a complimentary 3D physical model. In our hands, the 3D print replica adds “feel,” haptic and mechanical information. For instance, the initially designed osteotomies were technically reasonable and accessible within digital design but also required inspection of the resulting 3D print, to confirm they were actually safe and technically feasible in the actual patient. Additionally, unanticipated forces, such as supine positioning, yielded motion of the posterior osteotomized segments, which was otherwise unpredictable by a virtual model alone. As an additional “view,” future procedures may incorporate finite element analysis to predict movement and pressure effects from patient positioning.

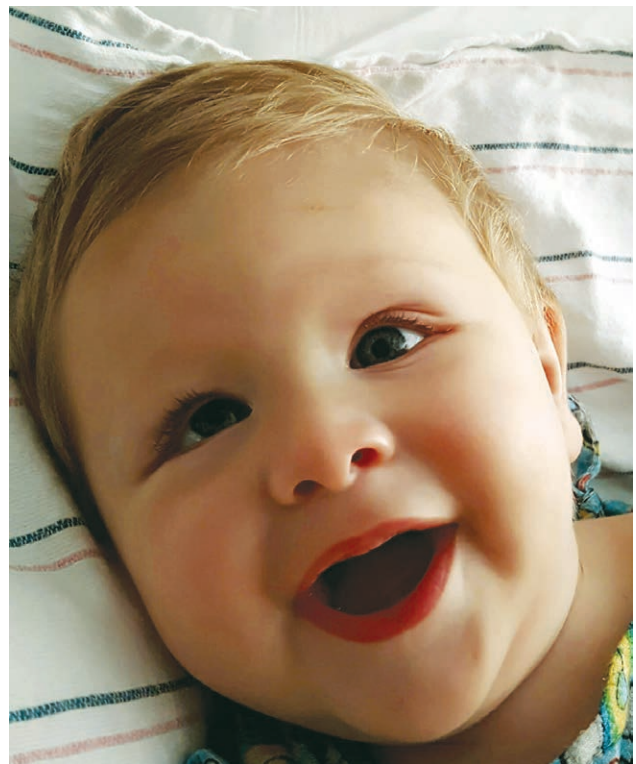

Fig. 4. The patient at 2 months postoperative.

CONCLUSIONS

New suites of simulation-based approaches offer novel paradigms of surgical preplanning allowing for risk-free discovery, rehearsal, and preparation of innovative procedures without peril to patients. Collabo-

ration of surgeons with simulator experts can convert cases once deemed too risky to endeavor into novel, life-saving procedures offered to new populations of patients.

Ingrid M. Ganske, MD, MPA

Department of Plastic & Oral Surgery
Boston Children's Hospital
300 Longwood Avenue
Boston, MA 02115

Email: Ingrid.ganske@childrens.harvard.edu

REFERENCES

- Altobelli DE, Kikinis R, Mulliken JB, et al. Computer-assisted three-dimensional planning in craniofacial surgery. *Plast Reconstr Surg.* 1993;92:576–585; discussion 586.
- Cohen A, Laviv A, Berman P, et al. Mandibular reconstruction using stereolithographic 3-dimensional printing modeling technology. *Oral Surg Oral Med Oral Pathol Oral Radiol Endod.* 2009;108:661–666.
- D'Urso PS, Barker TM, Earwaker WJ, et al. Stereolithographic biomodelling in cranio-maxillofacial surgery: a prospective trial. *J Craniomaxillofac Surg.* 1999;27:30–37.
- D'Urso PS, Earwaker WJ, Barker TM, et al. Custom cranioplasty using stereolithography and acrylic. *Br J Plast Surg.* 2000;53:200–204.
- Faber J, Berto PM, Quaresma M. Rapid prototyping as a tool for diagnosis and treatment planning for maxillary canine impaction. *Am J Orthod Dentofacial Orthop.* 2006;129:583–589.
- Gerstle TL, Ibrahim AM, Kim PS, et al. A plastic surgery application in evolution: three-dimensional printing. *Plast Reconstr Surg.* 2014;133:446–451.
- Girod S, Keeve E, Girod B. Advances in interactive craniofacial surgery planning by 3D simulation and visualization. *Int J Oral Maxillofac Surg.* 1995;24:120–125.
- Hidalgo HM, Romo GW, Estolano RT. Stereolithography: a method for planning the surgical correction of the hypertelorism. *J Craniofac Surg.* 2009;20:1473–1477.
- Imai K, Tsujiguchi K, Toda C, et al. Reduction of operating time and blood transfusion for craniostylosis by simulated surgery using three-dimensional solid models. *Neurol Med Chir (Tokyo).* 1999;39:423–426; discussion 427.
- Mironov V, Boland T, Trusk T, et al. Organ printing: computer-aided jet-based 3D tissue engineering. *Trends Biotechnol.* 2003;21:157–161.
- Müller A, Krishnan KG, Uhl E, et al. The application of rapid prototyping techniques in cranial reconstruction and preoperative planning in neurosurgery. *J Craniofac Surg.* 2003;14:899–914.
- Nyberg EL, Farris AL, Hung BP, et al. 3D-printing technologies for craniofacial rehabilitation, reconstruction, and regeneration. *Ann Biomed Eng.* 2017;45:45–57.
- Rengier F, Mehndiratta A, von Tengg-Kobligk H, et al. 3D printing based on imaging data: review of medical applications. *Int J Comput Assist Radiol Surg.* 2010;5:335–341.
- Sailer HF, Haers PE, Zollikofer CP, et al. The value of stereolithographic models for preoperative diagnosis of craniofacial deformities and planning of surgical corrections. *Int J Oral Maxillofac Surg.* 1998;27:327–333.
- Subburaj K, Nair C, Rajesh S, et al. Rapid development of auricular prosthesis using CAD and rapid prototyping technologies. *Int J Oral Maxillofac Surg.* 2007;36:938–943.
- Sirota K. Regeneration of defects in the calvaria. An experimental study. *Ann Med Exp Biol Fenn.* 1960;38:1–87.
- Gross RJ. Roentgenologic aspects of head trauma. *Am J Roentgenol Radium Ther.* 1950;64:399–408.
- Ingraham IJ, Matson DD. *Neurosurgery of Infancy and Childhood.* Springfield, Ill.: Charles C Thomas; 1954.
- Rowbotham GF. *Acute Injuries of the Head: Their Diagnosis, Treatment, Complications, and Sequels.* Edinburgh, Scotland: ES Livingstone; 1942.
- Moorhead JJ, Weller W. Fracture of the skull in children: a statistical survey of 100 cases. *Ann Surg.* 1921;74:72–78.