

Cryoablation of a duodenal adenoma with intramucosal carcinoma



Kohtaro Ooka, MD,¹ Romulo Celli, MD,² James J. Farrell, MBChB³

A 66-year-old man with Barrett's esophagus presented for evaluation of a 2-cm sporadic duodenal bulb tubulovillous adenoma with high-grade dysplasia (HGD) (Fig. 1). EUS revealed sparing of the muscularis propria and the submucosa. Initial therapy consisted of piecemeal EMR (Duette Kit, Cook Medical, Bloomington, Ind). When residual lesions were found on follow-up examination, EMR was reattempted, but the lesion could not be lifted with submucosal injection, likely because of scar tissue. The patient then underwent more than 2 years of repeated applications of argon plasma coagulation (APC) and radiofrequency ablation (RFA) (HALO, now Barrx, Medtronic, Minneapolis, Minn), but the lesion persisted (Fig. 2) and developed a single minute focus of intramucosal carcinoma. The patient refused surgical resection.

Next, cryoablation (Coldplay CryoBalloon, C2 Therapeutics, Redwood, Calif) was applied to the lesion over 2 endoscopic sessions, with each treatment lasting up to 12 seconds (Figs. 3A-C; Video 1, available online at www.VideoGIE.org). Our intention was eradication of the lesion. Removal with hot avulsion forceps was considered, but we opted for cryoablation because we hoped for more controlled treatment over a larger lesion area. Surveillance EGD (Fig. 4) after the first session revealed persistent HGD with focal complexity. A second session was performed 10 weeks after the first session. Follow-up EGD (Fig. 5) with extensive biopsies 1 month after the second session showed no evidence of dysplasia or carcinoma. There were no adverse events. A subsequent surveillance EGD was planned 3 to 6 months after the second cryoablation session.

To our knowledge, this is the first use of cryoablation on a duodenal neoplasm. It is also the first use of balloon-assisted cryoablation in the duodenum. First used in the GI tract in 1999,¹ cryoablation has been used to treat duodenal arteriovenous malformations, radiation-induced duodenitis, radiation-induced proctitis,² and gastric antral vascular ectasia.³ We found only 1 report of its use in the duodenum for any reason.² It has been used on the duodenal papilla in a porcine model.⁴

Endoscopic cryoablation is most commonly used to treat esophageal neoplasia and preneoplasia. Limited evidence from industry-supported high-quality studies have

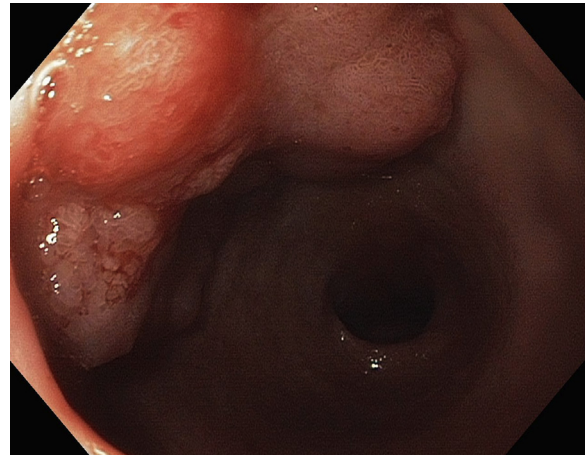


Figure 1. The lesion before interventions.

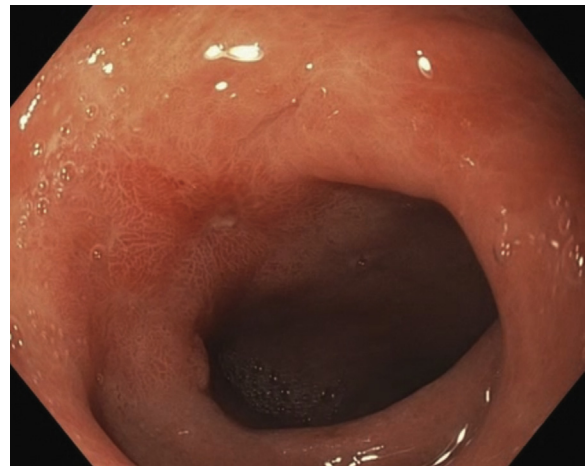

Figure 2. Persistence of the lesion despite multiple applications of EMR, argon plasma coagulation, and radiofrequency ablation. Image captured just before cryoablation.

reported downgrading of esophageal HGD in 68% to 97% of patients.⁵⁻⁷ In our case, 2 sessions of cryoablation were effective in ablating duodenal HGD and carcinoma that were refractory to multiple other modalities.

The risks include perforation, stricture, bleeding, and chest pain. Spray-type cryoablation in the esophagus has been shown to cause cryonecrosis reaching the

Written transcript of the video audio is available online at www.VideoGIE.org.

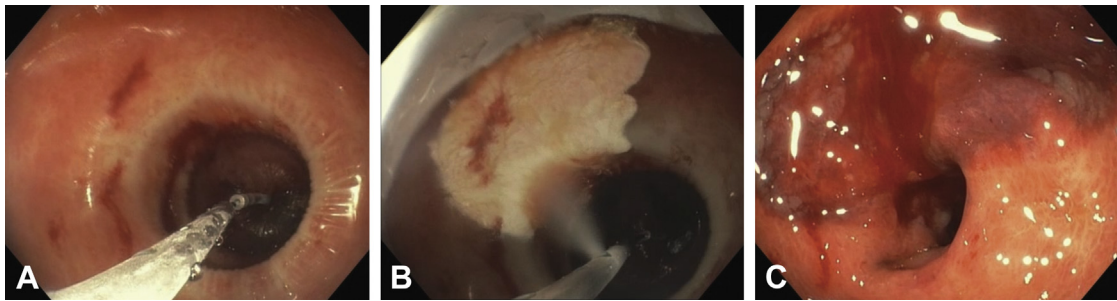

Figure 3. Application of cryoablation. The duodenal adenoma is visible (A) through the balloon before application of refrigerant, and (B) while refrigerant is being applied. (C) The lesion after cryotherapy.

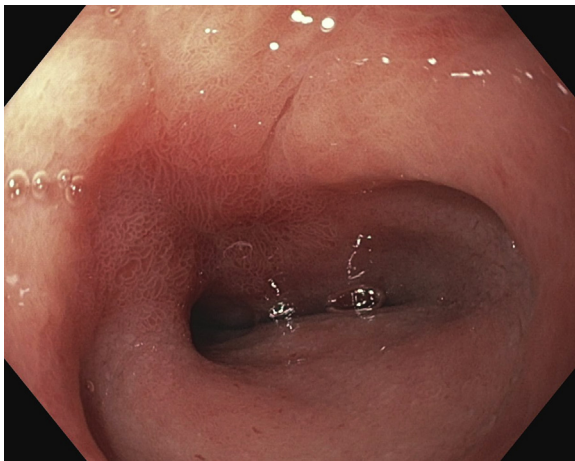


Figure 4. The duodenal adenoma several weeks after the first cryotherapy session.

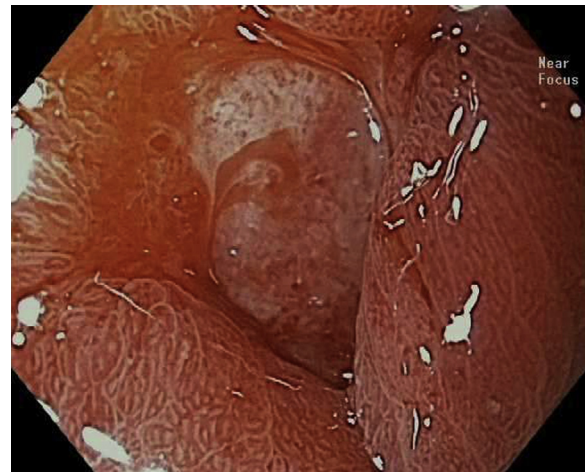


Figure 5. One month after the second cryotherapy session.

submucosa.⁸ In comparison with its use for esophageal lesions, the risk of perforation may be greater, given the thinner duodenal walls. Even though our patient had undergone multiple prior interventions, including EMR, RFA, and APC before cryotherapy, cryoablation did not result in perforation or any other adverse event.

The American Society for Gastrointestinal Endoscopy (ASGE) makes no specific recommendations regarding cryotherapy for the management of Barrett's esophagus⁹ but does recognize a potential role for cryoablation and other therapies for the ablation of residual tissue after resection.¹⁰ The American Gastroenterological Association guidelines cite a dearth of high-quality studies and lack of long-term follow-up; they do not recommend cryotherapy.¹¹ Based on a small number of high-quality studies, the ASGE guidelines recommend EMR for duodenal adenomas distal to the bulb and APC for destruction of remaining dysplastic tissue.¹² There are no recommendations regarding cryoablation in the duodenum.

DISCLOSURE

All authors disclosed no financial relationships relevant to this publication.

ACKNOWLEDGMENT

The authors thank Hiroyuki Aihara, MD, for the image of the lesion on final surveillance.

Abbreviations: APC, argon plasma coagulation; ASGE, American Society for Gastrointestinal Endoscopy; HGD, high-grade dysplasia; RFA, radiofrequency ablation.

REFERENCES

1. Pasricha PJ, Hill S, Wadwa KS, et al. Endoscopic cryotherapy: experimental results and first clinical use. *Gastrointest Endosc* 1999;49: 627-31.
2. Kantsevoy SV, Cruz-Correa MR, Vaughn CA, et al. Endoscopic cryotherapy for the treatment of bleeding mucosal vascular lesions of the GI tract: a pilot study. *Gastrointest Endosc* 2003;57:403-6.
3. Cho S, Zanati S, Yong E, et al. Endoscopic cryotherapy for the management of gastric antral vascular ectasia. *Gastrointest Endosc* 2008;68: 895-902.
4. Yang D, Reinhard MK, Wagh MS. Feasibility and safety of endoscopic cryoablation at the duodenal papilla: porcine model. *World J Gastrointest Endosc* 2015;7:728-35.
5. Dumot JA, Vargo JJ 2nd, Falk GW, et al. An open-label, prospective trial of cryospray ablation for Barrett's esophagus high-grade dysplasia and

- early esophageal cancer in high-risk patients. *Gastrointest Endosc* 2009;70:635-44.
6. Shaheen NJ, Greenwald BD, Peery AF, et al. Safety and efficacy of endoscopic spray cryotherapy for Barrett's esophagus with high-grade dysplasia. *Gastrointest Endosc* 2010;71:680-5.
 7. Gosain S, Mercer K, Twaddell WS, et al. Liquid nitrogen spray cryotherapy in Barrett's esophagus with high-grade dysplasia: long-term results. *Gastrointest Endosc* 2013;78:260-5.
 8. Ribeiro A, Bejarano P, Livingstone A, et al. Depth of injury caused by liquid nitrogen cryospray: study of human patients undergoing planned esophagectomy. *Dig Dis Sci* 2014;59:1296-301.
 9. Evans JA, Early DS, Fukami N, et al. The role of endoscopy in Barrett's esophagus and other premalignant conditions of the esophagus. *Gastrointest Endosc* 2012;76:1087-94.
 10. Evans JA, Early DS, Chandraskhara V, et al. The role of endoscopy in the assessment and treatment of esophageal cancer. *Gastrointest Endosc* 2013;77:328-34.
 11. Spechler SJ, Sharma P, Souza RF, et al. American Gastroenterological Association medical position statement on the management of Barrett's esophagus. *Gastroenterology* 2011;140:1084-91.
 12. Chathadi KV, Khashab MA, Acosta RD, et al. The role of endoscopy in ampullary and duodenal adenomas. *Gastrointest Endosc* 2015;82:773-81.
-
- Department of Internal Medicine (1), Department of Pathology (2), Yale Center for Pancreatic Disease, Section of Digestive Diseases, Yale University School of Medicine, New Haven, Connecticut, USA (3).
- Copyright © 2017 American Society for Gastrointestinal Endoscopy. Published by Elsevier Inc. This is an open access article under the CC BY-NC-ND license (<http://creativecommons.org/licenses/by-nc-nd/4.0/>).
- <http://dx.doi.org/10.1016/j.vgie.2017.04.013>
-