

Adult-Onset Seizure Disorder Secondary to Schizencephaly

Abstract

Schizencephaly is a very rare neurological disorder usually discovered during radiological evaluation of children and young adults with seizure disorders or neurodevelopmental anomalies. We present a 66-year-old patient with right-sided hemiatrophy and paresis presenting with an adult-onset seizure disorder. Her seizure was satisfactorily controlled with a single-therapy antiseizure drug. Congenital brain lesions should be part of the differential diagnoses in patients with epilepsy who have body asymmetry dated back to childhood.

Keywords: *Hemibody atrophy, schizencephaly, seizure disorders*

Introduction

Schizencephaly is a very rare congenital central nervous system malformation which occurs as a result of disordered neuronal cell migration which is characterized by cleft(s) spanning the cerebral hemisphere from the pia matter to the lateral ventricle, lined by gray matter.^[1] Its pathogenesis is not fully understood, but environmental and genetics factors have been implicated.^[1] There are two types of schizencephaly, namely Type I known as closed lip and Type II known as open lip.^[1,2] It can be unilateral or bilateral, but unilateral is more common than bilateral schizencephaly. Frontal lobe is the most common location followed by the parietal lobe.

Seizure disorder is the usual mode of presentation in childhood and young adult. Other modes of presentation include developmental delay, hemiparesis, quadriparesis, and headache or it may be an incidental finding.^[3] Presentation in the elderly is very rare in the literature.^[4,5]

Case Report

A 66-year-old left-handed female was brought to our clinic by her two sons on account of recurrent focal seizures involving the right upper and lower limbs, evolving to bilateral tonic-clonic convulsion. The first episode was at the age of 58 years with increasing frequency and severity. She had a history of mild right

hemiparesis from her childhood. There was no change in the patient's life style and no history of trauma, stress, or metabolic imbalance. It was initially thought to be a spiritual problem and she was taken for spiritual deliverance until the children were advised to seek medical consultation. She is a petty trader with no formal education. There is no history of chronic systemic medical disease.

Examination revealed elderly woman with normal vital signs. She was conscious with receptive aphasia. Cranial nerve examination was normal. There has a reduced muscle bulk on the right side of the body [Figure 1], a mild spastic hemiparesis with power grade 4+. Examination of other systems was normal.

A clinical diagnosis of adult-onset seizures most likely secondary to congenital brain lesion was made. Cranial computed tomography scan [Figure 2] showed left parietal Type II schizencephaly with no pressure effect. She was commenced on anticonvulsant (tablet carbamazepine 400 mg bid) with good seizure control. Her children declined electroencephalographic and brain magnetic resonance imaging due to financial constraint. She is being followed up.

Discussion

Schizencephaly is usually discovered during radiological evaluation of children and young adults with seizure disorders or

**Abiodun Idowu Okunlola^{1,2},
Paul Olowoyo^{3,4},
Cecilia Kehinde Okunlola³,
Olakunle Fatai Babalola^{1,2}**

Departments of ¹Surgery and ³Medicine, Federal Teaching Hospital, Ido-Ekiti, Departments of ²Surgery and ⁴Medicine, College of Medicine and Health Sciences, Afe Babalola University, Ado-Ekiti, Nigeria

Address for correspondence:
Dr. Abiodun Idowu Okunlola,
Department of Surgery,
Federal Teaching Hospital,
Ido-Ekiti, Nigeria.
Department of Surgery,
College of Medicine and
Health Sciences, Afe Babalola
University, Ado-Ekiti, Nigeria.
E-mail: okunlolab@yahoo.com

Access this article online

Website: www.asianjns.org

DOI: 10.4103/ajns.AJNS_293_19

Quick Response Code:



How to cite this article: Okunlola AI, Olowoyo P, Okunlola CK, Babalola OF. Adult-onset seizure disorder secondary to schizencephaly. Asian J Neurosurg 2020;15:159-61.

Submission: 20-09-2019

Accepted: 13-11-2019

Published: 25-02-2020

This is an open access journal, and articles are distributed under the terms of the Creative Commons Attribution-NonCommercial-ShareAlike 4.0 License, which allows others to remix, tweak, and build upon the work non-commercially, as long as appropriate credit is given and the new creations are licensed under the identical terms.

For reprints contact: reprints@medknow.com

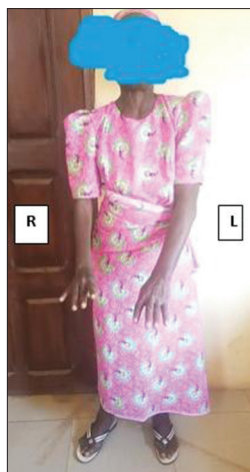

Figure 1: Right hemibody atrophy

neurodevelopmental anomalies.^[6] It can also be discovered incidentally while evaluating patients for unrelated pathologies.^[7] The clinical features of schizencephaly vary from hemiparesis to seizure disorder.^[8] The age at presentation is usually before the age of 10 years.^[9] Seizure disorders have been reported as the most common presentation in patients with schizencephaly and it usually begins before the age of 3 years.^[10] Our patient presented with focal seizures evolving to bilateral tonic-clonic convulsions, with onset at the age of 58 years, though she has had mild right hemiparesis and atrophy^[4] which could have explained her left handedness.

Bilaterality is the most consistent poor prognostic factor in schizencephaly, while unilateral schizencephaly has a good prognosis in terms of motor and mental functions.^[8,11] Other documented prognostic factors include the type, size, and location of the defects.^[12] It is the integrity of the underlying brain parenchyma that determines the prognosis. Therefore, there may not be any correlation with the morphology of the defects and the severity of the clinical manifestations, most especially for seizures.^[8] Our patient has mild mental and motor deficit because of the parietal location, though on the left cerebral hemisphere. The fact that there are no radiological features of pressure effect may also explain the relatively good prognosis in this patient. The index patient presented at the age of 66 years though her right hemiparesis dated back to childhood. There was no correlation between the type of schizencephaly and the type of seizures in the previous studies, but the right hemiparesis and atrophy correlated significantly with the contralateral schizencephaly. The patient responded satisfactorily to a single anticonvulsant therapy.

The management of schizencephaly is usually nonoperative except when it is associated with hydrocephalus in which case cerebrospinal fluid diversion may be necessary.^[13] Schizencephaly may not be as rare as previously documented, because with increasing

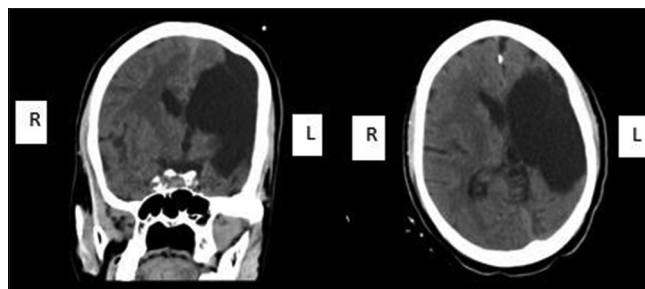


Figure 2: Cranial computed tomography scan showing left parietal open lip schizencephaly

availability of neuroimaging, more cases are being discovered.

Conclusion

Adult-onset seizures are rarely due to congenital brain lesions, but they should be a differential diagnoses in patients with body asymmetry dated back to childhood.

Declaration of patient consent

The authors certify that they have obtained all appropriate patient consent forms. In the form the patient(s) has/have given his/her/their consent for his/her/their images and other clinical information to be reported in the journal. The patients understand that their names and initials will not be published and due efforts will be made to conceal their identity, but anonymity cannot be guaranteed.

Financial support and sponsorship

Nil.

Conflicts of interest

There are no conflicts of interest.

References

1. Granata T, Battaglia G. Schizencephaly. *Handb Clin Neurol* 2008;87:235-46.
2. Tietjen I, Bodell A, Apse K, Mendonza AM, Chang BS, Shaw GM, *et al.* Comprehensive EMX2 genotyping of a large schizencephaly case series. *Am J Med Genet A* 2007;143A: 1313-6.
3. Mellado C, Poduri A, Gleason D, Elhosary PC, Barry BJ, Partlow JN, *et al.* Candidate gene sequencing of LHX2, HESX1, and SOX2 in a large schizencephaly cohort. *Am J Med Genet A* 2010;152A: 2736-42.
4. Cho WH, Seidenwurm D, Barkovich AJ. Adult-onset neurologic dysfunction associated with cortical malformations. *AJNR Am J Neuroradiol* 1999;20:1037-43.
5. Kamble V, Lahoti AM, Dhok A, Taori A, Pajinagara N. A rare case of schizencephaly in an adult with late presentation. *J Family Med Prim Care* 2017;6:450-2.
6. Landy HJ, Ramsay RE, Ajmone-Marsan C, Levin BE, Brown J, Pasarin G, *et al.* Temporal lobectomy for seizures associated with unilateral schizencephaly. *Surg Neurol* 1992;37:477-81.
7. Stopa J, Kucharska-Miąsik I, Dziurzyńska-Białek E, Kostkiewicz A, Solińska A, Zajac-Mnich M, *et al.* Diagnostic imaging and problems of schizencephaly. *Pol J Radiol*

- 2014;79:444-9.
8. Lopes CF, Cendes F, Piovesana AM, Torres F, Lopes-Cendes I, Montenegro MA, *et al.* Epileptic features of patients with unilateral and bilateral schizencephaly. *J Child Neurol* 2006;21:757-60.
 9. Denis D, Chateil JF, Brun M, Brissaud O, Lacombe D, Fontan D, *et al.* Schizencephaly: Clinical and imaging features in 30 infantile cases. *Brain Dev* 2000;22:475-83.
 10. Guerrini R, Carozzo R. Epileptogenic brain malformations: Clinical presentation, malformative patterns and indications for genetic testing. *Seizure* 2001;10:532-43.
 11. Mighell AS, Johnstone ED, Levene M. Post-natal investigations: Management and prognosis for fetuses with CNS anomalies identified in utero excluding neurosurgical problems. *Prenat Diagn* 2009;29:442-9.
 12. Denis D, Maugey-Laulom B, Carles D, Pedespan JM, Brun M, Chateil JF. Prenatal diagnosis of schizencephaly by fetal magnetic resonance imaging. *Fetal Diagn Ther* 2001;16:354-9.
 13. Halabuda A, Klasa L, Kwiatkowski S, Wyrobek L, Milczarek O, Gergont A. Schizencephaly-diagnostics and clinical dilemmas. *Childs Nerv Syst* 2015;31:551-6.