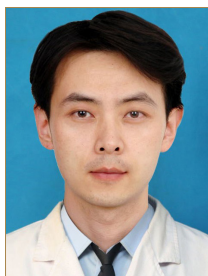



Editorial



Corresponding Author

Lingbo Kong

<https://orcid.org/0000-0002-3655-3171>

Xi'an Honghui Hospital, Xi'an Jiaotong University, School of Medicine, Xi'an, China

E-mail: lingbokong@163.com

See the article "Weak Ligaments and Sloping Joints: A New Hypothesis for Development of Congenital Atlantoaxial Dislocation and Basilar Invagination" via <https://doi.org/10.14245/ns.2040434.217>.



This is an Open Access article distributed under the terms of the Creative Commons Attribution Non-Commercial License (<https://creativecommons.org/licenses/by-nc/4.0/>) which permits unrestricted non-commercial use, distribution, and reproduction in any medium, provided the original work is properly cited.

Copyright © 2020 by the Korean Spinal Neurosurgery Society

Commentary on “Weak Ligaments and Sloping Joints: A New Hypothesis for Development of Congenital Atlantoaxial Dislocation and Basilar Invagination”

The craniovertebral junction (CVJ), as a critical transitional zone between the cranium and the spine, has a complicated structure of osseous anatomy and intricate relationship that associated with the cranial nervous, vascular, and musculoskeletal structures, which finally form a unique system.¹ Several pathological conditions and congenital malformation may affect the structure of CVJ. However, the invasive treatment of various types of abnormalities in CVJ region may pose great challenges, especially in the pediatric group, such as: resulting in segmental instability.² Besides that, the clinical manifestations are often delayed into the second and third decade because they are usually subtle and easily be neglected in children unless looked for specifically.³⁻⁵

In fact, different types of malformation and abnormalities with a complicated pathological osseous structural anatomy requiring individual management decisions designated for each particular case.⁴ In that cases of osseous structural malformation and abnormalities may vary among different demographic environment. As previously reported that the Indian subcontinent with its varied demographic profile of the population along with a high incidence of infectious pathologies like tuberculosis, which could present a broad spectrum of abnormalities.⁶ Pang and Thompson⁷ systematically reviewed the embryology and bony malformations of the CVJ. In their excellent study, they concluded a special characteristic of the abnormal and normal development of CVJ.


However, there still lack molecular studies for this abnormality. Current study titled “Weak Ligaments and Sloping Joints: A New Hypothesis for Development of Congenital Atlantoaxial Dislocation and Basilar Invagination”⁸ conducted by Chauhan has further investigated FB1 gene's alterations in the development of congenital atlantoaxial dislocation and basilar invagination in India population. Their hypothesis initially enlightened by previous study based on GWAS (genome-wide association), which currently demonstrated as a novel method for pathological related genes screening.

Very interestingly as their current study demonstrated that “significant number of DNA sequence variants in patients with developmental CVJ anomalies signifies that these variants may not be directly pathogenic, but probably they have some role with the “main causing agent” since they were not detected in the control population.” Their study also suggested that the nonsyndromic developmental CVJ anomalies commonly encountered in their clinical situation, which might present as a “subtler version” of Marfan's syndrome or similar connective tissue disorders with the FBN1 genetic involvement. The current study is

quite promising because it provided further investigation in genetic basis for developmental CVJ anomalies. However, extensive studies should be conducted for the role of FBN1 in the developmental CVJ anomalies, as well as the molecular cross talking with other genes such as: Pax family members.

REFERENCES

1. Ricciardi L, Sturiale CL, Izzo A, et al: Submandibular approach for single-stage craniovertebral junction ventral decompression and stabilization: a preliminary cadaveric study of technical feasibility. *World Neurosurg* 2019;127:206-12.
2. Ito K, Yamada M, Horiuchi T, et al. Appropriate surgical procedures for Chiari type 1 malformation and associated syrinx based on radiological characteristics of the craniovertebral junction. *Neurosurg Rev* 2020;43:575-80.
3. Parikh RN, Muranjan M, Karande S, et al. Atlas shrugged: cervical myelopathy caused by congenital atlantoaxial dislocation aggravated by child labor. *Pediatr Neurol* 2014;50:380-3.
4. Kumar R, Nayak SR. Management of pediatric congenital atlantoaxial dislocation: a report of 23 cases from northern India. *Pediatr Neurosurg* 2002;36:197-208.
5. Shiba R, Murota K, Kondo H, et al. Cervical congenital kyphosis with atlantoaxial dislocation. A case report. *Spine (Phila Pa 1976)* 1993;18:762-3.
6. Kale SS, Ailawadhi P, Yerramneni VK, et al. Pediatric bony craniovertebral junction abnormalities: Institutional experience of 10 years. *J Pediatr Neurosci* 2011;6(Suppl 1):S91-5.
7. Pang D, Thompson DN. Embryology and bony malformations of the craniovertebral junction. *Childs Nerv Syst* 2011;27:523-64.
8. Chauhan AK, Chandra PS, Goyal N. Weak ligaments and sloping joints: a new hypothesis for development of congenital atlantoaxial dislocation and basilar invagination. *Neurospine* 2020;17:843-56.



Title: Palace of Arts, Barcelona
 Artist: Pablo Picasso
 Year: 1903
 © 2020 - Succession Pablo Picasso - SACK (Korea)