

CASE REPORT

Open Access



Long term disease free survival with multimodal therapy in small cell bladder cancer

Isabel Heidegger^{1*}, Gennadi Tulchiner¹, Georg Schäfer², Wolfgang Horninger¹ and Renate Pichler^{1*}

Abstract

Background: Small cell bladder cancer (SCBC) is an aggressive subtype accounting for less than 1 % of all bladder malignancies associated with rapid progression, early metastases formation and high mortality rates.

Case presentation: We present an unusual long term disease free survival of a 60 year-old man who was diagnosed with SCBC two and a half years ago. He underwent four cycles of cisplatin/etoposide chemotherapy as well as a prophylactic whole-brain radiotherapy followed by a radical cystoprostatectomy and ileal neobladder with extended pelvic lymphadenectomy. Since 33 months the patient is now recurrence-free.

Conclusion: In this case report, we were able to show that early multimodal therapy results in long term disease free survival, thus we highly recommend neoadjuvant chemotherapy as a part of multimodal management of a primary metastases-free, localized and surgically resectable SCBC.

Keywords: Small cell bladder cancer, Multimodal therapy, Neoadjuvant chemotherapy, Disease free survival

Background

Bladder cancer is one of the most common urological malignancies in men and women. While about 95 % of diagnosed bladder cancers are histologically urothelial cancers, small cell bladder cancer (SCBC) is an aggressive subtype accounting for less than 1 % of all bladder malignancies associated with rapid progression, early metastases formation and high mortality rates [1–3].

SCBC primarily affects caucasian males between 60 and 80 years, mostly with a history of heavy smoking. Clinical symptoms like hematuria, imaging and cystoscopy do not allow the prediction of this aggressive type of bladder cancer, thus only tissue diagnostics are able to diagnose SCBC. In the recent years, new histopathological markers including TMPSS-ERG fusions or a positive HPV status have been reported as risk factors for SCBC [4, 5].

As no general guidelines for the optimal treatment of SCBC are available in the urological field, single modality local therapy (15 %), surgical (21 %) or radiation-based (14 %) as well as multimodal therapies (50 %) including cisplatin-based chemotherapeutic regimes have been reported [5]. A recent investigation utilizing the National Cancer Data Base based on 960 SCBC patients revealed that median overall survival (OS) in patients who were metastasis free at primary diagnosis was 8.3 months [6].

We present an unusual long term disease free survival of a 60 year old man who was diagnosed with SCBC two and a half years ago. He underwent four cycles of cisplatin/etoposide chemotherapy as well as a prophylactic whole brain radiotherapy (WBRT) followed by a radical cystoprostatectomy and ileal neobladder with extended pelvic lymphadenectomy. Currently, the patient is recurrence-free since 33 months.

Case report

A 60 years-old man was referred to our department due to painless gross hematuria. The patient had no risk factors including smoking, previous radiation therapy,

*Correspondence: isabel-maria.heidegger@i-med.ac.at; renate.pichler@i-med.ac.at

¹ Department of Urology, Medical University Innsbruck, Anichstrasse 35, 6020 Innsbruck, Austria

Full list of author information is available at the end of the article

occupational risk factors or hereditary factors. In addition, no other pre-existing conditions were known. The patient was painless and did not have any B-symptoms including weight loss or night sweats, furthermore, no neurological deficits were reported.

After exclusion of urinary infection as cause for hematuria, cystoscopy has been performed revealing a 6 cm solid tumor on the right bladder wall. Urinary cytology (voided urine and bladder washing) remained negative.

Consequently, a transurethral resection of the tumor has been performed and the tumor was macroscopically totally removed. Primary histology of the tumor specimen showed a muscle invasive small cell neuroendocrine carcinoma pT2a GIII. Moreover, tumor cells were positive for synaptophysin and AE1/AE3, with a high proliferation rate (KI-67) of 95 % on immunohistochemical analysis (Fig. 1). In contrast, chromogranin A, CD56, CD3, CD20, TdT, S-100 and HMB45 confirmed negative staining.

18 FDG-positron emission tomography/computed tomography (PET/CT) performed at the time of primary diagnosis did not show any lymph node or visceral metastatic tumor spread. A subsequent cranial magnet

resonance tomography (MRT) also confirmed no tumor infiltration into the brain.

As there are reports of increased survival rates upon neoadjuvant chemotherapy in patients suffering from SCBC [5], the patient underwent four cycles (day 1–3; 1 cycle = 21 days) of cisplatin (25 mg/m²)/etoposide (100 mg/m²) without any complications. In addition, we performed a prophylactic WBRT with a total dose of 26 Gray. Subsequently, the patient underwent radical cystoprostatectomy and ileal neobladder with bilateral extended pelvic lymphadenectomy (including 32 resected tumor-free lymph nodes). Final pathology confirmed complete response to neoadjuvant chemotherapy, with no vital small cell carcinoma tissue formations in both the lymph nodes and the cystoprostatectomy specimen (ypT0, N0, L0, V0, Pn0). An uneventful intra- and postoperative course was observed. The time from transurethral resection to chemotherapy start was 28 days. 34 days after chemotherapy was stopped, radical cystoprostatectomy has been performed.

Currently, the patient undergoes 6-monthly regular follow-up controls including urinary cytology (voided urine), measurement of residual urine, blood gas analysis

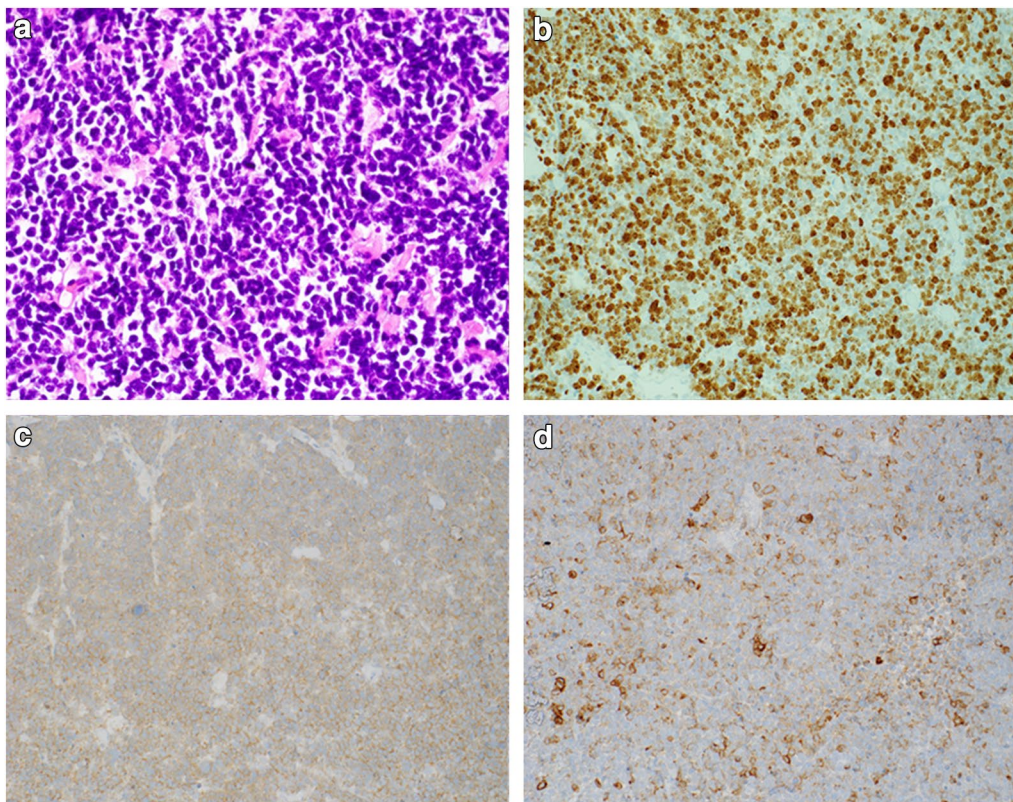


Fig. 1 Hematoxylin and eosin staining of cancer tissue sections (a) and immunohistochemistry for KI-67 (b), synaptophysin (c) and AE1/AE3 (d)

and imaging studies (chest/abdominal CT scan every second visit or chest radiography in combination with abdominal ultrasound). We noticed no evidence for relapse, even 33 months after initial diagnosis of SCBC.

Discussion

SCBC is a rare urological disease consequently associated with obvious limitations in literature and treatment experience leading to the fact that no clear urological-guideline based standard treatment is available for patients suffering from SCBC. To our knowledge, only the Canadian Association of Genitourinary Medical Oncologists recommended in 2013 treating the disease with neoadjuvant (Level 3, Grade C) or adjuvant chemotherapy (Level 4, Grade D) using cisplatin and etoposide (Level 3, Grade C), followed by cystectomy or radiation in a bladder-sparing therapy (Level 3, Grade C) [7].

Focusing on the literature, a multimodal treatment combining cisplatin-based neoadjuvant chemotherapy with radical surgery seems to be most efficacious, whereof chemotherapy has the key role in this therapy concept [8]. However, also bladder preservation multimodality approaches with a maximal complete transurethral resection, followed by radiation therapy and concurrent chemotherapy has demonstrated promising oncological outcomes [9]. Despite of this evidence, in the present case we decided to undergo radical cystoprostatectomy as the primary tumor has a size of 6 cm infiltrating almost the whole right bladder side-wall.

In addition, our patient underwent prophylactic whole-brain radiation as it has been reported that it may be considered and discussed with patients with limited and extensive disease who have had a good clinical response to treatment [7].

In general, the concept of neoadjuvant chemotherapy even if radiography lacks the evidence of metastatic disease, underlines the possibility to treat micrometastatic disease at an early stage and downstage the disease thereby facilitating radical surgery. In addition, as especially cisplatin correlates with numerous side effects, tolerability is higher before than after surgery.

Already 12 years ago Siefker-Radtke et al. [10] compared retrospectively the efficacy of neoadjuvant chemotherapy to surgery alone in a cohort of 46 patients. Thereby they found that the five years cancer specific survival was significantly higher in the chemotherapy group compared to those patients who underwent immediate surgery alone. A consequently performed prospective phase II clinical trial by the same group including 30 patients confirmed the survival benefit of neoadjuvant chemotherapy as part of multimodal treatment in SCBC [11].

In addition, there is evidence that neoadjuvant chemotherapy leads to pathological downstaging to \leq pT1N0 in

62 % of tumors compared to 9 % of patients treated with surgery alone. Our data are in line, or even better as these data, as pathology of the cystoprostatectomy specimen showed complete response, without any evidence for residual tumor after four neoadjuvant cycles of cisplatin/etoposide [12].

In general, SCBC primarily affects males aged between 60–80 years with a history of heavy smoking (reviewed in [13]). Interestingly, the present patient did not report a history of smoking, indicating that other risk factors induce genetic aberrations, mutations or epigenetic alterations. Thus, we feel the importance of further studies investigating this issue.

Reviewing the literature, median overall survival in patients who were metastasis-free at primary diagnosis was 8.3 months [5]. The patient presented in the manuscript has currently a disease-free OS of 33 months.

However, one has to consider that our case harbored an initial T2 GIII stage, with a complete response (pT0 N0) after neoadjuvant chemotherapy underlying the importance of a multimodal treatment concept. This might be of importance as Choong et al. [14] showed that higher stages are associated with poor outcome. On the other hand, our patient had a large tumor (6 cm) and—in line with urothelial cancers of the bladder tumor size >3 cm may be classified as a high risk tumor. Again, the fact that the patient had no smoking history possibly influences this extraordinary satisfactory outcome.

However, in summary we can assume that early multimodal treatment may help to diminish recurrence or progression rates in patients with SCBC.

Conclusion

SCBC is a rare and very aggressive disease with a median overall survival rate of 8.3 months. Multimodal treatment has been shown to be superior to local therapy alone. Early multimodal therapy may result in long term disease free survival, thus we highly recommend neoadjuvant chemotherapy as a part of multimodal management of a primary metastases-free, localized and surgically resectable SCBC.

Abbreviations

OS: overall survival; PET/CT: positron emission tomography/computed tomography; MRT: magnet resonance tomography; SCBC: small cell bladder cancer; WBRT: whole brain radiotherapy.

Authors' contributions

IH, RP, GT manuscript. GS pathology. WH supervision, surgery. All authors read and approved the final manuscript.

Author details

¹ Department of Urology, Medical University Innsbruck, Anichstrasse 35, 6020 Innsbruck, Austria. ² Division of General Pathology, Department of Pathology, Medical University Innsbruck, Innsbruck, Austria.

Competing interests

The authors declare that they have no competing interests.

Received: 4 August 2016 Accepted: 6 October 2016

Published online: 13 October 2016

References

- Blomjous CE, Vos W, De Voogt HJ, et al. Small cell carcinoma of the urinary bladder. A clinicopathologic, morphometric, immunohistochemical, and ultrastructural study of 18 cases. *Cancer*. 1989;64:1347–57.
- Lopez JI, Angulo JC, Flores N, Toledo JD. Small cell carcinoma of the urinary bladder. A clinicopathological study of six cases. *Br J Urol*. 1994;73:43–9.
- Mazzucchelli R, Scarpelli M, Galosi AB, Lopez-Beltran A, Cheng L, Montironi R. "Pathology of the Bladder" (Capitolo di Libro Internazionale), p. 26–39, October 2015, in *Advances in Bladder Cancer Management*, Copyright © 2015 Future Medicine Ltd, doi: [10.2217/9781780844237](https://doi.org/10.2217/9781780844237), eISBN (PDF): 978-1-78084-423.
- Williamson SR, Zhang S, Yao JL, et al. ERG-TMPRSS2 rearrangement is shared by concurrent prostatic adenocarcinoma and prostatic small cell carcinoma and absent in small cell carcinoma of the urinary bladder: evidence supporting monoclonal origin. *Mod Pathol*. 2011;24(8):1120–7.
- Wang X, Zhang S, MacLennan GT, et al. Epidermal growth factor receptor protein expression and gene amplification in small cell carcinoma of the urinary bladder. *Clin Cancer Res*. 2007;13(3):953–7.
- Geynisman DM, Handorf E, Wong YN, et al. Advanced small cell carcinoma of the bladder: clinical characteristics, treatment patterns and outcomes in 960 patients and comparison with urothelial carcinoma. *Cancer Med*. 2016;5(2):192–9. doi:[10.1002/cam4.577](https://doi.org/10.1002/cam4.577) **Epub 2015 Dec 18.**
- Moretto P, Wood L, Emmenegger U, et al. Management of small cell carcinoma of the bladder: consensus guidelines from the Canadian Association of Genitourinary Medical Oncologists (CAGMO). *Can Urol Assoc J*. 2013;7:E44–56.
- Celik O, Ekin G, Ipekci T, et al. Diagnosis and treatment in primary bladder small cell carcinoma: literature review. *Arch Ital Urol Androl*. 2016;88(1):52–5.
- Mak RH, Hunt D, Shipley WU, et al. Long-term outcomes in patients with muscle-invasive bladder cancer after selective bladder-preserving combined-modality therapy: a pooled analysis of Radiation Therapy Oncology Group protocols 8802, 8903, 9506, 9706, 9906, and 0233. *J Clin Oncol*. 2014;32:3801–9.
- Siefker-Radtke AO, Dinney CP, Abrahams NA, et al. Evidence supporting preoperative chemotherapy for small cell carcinoma of the bladder: a retrospective review of the MD Anderson cancer experience. *J Urol*. 2004;172(2):481–4.
- Siefker-Radtke AO, Kamat AM, Grossman HB, et al. Phase II clinical trial of neoadjuvant alternating doublet chemotherapy with ifosfamide/doxorubicin and etoposide/cisplatin in small-cell urothelial cancer. *J Clin Oncol*. 2009;27(16):2592–7.
- Lynch SP, Shen Y, Kamat A, et al. Neoadjuvant chemotherapy in small cell urothelial cancer improves pathologic downstaging and long-term outcomes: results from a retrospective study at the MD Anderson Cancer Center. *Eur Urol*. 2013;64(2):307–13.
- Thota S, Kistangari G, Daw H, et al. A clinical review of small-cell carcinoma of the urinary bladder. *Clin Genitourin Cancer*. 2013;11(2):73–7.
- Choong NW, Quevedo JF, Kaur JS. Small cell carcinoma of the urinary bladder. The Mayo clinic experience. *Cancer*. 2005;103(6):1172–8.

Submit your next manuscript to BioMed Central and we will help you at every step:

- We accept pre-submission inquiries
- Our selector tool helps you to find the most relevant journal
- We provide round the clock customer support
- Convenient online submission
- Thorough peer review
- Inclusion in PubMed and all major indexing services
- Maximum visibility for your research

Submit your manuscript at
www.biomedcentral.com/submit

