

This is an Open Access article licensed under the terms of the Creative Commons Attribution-NonCommercial 3.0 Unported license (CC BY-NC) (www.karger.com/OA-license), applicable to the online version of the article only. Distribution permitted for non-commercial purposes only.

Association of Cryptogenic Organizing Pneumonia in Bilateral Anterior Uveitis

Kaori Fujimoto Miki Hiraoka Shuichiro Inatomi Hiroshi Ohguro

Department of Ophthalmology, School of Medicine, Sapporo Medical University,
Sapporo, Japan

Key Words

Bilateral uveitis · Cryptogenic organizing pneumonia · Hypopyon · Systemic corticosteroid administration

Abstract

Two female patients with histories of cancer who showed cryptogenic organizing pneumonia (COP) complications and bilateral anterior uveitis with hypopyon were examined. Both patients had suffered from COP and received intermitted systemic corticosteroid administration (SCA). The first patient, a 65-year-old woman with a history of breast cancer, showed bilateral uveitis with hypopyon. The topical corticosteroid treatment was ineffective. After SCA for the treatment of COP was started, the hypopyon gradually dissipated. Upon termination of SCA, uveitis relapses were controlled by renewed SCA. The other patient, a 69-year-old woman with a history of ovarian cancer, showed bilateral anterior uveitis with hypopyon. Her intraocular outcome did not improve by the topical corticosteroid administration, but SCA that was applied to treat COP led to remission of uveitis. Imaging examinations, biochemical analysis, symptoms or HLA-B27 antigen screenings in either patient did not explain the development of uveitis. Bilateral anterior uveitis is commonly related to autoimmune disease or systemic syndrome. We report two cases with COP that developed bilateral anterior uveitis with hypopyon resistant to topical administration but responsive to systemic administration of corticosteroid. These findings suggest that COP can be associated with the etiology of anterior uveitis.

© 2014 S. Karger AG, Basel

Miki Hiraoka, MD, PhD
S1 W16 Chuo-ku
Sapporo, Hokkaido 060-8543 (Japan)
E-Mail mikihira@sapmed.ac.jp

Introduction

Cryptogenic organizing pneumonia (COP), also known as bronchiolitis obliterans organizing pneumonia (BOOP), is a relatively rare disorder with distinctive clinical, imaging and pathological features. The pathological findings are characterized by plugs of granulation tissue lying within small airways, alveolar ducts and alveoli and by chronic inflammatory cell infiltration in the alveolar walls. COP is defined as idiopathic and any cause for the development of pneumonia such as infection or underlying tissue disease is excluded. Patients with COP manifest rapid clinical and imaging improvement with corticosteroid therapy [1], but suffer from frequent relapses.

Through histopathological examination and clinical observation, uveitis is usually classified into two categories, granulomatous and nongranulomatous. Hypopyon is the accumulation of white blood cells in the anterior chamber and is often observed in nongranulomatous uveitis. Nongranulomatous presentations are mostly idiopathic or due to HLA-B27 antigen involvement [2–4]. It is well known that systemic diseases that can be associated with nongranulomatous uveitis include Behçet's disease, ankylosing spondylitis, inflammatory bowel disease and psoriasis [4]. Although the cause is not fully disclosed, certain ocular and systemic conditions might be the underlying association with nongranulomatous uveitis.

In this report, we describe two cases of COP who developed bilateral anterior uveitis with hypopyon unresponsive to topical corticosteroid therapy but responsive to systemic corticosteroid therapy. In addition, the clinical condition of their COP was concomitant to that of their intraocular inflammation.

Case Presentations

The medical records of 2 patients with COP were retrospectively reviewed.

Case 1

A 65-year-old woman was referred for evaluation of bilateral decreased vision and glaucoma. She had undergone a series of treatment for breast cancer with surgery, radiation and chemotherapy 14 years earlier. Additionally, she had been regularly examined and treated for COP. Concerning her ocular history, she had been diagnosed as having an epiretinal macular membrane on her right eye and received a vitrectomy and phacoemulsification 3 years prior. One year later, her right eye had developed uveitis and secondary glaucoma. The intraocular inflammation was resistant to topical betamethasone administration but decreased spontaneously in 1 year. Despite the uveitis being mostly controlled, the intraocular pressure in both eyes had gradually increased and she was referred to our hospital.

The initial ophthalmic examination disclosed a best-corrected visual acuity (BCVA) of 20/50 in the right eye and 20/80 in the left eye. The intraocular pressure was 25 mm Hg in the right and 40 mm Hg in the left eye. Slit-lamp examination demonstrated no sign of uveitis or retinal disease besides pseudophakia in the right eye and a cataract in the left eye. Both eyes showed substantial anterior chamber depth without goniosynechia. The results of the laboratory investigations of serum including angiotensin-converting enzyme, antinuclear antibodies, rheumatoid factor and antineutrophil cytoplasmic antibodies were unremarkable despite for the presence of elevated C-reactive protein. Serological analyses indicated that there was no active infection of syphilis, human T-cell lymphoma virus 1, herpes

simplex virus or varicella zoster virus. The results of human leukocyte antigen type B testing were positive for B-60 and B-61. The expectoration culture was negative for tuberculosis.

After admission, the patient underwent phacoemulsification surgery with intraocular lens implantation and a viscocanalostomy in the left eye for her cataract and glaucoma. Her BCVA improved to 20/40 in the right eye and 20/32 in the left eye, and both the intraocular inflammation and intraocular pressure were controlled. Five months later, the cellular infiltration with hypopyon in the anterior chamber was seen in both eyes (fig. 1a). Topical betamethasone drops were applied with little positive response. Then, the patient received systemic prednisolone (PSL) 40 mg/day administered orally to treat the aggravated COP, and both lung symptoms and intraocular inflammation diminished. When PSL dosage was reduced to 5 mg/day during tapering, cellular infiltration in the anterior chamber and hypopyon relapsed and BCVA of her eyes, particularly of her left eye, declined despite administration of topical dexamethasone. An optical coherence tomography (OCT) examination showed a macular edema in her left eye (fig. 1b). Although a subconjunctival triamcinolone injection was given when her left BCVA reached 20/200, there was little improvement. Then, oral PSL was increased to 30 mg/day, and the intraocular inflammation subsequently decreased and her BCVA gradually recovered (fig. 2). At 24 months, yttrium-aluminum-argon (YAG) laser treatment was performed to treat posterior capsule opacification in her left eye. During the clinical course, there was temporal intraocular pressure elevation, which could be maintained by topical antiglaucoma medication.

At the middle of the relapse period, the aqueous humor of the left eye was collected. Cytological examination of infiltrated cells in the anterior chamber showed neutrophils and a few lymphocytes, but no atypical cell. The genomic DNA in aqueous humor was analyzed to screen infectious pathogens including bacteria, parasites, and viruses by comprehensive polymerase chain reaction. No pathogen was detected. During observation, there were no physical findings of skin disease, oral aphtha, pudendal ulcers, joint inflammation, spondylitis or digestive symptoms.

Case 2

A 69-year-old woman presented with blurred vision in both eyes. She had undergone treatment for ovarian cancer with surgery 8 years earlier. In addition, she had been regularly examined and treated for COP and nephrolithiasis. Her ocular history expressed age-related macular degeneration in both eyes 6 years prior. Three years later, she had developed uveitis in both eyes. The topical betamethasone administration was not effective to treat the intraocular inflammation. Subsequently, she was referred to our hospital.

The initial ophthalmic examination disclosed a BCVA of 20/25 in the right eye and 20/20 in the left eye. The intraocular pressure was 12 mm Hg in both eyes. Slit-lamp examination demonstrated bilateral fine keratic precipitates, hypopyon and intensive cell infiltration in the anterior chamber. There was a mild cataract but no sign of posterior uveitis or diabetic change in the retina. The clinical course is described in fig. 3. The results of the laboratory investigations of serum including angiotensin-converting enzyme, antinuclear antibodies, rheumatoid factor, and antineutrophil cytoplasmic antibodies were unremarkable despite for the presence of elevated C-reactive protein and HbA1c (7.1%). Serological analyses showed no active infection of syphilis, human T-cell lymphoma virus 1, herpes simplex virus or varicella zoster virus. The results of human leukocyte antigens type B testing were positive for B-51 and B-61.

Frequent topical betamethasone drops were applied, but there was little response. One month later, she was administered systemic PSL 40 mg/day orally to treat COP. The intraocular cell infiltration and hypopyon diminished in 1 month. During PSL tapering,

bilateral visual loss emerged. An OCT examination showed an epiretinal membrane and macular edema in both eyes (fig. 1c). After 6 months, the macular edema improved spontaneously and BCVA recovered to 20/20. The PSL administration was reduced gradually and then halted, with no recurrence of uveitis. Temporal intraocular pressure elevation was observed and was controlled with topical antiglaucoma medication.

This case had no relapse. Therefore, the cytological examination of infiltrated cells in the anterior chamber or the genomic DNA analysis of infectious pathogens was not performed. During observation, there were no physical findings of skin disease, oral aphtha, pudendal ulcers, joint inflammation, spondylitis or digestive symptoms.

Discussion

In the present study, we described two cases that had common points in their phenotype. First, both cases showed bilateral anterior uveitis with hypopyon. Their intraocular inflammation was unresponsive to the administration of topical corticosteroids but showed a greater response to systemic corticosteroid administration (SCA). Furthermore, both patients were receiving treatments for COP, and had medical histories of malignant tumors. However, neither was identified with any systemic disease that could be associated with uveitis.

The causes of uveitis vary and include infection, autoimmune disease and malignant tumors. Hypopyon is mostly observed at nongranulomatous anterior uveitis, and occasionally seen at sarcoidosis. Nongranulomatous uveitis is characterized by fine keratic precipitates, and in severe cases, fibrinous clotting or hypopyon in the anterior chamber. The most common form of nongranulomatous anterior uveitis is acute anterior uveitis, which is associated with the HLA-B27 allele [2, 3, 5]. The ocular feature of HLA-B27-associated acute anterior uveitis is acute onset of unilateral inflammation, and is common in males between the ages of 20–40 years. In this series, both cases were HLA-B27 negative, and the uveitis was bilateral. Other diseases that could be associated with uveitis were screened [4]. By the absence of systemic symptoms such as skin lesion, genital ulcer, oral aphtha and digestive symptoms, Behçet's disease was ruled out. The laboratory investigations also eliminated the involvement of ankylosing spondylitis, arthritis, inflammatory bowel disease, sarcoidosis and infection. Furthermore, the ophthalmological outcome excluded Fuchs heterochromic iridocyclitis and Posner-Schlossman syndrome. In addition, several drugs including cidofovir and rifabutin are reported to induce uveitis [6]. In the present study, neither patient had taken those medicines during the period in which they contracted uveitis. It is also known that the malignant neoplasm can introduce hypopyon that resembles intraocular inflammation [7–9]. Both patients had a medical history of cancer treated several years ago. Since they had not shown any recurrence for several years, it was assumed that their malignancies were controlled. Additionally, the cytological analysis of aqueous humor with cell infiltration in case 1 showed a moderate inflammation pattern without neoplastic cell. Through the follow-up period of ovarian cancer without anticancer therapy in case 2, there was no sign of recurrent cancer or metastasis. From these facts, it is unlikely that their malignancy is associated with uveitis in their eyes.

COP is diagnosed by its typical pathological findings of organizing pneumonia and the absence of any identified cause. It affects men and women between 50 and 60 years equally [10]. The organizing pneumonia occurs in cases of autoimmune diseases such as rheumatoid arthritis and Sjögren's syndrome [11]. Several reports have described how COP accompanies uveitis as a part of Behçet's disease [12, 13]. In those cases, SCA was required to treat uveitis.

Although the uveitis in our report developed concomitant to COP, there was no clinical indication to suggest a diagnosis of Behçet's disease. Additionally, the anterior uveitis in our patients was resistant to topical corticosteroid drops, which rarely occurs during anterior uveitis care. When systemic corticosteroid for COP was applied, the hypopyon vanished. This suggests that anterior uveitis in our cases was associated with COP. At present, there is one report that describes the complications of COP and uveitis without any cause [14]. In this case, bilateral nongranulomatous uveitis was unresponsive to topical corticosteroid treatment, but systemic corticosteroid treatment had a more positive effect.

The present findings suggest the possibility that there is a novel cause of uveitis that shares the same etiology with COP. Further investigation with increased numbers of case studies and statistical analysis may result in the discovery of new symptoms for uveitis and COP.

Acknowledgements

We would like to thank Prof. Greg Wheeler for kindly reading and providing careful advice regarding the manuscript.

Disclosure Statement

None.

References

- 1 Cordier JF: Cryptogenic organizing pneumonia. *Clin Chest Med* 2004;25:727–738, vi–vii.
- 2 D'Alessandro LP, Forster DJ, Rao NA: Anterior uveitis and hypopyon. *Am J Ophthalmol* 1991;112:317–321.
- 3 Chang JH, McCluskey PJ, Wakefield D: Acute anterior uveitis and HLA-B27. *Surv Ophthalmol* 2005;50:364–388.
- 4 Pan J, Kapur M, McCallum R: Noninfectious immune-mediated uveitis and ocular inflammation. *Curr Allergy Asthma Rep* 2014;14:409.
- 5 Zaidi AA, Ying GS, Daniel E, Gangaputra S, Rosenbaum JT, Suhler EB, Thorne JE, Foster CS, Jabs DA, Levy-Clarke GA, Nussenblatt RB, Kempen JH: Hypopyon in patients with uveitis. *Ophthalmology* 2010;117:366–372.
- 6 Moorthy RS, London NJ, Garg SJ, Cunningham ET Jr: Drug-induced uveitis. *Curr Opin Ophthalmol* 2013;24:589–597.
- 7 Ayliffe W, Foster CS, Marcoux P, Upton M, Finkelstein M, Kuperwaser M, Legmann A: Relapsing acute myeloid leukemia manifesting as hypopyon uveitis. *Am J Ophthalmol* 1995;119:361–364.
- 8 Gruenewald RL, Perry MC, Henry PH: Leukemic iritis with hypopyon. *Cancer* 1979;44:1511–1513.
- 9 Yi DH, Rashid S, Cibas ES, Arrigg PG, Dana MR: Acute unilateral leukemic hypopyon in an adult with relapsing acute lymphoblastic leukemia. *Am J Ophthalmol* 2005;139:719–721.
- 10 Alasaly K, Muller N, Ostrow DN, Champion P, FitzGerald JM: Cryptogenic organizing pneumonia. A report of 25 cases and a review of the literature. *Medicine (Baltimore)* 1995;74:201–211.
- 11 Cordier JF: Organising pneumonia. *Thorax* 2000;55:318–328.
- 12 Erkan F: Pulmonary involvement in Behcet disease. *Curr Opin Pulm Med* 1999;5:314–318.
- 13 Nanke Y, Kobashigawa T, Yamada T, Kamatani N, Kotake S: Cryptogenic organizing pneumonia in two patients with Behcet's disease. *Clin Exp Rheumatol* 2007;25:S103–S106.
- 14 Saito W, Saito A, Namba K, Kase S, Shiratori M, Ohno S: Chronic panuveitis and scleritis in a patient with cryptogenic organizing pneumonia. *Jpn J Ophthalmol* 2006;50:558–561.
- 15 Jabs DA, Nussenblatt RB, Rosenbaum JT: Standardization of uveitis nomenclature for reporting clinical data. Results of the First International Workshop. *Am J Ophthalmol* 2005;140:509–516.

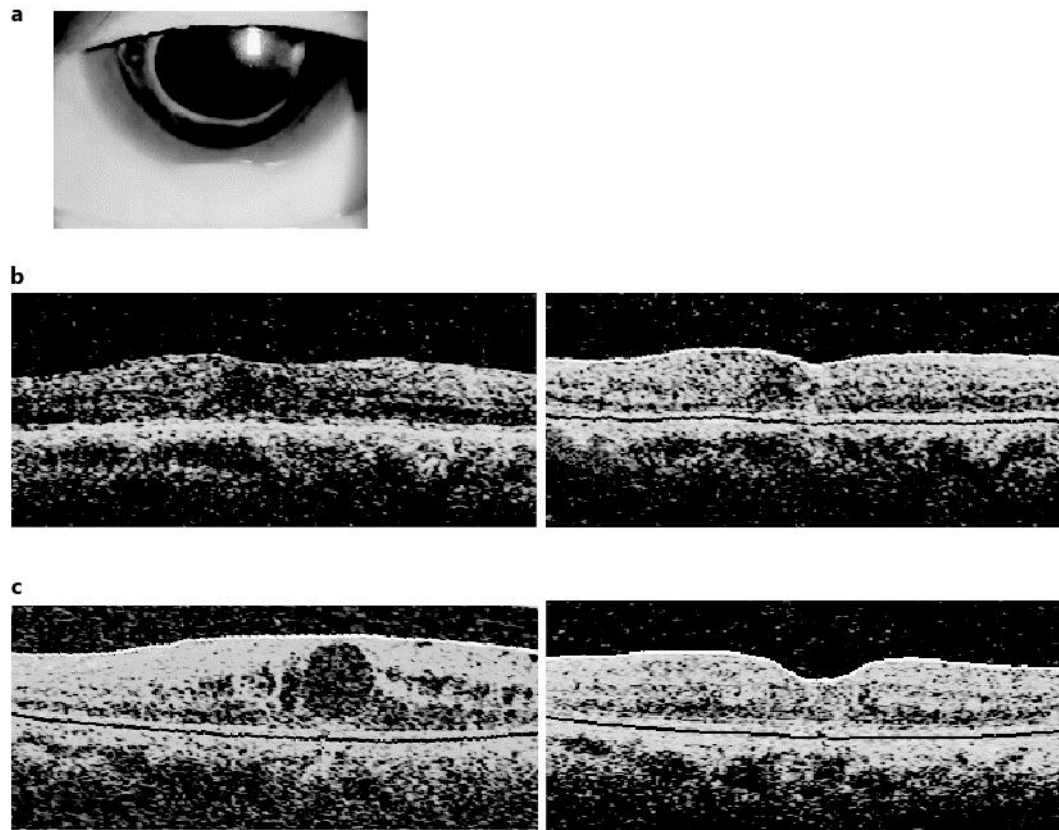


Fig. 1. **a** Slit-lamp photograph of case 1 with hypopyon in the anterior chamber of her left eye. **b** OCT image at the macular area of case 1 (left eye). At 18 months, the patient's left eye developed a macular edema (left panel). At 25 months, the macular edema decreased (right panel). **c** OCT image at the macular area of case 2 (left eye). At 2 months, her left eye developed cystic macular edema (left panel). At 24 months, the macular edema decreased (right panel).

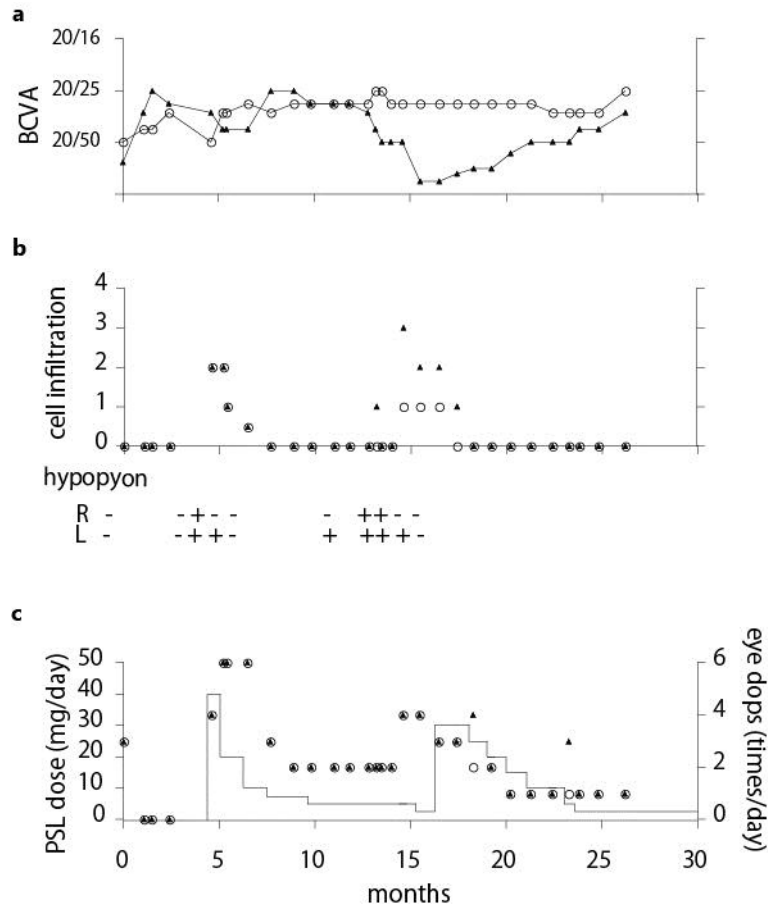


Fig. 2. Clinical course of case 1. **a** The transition of the BCVA is presented. The vertical axis shows the scale of fractional visual acuity. **b** The extent of anterior uveitis is presented. The graph displays the cell infiltration in the anterior chamber. The grade is evaluated based on a previous study [15]. The presence of hypopyon is listed below. **c** The administration of corticosteroid is presented. The columns indicate the dose of oral PSL. The dose volume is indicated by the left vertical axis. Betamethasone eye drops are displayed as circles or triangles with their frequency indicated by the right vertical axis. An open circle indicates the right eye, and a closed triangle represents the left eye. The horizontal axis displays (in months) the duration of observation.

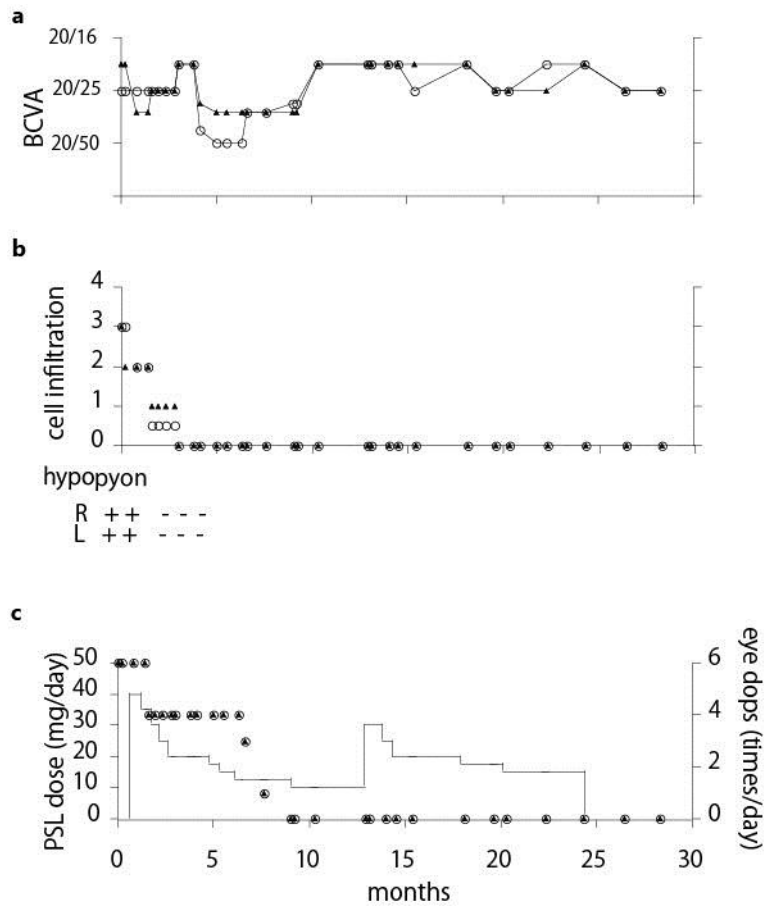


Fig. 3. Clinical course of case 2. **a** The transition of the BCVA is presented. The vertical axis shows the scale of fractional visual acuity. **b** The extent of anterior uveitis is presented. **c** The administration of corticosteroid is presented. The notations are the same as in fig. 2.