



Contents lists available at ScienceDirect

## International Journal of Surgery Case Reports

journal homepage: [www.casereports.com](http://www.casereports.com)

## Massive intrathoracic lipoma in men1 syndrome



Alessandro Sturiale<sup>a,\*</sup>, Francesco Giudici<sup>a</sup>, Giovanni Alemanno<sup>a</sup>, Tiziana Cavalli<sup>a</sup>,  
Rami Addasi<sup>a</sup>, Carmine Santomaggio<sup>b</sup>, Giulia Meoni<sup>c</sup>, Maria Luisa Brandi<sup>d</sup>,  
Francesco Tonelli<sup>a</sup>

<sup>a</sup> Digestive Surgery Unit, Department of Surgery and Translational Medicine, University of Florence Medical School, Careggi University Hospital, Florence, Italy

<sup>b</sup> Department of Pneumology, University of Florence Medical School, Careggi University Hospital, Florence, Italy

<sup>c</sup> Department of Oncology, Medical Oncology 1, Careggi University Hospital, Florence, Italy

<sup>d</sup> Regional Centre for Hereditary Endocrine Tumors, Unit of Metabolic Bone Diseases, Department of Internal Medicine, University of Florence, Florence, Italy

## ARTICLE INFO

## Article history:

Received 24 February 2014

Received in revised form 17 October 2014

Accepted 18 October 2014

Available online 12 December 2014

## Keywords:

Intrathoracic lipoma

MEN 1 syndrome

Surgery

GEP-NET

## ABSTRACT

**INTRODUCTION:** The multiple endocrine neoplasia type 1 (MEN1) is a rare autosomal dominant syndrome characterized by the onset of hyperparathyroidism, gastroenteropancreatic neuroendocrine tumors and pituitary lesions.

**PRESENTATION OF CASE:** This appears to be the first described case of a massive intrathoracic lipoma in MEN1. The patient was affected with primary hyperparathyroidism treated with a total parathyroidectomy followed by a distal pancreatectomy for insulinoma. At follow-up, the computed tomography showed a massive lesion on the left emithorax suggestive of a lipoma. At the onset of a mild dyspnea we decided to perform the surgical excision of the mass obtaining a complete relief of the symptoms.

**DISCUSSION:** This case is evidence of the importance of a strict follow-up of such patients.

**CONCLUSION:** Lipomas are the most frequent benign soft tissue tumors. They are usually sporadic but are sometimes related to hereditary syndromes. Intrathoracic localizations are rare and can arise mainly in the mediastinum, bronchus or lung. The diagnosis is often incidental; despite preoperative imaging will accurately show the features of the lesions, it is impossible obtain an accurate diagnosis-hence, the treatment of choice remains the surgical excision.

© 2014 The Authors. Published by Elsevier Ltd. on behalf of Surgical Associates Ltd. This is an open access article under the CC BY-NC-ND license (<http://creativecommons.org/licenses/by-nc-nd/3.0/>).

## 1. Introduction

The multiple endocrine neoplasia type 1 syndrome (MEN1) is a rare autosomal dominant hereditary cancer syndrome characterized by the development of endocrine tumors in different sites. The most frequent organs involved are the parathyroid glands, the endocrine pancreas and the anterior pituitary gland, sometimes associated with less frequent manifestations such as lipomas, carcinoid, adrenal tumors, skin angiofibromas and other types.<sup>1</sup> Lipomas originate from adipocytes with a prevalence rate of 2.1 per 1000 individuals and account for almost 80% of benign soft tissue tumors. They are frequent in adults and usually asymptomatic. These tumors develop, most likely, in subcutaneous tissue, but may occur in deeper sites making the diagnosis more difficult. They are

generally well-capsulated, slow-growing and may appear single or in clusters. Intrathoracic localizations are extremely rare and can occur at different sites such as in the bronchus, lung, diaphragm, mediastinum or thoracic wall.<sup>2</sup> To our knowledge, this appears to be the first case reporting the massive intrathoracic lipoma in MEN1.

## 2. Case presentation

A 33-year-old female patient referred to our department with a diagnosis of primary hyperparathyroidism. Her father had died at the age of 53 with a malignant non-functioning neuroendocrine pancreatic tumor. Her sister had undergone total parathyroidectomy for primary hyperparathyroidism and genetic testing showed frameshift 908 GCT in exon 5 of *MEN1* gene. Our patient appeared to have the same *MEN1* gene mutation. Furthermore, she had breast cancer 1 (*BRCA-1*) gene exon 11 mutation, inherited from her mother. The first surgery performed was a total parathyroidectomy with autotransplantation of a fragmented gland in a non-dominant forearm. After several months later the patient developed hypoglycaemic symptoms with a positive glucose fasting test and was diagnosed insulinoma. Abdominal

**Abbreviations:** MEN1, multiple endocrine neoplasia 1; BRCA-1, breast cancer 1; CT, computerized tomography; MRI, magnetic resonance imaging; MDM-2, mouse double minute 2; LOH, loss of heterozygosity; CDK-4, cyclin-dependent kinase 4.

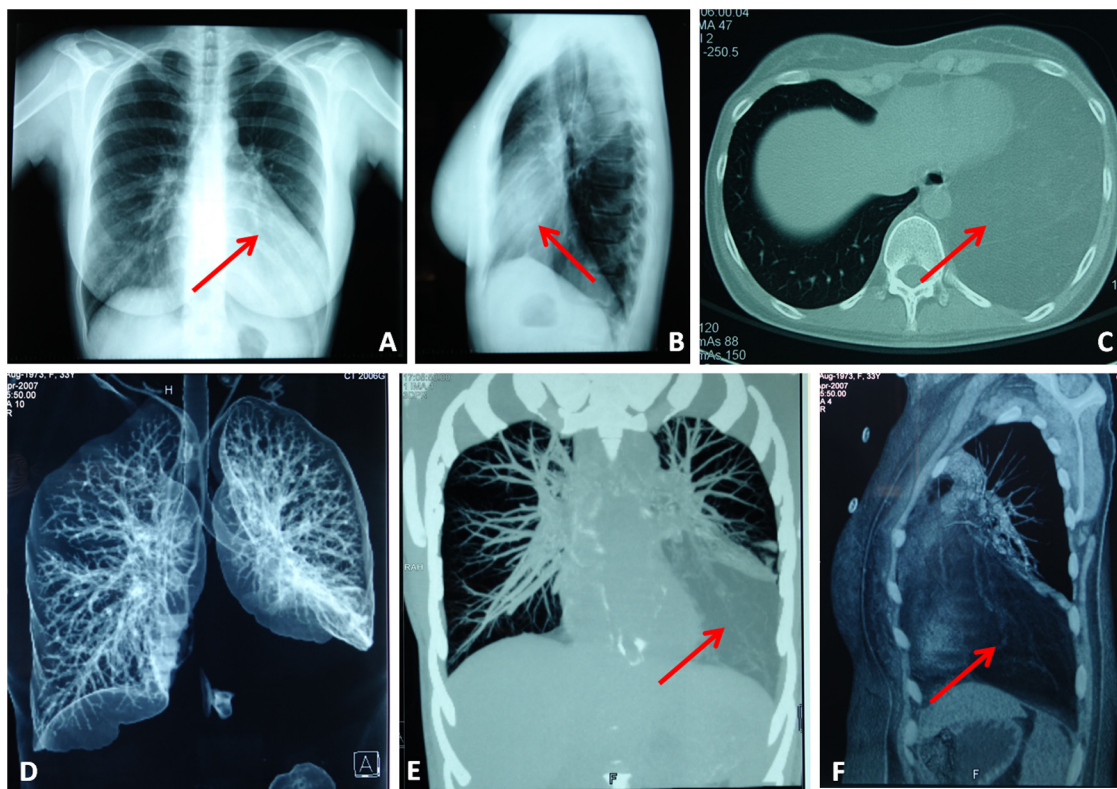
\* Corresponding author at: Largo Brambilla 3, 50134 Florence, Italy.

Tel.: +39 055 7947449; fax: +39 055 7947449.

E-mail addresses: [alexstur@yahoo.it](mailto:alexstur@yahoo.it), [a.sturialemd@gmail.com](mailto:a.sturialemd@gmail.com) (A. Sturiale).

<http://dx.doi.org/10.1016/j.ijscr.2014.10.071>

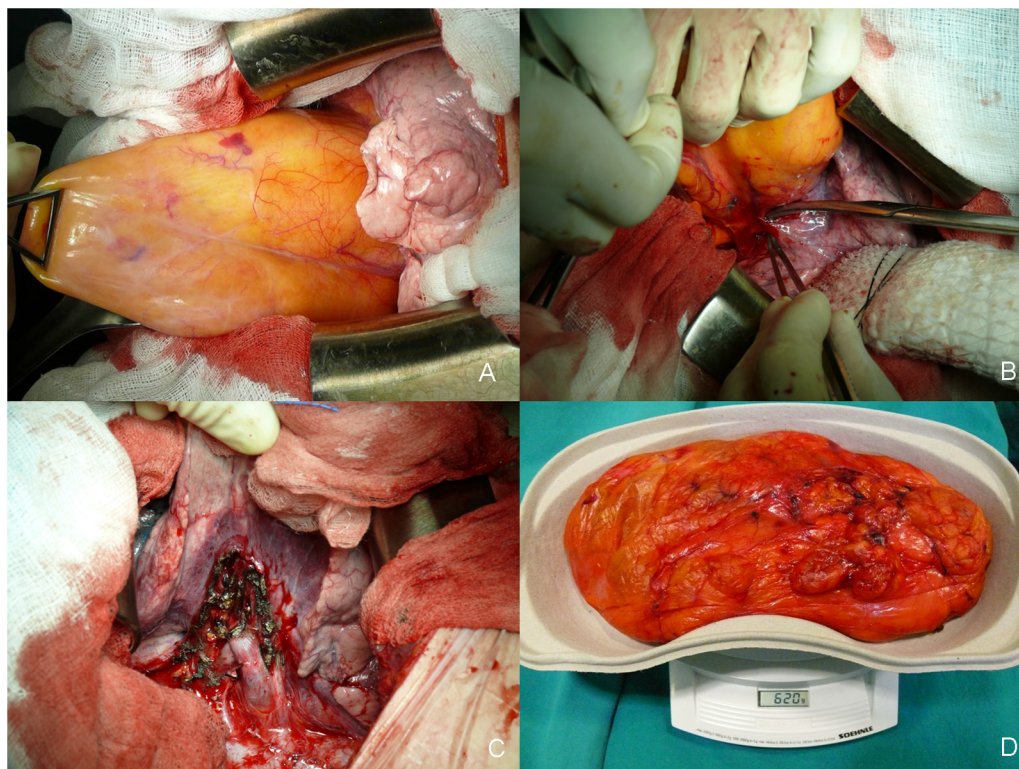
2210-2612/© 2014 The Authors. Published by Elsevier Ltd. on behalf of Surgical Associates Ltd. This is an open access article under the CC BY-NC-ND license (<http://creativecommons.org/licenses/by-nc-nd/3.0/>).



**Fig. 1.** Frontal (A) and lateral (B) chest X-ray. Transverse (C) and frontal (E) computed tomography section. Tridimensional lung (D) and lipoma (F) Computed Tomography reconstruction. Lipoma is indicated by arrows.

computed tomography (CT) showed three pancreatic nodules with a 10–15 mm diameter, two of which were located in the pancreatic tail and another one in the head. Pancreatic surgery was, therefore, scheduled. A preoperative chest X-ray showed atelectatic left

lower lung lobe (Fig. 1A and B). Endobronchial lesions were ruled out by bronchoscopy. Due to a persistence hypoglycaemic crisis and no respiratory symptoms with normal arterial blood gas analysis, distal pancreatectomy was performed, extended to the



**Fig. 2.** Intrathoracic lipoma (A), isolation of its peduncle (B, C); excised lipoma (D).



pancreatic body with enucleation of a pancreatic head nodule. The post-operative course was complicated by intra-abdominal hemorrhage demanding surgical hemostasis. Subsequently, the patient developed pancreatic a pseudo-cyst with an 8 cm diameter which was drained percutaneously. The patient was discharged on the 13th post-operative day and a control CT was scheduled to check out the thoracic findings described preoperatively. A massive lesion (Fig. 1C–F) compatible with lipomatous tissue was outlined. The patient developed a mild dyspnea. After counseling, excision of the intrathoracic mass was scheduled. Thoracotomy at 6th left intercostal space was performed, accurately detaching the mass from the phrenic nerve and the left inferior lobe. The lesion originated from the inferior bronchus; a complete excision was performed with the ligation of its vascular pedicle. The postoperative course was uneventful and the patient was discharged one week later. The histopathological examination showed a 16 cm × 12 cm × 7 cm, 620-g, mature lipoma (Fig. 2A and B). The immunohistochemical examination was negative for the Mouse Double Minute 2 (MDM-2) protein. Following surgery the patient had a complete relief of dyspnea. She is being accurately followed up and there is no evidence of signs of MEN-1 related manifestations.

### 3. Discussion

The MEN1 incidence is 1/30,000 individuals/year with a very high penetrance and equitable gender distribution. The familial form is characterized by a MEN1 case with one relative affected by one of the typical endocrine neoplasias. The typical tumors of such syndrome develop in different organs such as parathyroid glands, endocrine pancreas and the anterior pituitary gland. In association with these lesions, other endocrine and non-endocrine tumors, such as adrenal tumors, carcinoids, angiofibromas and lipomas have been reported. This may be helpful in the early diagnosis of MEN1, before hormone-secreting tumors signs appear. The published incidence of lipomas in patients with MEN1 syndrome is wide ranging from 5% to 34%.<sup>10</sup> The pathogenesis of the disease is based on the loss of heterozygosity (LOH) of *MEN1* gene, mapped on chromosome 11q13, which encodes a 610 aminoacid nuclear protein. The mutation causes the inactivation of *MEN1* tumor-suppressor gene, involved in the regulation of DNA replication and repair.<sup>1</sup> There is evidence in literature which proves which is the role of *MEN1* gene in the pathogenesis of less specific MEN1 tumors, such as carcinoids and lipomas. More evidence showed that *MEN1* mutation may be involved in the development of both MEN1-associated and sporadic lipomas and that 11q13 LOH can vary in different tumors in the same patient. This suggests that the tumorigenesis is an independent somatic event involving the wild-type allele, which can occur in different tissues.<sup>3</sup> Studies conducted on sporadic lipomas show cytogenetic aberrations involving the 12q13–q15 regions but it is argued whether all lipomas share one or more of the same breakpoint sites. It has been described that lipomas with breakpoints in 12q13 and 12q14 and those with normal karyotypes are clinically and histologically indistinguishable.<sup>4</sup> Lipomas are the most frequent benign soft tissue tumors and their

incidence is not dependent on sex and age. They usually become symptomatic in case of compression of the surrounding structures. The intrathoracic localization is rare, and the main symptom is dyspnea.<sup>2</sup> The diagnosis is often incidental, following chest X-ray, as in our case; the X-ray examination showed, a lipoma having a soft tissue density and occasionally a clear peripheral zone around the tumor. Nevertheless further investigations such as CT or MRI are needed to differentiate a lipoma from other lesions and to evaluate the relationship with the nearby structures. CT scan findings suggestive of lipoma are the presence of non-calcificating lesion with smooth rounded edges, originating from structures containing adipose tissue such as mediastinum, diaphragm, bronchus, lung or thoracic wall, with a density of –50 to –150 HU. MRI, instead, is performed when a liposarcoma is suspected.<sup>5</sup> Although there are differences in radiological imaging between lipoma and liposarcoma, the definitive diagnosis is achieved only by means of a histopathological examination.<sup>6</sup> Lipomas are composed by sheets of mature adipocytes without any mitotic activity and are separated by incomplete fibrous septa. Liposarcomas have five histological subtypes among which there is the well-differentiated and dedifferentiated form. The former is characterized by the presence of lipoblasts and atypical stromal cells with several mitoses and hyperchromatic nuclei inside a mature fat tissue. The latter, instead, has a morphology which is very similar to a fibrosarcoma or a histiocytoma and it is generally close to well-differentiated elements. The immunohistochemical stain showing the MDM-2 and cyclin-dependent kinase 4 (CDK-4) hyperexpression enables a certain diagnosis of dedifferentiated liposarcoma.<sup>7</sup> Surgery is the treatment of choice for such lesions.<sup>8</sup> The recurrence rate after excision is of about 5%. The surgical resection should, therefore, be radical although some reports show that the mass growth may be halted even after incomplete removal.<sup>9</sup>

### 4. Conclusion

Patients with MEN 1 syndrome can develop different tumors in diverse sites. Non-endocrine lesions may, at times, promote diagnosis. Hence, for it is fundamental to follow up these patients very accurately, by means of physical examination and radiological imaging focusing on initial signs and symptoms that might appear.

### Disclosure

None.

### Authors' contribution

All authors contributed to this work: Alessandro Sturiale, Tiziana Cavalli and Carmine Santomaggio collected the data, Francesco Giudici, Alessandro Sturiale and Giovanni Alemanno analyzed data, Alessandro Sturiale, Giovanni Alemanno, Francesco Giudici, Rami Addasi and Giulia Meoni wrote the manuscript and Francesco Tonelli and Maria Luisa Brandi supervised all the manuscript.

### Key learning points

- How to treat a rare case of intrathoracic lipoma in men1 syndrome.
- The importance to follow-up these patients.

## Acknowledgement

Prof. Maria Rosaria Buri, Professional Translator/Aiic Conference Interpreter, University of Salento, for English language editing.

## References

1. Marini F, Falchetti A, Del MF, Carbonell SS, Gozzini A, Luzi E, et al. Multiple endocrine neoplasia type 1. *Orphanet J Rare Dis* 2006;**1**:38.
2. Vougiouklakis T, Mitselou A, Agnantis NJ. Giant lipoma: an unusual cause of intrathoracic mass. *Pathol Res Pract* 2006;**202**(1):47–9.
3. Dong Q, Debelenko LV, Chandrasekharappa SC, Emmert-Buck MR, Zhuang Z, Guru SC, et al. Loss of heterozygosity at 11q13: analysis of pituitary tumors, lung carcinoids, lipomas, and other uncommon tumors in subjects with familial multiple endocrine neoplasia type 1. *J Clin Endocrinol Metab* 1997;**82**(5):1416–20.
4. Merscher S, Marondel I, Pedetour F, Gaudray P, Kucherlapati R, Turc-Carel C. Identification of new translocation breakpoints at 12q13 in lipomas. *Genomics* 1997;**46**(1):70–7.
5. Kato M, Saji S, Kunieda K, Yasue T, Nishio K, Adachi M. Mediastinal lipoma: report of a case. *Surg Today* 1997;**27**(8):766–8.
6. Buesoramos C, Yang Y, Manshoury T, Feltz L, Ayala A, Glassman A, et al. Molecular abnormalities of mdm-2 in human sarcomas. *Int J Oncol* 1995;**7**(5):1043–8.
7. Crago AM, Singer S. Clinical and molecular approaches to well differentiated and dedifferentiated liposarcoma. *Curr Opin Oncol* 2011;**23**(4):373–8.
8. Hagmaier RM, Nelson GA, Daniels LJ, Riker AL. Successful removal of a giant intrathoracic lipoma: a case report and review of the literature. *Cases J* 2008;**1**(1):87.
9. Wurlitzer F, Bedrossian C, Ayala A, McBride C. Problems of diagnosing and treating infiltrating lipomas. *Am Surg* 1973;**39**(4):240–3.
10. Agarwal S, Monsaert RP. Multiple Endocrine Neoplasia Type 1 and Lipomas. *Clinical Review Article. Hospital Physician*; May 2002. p. 51–4. [www.turner-white.com](http://www.turner-white.com)

## Open Access

This article is published Open Access at [sciedirect.com](http://sciedirect.com). It is distributed under the [IJSCR Supplemental terms and conditions](#), which permits unrestricted non commercial use, distribution, and reproduction in any medium, provided the original authors and source are credited.