

Perforation of a Long-standing Ileocolonic Anastomosis During Colonoscopy

Christina J. Tofani, MD¹, Benjamin Phillips, MD², Peter McCue, MD³, Jeffrey Baliff, MD³, and David Kastenberg, MD, FACP, AGAF, FACG¹

¹Department of Gastroenterology, Thomas Jefferson University Hospital, Philadelphia, PA

²Department of Surgery, Thomas Jefferson University Hospital, Philadelphia, PA

³Department of Pathology, Thomas Jefferson University Hospital, Philadelphia, PA

Abstract

Colonoscopy is a valuable diagnostic and therapeutic procedure. Colonic perforation is a serious complication of colonoscopy that must be promptly recognized to limit morbidity and mortality. We present a 69-year-old woman who, during colonoscopy, had a perforation secondary to barotrauma of a long-standing ileocolonic anastomosis proximal to the point of colonoscopic intubation. To our knowledge, this is the first case report of a perforation of a well-established anastomosis proximal to the point of endoscope intubation during colonoscopy.

Introduction

The risks associated with colonoscopy are well-recognized and most commonly include cardiopulmonary events and hemorrhage. Perforation is an uncommon complication, but must be promptly recognized to limit morbidity and mortality. Perforation can occur due to mechanical forces, therapeutic interventions, or barotrauma.¹ The incidence of perforation ranges from 0.016% for diagnostic procedures to as high as 5% for therapeutic colonoscopies.² More than half of perforations occur in the rectosigmoid, and about 10-20% in the cecum.³ Risk factors include advanced patient age (>60 years), female sex, polypectomy, diverticulosis, prior abdominal or pelvic surgery, low-volume endoscopist, severe and active inflammatory bowel disease, and use of systemic steroids.^{4,5} Dehiscence of an anastomosis related to endoscopy is rare, even early in the postoperative period.⁶

Case Report

A 69-year-old woman with pancolonic ulcerative colitis for 31 years presented for colonoscopy to evaluate 6 weeks of painless, non-bloody diarrhea. She had maintained remission for the past 10 years on mesalamine. Medical history included migraines, hypothyroidism, acid reflux, aortic stenosis, and chronic obstructive pulmonary disease. Abdominal surgeries included hysterectomy, cholecystectomy, and ileocectomy 4 years ago for small bowel obstruction due to adhesions. Pathologic review showed viable mucosa without any histologic changes. Additional daily medications included zolpidem, aspirin, metoprolol, mirabegron, omeprazole, levothyroxine, and topiramate. Physical exam was notable for an obese abdomen with well-healed scars. She had normal thyroid-stimulating hormone, IgA, fecal calprotectin, and negative tissue transglutaminase antibody IgA. Stool culture was negative for *Campylobacter*, *Salmonella*, *Shigella*, and *Clostridium difficile*.

The patient underwent colonoscopy by an experienced (>10,000 colonoscopies) gastroenterologist. The sigmoid could not be traversed with a pediatric colonoscope (Olympus® CF-H180AL-4699, Olympus, Center Valley, PA). An adult endoscope (Olympus® GIF-H180, Olympus, Center Valley, PA) was advanced to the mid-transverse

ACG Case Rep J 2015;2(4):221-223. doi:10.14309/crj.2015.65. Published online: July 9, 2015.

Correspondence: Christina J. Tofani, MD, Thomas Jefferson University Hospital, 132 S. 10th St., Main Building, Suite 480, Philadelphia, PA 19107 (christina.tofani@gmail.com).



Copyright: © 2015 Tofani et al. This work is licensed under a Creative Commons Attribution-NonCommercial-NoDerivatives 4.0 International License. To view a copy of this license, visit <http://creativecommons.org/licenses/by-nc-nd/4.0>.

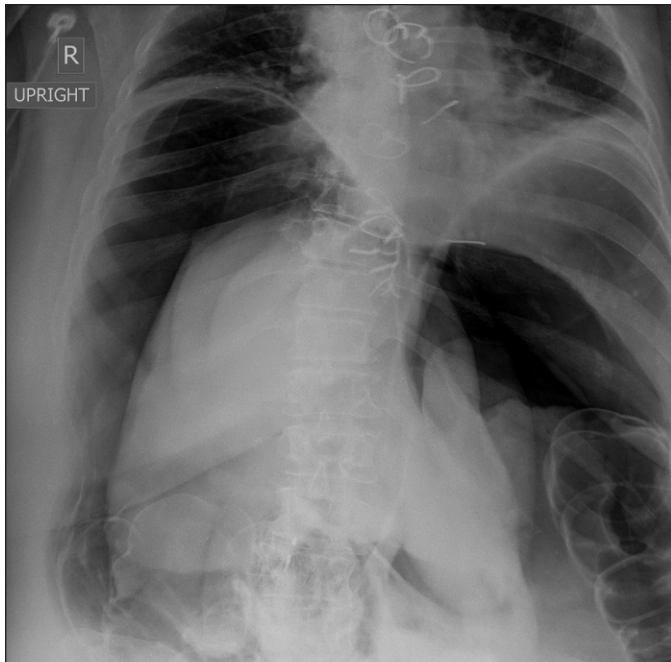


Figure 1. Abdominal x-ray demonstrating the pneumoperitoneum.

colon, but the anastomosis was not reached despite left lower quadrant pressure; there was no change in patient position. Room air was used for insufflation. Quiescent colitis was noted throughout and random surveillance biopsies were performed. The procedure duration was 20 minutes.

Immediately post-procedure, the patient experienced severe abdominal pain and distension. Abdominal x-ray showed pneumoperitoneum and emergent laparotomy was performed (Figure 1). A pinhole perforation was identified at the “crotch” of the stapled ileocolonic anastomosis

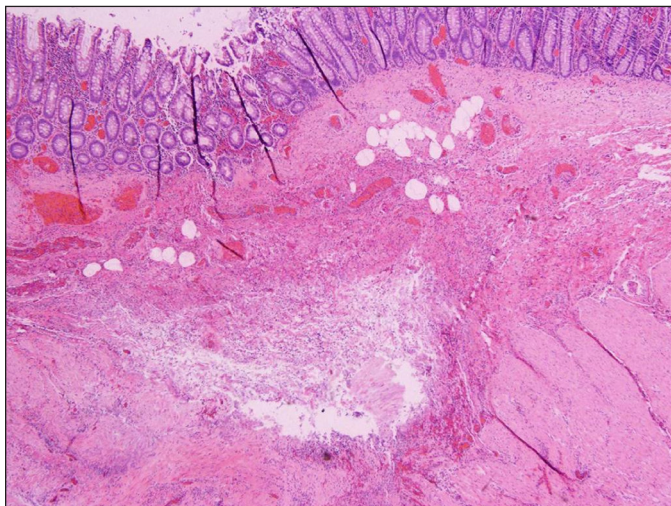


Figure 2. An established defect centered in the lamina propria and extending into the muscularis propria. There is associated mixed inflammation and early organization around its periphery.

with a large amount of pneumoperitoneum. There was no feculent material within the abdomen, and the ileum and colon appeared normal. The ileocolonic anastomosis was resected and a sewn side-to-end terminal ileum to mid-transverse colon anastomosis performed. Pathological evaluation of the resected ileocolonic anastomosis showed a focus of submucosal myxoid degeneration with organizing fibrosis and rare multinucleated giant cells in the colon; the overlying colonic mucosa was normal (Figures 2 and 3). No granulomas or infectious organisms were identified. The postoperative course was complicated by atelectasis and obesity hypoventilation syndrome. She was gradually weaned from supplemental oxygen and discharged on 6 days later.

Discussion

Colonic perforations during colonoscopy can be managed endoscopically, surgically, or medically.⁷ Nonsurgical management may be possible in afebrile, hemodynamically stable patients without severe abdominal pain. Nonsurgical management includes bowel rest, intravenous fluids and antibiotics, and serial evaluation. Surgical management is necessary for patients presenting with peritonitis, large perforations, or after failed nonsurgical management.⁸ Surgical approaches include primary suturing of perforation, but most favor colonic resection with either primary anastomosis or ostomy creation.² Recent reports have proven the safety and efficacy of laparoscopic approaches to colonoscopic perforation.⁹⁻¹¹ Endoscopic clip closure of an immediately recognized perforation may prevent the need for surgical repair¹²; however, clinical deterioration after clip repair and medical management necessitates immediately referral for surgery.¹³

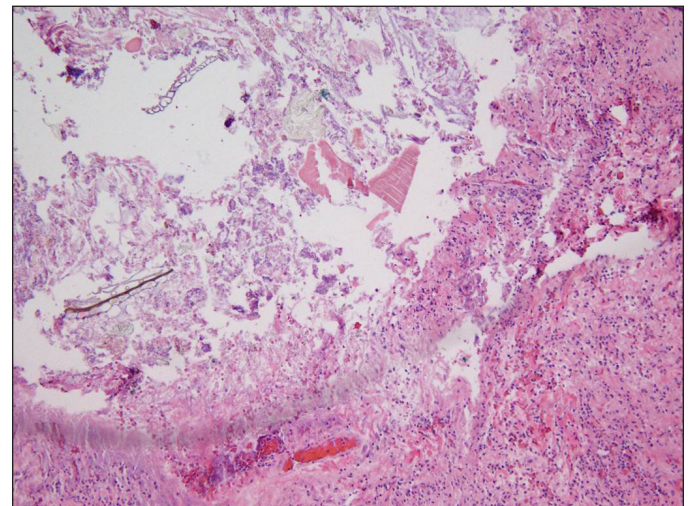


Figure 3. Cavity and the cavity wall showing hemorrhage, chronic-active inflammation, and an ingrowth of capillaries and fibroblasts. The lumen is filled with inflammatory debris and fecal contents.

To our knowledge, this is the first case report of a perforation of a well-established anastomosis proximal to the point of endoscope intubation during colonoscopy. The cause of this perforation was likely barotrauma. Barotrauma causes linear mucosal tears that may lead to full thickness tears and perforation.⁸ Insufflation to pressures above 140 mm Hg are likely to cause perforation.¹⁴ During insufflation, the diameter of the right colon, which is thin walled and at the highest risk for barotrauma, increases at a greater rate than the left colon.¹⁵ While colonoscopic insufflation with CO₂ causes less abdominal pain and distension, there is no reduced risk for adverse events, including perforation.¹⁶ The etiology of the defect in the resected specimen in this case was likely due to subclinical chronic submucosal inflammation. Air insufflation during colonoscopy led to opening of the defect and subsequent perforation. Technical difficulty and prolonged procedure duration likely increased the risk for barotrauma.

Disclosures

Author contributions: All authors participated in writing the case report. B. Phillips and D. Kastenber edited the manuscript. D. Kastenber is the article guarantor.

Financial disclosure: D. Kastenber has received research support from Ferring and is a consultant for Salix.

Informed consent was obtained for this case report.

Received: January 15, 2015; Accepted: April 30, 2015

References

1. Fisher DA, Maple JT, Ben-Menachem T, et al; ASGE Standards of Practice Committee. Complications of colonoscopy. *Gastrointest Endosc*. 2011;74(4):745–752.
2. Lohsiriwat V. Colonoscopic perforation: Incidence, risk factors, management and outcome. *World J Gastroenterol*. 2010;16(4):425–430.
3. Farley D, Bannon M, Zietlow S, et al. Management of colonoscopic perforations. *Mayo Clin Proc*. 1997;72(8):729–733.
4. Levin T, Zhao W, Connell C, et al. Complications of colonoscopy in an integrated health care delivery system. *Ann Intern Med*. 2006;145(12):880–886.
5. Rabeneck L, Paszat LF, Hilsden RJ, et al. Bleeding and perforation after outpatient colonoscopy and their risk factors in usual practice. *Gastroenterology*. 2008;135(6):1899–1906.
6. Reategui C, Testa A, Mentz R, et al. Safety of lower endoscopy in the early postoperative period after colorectal resection and anastomosis. Paper presented at: Society of American Gastrointestinal and Endoscopic Surgeons; March 30–April 2, 2011; San Antonio, Texas.
7. Kavic S, Basson M. Management of complications of colonoscopy. In: *Holzheimer RG, Mannick JA, eds. Surgical Treatment: Evidence-Based and Problem-Oriented*. Munich, Zuckschwerdt; 2001:209–210.
8. Lin I, Wang J, King T. Incidence and management of iatrogenic colonoscopic perforations. *J Soc Colon Rectal Surgeon*. 2010;21:53–58.
9. Makarawo TP, Damadi A, Mittal VK, et al. Colonoscopic perforation management by laparoendoscopy: An algorithm. *JSLs*. 2014;18(1):20–7.
10. Hansen AJ, Tessier DJ, Anderson ML, Schlinkert RT. Laparoscopic repair of colonoscopic perforations: Indications and guidelines. *J Gastrointest Surg*. 2007;11(5):655–9.
11. Alfonso-Ballester R, Lo Pez-Mozos F, Mart-Obiol R, Garcia-Botello SA, Lledo-Matoses S. Laparoscopic treatment of endoscopic sigmoid colon perforation: A case report and literature review. *Surg Laparosc Endosc Percutan Tech*. 2006;16(1):44–6.
12. Yang D, Byeon JS, Lee KH, et al. Is endoscopic closure with clips effective for both diagnostic and therapeutic colonoscopy-associated bowel perforation. *Surg Endosc*. 2010;24(5):1177–85.
13. Byeon J. Colonic perforation: Can we manage it endoscopically? *Clin Endosc*. 2013;46(5):495–499.
14. Woltjen J. A retrospective analysis of cecal barotrauma caused by colonoscope air flow and pressure. *Gastrointest Endosc*. 2005;61(1):37–45.
15. Kozarek R, Earnest D, Silverstein M, et al. Air-pressure-induced colon injury during diagnostic colonoscopy. *Gastroenterology*. 1980;78(1):7–14.
16. Maple JT, Banerjee S, Barth BA, et al; ASGE Technology Assessment Committee. Methods of luminal distention for colonoscopy. *Gastrointest Endosc*. 2013;77(4):519–525.

Publish your work in ACG Case Reports Journal

ACG Case Reports Journal is a peer-reviewed, open-access publication that provides GI fellows, private practice clinicians, and other members of the health care team an opportunity to share interesting case reports with their peers and with leaders in the field. Visit <http://acgcasereports.gi.org> for submission guidelines. Submit your manuscript online at <http://mc.manuscriptcentral.com/acgcr>.