



Corneal Nerves Alteration Associated with Corneal Complications after Pars Plana Vitrectomy

Tiezhu Lin¹, Hong Ye^{1,2}, Emmanuel Eric Pazo¹, Guangzheng Dai¹, Yang Xia¹, Wei He¹

¹Department of Vitreous and Retina, He Eye Specialist Hospital, Shenyang, China

²Department of Vitreous and Retina, Bright Eye Hospital, Hefei, China

Purpose: To evaluate the effect of corneal nerves assessment on predicting corneal complications following pars plana vitrectomy (PPV).

Methods: In this prospective single-center cohort study, 94 patients (94 eyes) received PPV, and were divided into postoperative groups with and without corneal complications. All eyes had corneal nerve fiber length (CNFL), corneal nerve fiber density, and branch density of corneal nerve fibers assessed and calculated with Image J preoperatively. Multivariate logistic regression analysis was used to identify corneal nerve fiber parameters that correlated to post-operative corneal complications. Receiver operator characteristic curve analysis was performed to identify the optimal cut-off point of the corneal fibers' parameters for predicting corneal complications after PPV.

Results: Eleven eyes (11.70%) developed corneal complications at 1 week after PPV. There was significant difference between CNFL (19.44 ± 6.88 vs. 26.84 ± 7.53 , $p = 0.003$), corneal nerve fiber density (28.82 ± 9.91 vs. 37.10 ± 10.16 , $p = 0.013$) and branch density of corneal nerve fibers (55.84 ± 21.08 vs. 82.04 ± 31.89 , $p = 0.01$) in two groups, respectively. Receiver operator characteristic analysis showed that the optimal cutoff value of CNFL to predict corneal complications following PPV was <26.495 mm/mm².

Conclusions: The decrease of CNFL may predict corneal complications following PPV. Regular preoperative corneal confocal microscopy test in PPV patients could be considered.

Key Words: Microscope, Nerve fibers, Postoperative complications, Vitrectomy

Corneal complications such as corneal epithelial defects, corneal edema, or superficial punctate keratopathy are common after pars plana vitrectomy (PPV), which may ad-

vance to ocular discomfort, poor vision, infection, scarring of the cornea, and corneal melting [1,2]. Though previous studies found that risk factors for poor corneal status after PPV are diabetes mellitus (DM), longer operative time, rhegmatogenous retinal detachment, intravitreal tamponade with perfluoropropane, and assistance of a first-year resident were risk factors for poor corneal status after PPV [1,3], the biomarkers have not been found. Corneal confocal microscopy (CCM) assessment is a rapid and reproducible technique that quantifies corneal nerve morphology, and

Received: March 31, 2021 Final revision: May 5, 2021
Accepted: May 17, 2021

Corresponding Author: Tiezhu Lin, MD. Department of Retinal and Vitreous Disease, He Eye Specialist Hospital, No. 128 Huanghe Street, Yuhong District, Shenyang, Liaoning Province 110000, China. Tel: 86-136-5403-2699, Fax: 86-024-2397-4661, E-mail: lintiezhu@hsyk.com.cn

© 2021 The Korean Ophthalmological Society

This is an Open Access article distributed under the terms of the Creative Commons Attribution Non-Commercial License (<http://creativecommons.org/licenses/by-nc/3.0/>) which permits unrestricted non-commercial use, distribution, and reproduction in any medium, provided the original work is properly cited.

the intra class correlation coefficient values were 0.94, 0.95, and 0.96 for corneal nerve fiber density (CNFD), branch density of corneal nerve fibers (CNBD), and corneal nerve fiber length (CNFL) [4]. Therefore, it might be possible to use these parameters from CCM to predict corneal complications such as epithelial defects after PPV.

In this study, we investigated the corneal nerves alteration associated with corneal complications after PPV. Our aim was to identify which parameter of corneal nerve plexus correlated with corneal complications after PPV. Additionally, receiver operating characteristic (ROC) curve was plotted and optimal cut-off values for predicting corneal complications following PPV was explored.

Materials and Methods

Participants

This study was performed under the approval from the institutional review board of He Eye Specialist Hospital (IRB(2020)K004.01) and conformed to the tenets of Declaration of Helsinki. All participants were informed of their rights and provided written informed consent before undergoing study procedures. Consecutive patients who underwent PPV in He Eye Specialist Hospital from April 1, 2020 to June 30, 2020 were enrolled in the study, including proliferative diabetic retinopathy (PDR), rhegmatogenous retinal detachment and vitreous hemorrhage form retinal vein occlusion and so on. Participants were excluded from the analysis if they had corneal surgery, corneal dystrophy, or cystic corneal disorders. Participants in this study were divided into two groups (group 1: with corneal complications after PPV and group 2: non corneal complications after PPV), these groups were named as follows: group 1 = G1 and group 2 = G2.

The primary outcome measures in this study was corneal complications. Defined as corneal complications after PPV reported by Hiraoka et al. [5] and Chen et al. [1], as “the presence of corneal epithelial defects, corneal edema, or superficial punctate keratopathy lasting for at least 7 days after PPV”. The definition of persistent corneal epithelial defects (PCED) as suggested by Tsubota et al. [6], is a corneal epithelial defect persisting for more than 2 weeks without improvement despite conventional treatment such as artificial tear drops or extended soft contact lens use.

CCM

All participants enrolled for this study were preoperatively assessed using a slit lamp biomicroscope, indirect ophthalmoscope and tonometer. Additionally, all participants underwent CCM assessment using a Heidelberg Retina Tomography III (Heidelberg Engineering, Heidelberg, Germany), which uses an additional lens (Rostock Cornea Module) for corneal observation. CCM was performed by an expert examiner (WH) who obtained images from the central cornea at the level of sub-basal nerve plexus (SNP). The assessor anaesthetized the eye prior to CCM assessment using one drop of 0.4% benoxinate hydrochloride (Santen Pharmaceutical, Osaka, Japan). To improve the adhesion between the cornea and applanation cap, Viscotears (Carbomer 980, 0.2%; Novartis, North Ryde, UK) was used. Patients were asked to place their forehead against the headrest and fixate onto a light target in order for achieve centration. The objective lens of the microscope was gradually moved forward till gel came in contact with the cornea. The confocal scanning laser method allows a detailed visualization of the cornea and its layers separately within a 400- μm \times 400- μm viewing area. Five to eight images generated by Heidelberg Retina Tomography III provides an acceptable level of accuracy to quantify SNP morphology [7]. We chose and analyzed five images with high-clarity from the central SNP. Criteria for image selection were contrast, depth, and focus position.

Analysis of corneal images

Five high-clarity images (without motion artifact) of SNP were assessed for further quantitative evaluation. The assessment of SNP was based on the calculation of three parameters, which could be used to denote as a potential morphological state of nerve fiber [8,9]. These parameters included (1) CNFD: total number of nerve fibers observed within a frame (nerve fibers/ mm^2), (2) CNBD: total number of nerve branches originating from major nerve trunks, per mm^2 of corneal tissue (nerve branches/ mm^2), and (3) CNFL: total length of nerve fibers and branches within a frame (mm/mm^2) [8]. Analysis of the CCM images of SNP was carried out by Neuron J of Image J (National Institutes of Health, Bethesda, MD, USA). The average of measurements was used for further comparative analysis. All photographs were graded by two independent ophthalmol-

ogists (HY and GQ) in a masked fashion.

Surgical techniques

All patients underwent an extensive 3-port PPV using 23-gauge instrumentation (OS4; Oertli, Berneck, Switzerland) and Resight 500 (Carl Zeiss Meditec, Dublin, CA, USA) for visualization under retrobulbar anesthesia. According to each subject's particular needs and requirements, fibrovascular membrane dissection were performed. Endolaser PRP was performed during the operation until all 4 quadrants had laser burns 1 burn length apart at least to the end of the midperipheral retina in PDR eyes. Vitreous replacement with air, long acting expansile gas mixtures (C2F6), fluid or 1000 centistoke silicone oil and sub-tenon's dexamethasone administration at the end of the surgery were left to the judgement of the surgeon. In case of a combined procedure, phacoemulsification was systematically performed before the PPV, through a 2.8-mm clear corneal incision, with implantation of an acrylic foldable intraocular lens. Start time of the operation was recorded at the time of retrobulbar anesthesia, and the operation finish time was recorded following eyelid speculum removal at the end of the PPV. Postoperatively, patients were instructed to instill topical 1% prednisolone acetate, four times daily for 28 days, and topical 0.5% levofloxacin, four times daily for 7 days. Brinzolamide and timolol maleate

eye drops would be topically given twice a day if intraocular pressure was ≥ 30 mmHg. Postoperative data collection was performed at five visits: day 1, day 7, day 14, day 28, and 3rd month.

Statistical analysis

Normality was assessed using histograms and Shapiro-Wilk test. Categorical variables were analyzed using chi-square test. Student *t*-test was used for comparison of groups with normally distributed variables, while Wilcoxon rank-sum test for continuous non-normally distributed variables. All eyes were analyzed together in a multivariate logistic regression model to identify baseline factors that are predictive of corneal complications after PPV. ROC curve analysis was performed to identify the optimal cut-off point of the corneal fibers' parameters (at which sensitivity and specificity would be at a maximum) for the prediction of corneal complications after PPV. All statistical analyses were performed with IBM SPSS Statistics ver. 25.0 (IBM Corp., Armonk, NY, USA), alpha level (type I error) was set at 0.05.

The inter-rater agreement for assessment of corneal fibers' parameters (CNFD, CNBD, and CNFL) was checked using intraclass coefficient (ICC). The agreement between reviewers was high: ICC = 0.986 for CNFD evaluation, ICC = 0.963 for CNBD, and ICC = 0.983 for CNFL assessment (all $p < 0.001$).

Table 1. Comparison of baseline characteristic among two groups

	Group 1 (n = 11)	Group 2 (n = 83)	<i>p</i> -value
Age (yr)	55.00 ± 9.66	56.72 ± 11.81	0.645
DM (yes : no)	10 : 1	48 : 35	0.034
Sex (male : female)	5 : 6	44 : 39	0.642
ECC (no/mm ²)	2,645.63 ± 296.60	2,628.80 ± 354.14	0.881
Operative time (min)	70.45 ± 35.88	57.41 ± 19.53	0.067
Surgery procedure (phacovitrectomy : single PPV)	10 : 1	60 : 23	0.187
Tamponade (silicone oil : gas)	3 : 8	19 : 64	0.750
Corneal fibers (mm/mm ²)			
CNFL	19.44 ± 6.88	26.84 ± 7.53	0.003
CNFD	28.82 ± 9.91	37.10 ± 10.16	0.013
CNBD	55.84 ± 21.08	82.04 ± 31.89	0.010

Values are presented as mean ± standard deviation or number.

DM = diabetes mellitus; ECC = endothelial cell count; PPV = pars plana vitrectomy; CNFL = corneal nerve fiber length; CNFD = corneal nerve fiber density; CNBD = branch density of corneal nerve fibers.

Table 2. Corneal complications at 1 week after pars plana vitrectomy

	Diabetic patients (n = 58)	Non-diabetic patients (n = 36)	p-value
Group 1 (n = 11)	10 (17.24)	1 (2.78)	0.047
Group 2 (n = 83)	48 (82.76)	35 (97.22)	

Values are presented as number (%).

Table 3. Multivariate logistic regression analysis of the associated risk factors with corneal complications following pars plana vitrectomy

	p-value	Odds ratio	95% CI
Operative time	0.140	-	-
Diabetes mellitus	0.431	-	-
Surgery procedure	0.154	-	-
CNFL	0.005	0.858	0.770–0.956
CNFD	0.997	-	-
CNBD	0.934	-	-

CI = confidence interval; CNFL = corneal nerve fiber length; CNFD = corneal nerve fiber density; CNBD = branch density of corneal nerve fibers.

Results

Ninety-four eyes of 94 patients were enrolled in this study, with 11 eyes with corneal complications after PPV in G1, and 83 eyes without corneal complications in G2. The mean age was 56.52 ± 11.55 years old, with a slight male predominance (52.12%). The baseline characteristics of patients in both groups are presented in Table 1.

There was statistically significant difference between CNFL (19.44 ± 6.88 vs. 26.84 ± 7.53, *p* = 0.003), CNFD (28.82 ± 9.91 vs. 37.10 ± 10.16, *p* = 0.013), and CNBD (55.84 ± 21.08 vs. 82.04 ± 31.89, *p* = 0.01) in two groups, respectively (Table 1).

Eleven eyes (11.70%) developed corneal complications at 1 week after PPV in all patients. Ten eyes (10.6%) with corneal complications were diabetic patients (Table 2), and eight (8.51%) of them developed PCED on 2 weeks after PPV. PCED had been lasting for at least 3 months in four eyes (4.26%), two eyes of them failed medicine therapy and progressed corneal ulcer, which eventually got amni-

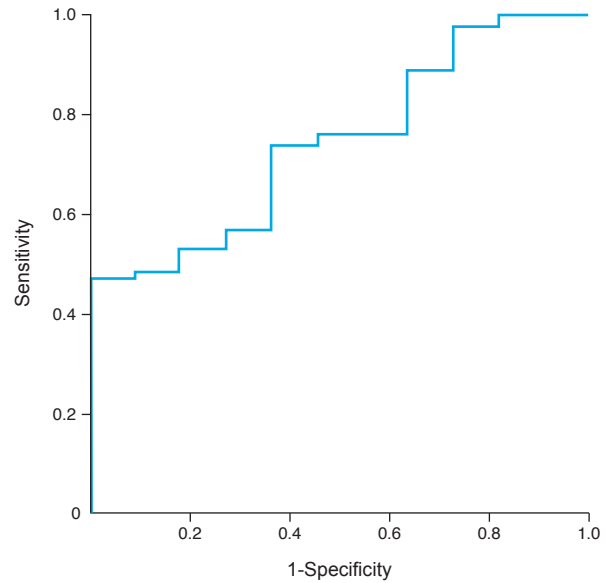


Fig. 1. Receiver operating characteristic curve analysis, the optimal cutoff value of corneal nerve fiber length in the prediction of corneal complications following pars plana vitrectomy. An area under the curve value is 0.743, with 47% sensitivity and 100% specificity.

otic membrane transplantation and healed.

The variables of operative time, DM, three SNP parameters and operative procedure were enrolled in the multivariate logistic regression analysis. The result showed that CNFL was the only significant risk factor for corneal complications after PPV. Every micrometer decrease of CNFL increased the likelihood of achieving corneal complications after PPV by 17% (odds ratio, 0.858; 95% confidence interval, 0.770–0.956; *p* = 0.005) (Table 3).

According to the ROC curve analysis, the optimal cutoff value of CNFL in the prediction of corneal complications following PPV was detected. The optimal cutoff value of CNFL to predict corneal complications following PPV was <26.495 mm/mm², with an area under the curve value of 0.743, 95% confidence interval 0.610–0.875, sensitivity 47%, and specificity 100% (Fig. 1).

Discussion

PPV allows the treatment for various vitreoretinal disorders involving the vitreous, retina and choroid, which may offer the opportunity for visual recovery. Corneal complications following PPV are comparatively common, with an

incidence rate reaching up to 23.1% [1,3,10]. In our study, the prevalence of corneal complications after PPV is 11.7%, lower compared to previous studies. The technique of PPV is progressing very fast recently, including the updating of assisting lens used in the operation. Chiang et al. [3] reported that the lens they used was contact lens with lens ring fixed by scleral suture. Chen et al. [1] reported a hand-held contact lens used with an assistant needed in their study and found a first-year resident assisting the operation was the risk factor for PCED. However, we used Resight 500 noncontact viewing system in this study, which does not need an assistant holding the lens or lens suture fixation, no eyes with corneal epithelium debridement, that could reduce the mechanical scratching to the cornea, this may be the reason to explain the low rate of corneal complication following PPV in our study, our result is also close to the rate (15.9%) of corneal complications Al-Hinai et al. [10] reported, noncontact viewing system was used in his study too. Additional, Chiang et al. [3] reported that operative time was a risk factor for corneal epithelial defect, the operative time in his study was nearly two hours, but the mean operative time was just 58.94 ± 22.19 minutes in our study. Though there is no significant difference between operative time in G1 and G2, G1 has the tendency of more time used compared to G2 (70.45 ± 35.88 vs. 57.41 ± 19.53 minutes, $p = 0.067$), so less operative time used might be another reason to support our result. The rate of PCED is 8.51% in our study, slightly higher compared to previous studies, Chen et al. [1] reported that the rate of PCED was 4.6% in their study, they also found DM was a risk factor for PCED. PDR patients were predominant (61.7%) in our study, and all the PCED patients were with PDR, that could explain that.

The cornea is densely innervated with nerves, containing A- δ and unmyelinated C fibers derived from the ophthalmic division of the trigeminal nerve [11,12]. In addition to their sensory and reflex functions, corneal nerves also have significant trophic effects on the cornea and play an important role in the preservation of ocular surface health through the stimulation of corneal wound healing after corneal injuries [13]. Several studies have been conducted to investigate the exact mechanism by which the corneal nerve fibers maintain a healthy cornea and promote wound healing after corneal injuries. The results of these studies suggest that there is a trophic relationship between corneal nerves and epithelial cells. Corneal nerves can stimulate

epithelial cell growth, proliferation, differentiation and type IV collagen formation through the release of neurotrophins and neuropeptides [14]. In our study, CNFL, CNFD and CNBD is significant decreased in the G1 compared to G2, respectively. Decreased corner nerve fibers might influence the corneal wound healing.

Diabetic keratopathy is characterized by abnormal innervation of the cornea that results in decreased sensitivity and impaired epithelial wound healing [15]. SNP is frequently affected in diabetic patients with neuropathy and the changes depend on the severity of neuropathy. It has been found that the number of fibers, number of beadings, and branching pattern of fibers in the sub-basal plexus decreases in cases of mild to severe neuropathy [9,16,17]. These are primarily caused by changes within the arrangement of the corneal epithelial basement membrane, deposition of glycation products, corneal nerve endings damage and reduction in tear secretion, that leads to oxidative stress during the hyperglycemic condition [18]. Several studies had testified DM was a risk factor for corneal complications after PPV [1,3], though more diabetic patients had corneal complications after PPV in this study, DM was not noted as the risk factor in the multivariate logistic regression analysis. CNFL was the only significant risk factor for corneal complications after PPV.

The corneal complications after PPV would rarely happen if $CNFL \geq 26.495$ mm/mm² according to the ROC analysis result, the occurrence of corneal complications after PPV might be about 50% if $CNFL < 26.495$ mm/mm². These results could help the retinal surgeons to evaluate the risk factors of corneal complications following PPV before the operation. Interestingly, Scarr et al. [19] also suggested CNFL be classified as abnormal for the NPDR and PDR groups adhering to the cutoff values.

The limitations of this study are the relatively small study population and single center study. However, to the best of our knowledge, this is the first study to use preoperative corneal nerve parameters to predict the corneal complications following PPV. This study is also void of any bias from pharmaceutical sponsorship; hence, the data are generalizable to the typical retina practice patient.

In conclusion, preoperative corneal nerve parameters (CNFL, CNFD, and CNBD) decreases in PPV patients with postoperative corneal complications, the rate of corneal complications following PPV may decrease with the noncontact viewing system, the decrease of CNFL may

predict corneal complications following PPV. Regular pre-operative CCM test in PPV patients could be considered.

Conflict of Interest

No potential conflict of interest relevant to this article was reported.

References

1. Chen HF, Yeung L, Yang KJ, Sun CC. Persistent corneal epithelial defect after pars plana vitrectomy. *Retina* 2016;36:148-55.
2. Chen WL, Lin CT, Ko PS, et al. In vivo confocal microscopic findings of corneal wound healing after corneal epithelial debridement in diabetic vitrectomy. *Ophthalmology* 2009;116:1038-47.
3. Chiang WY, Lee JJ, Kuo HK, et al. Factors associated with corneal epithelial defects after pars plana vitrectomy. *Int Ophthalmol* 2018;38:105-110.
4. Kalteniece A, Ferdousi M, Adam S, et al. Corneal confocal microscopy is a rapid reproducible ophthalmic technique for quantifying corneal nerve abnormalities. *PLoS One* 2017;12:e0183040.
5. Hiraoka M, Amano S, Oshika T, et al. Factors contributing to corneal complications after vitrectomy in diabetic patients. *Jpn J Ophthalmol* 2001;45:492-5.
6. Tsubota K, Goto E, Shimmura S, Shimazaki J. Treatment of persistent corneal epithelial defect by autologous serum application. *Ophthalmology* 1999;106:1984-9.
7. Vagenas D, Pritchard N, Edwards K, et al. Optimal image sample size for corneal nerve morphometry. *Optom Vis Sci* 2012;89:812-7.
8. Kallinikos P, Berhanu M, O'Donnell C, et al. Corneal nerve tortuosity in diabetic patients with neuropathy. *Invest Ophthalmol Vis Sci* 2004;45:418-22.
9. Malik RA, Kallinikos P, Abbott CA, et al. Corneal confocal microscopy: a non-invasive surrogate of nerve fibre damage and repair in diabetic patients. *Diabetologia* 2003;46:683-8.
10. Al-Hinai AS. Corneal epithelial defect after pars plana vitrectomy. *Oman J Ophthalmol* 2017;10:162-6.
11. Al-Aqaba MA, Alomar T, Miri A, et al. Ex vivo confocal microscopy of human corneal nerves. *Br J Ophthalmol* 2010;94:1251-7.
12. Nielsen NV, Lund FS. Diabetic polyneuropathy: corneal sensitivity, vibratory perception and Achilles tendon reflex in diabetics. *Acta Neurol Scand* 1979;59:15-22.
13. Al-Aqaba MA, Dhillon VK, Mohammed I, et al. Corneal nerves in health and disease. *Prog Retin Eye Res* 2019;73:100762.
14. Baker KS, Anderson SC, Romanowski EG, et al. Trigeminal ganglion neurons affect corneal epithelial phenotype: influence on type VII collagen expression in vitro. *Invest Ophthalmol Vis Sci* 1993;34:137-44.
15. Bikbova G, Oshitari T, Baba T, et al. Diabetic corneal neuropathy: clinical perspectives. *Clin Ophthalmol* 2018;12:981-7.
16. Hossain P, Sachdev A, Malik RA. Early detection of diabetic peripheral neuropathy with corneal confocal microscopy. *Lancet* 2005;366:1340-3.
17. Midena E, Brugin E, Ghirlando A, et al. Corneal diabetic neuropathy: a confocal microscopy study. *J Refract Surg* 2006;22(9 Suppl):S1047-52.
18. Priyadarsini S, Welchel A, Nicholas S, et al. Diabetic keratopathy: insights and challenges. *Surv Ophthalmol* 2020;65:513-29.
19. Scarr D, Lovblom LE, Ostrovski I, et al. Agreement between automated and manual quantification of corneal nerve fiber length: implications for diabetic neuropathy research. *J Diabetes Complications* 2017;31:1066-73.