

 **Case Report** 

Fatal Vasospasm of the Coronary Arteries in a Patient Undergoing Distal Bypass Surgery and Endovascular Therapy for Threatened Lower Limbs Due to Acute Exacerbation of Peripheral Arterial Disease

Daisuke Takeyoshi, MD,¹ Shinsuke Kikuchi, MD, PhD,² Keisuke Miyake, MD,² Takamitsu Tatsukawa, MD,¹ Daita Kobayashi, MD,¹ Daiki Uchida, MD,² Yuya Kitani, MD,³ Hiroyuki Kamiya, MD, PhD,¹ and Nobuyoshi Azuma, MD, PhD²

A 79-year-old man with a heavy smoking history presented with threatened lower limbs due to acute exacerbation of peripheral artery disease (PAD). He underwent emergent distal bypass surgery for the right leg and external iliac stenting for the left leg. Fatal coronary artery spasm (CAS) with ST segment changes on electrocardiography was observed 28h after the procedures, resulting in cardiac arrest. Coronary angiography showed widespread CAS with improvement after intra-arterial nitroglycerin infusion. We should keep in mind that CAS may occur more frequently than expected in PAD patients, especially those who have not stopped smoking prior to revascularization.

Keywords: peripheral artery disease, coronary artery spasm, smoking


¹Department of Cardiac Surgery, Asahikawa Medical University, Asahikawa, Hokkaido, Japan

²Department of Vascular Surgery, Asahikawa Medical University, Asahikawa, Hokkaido, Japan

³Department of Cardiology, Asahikawa Medical University, Asahikawa, Hokkaido, Japan

Received: May 17, 2018; Accepted: July 2, 2018

Corresponding author: Nobuyoshi Azuma, MD, PhD. Department of Vascular Surgery, Asahikawa Medical University, 2-1 Midorigaoka-higashi, Asahikawa, Hokkaido 078-8510, Japan
Tel: +81-166-68-2494, Fax: +81-166-68-2499
E-mail: nazuma@asahikawa-med.ac.jp

 ©2018 The Editorial Committee of Annals of Vascular Diseases. This article is distributed under the terms of the Creative Commons Attribution License, which permits use, distribution, and reproduction in any medium, provided the credit of the original work, a link to the license, and indication of any change are properly given, and the original work is not used for commercial purposes. Remixed or transformed contributions must be distributed under the same license as the original.

Introduction

Coronary artery spasm (CAS) is a well-known perioperative complication in patients undergoing cardiac, thoracic, and abdominal surgery.¹ In non-cardiac surgery, its incidence is very low (0.05%).² There have been only a few studies on CAS in patients with peripheral artery disease (PAD) that have shown that a higher incidence of CAS may be expected in patients with PAD secondary to endothelial dysfunction due to multiple vascular risk factors and oxidation stress and metabolic remnants from ischemic limbs.^{3,4} The frequency of CAS appears to be greater in the Japanese population than in the Western population. It is a very important consideration in the treatment of PAD.⁵ In addition to that, the high prevalence of coronary artery disease (CAD) in PAD is well known, and this combination is at increased risk for cardiovascular mortality and cardiovascular event.⁶ Here, we report a case of fatal diffuse vasospasm of the coronary arteries in a patient undergoing revascularization of both lower limbs compromised by acute exacerbation of PAD.

Case Report

A 79-year-old man was referred to our hospital because both of his lower limbs were affected by abnormalities of sensation and motility due to acute exacerbation of PAD. One week had passed since his leg pain and the symptom gradually worsened. He had a long history of smoking (>20 cigarettes per day for 50 years), hypertension, and hyperlipidemia, but he had no history of CAD. Cyanosis was seen in both feet, and ulcers had developed in the bilateral side of the malleolus of the right foot (Fig. 1). The ankle-brachial index showed no wave (unmeasurable) in either leg, and his skin perfusion pressure was

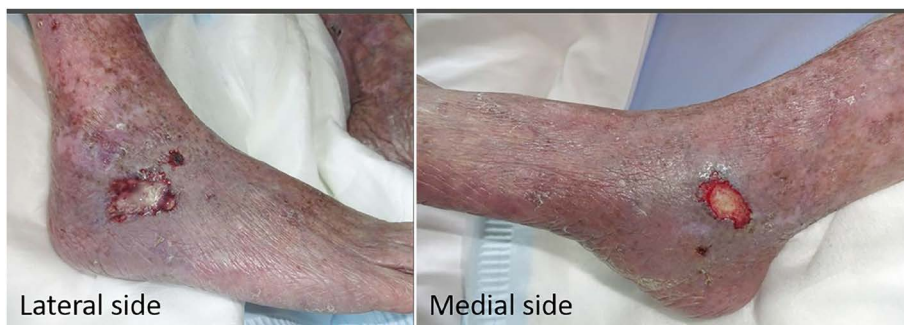

Fig. 1 A photograph of the threatened right lower limb.

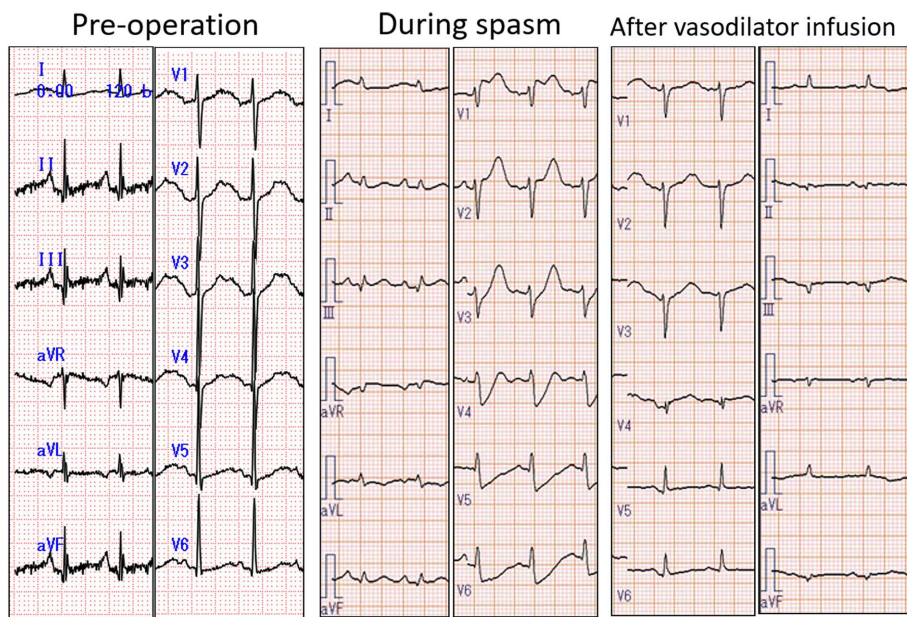


Fig. 2 Electrocardiography before operation, during spasm, and after vasodilator infusion.

<20 mmHg in the dorsa and the plantar surfaces of both feet. Additionally, his preoperative creatinine kinase was elevated (3,036 IU/L), and metabolic acidosis that come from the ischemic extremity was also found (pH 7.178, base excess -12.5 mmol/L, HCO_3^- 15.0 mmol/L, and lactate 10 mg/dL from arterial blood gases). Preoperative electrocardiography (ECG) showed a normal finding (Fig. 2, left panel). Transthoracic echocardiogram also showed a normal ejection fraction (60%) and no heart wall asynergy. Preoperative computed tomography angiography revealed common femoral artery (CFA) stenosis with calcification and chronic total occlusion (CTO) from the superficial femoral artery (SFA) to the distal popliteal artery of the right leg (Fig. 3, left panel) and significant stenosis of the external iliac artery and CTO of the SFA in the left leg. Emergency revascularization, right CFA endarterectomy, CFA-peroneal bypass using an autogenous vein for infrainguinal arterial lesions, and left external iliac artery stenting for the left inflow arterial lesion were performed

under general anesthesia (Fig. 3, right panel). Although the intraoperative course was uneventful, the procedure was performed for 8 h. The patient was postoperatively managed under sedation with intubation to provide intensive treatment against ischemia-reperfusion disorder. No vasodilator was administered intraoperatively and postoperatively. ST segment depression was observed on ECG 28 h after the procedures (Fig. 2, middle panel). Volume loading without any vasodilator use was performed for the ST change, considering hypovolemia due to the bilateral revascularization, more especially for acute limb ischemia. Two hours later, he suffered sudden severe cardiac shock with significant ST elevation followed by cardiac arrest. Extracorporeal cardiopulmonary resuscitation and subsequent extracorporeal membrane oxygenation (ECMO) were performed. Emergency coronary angiography revealed severe diffuse CAS, which was treated with an intracoronary infusion of nitroglycerin. The coronary artery angiography showed collateral artery growth from

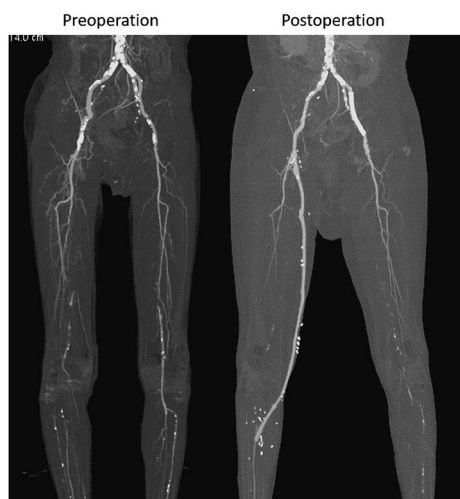


Fig. 3 Computed tomography angiography before and after revascularization. The latter was taken after the discontinuation of extracorporeal membrane oxygenation support, showing worse in the left lower leg perfusion.

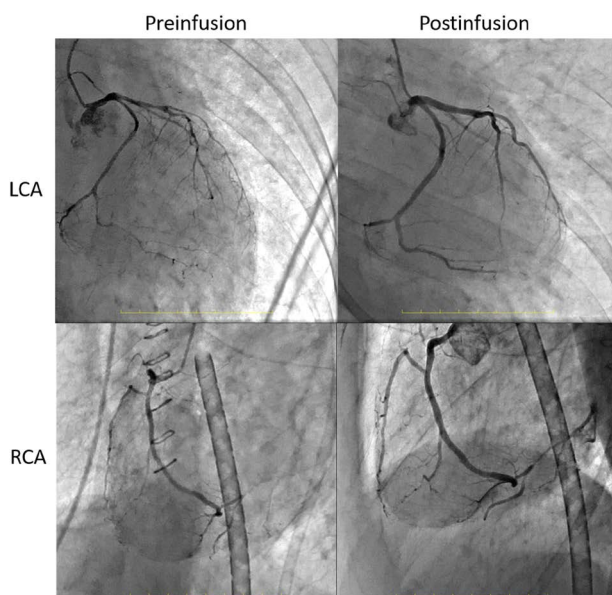


Fig. 4 Coronary artery angiography showing coronary artery spasm upon cardiac arrest with subsequent improvement after nitroglycerin infusion. Collateral arteries were found from the atrioventricular node branch to the posterolateral artery. LCA: left coronary artery; RCA: right coronary artery

the atrioventricular node branch to the posterolateral artery, indicating organic coronary artery lesions (Fig. 4). We treated the patient with ECMO support and infusions of diltiazem and nitroglycerin. The vasodilators improved the ST change on ECG (Fig. 2, right panel). His left ventricular ejection fraction gradually improved from 10% to 60% in a few days, and ECMO was smoothly weaned and discontinued on day 4 after CAS development. Un-

fortunately, he eventually died 2 months later because of respiratory failure by acute respiratory distress syndrome and pneumonia, which required a tracheal incision, hypoalbuminemia by chronic intestinal ischemia, and fungal sepsis. He provided informed consent for the publication of this report.

Discussion

We report a rare case of perioperative vasospasm of the coronary arteries following infrainguinal surgical revascularization of both lower limbs to treat acute exacerbation of PAD. A search for reports similar to the present case in PubMed with the terms “limb ischemia” or “PAD” and “spasm” was performed, but no case report published in English was found. Therefore, to the best of our knowledge, this is the first case report of CAS in a patient undergoing distal bypass surgery for threatened limbs due to PAD.

On the basis of a large study,⁷⁾ epicardial spasm was induced by intracoronary acetylcholine provocation in 33.4% of patients submitted to diagnostic angiography for suspected myocardial ischemia. Epicardial spasm was frequently diffuse, but fatal or irreversible complications rarely occurred (<10%). The clinical characteristics associated with epicardial spasm were male sex, age, cigarette smoking, a previous history of CAD, and a clinical presentation with acute coronary syndrome, suggesting that preoperative assessment of cardiac function is essential for patients with PAD, especially those with threatened limbs and a high risk for CAD. In the current case, we had no preoperative information on coronary artery risk beyond the transthoracic echocardiogram results because emergent revascularization was required. The coronary angiography after vasodilator infusion showed the organic coronary artery lesions, indicating an importance of association between high prevalence of CAD and CAS occurrence in PAD patients.

The effects of endothelial factors are also important in CAS. Vasomotor responses in human conduit arteries are influenced by both vasodilating and vasoconstricting products of the local endothelium, such as nitric oxide (NO). Endothelial production of vasoactive agents is regulated by the shear stress generated by local blood flow.⁸⁾ Endothelium-dependent vasodilation is generally impaired in patients with PAD.^{9,10)} On the basis of the details of the present case, a volume shift in hemodynamics due to revascularization of both lower limbs in addition to impaired endothelium function caused by long-term smoking may have reduced flow-mediated coronary dilation. As other possibilities, oxidative stress and metabolic remnants from the ischemic limbs and the limb perfusion may also cause CAS.⁴⁾

Perioperative administration of calcium-channel blockers and long-acting nitrates is effective for patients with a high risk of CAS.⁴⁾ When emergent surgical procedures for PAD are required, the possibility of cardiac injury, including CAS and CAD progression, should be anticipated before surgery and prevented with continuous infusions of vasodilators perioperatively.

Conclusion

We present a case of widespread coronary spasm after revascularization of both lower limbs to treat acute PAD exacerbation, which led to cardiac arrest. We should keep in mind that CAS may occur more frequently than expected in PAD patients, especially those who have not stopped smoking prior to revascularization.

Disclosure Statement

All authors have no conflict of interest.

Author Contributions

Surgical procedures: DT, SK, KM, TT, DU, DK, NA

Coronary artery angiography procedure: YK

Writing: DT, SK, HK, NA

Critical review and revision: all authors

Final approval of the article: all authors

Accountability for all aspects of the work: all authors

References

- 1) He GW, Taggart DP. Spasm in arterial grafts in coronary artery bypass grafting surgery. *Ann Thorac Surg* 2016; **101**: 1222-9.
- 2) Nagayoshi Y, Kawano H, Kojima S, et al. Significance of coronary vasospasm in the perioperative management of non-cardiac surgery. *Circ J* 2012; **76**: 1965-71.
- 3) Chen KY, Rha SW, Li YJ, et al. Peripheral arterial disease is associated with coronary artery spasm as assessed by an intracoronary acetylcholine provocation test. *Clin Exp Pharmacol Physiol* 2009; **36**: e78-82.
- 4) Yasue H, Nakagawa H, Itoh T, et al. Coronary artery spasm—clinical features, diagnosis, pathogenesis, and treatment. *J Cardiol* 2008; **51**: 2-17.
- 5) Isogai T, Yasunaga H, Matsui H, et al. Serious cardiac complications in coronary spasm provocation tests using acetylcholine or ergonovine: analysis of 21 512 patients from the diagnosis procedure combination database in Japan. *Clin Cardiol* 2015; **38**: 171-7.
- 6) Aronow WS. Peripheral arterial disease in the elderly. *Clin Interv Aging* 2007; **2**: 645-54.
- 7) Ong P, Athanasiadis A, Borgulya G, et al. Clinical usefulness, angiographic characteristics, and safety evaluation of intracoronary acetylcholine provocation testing among 921 consecutive white patients with unobstructed coronary arteries. *Circulation* 2014; **129**: 1723-30.
- 8) Klocke FJ. Epicardial coronary artery vasomotion. *J Am Coll Cardiol* 2010; **56**: 1666-7.
- 9) Motoyama T, Kawano H, Kugiyama K, et al. Flow-mediated, endothelium-dependent dilatation of the brachial arteries is impaired in patients with coronary spastic angina. *Am Heart J* 1997; **133**: 263-7.
- 10) Weiss T, Fischer D, Hausmann D, et al. Endothelial function in patients with peripheral vascular disease: influence of prostaglandin E1. *Prostaglandins Leukot Essent Fatty Acids* 2002; **67**: 277-81.