



Case report

Hybrid surgery of ventral intermediate nucleus thalamotomy using magnetic resonance-guided focus ultrasound and modulation by deep brain stimulation controls bilateral essential tremor

Akira Tempaku¹

¹Department of Neurosurgery, Hokuto Hospital, Japan

Abstract

Objective: Medication-resistant essential tremor requires surgical treatment. Deep brain stimulation to the thalamic ventral intermediate nucleus is an established procedure to diminish tremors. Tremor on both sides needs dual deep brain stimulation implantation. Nowadays, magnetic resonance-guided focus ultrasound is broadened to treat essential tremor. However, the safety of magnetic resonance-guided focus ultrasound against dual ventral intermediate is still under discussion, since bilateral thalamotomy causes speech disturbance or ataxia.

Patient and Methods: A 66-year-old right-handed man had medication-resistant essential tremor at bilateral upper extremities superior to the left arm. A treatment of magnetic resonance-guided focus ultrasound was performed by using the ExAblate transcranial system against the left ventral intermediate. One year after magnetic resonance-guided focus ultrasound treatment, the stereotactic implantation of a deep brain stimulation electrode into the right ventral intermediate was done.

Results: Clinical rating scale for tremor in the right arm was reduced from 12 to 0 points by magnetic resonance-guided focus ultrasound against the left ventral intermediate. The clinical rating scale for tremor in the left arm was reduced from 23 to 1 point by deep brain stimulation to the right ventral intermediate.

Conclusion: Hybrid surgery of magnetic resonance-guided focus ultrasound and deep brain stimulation refined bilateral essential tremor, without any neurological deficiencies. This combined surgery would be useful to manage medication-resistant bilateral essential tremor patients who are carrying some difficulties to introduce deep brain stimulation on the bilateral side.

Key words: magnetic resonance-guided focus ultrasound, deep brain stimulation, hybrid surgery, ventral intermediate nucleus

(J Rural Med 2022; 17(4): 265–269)

Introduction

Essential tremor (ET) is one of the major causes of tremor-based movement disorders. The disorder of ET is observed in 2.5 to 10% of the population, mainly in the elderly generation. Therapeutic strategy against medication-

resistant ET at bilateral extremities is still under discussion. Since ventral intermediate (Vim) nucleus thalamotomy is useful to control tremor^{1–4)}, bilateral thalamotomy includes a 20–30% risk of speech disturbance or ataxia⁵⁾. Neuro-modulation by deep brain stimulation (DBS) to the Vim has been applied to regulate ET⁶⁾. However, the stereotactic introduction of the electrode to the Vim and implantation of the pulse generator for DBS at the subcutaneous pocket of the infra-clavicle are invasive. Postoperative infection or device disorders interrupt continuous neuromodulation. The rate of complication associated with the surgical treatment would rather increase at the bilateral side handling than at the hemi-lateral side handling. Further, patient with post-DBS implantation needs the impairment of the intensity of electric stimulation by the physician owing to the change in clinical symptoms. In addition, the pulse generator needs exchanging to maintain constant stimulation. The DBS is

Received: January 18, 2022

Accepted: June 16, 2022

Correspondence: Akira Tempaku, Department of Neurosurgery, Hokuto Hospital, 7-5 Inada-cho-kisen, Obihiro, Hokkaido 080-0833, Japan

E-mail: tempaku@hokuto7.or.jp

This is an open-access article distributed under the terms of the Creative Commons Attribution Non-Commercial No Derivatives

(by-nc-nd) License <<http://creativecommons.org/licenses/by-nc-nd/4.0/>>.



useful but demands a continuous follow-up. Dual side DBS demands double the maintenance.

Magnetic resonance (MR)-guided focus ultrasound (MRgFUS) is established as a less invasive therapy against ET⁷⁻⁹, Parkinson's disease, and breast cancer etc¹⁰. A clinical trial of MRgFUS for ET shows a remarkable outcome with a few complications⁸. An MRgFUS against Vim is a kind of thalamotomy without any surgical treatment. Since MRgFUS is a less invasive therapy, the risk of neurological deficit is assumed to be similar to that of the classical thalamotomy. Hemi-lateral Vim treatment by MRgFUS was confirmed to be a useful procedure for hemi-lateral ET⁹. However, some patients of ET suffer from bilateral tremors. Though Gallay reported the success of bilateral MRgFUS treatment for the cerebellothalamic tract within a few cases¹¹, the safety is still under discussion. Because the experience of bilateral MRgFUS treatment is limited in cases and the observation time is short, the complications of bilateral MRgFUS treatment remain unclear. Furthermore, we don't know the effects and complications of the direct thalamotomy for bilateral Vim.

Case Report

A 66-year-old right-handed man had medication-resistant bilateral ET in the upper extremities. He had diabetes mellitus and hypertension with medication. His mother had essential tremors. His tremor had been onset at the left upper extremity for a 60-years-old. Within a few years, the right upper extremity also started having tremors. The movement-induced tremor was much more severe in the left upper extremity. No obvious brain lesion was detected. Because of mainly using his right hand during his job, he wanted to treat right-hand tremors, predominantly. To improve his social working activity, MRgFUS was performed on the left Vim at first. During the next year's follow-up, he had not acquired the tremor recurrence in the right upper limb and any neurological deficits by MRgFUS. Then, recovering the adequate quality of daily activities, DBS was introduced to the right Vim.

An MRgFUS was performed by ExAblate™ 4000 High-Intensity Focused Ultrasound (HIFU) head system with a 650 kHz transducer (Insightech, Tirat Carmel, Israel). The focus of ultrasound was determined by the MRI of fluid-attenuated inversion recovery (FLAIR). A computed tomography scan of cranial bone revealed the skull density ratio (SDR) was 0.39. The left Vim nucleus was sonicated 15 times (total irradiation energy was 174,776 Joule (J) and peak irradiation energy in one session was 22,620 J). During each sonication session, the severity of the tremor was checked by the drawing task.

Quadripolar DBS electrodes (Activa 3389, Medtronic, Dublin, Ireland) were implanted with a stereotactic proce-

dure. Target localization of the right Vim was based on the Schaltenbrand–Wahren atlas and direct visualization of the MRI image by using surgical planning computer software (Frame Link, Stealth Station, Medtronic, Dublin, Ireland). DBS electrode introduction to the right Vim was performed with Leksell frame following X 86.1 mm, Y 86.7 mm, Z 105.2 mm, Ring 70.2°, Arch 76.2° condition^{12, 13}. Right, Vim was physiologically isolated by micro-electrophysiological test¹⁴. It was confirmed with tremor inducing test, which was performed under the local anesthesia without a muscle relaxant. An internal pulse generator (ActivaSC 37603, Medtronic) was implanted at the right subclavian subcutaneous pocket and connected with the DBS electrode. DBS was started under 0-1+, 90 μ sec, 160 Hz, 0.5 V, 2,019 Ω , 0.261 mA conditions. Stimulation intensity was gradually modulated due to the tremor severity, for the following 15 months.

The clinical rating scale for tremor (CRST)¹⁵ was used to estimate premedication and improved states by MRgFUS and DBS, respectively.

The left Vim nucleus was degenerated by MRgFUS treatment. The sonicated spot was visualized by T2 weighted MRI (Figure 1). The tremor of the right upper extremity was improved by MRgFUS against the left Vim. CRST in the right arm was reduced from 12 to 0 points. MRgFUS to the left Vim got 100% of improvement on the right trem-

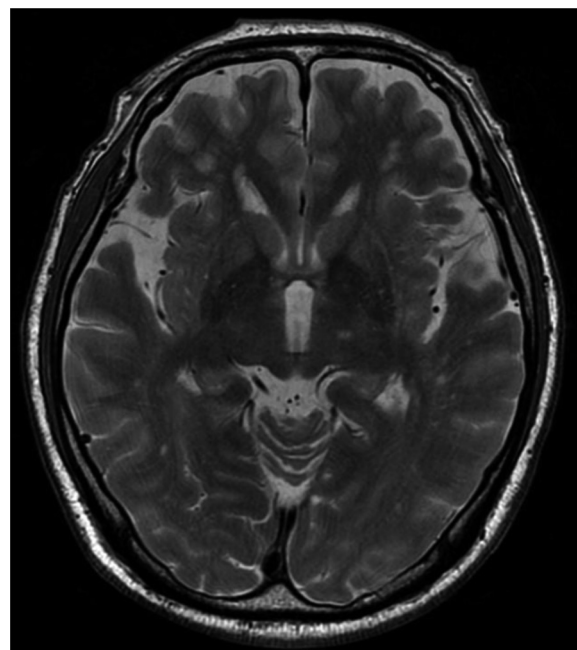


Figure 1 T2 weighted magnetic resonance image (MRI) of the head. After the magnetic resonance (MR)-guided focus ultrasound treatment against the left ventral intermediate nucleus, T2 MRI was obtained. The edematous focus of sonication showed a hyperintensity signal.

or. The recurrent tremor was not observed during the next year. The electrode of DBS was successfully introduced to the right Vim (Figure 2). Tremor of the left upper extremity was diminished by DBS to the right Vim. CRST in the left arm was reduced from 23 to 1 point. The DBS to the right Vim caused a 96% of improvement on left tremor. Disability in daily life (Part C in CRST) was improved from 18 to 5 points by left MRgFUS and from 5 to 1 points by right DBS, respectively. The improvement rate was 72% by left MRgFUS and 80% by right DBS, respectively. The total score of CRST was improved from 52 to 31 points by left MRgFUS and from 31 to 2 points by right DBS, respectively (Figure 3). The improvement rate of the total CRST score was 40% by left MRgFUS and 94% by right DBS, respectively. Part C of the CRST score was improved from 32 to 23 points by left MRgFUS and 23 to 1 point by right DBS, respectively. Tremor of right upper extremity reduced from 12 to 0 point by left MRgFUS. Tremor of left upper extrem-

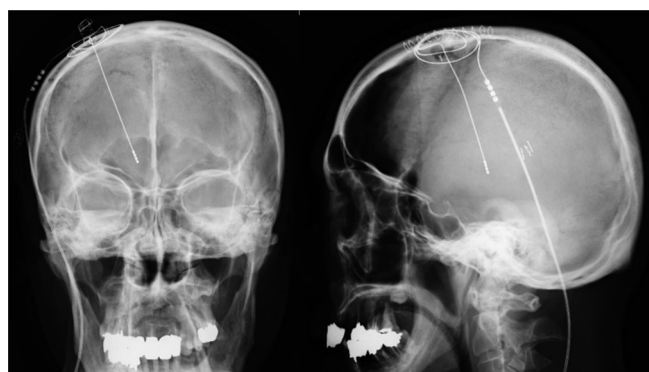


Figure 2 Cranial X-ray picture. The microelectrode was introduced to the right ventral intermediate nucleus. The position of the electrode tip was checked by the anterior-posterior view and lateral side view.

ity changed from 20 to 23 points by left MRgFUS, and from 23 to 1 point by right DBS, respectively (Table 1). The total improvement rate by MRgFUS and DBS hybrid surgery was 96%. No neurological deficiencies or other complications were observed during the clinical course of MRgFUS treatment and DBS introduction. The patient developed no speech disturbance or ataxia.

In the course of the following five years post-DBS and six years post-MRgFUS, right tremor has been slightly recurrent occasionally in daily life. Right hand CRST has been 1 point with slight positional tremor. Action tremors, which include writing, drawing, and pouring are occasionally observed in daily living activities. Left-hand CRST is 0 points. Action tremors at pouring are rarely observed. Total

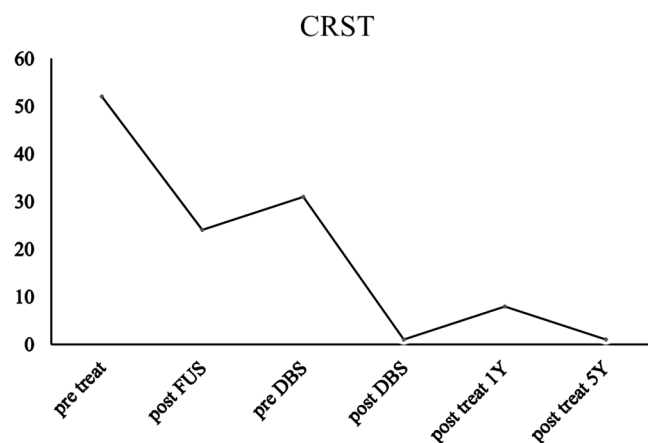


Figure 3 A severity of tremor in the whole observation period was estimated by CRST. Pre-DBS means a post-1 year of MRgFUS. Post treat 1Y and 5Y mean that post 2 years of FUS with post 1 year of DBS and post 6 years of FUS with post 5 years of DBS, respectively. CRST: clinical rating scale for tremor; FUS: focus ultrasound; DBS: deep brain stimulation.

Table 1 Clinical transition of tremor severity for the FUS and DBS treatment

	Limb	Positional	Intentional	Actional (drawing+pouring)	Hemi-total	Total
Pre treat	RUE	2	2	8	12	32
	LUE	4	3	8	20	
Post FUS (left Vim)	RUE	0	0	0	0	23
	LUE	4	3	16	23	
Post DBS (right Vim)	RUE	0	0	0	0	1
	LUE	1	0	0	1	
Post 2Y FUS	RUE	0	0	0	0	7
	LUE	1	0	6	7	
Post 6Y FUS	RUE	1	0	0	1	1
	LUE	0	0	0	0	

FUS: focus ultrasound; DBS: deep brain stimulation; Vim: ventral intermediate nucleus; RUE: right upper extremity; LUE: left upper extremity.

CRST in long term is 1 point (Figure 3). Continuous modulation of DBS stimulation was done. No medication was needed against tremors.

This case report was conducted in accordance with the ethical standards of the institutional and/or national research committee and with the 1964 Helsinki declaration and its later amendments or comparable ethical standards. Informed consent was obtained from the patient for publication of this case report and any accompanying images.

Discussion

The MRgFUS against the Vim is a type of thalamotomy. Tremor severity and adverse event occurrence by sonicating destruction of the Vim were checked during the treatment at the interval of each sonication. For the MRgFUS treatment, he experienced no obvious adverse events. The tremor of the right upper extremity was almost diminished. Following the previous reports, hemi-lateral MRgFUS could improve the tremor of the contralateral side. However, bilateral ET patients usually need both sides of treatment for the improvement of activities of daily living. Because the previous study demonstrated the complications of bilateral thalamotomy⁵⁾, it was careful of causing permanent deficits of speech disturbance or ataxia from bilateral MRgFUS. Though Galloway reported the success of bilateral MRgFUS treatment as the cerebellothalamic tractomy¹¹⁾ for three patients without any complications, long-term outcomes remain opaque. In addition, direct thalamotomy for bilateral Vim by MRgFUS was never performed. Alshaikh presumed the bilateral thalamotomy might be useful with no complication among patients without any baseline abnormalities in speech and balance¹⁶⁾. However, nobody could confirm the safety of bilateral Vim treatment by MRgFUS. For these reasons, bilateral MRgFUS is still under restriction during the clinical trial for ET.

Bilateral ET patients sometimes experienced slightly worse non-treatment side tremors after MRgFUS. This patient also experienced worse left upper extremity tremors from 20 to 23 points in CRST. The mechanism is still unclear, that should be researched in the future.

Tremor of the left upper extremity worsened for one-year post DBS against right Vim. This slight progression of the tremor was usually observed in DBS therapy. In the early period post-DBS operation, tremor is well suppressed by

the surgical thalamotomy effect and electrical stimulation. Because the surgical thalamotomy effect diminishes for several months post-DBS, the tremor suppression decreases slightly. The continuous modulation of DBS regulates the tremor for an extended period.

Hybrid surgery including MRgFUS, and DBS could be a useful therapy against medication-resistant bilateral essential tremors. Reducing the apparatus implantation number would contribute to diminishing the surgery-associated complications. Brain surface condition and the distribution of veins and arteries are patient specific matters. Integrated surface vessels might prevent adequate DBS electrode introduction. This combined procedure would apply to some patients, who present any difficulties to introduce DBS to the bilateral brain side. This hybrid surgery could be performed on patients with post-traumatic, post-operative, or some brain-damaged disease carriers, who have much trouble with the introduction of microelectrode to the deep brain.

Conclusion

The hybrid surgery of MRgFUS and DBS for the medication-resistant bilateral essential tremor is useful. Tremor regulation for the long term is sufficient without any neurological complications.

Conflicts of interest: There are no potential conflicts of interest to disclose. The author has no personal financial or institutional interest in any of the drugs, materials, or devices mentioned in this article.

Acknowledgments

MRgFUS was performed as a clinical trial for essential tremor (Clinical trial on effectiveness and safety of Exablate MRgFU thalamotomy for medically intractable essential tremor: ET002J). I thank Insightech staff for the technical support of the ExAblate™ 4000 HIFU head system operation. I thank K. Yamada for the MRgFUS operation and the technical advice on DBS implantation. This case research was supported by T. Maeda and K. Moriyama at the MRgFUS operation. This patient was managed by K. Kondoh, A. Mori, Y. Tsutsumi and T. Okada.

References

1. Nagaseki Y, Shibasaki T, Hirai T, *et al.* Long-term follow-up results of selective VIM-thalamotomy. *J Neurosurg* 1986; 65: 296–302. [[Medline](#)] [[CrossRef](#)]
2. Benabid AL, Pollak P, Gervason C, *et al.* Long-term suppression of tremor by chronic stimulation of the ventral intermediate thalamic nucleus. *Lancet* 1991; 337: 403–406. [[Medline](#)] [[CrossRef](#)]
3. Goldman MS, Ahlskog E, Kelly PJ. The symptomatic and functional outcome of stereotactic thalamotomy for medically intractable essential tremor. *J Neurosurg* 1992; 76: 924–928. [[Medline](#)] [[CrossRef](#)]

4. Goldman MS, Kelly PJ. Stereotactic thalamotomy for medically intractable essential tremor. *Stereotact Funct Neurosurg* 1992; 58: 22–25. [[Medline](#)] [[CrossRef](#)]
5. Matsumoto K, Asano T, Baba T, *et al.* Long-term follow-up results of bilateral thalamotomy for parkinsonism. *Appl Neurophysiol* 1976-1977; 39: 257–260. [[Medline](#)]
6. Lyons KE, Pahwa R. Deep brain stimulation and tremor. *Neurotherapeutics* 2008; 5: 331–338. [[Medline](#)] [[CrossRef](#)]
7. Lipsman N, Mainprize TG, Schwartz ML, *et al.* Intracranial applications of magnetic resonance-guided focused ultrasound. *Neurotherapeutics* 2014; 11: 593–605. [[Medline](#)] [[CrossRef](#)]
8. Elias WJ, Huss D, Voss T, *et al.* A pilot study of focused ultrasound thalamotomy for essential tremor. *N Engl J Med* 2013; 369: 640–648. [[Medline](#)] [[CrossRef](#)]
9. Chang WS, Jung HH, Kweon EJ, *et al.* Unilateral magnetic resonance guided focused ultrasound thalamotomy for essential tremor: practices and clinicoradiological outcomes. *J Neurol Neurosurg Psychiatry* 2015; 86: 257–264. [[Medline](#)] [[CrossRef](#)]
10. Dobrakowski PP, Machowska-Majchrzak AK, Labuz-Roszak B, *et al.* MR-guided focused ultrasound: a new generation treatment of Parkinson's disease, essential tremor and neuropathic pain. *Interv Neuroradiol* 2014; 20: 275–282. [[Medline](#)] [[CrossRef](#)]
11. Galloway MN, Moser D, Rossi F, *et al.* Incisionless transcranial MR-guided focused ultrasound in essential tremor: cerebellothalamic tractotomy. *J Ther Ultrasound* 2016; 4: 5 [[CrossRef](#)]. [[Medline](#)]
12. McNeely PD, Mendez I, Hill R, *et al.* Stabilization clamp for insertion of deep brain stimulation electrodes: technical note. *Stereotact Funct Neurosurg* 2004; 82: 31–34. [[Medline](#)] [[CrossRef](#)]
13. Yamada K, Hamasaki T, Kuratsu J. Thalamic stimulation alleviates levodopa-resistant rigidity in a patient with non-Parkinson's disease parkinsonian syndrome. *J Clin Neurosci* 2014; 21: 882–884. [[Medline](#)] [[CrossRef](#)]
14. Umemura A, Oka Y, Yamada K, *et al.* Validity of single tract microelectrode recording in subthalamic nucleus stimulation. *Neurol Med Chir (Tokyo)* 2013; 53: 821–827. [[Medline](#)] [[CrossRef](#)]
15. Fahn S, Tolosa E, Marin C. Clinical rating Scale for Tremor. In: *Parkinson's Disease and Movement Disorders*. Jankovik J and Tolosa E. Urban & Schwarzenberg, Baltimore-Munich, 1988; 225–234.
16. Alshaiikh J, Fishman PS. Revisiting bilateral thalamotomy for tremor. *Clin Neurol Neurosurg* 2017; 158: 103–107. [[Medline](#)] [[CrossRef](#)]