



# Acute amiodarone pulmonary toxicity in the form of organizing pneumonia triggered by orthotopic heart transplantation

Natalya Kozlova<sup>a</sup>, Gregg M. Lanier<sup>b</sup>, George Kleinman<sup>c</sup>, Oleg Epelbaum<sup>a,\*</sup>

<sup>a</sup> Division of Pulmonary, Critical Care, and Sleep Medicine, Westchester Medical Center, Valhalla, NY, USA

<sup>b</sup> Division of Transplant Cardiology, Westchester Medical Center, Valhalla, NY, USA

<sup>c</sup> Department of Pathology, Westchester Medical Center, Valhalla, NY, USA

## ARTICLE INFO

### Keywords:

Amiodarone  
Pulmonary toxicity  
Organizing pneumonia  
Heart transplantation

## ABSTRACT

We report a case of a 60-year-old man who underwent orthotopic heart transplantation after short-term receipt of low-dose oral amiodarone for the management of ventricular tachycardia. Prior to transplant surgery, he had a normal chest radiograph and was free of supplemental oxygen. His initial postoperative chest radiograph showed subtle infiltrates, and thereafter his chest imaging continued to worsen. Although he was eventually able to wean off mechanical ventilation via a tracheostomy, he remained dyspneic and oxygen-dependent with persistently abnormal chest imaging as his post-transplant corticosteroid regimen was being tapered. In light of progressively worsening diffuse lung disease, he underwent bronchoscopy with transbronchial biopsies. Histology revealed foamy macrophages in association with foci of organizing pneumonia, a picture consistent with amiodarone pulmonary toxicity. Given these findings, corticosteroid dosing was increased for the clinical diagnosis of acute amiodarone pulmonary toxicity with subsequent normalization of oxygen saturation and chest radiography. Our case is the first to identify orthotopic heart transplantation as a potential trigger for acute amiodarone pulmonary toxicity. It is also only the second documented example of organizing pneumonia as the histological substrate of amiodarone pulmonary toxicity, which is an association that has therapeutic implications.

## 1. Introduction

Amiodarone is a heavily iodinated compound that was first introduced into clinical practice as an antianginal agent in the 1960s [1]. Given its multifaceted antiarrhythmic properties and favorable cardiovascular side effect profile, amiodarone has become a widely prescribed pharmaceutical for atrial fibrillation and ventricular tachycardia. At the same time, the prescribing community has encountered amiodarone's myriad adverse reactions with amiodarone pulmonary toxicity (APT) being perhaps the most familiar. Typically presenting subacutely and afflicting those with large cumulative drug dosing, APT also has an acute variant in which antecedent cardiothoracic interventions are implicated as inciting events in an apparent "two-hit" phenomenon. Almost every type of cardiothoracic procedure and operation has been linked to acute APT with the notable exception of orthotopic heart transplantation (OHT). We describe a case of acute APT that complicated the immediate postoperative course of an OHT recipient with relatively brief pre-transplant amiodarone exposure. Our patient's lung biopsy revealed

organizing pneumonia, a pattern heretofore associated more closely with subacute than acute APT and important to recognize because of its exquisite corticosteroid sensitivity.

## 2. Case report

### 2.1. Clinical history

A 60-year-old man was transferred to our institution from an outlying hospital for OHT evaluation. He had a history of non-ischemic cardiomyopathy (NICM) with a left ventricular ejection fraction by echocardiography of 25%. His NICM was complicated by multiple episodes of ventricular tachycardia, which was the reason for his admission to the outlying hospital. He had been taking amiodarone for approximately 3 months prior to presentation to that hospital. There he was continued on amiodarone and was transferred to our institution with a dose of 200mg orally twice daily, which was later reduced to 200mg once daily. He had known chronic kidney disease. He was a former smoker with a history of chronic obstructive pulmonary disease (COPD)

\* Corresponding author. Westchester Medical Center Division of Pulmonary, Critical Care, and Sleep Medicine, 100 Woods Road, Macy Pavilion—Pulmonary Lab, Valhalla, NY, 10595, USA.

E-mail address: [oleg.epelbaum@wmchealth.org](mailto:oleg.epelbaum@wmchealth.org) (O. Epelbaum).

<https://doi.org/10.1016/j.rmcr.2021.101532>

Received 16 August 2021; Accepted 19 October 2021

Available online 22 October 2021

2213-0071/© 2021 The Authors.

Published by Elsevier Ltd.

This is an open access article under the CC BY-NC-ND license

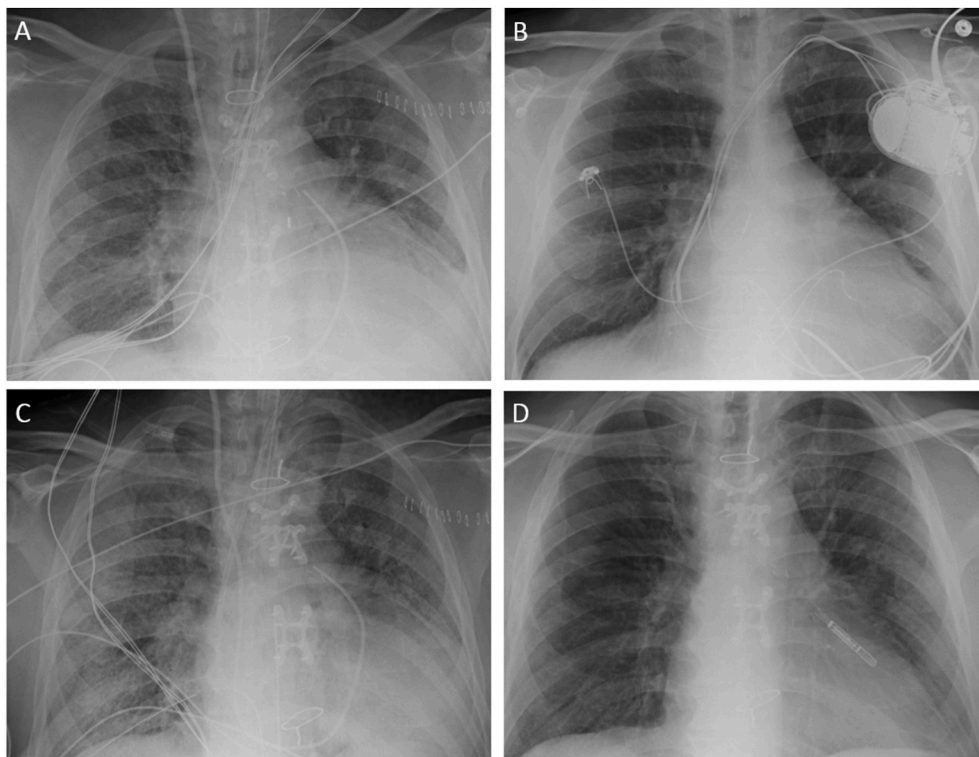
(<http://creativecommons.org/licenses/by-nc-nd/4.0/>).

**Abbreviations**

APT	Amiodarone pulmonary toxicity
AAPT	Acute/Accelerated amiodarone pulmonary toxicity
COPD	Chronic obstructive pulmonary disease
CT	Computed tomography
CXR	Chest radiograph
GGO	Ground glass opacity
IABP	Intra-aortic balloon pump
NICM	Non-ischemic cardiomyopathy
OHT	Orthotopic heart transplantation
OP	Organizing pneumonia
POD	post-operative day

dobutamine infusion and was breathing comfortably on room air with an oxygen saturation of 97%. Physical examination was remarkable for the absence of jugular venous distention and lower extremity edema. Lungs were clear to auscultation, and he had warm extremities. Laboratory evaluation was significant for elevated serum creatinine of 2.61mg/dL (normal range 0.72–1.25mg/dL). Liver function testing was normal. His initial chest radiograph (CXR) demonstrated clear lung fields.

His hospital course was characterized by persistent requirement for inotropic and vasodilator therapy as well as support with an intra-aortic balloon pump (IABP). He remained with oxygen saturations of >90% on room air throughout. On hospital day 78, he underwent OHT with a graft ischemic time of 191 minutes. The donor was seropositive for cytomegalovirus; the patient was seronegative. Amiodarone had been continued up until the day of surgery. His immediate post-transplant course was complicated by biventricular acute graft dysfunction, so

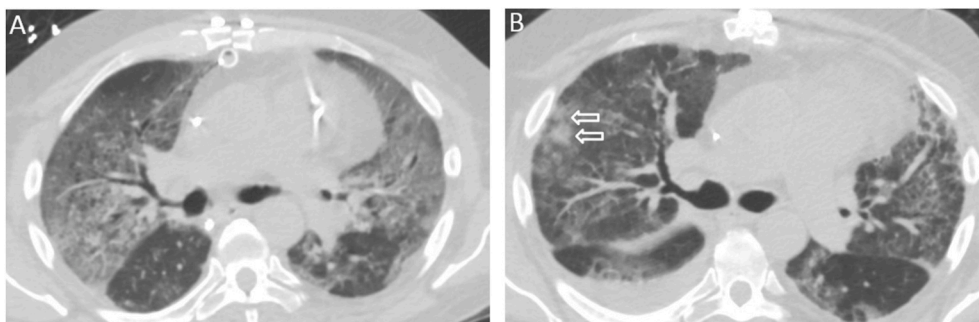


**Fig. 1.** Portable chest radiographs. (A) The patient’s chest radiograph upon emerging from the operating room after his orthotopic heart transplantation showed subtle reticular infiltrates interpreted at the time as mild postoperative pulmonary edema. (B) The patient’s chest radiograph obtained upon arrival to our institution had shown clear lung fields as had his last preoperative chest radiograph taken 12 days prior to transplantation (not provided). (C) The patient’s chest radiograph from the fifth postoperative day demonstrated progression of diffuse bilateral opacities in comparison to the initial postoperative film in panel (A). (D) The patient’s chest radiograph obtained following completion of corticosteroid therapy for organizing pneumonia revealed marked improvement in the appearance of lung fields compared to panel (C).

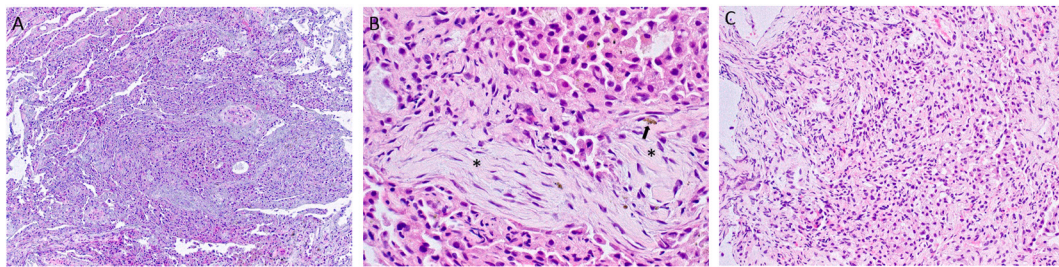
and was receiving combination inhaled therapy with fluticasone-salmeterol at time of transfer.

Upon transfer, he was hemodynamically stable while receiving a

IABP support was maintained, and he received milrinone, dopamine, and epinephrine infusions. Inhaled nitric oxide was initiated at 40 parts per million. His initial immunosuppressive regimen consisted of



**Fig. 2.** Chest computed tomography (CT). (A) Axial chest CT section set to lung window from the scan obtained on the fifth postoperative day showing confluent bilateral ground glass opacities heavily affecting the upper lobes. (B) Axial CT section set to lung window from the scan repeated on postoperative day 35 showing residual ground glass opacities along with a subpleural focus of consolidation in the right upper lobe (arrows). The same pattern was observed in other lung zones, and areas of subpleural reticulation were noted elsewhere, concerning for evolving fibrosis (not shown).



**Fig. 3.** (A) Lung histology from transbronchial biopsy. (A) Low power magnification showing lung parenchyma with thickened alveolar septa and mild chronic inflammation. Vaguely nodular and relatively demarcated areas of loose fibrosis, as well as numerous desquamated pneumocytes, are seen (H&E 100X). (B) High power magnification showing fibrocollagenous polypoid plugs (asterisks) within the alveolar spaces that also partially obstruct the bronchiolar lumina. Alveolar spaces are filled by loose collections of histiocytes, many of which reveal cytoplasmic vacuolization, indicative of amiodarone exposure. Yellow-brown pigment (arrow) is evident, suggestive of prior alveolar hemorrhage or exudation (H&E 400X). (C) Intermediate power magnification showing alveolar wall thickening with diffuse type II pneumocyte hyperplasia and focal squamous metaplasia (H&E 200X). (For interpretation of the references to colour in this figure legend, the reader is referred to the Web version of this article.)

methylprednisolone and mycophenolate mofetil, in addition to which he received three doses of antithymocyte globulin, and then tacrolimus was added. CXR performed on postoperative day (POD) 0 showed subtle bilateral infiltrates interpreted as mild postoperative pulmonary edema (Fig. 1A). A pre-operative CXR had been obtained 12 days prior to transplant, and at that time the lung fields were clear, as they had been when he first arrived to our institution (Fig. 1B). Despite normalization of left ventricular function and a course of diuresis, by POD 5 the patient remained mechanically ventilated and exhibited progressively worsening chest radiography (Fig. 1C). Chest computed tomography (CT) performed on that day showed diffuse ground glass opacities (GGO) bilaterally, most prominently affecting the upper lobes (Fig. 2A). Over the ensuing weeks, the patient underwent tracheostomy and was weaned off mechanical ventilation. His corticosteroid regimen was gradually reduced to 20mg daily. Off the ventilator, he remained dependent on supplemental oxygen and dyspneic with persistently abnormal chest radiography. On POD 35, chest CT was repeated, now showing a mixture of GGO and consolidation as well as subpleural reticulation, the latter consistent with evolving fibrotic changes (Fig. 2B). At that point, his corticosteroid regimen was changed to prednisone 60mg daily, and bronchoscopy with transbronchial biopsies of the right upper, middle, and lower lobes was performed a week later.

## 2.2. Histopathological findings

Microscopic sections revealed lung parenchyma with thickened alveolar septa and mild chronic inflammation. Vaguely nodular and relatively demarcated areas of loose fibrosis were evident (Fig. 3A). Characteristic of the organizing pneumonia (OP) pattern, fibrocollagenous polypoid plugs were present within the alveolar spaces and partially obstructed and obliterated bronchiolar lumina. Alveolar spaces were focally collapsed and filled by loose collections of histiocytes, many of which exhibited cytoplasmic vacuolization (so-called “foamy” appearance), indicative of amiodarone exposure. Yellow-brown pigment within the alveolar lumina was also seen, suggesting antecedent mild focal alveolar hemorrhage (Fig. 3B). Additionally, diffuse type II pneumocyte hyperplasia and focal squamous metaplasia were identified (Fig. 3C). No histological evidence of viral cytopathic changes, intracellular organisms, or granulomata were identified. The constellation of histopathological findings detailed above is consistent with the OP pattern.

## 2.3. Follow up

The patient completed a prolonged course of prednisone for the clinical diagnosis of OP as a manifestation of acute APT. After two months of therapy, his CXR markedly improved (Fig. 1D), and he was free of supplemental oxygen. Chest CT did, however, continue to show

residual subpleural fibrosis. His subsequent post-transplant course was complicated by *Pneumocystis jirovecii* pneumonia and invasive pulmonary aspergillosis. The patient ultimately passed away at his local hospital from mounting complications of OHT.

## 3. Discussion

Amiodarone is a class III antiarrhythmic drug with a broad range of applications that have been reviewed elsewhere [2]. The use of this versatile agent is limited by a correspondingly broad range of extra-cardiac toxicities; lung involvement, although not the most frequent, tends to be the most feared. Classically, APT is an indolent process in which patients present with subacute symptoms such as cough and dyspnea after accumulation of a threshold amiodarone exposure in a dose-dependent fashion. The histological signature of the exposure of lung to amiodarone is the presence of so-called “foamy” macrophages that acquire this appearance due to phospholipid inclusions resulting from amiodarone’s interference with intracellular phospholipid processing. Although these complexes of amiodarone bound to phospholipids are one of the factors implicated in APT pathogenesis, their presence in isolation is not a marker of lung toxicity. Histopathological patterns associated with typical subacute APT are numerous and include cellular nonspecific interstitial pneumonia, lymphoid interstitial pneumonia, eosinophilic pneumonia, and OP [3]. All of these substrates share sensitivity to corticosteroids, explaining the robust response of subacute APT to this form of therapy. Although rarely fatal, APT may leave behind a fibrotic diffuse parenchymal lung disease that can be difficult to differentiate from idiopathic fibrotic lung diseases such as idiopathic pulmonary fibrosis and idiopathic fibrosing nonspecific interstitial pneumonia [4]. It should be noted that lung histology in patients with APT who are selected for biopsy or autopsy may be characterized predominantly by diffuse alveolar damage (DAD), a lung injury pattern that correlates with acute respiratory distress syndrome (ARDS), at time of sampling [5].

It has been recognized since at least the 1980s that APT can also develop very rapidly, leading to acute or accelerated APT (AAPT) that in its most sudden and catastrophic form fulfills criteria for ARDS [6]. Occurrence of this type of APT tends to follow cardiothoracic procedures and surgeries, an observation that suggests triggering by the interventions themselves or the associated mechanical ventilation, including high inspired oxygen fractions, among other potential culprits [7]. Most descriptions of AAPT involve amiodarone use over months to years, but cases limited to perioperative exposure measured in days to weeks have also been reported [8,9]. To our knowledge, OHT has not been previously implicated as the catalyst for onset of AAPT. Although amiodarone is recognized as a valuable antiarrhythmic option in pre-OHT patients, it has been previously linked to increased post-transplant mortality and primary graft dysfunction, which was



**Table 1**

Tabulation of published cases of amiodarone pulmonary toxicity, including the present case, with organizing pneumonia as the underlying lung histology.

Source/Year	Age/Gender	Amiodarone exposure	APT or AAPT	Diagnostic modality	Therapy	Outcome
Valle 1995 [14]	61/F	8 years	APT	TBB	CS	Recovered
Conte 1997 [15]	69/M	4 years	APT	OLB	CS	Recovered
Aranda 1998 [16]	77/M	1.5 years	APT	TBB	CS	Recovered
Malhotra 2003 [17]	82/M	1 year	APT	OLB	CS	Recovered
Ott 2003 [18]	82/M	2 years	APT	OLB	CS	Died
Omeroglu 2006 [13]	67/M	NR	APT	OLB	AW	Recovered
Boriani 2012 [8]	77/M	4 days <sup>a</sup>	AAPT	OLB	CS	Died
Chatterjee 2017 [19]	58/M	7 months	APT	OLB	CS	Recovered
Coulier 2020 [20]	78/M	10 years	APT	NR	AW	Recovered
Present Case	60/M	6 months <sup>b,c</sup>	AAPT	TBB	CS	Recovered

APT = (subacute) amiodarone pulmonary toxicity; AAPT = acute amiodarone pulmonary toxicity; AW = amiodarone withdrawal; CS = corticosteroids; OLB = open lung biopsy; TBB = transbronchial lung biopsy.

<sup>a</sup> Postoperative administration.

<sup>b</sup> Approximate duration.

<sup>c</sup> Preoperative administration.

present in this case [10]. However, both a recent study [11] as well as an updated meta-analysis [12] found no association between amiodarone use of any duration and reduced post-OHT survival. It is unknown whether APT has been a contributing factor to the turbulent history between amiodarone and OHT.

OP is a lung histology pattern that can occur in response to an insult of any form, including drug toxicity. Predictably, it has been described as both the predominant and accompanying finding on lung biopsy of patients with APT. The vast majority of reported APT cases characterized by histologically confirmed OP in lung samples have been classic ones with subacute evolution and prolonged exposure to amiodarone (Table 1). Of note, they include an OHT candidate diagnosed with APT prior to transplant who improved with drug discontinuation and eventually underwent successful transplantation [13]. They also include a case of AAPT following thoracic surgery in a patient treated with amiodarone only in the immediate postoperative period [8]. In this specific group of cases with OP histology, ours stands out as only the second with AAPT and the first linked to OHT. As mentioned, we are not aware of another published case wherein OHT served as the trigger for amiodarone pulmonary toxicity irrespective of lung histology, disease tempo, and duration of exposure. OHT is unique among cardiac surgeries in that it is followed by initiation of potent immunosuppressive therapy, including calcineurin inhibitors such as tacrolimus. Because immunosuppression is likewise the treatment for OP, it could be reasonably hypothesized that OHT surgery would be a rare inciting event for AAPT. On the other hand, there does exist a case report of APT following lung transplantation [21]. This raises the possibility that certain post-transplant medications like tacrolimus, which is metabolized by the liver, could potentiate toxicity from amiodarone. Our patient's lung disease persisted while post-transplant corticosteroid therapy was tapered, and it remitted only after the dose was increased to an effective level for OP.

#### 4. Conclusion

AAPT is a characteristic form of lung injury that could develop in a patient with primary cardiovascular disease, typically following an invasive procedure or surgery. Our case is a reminder that the exposure to amiodarone need not be extensive for this type of APT to occur in the early postoperative period. This case also adds OHT to the list of interventions that can be viewed as potential triggers for the development of AAPT. As post-transplant immunosuppression is tapered, corticosteroid-sensitive AAPT substrates such as OP may persist or even progress.

#### Funding

None.

#### Author contributions

NK: Conceived and designed the manuscript; labeled histopathology images and provided legends.

GL: Wrote the paper.

GK: Obtained and selected the histopathology images.

OE: Conceived and designed the manuscript; wrote the paper.

#### Declaration of competing interest

None of the authors has any conflicts of interest to declare.

#### Acknowledgements

None.

#### References

- [1] S.A. Papiris, C. Triantafyllidou, L. Kolilekas, D. Markoulaki, E.D. Manali, Amiodarone: review of pulmonary effects and toxicity, *Drug Saf.* 33 (7) (2010 Jul 1) 539–558, <https://doi.org/10.2165/11532320-000000000-00000>.
- [2] P. Vassallo, R.G. Trohman, Prescribing amiodarone: an evidence-based review of clinical indications, *J. Am. Med. Assoc.* 298 (11) (2007 Sep 19) 1312–1322, <https://doi.org/10.1001/jama.298.11.1312>.
- [3] B.T. Larsen, L.T. Vaszar, T.V. Colby, H.D. Tazelaar, Lymphoid hyperplasia and eosinophilic pneumonia as histologic manifestations of amiodarone-induced lung toxicity, *Am. J. Surg. Pathol.* 36 (4) (2012 Apr) 509–516, <https://doi.org/10.1097/PAS.0b013e318243fd9a>.
- [4] C.W. Bedrossian, C.J. Warren, J. Ohar, R. Bhan, Amiodarone pulmonary toxicity: cytopathology, ultrastructure, and immunocytochemistry, *Ann. Diagn. Pathol.* 1 (1) (1997 Oct) 47–56, [https://doi.org/10.1016/s1092-9134\(97\)80008-1](https://doi.org/10.1016/s1092-9134(97)80008-1).
- [5] P.J. Dean, K.D. Groshart, J.G. Porterfield, D.H. Iansmith, E.B. Golden Jr., Amiodarone-associated pulmonary toxicity. A clinical and pathologic study of eleven cases, *Am. J. Clin. Pathol.* 87 (1) (1987 Jan) 7–13, <https://doi.org/10.1093/ajcp/87.1.7>.
- [6] D.L. Wood, M.J. Osborn, J. Rooke, D.R. Holmes Jr., Amiodarone pulmonary toxicity: report of two cases associated with rapidly progressive fatal adult respiratory distress syndrome after pulmonary angiography, *Mayo Clin. Proc.* 60 (9) (1985 Sep) 601–603, [https://doi.org/10.1016/s0025-6196\(12\)60983-5](https://doi.org/10.1016/s0025-6196(12)60983-5).
- [7] J. Teerakanok, P. Tantrachoti, P. Chariyawong, K. Nugent, Acute amiodarone pulmonary toxicity after surgical procedures, *Am. J. Med. Sci.* 352 (6) (2016 Dec) 646–651, <https://doi.org/10.1016/j.amjms.2016.08.013>.
- [8] G. Boriani, L. Ferruzzi, B. Corti, A. Ruffato, G. Gavelli, S. Mattioli, Short-term onset of fatal pulmonary toxicity in a patient treated with intravenous amiodarone for post-operative atrial fibrillation, *Int. J. Cardiol.* 159 (1) (2012 Aug 9) e1–4, <https://doi.org/10.1016/j.ijcard.2011.10.134>.
- [9] H. Baumann, P. Fichtenkamm, T. Schneider, J. Biscopring, M. Henrich, Rapid onset of amiodarone induced pulmonary toxicity after lung lobe resection - a case report and review of recent literature, *Ann Med Surg (Lond)*. 21 (2017 Jul 19) 53–57, <https://doi.org/10.1016/j.amsu.2017.07.034>.
- [10] L.B. Cooper, R.J. Mentz, L.B. Edwards, A.R. Wilk, J.G. Rogers, C.B. Patel, et al., Amiodarone use in patients listed for heart transplant is associated with increased 1-year post-transplant mortality, *J. Heart Lung Transplant.* 36 (2) (2017 Feb) 202–210, <https://doi.org/10.1016/j.healun.2016.07.009>.
- [11] R. Rivinius, M. Helmschrott, A. Ruhparwar, F.F. Darche, D. Thomas, T. Bruckner, et al., Comparison of posttransplant outcomes in patients with no, acute, or chronic

- amiodarone use before heart transplantation, *Drug Des. Dev. Ther.* 11 (2017 Jun 19) 1827–1837, <https://doi.org/10.2147/DDDT.S136948>.
- [12] D.L. Jennings, W.L. Baker, Pre-cardiac transplant amiodarone use is not associated with postoperative mortality: an updated meta-analysis, *Int. J. Cardiol.* 236 (2017 Jun 1) 345–347, <https://doi.org/10.1016/j.ijcard.2017.02.045>.
- [13] G. Omeroglu, Y. Kalugina, C. Ersahin, E.M. Wojcik, Amiodarone lung toxicity in a cardiac transplant candidate initially diagnosed by fine-needle aspiration: cytologic, histologic, and electronmicroscopic findings, *Diagn. Cytopathol.* 34 (5) (2006 May) 351–354, <https://doi.org/10.1002/dc.20313>.
- [14] J.M. Valle, D. Alvarez, J. Antúnez, L. Valdés, Bronchiolitis obliterans organizing pneumonia secondary to amiodarone: a rare aetiology, *Eur. Respir. J.* 8 (3) (1995 Mar) 470–471, <https://doi.org/10.1183/09031936.95.08030470>.
- [15] S.C. Conte, V. Pagan, B. Murer, Bronchiolitis obliterans organizing pneumonia secondary to amiodarone: clinical, radiological and histological pattern, *Monaldi Arch. Chest Dis.* 52 (1) (1997 Feb) 24–26.
- [16] E. Antón Aranda, R. Alkiza Basañez, Y. Laplaza Jiménez, Bronchiolitis obliterans organising pneumonia secondary to amiodarone treatment, *Neth. J. Med.* 53 (3) (1998 Sep) 109–112, [https://doi.org/10.1016/s0300-2977\(98\)00060-6](https://doi.org/10.1016/s0300-2977(98)00060-6).
- [17] A. Malhotra, V.V. Muse, E.J. Mark, Case records of the Massachusetts General Hospital. Weekly clinicopathological exercises. Case 12-2003. An 82-year-old man with dyspnea and pulmonary abnormalities, *N. Engl. J. Med.* 348 (16) (2003 Apr 17) 1574–1585, <https://doi.org/10.1056/NEJMcpc030005>.
- [18] M.C. Ott, A. Khor, J.P. Leventhal, T.E. Paterick, C.D. Burger, Pulmonary toxicity in patients receiving low-dose amiodarone, *Chest* 123 (2) (2003 Feb) 646–651, <https://doi.org/10.1378/chest.123.2.646>.
- [19] K. Chatterjee, Y.M. Rochlani, K. Kuriakose, AndrewDunn, K. Khasawneh, H. Paydak, Amiodarone induced interstitial and organizing pneumonia reversed with steroids, *J. Ark. Med. Soc.* 113 (12) (2017 Jun) 294–296.
- [20] B. Coulier, G.C. Colin, G. Beniuga, Amiodarone-induced cryptogenic organizing pneumonia (COP), *Diagn Interv Imaging* 101 (9) (2020 Sep) 623–625, <https://doi.org/10.1016/j.diii.2020.01.004>.
- [21] E. Diaz-Guzman, E. Mireles-Cabodevila, A. Arrossi, J.P. Kanne, M. Budev, Amiodarone pulmonary toxicity after lung transplantation, *J. Heart Lung Transplant.* 27 (9) (2008) 1059–1063, <https://doi.org/10.1016/j.healun.2008.05.023>.