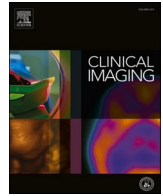



Elsevier has created a [Monkeypox Information Center](#) in response to the declared public health emergency of international concern, with free information in English on the monkeypox virus. The Monkeypox Information Center is hosted on Elsevier Connect, the company's public news and information website.

Elsevier hereby grants permission to make all its monkeypox related research that is available on the Monkeypox Information Center - including this research content - immediately available in publicly funded repositories, with rights for unrestricted research re-use and analyses in any form or by any means with acknowledgement of the original source. These permissions are granted for free by Elsevier for as long as the Monkeypox Information Center remains active.



Body Imaging

Imaging features of anorectal proctitis in monkeypox infection

Mark D. Messina^{a,*}, Ellen L. Wolf^a, Devaraju Kanmaniraja^a, Peter L. Alpert^b, Zina J. Ricci^a^a Department of Radiology, Montefiore Medical Center, Albert Einstein College of Medicine, 111 E 210th St, Bronx, NY 10467, USA^b Department of Medicine (Infectious Diseases), Montefiore Medical Center, Albert Einstein College of Medicine, 111 E 210th St, Bronx, NY 10467, USA

ARTICLE INFO

Keywords:

Monkeypox
Proctitis
Anorectal ulceration

ABSTRACT

The monkeypox outbreak of 2022 saw the first community-sustained transmission of the monkeypox virus outside of Africa, and rapidly developed into multi-country spread. A common presenting sign of monkeypox infection during this outbreak has been rectal pain due to proctitis. Proctitis with large hypoattenuated anorectal ulcers on CT scan should invoke consideration for monkeypox infection in young homosexual or bisexual men with associated skin eruptions.

1. Case description

A 41-year-old male presented to the emergency department (ED) with rectal pain and facial rash. His past medical history was notable for HIV with recent non-compliance with anti-retroviral therapy. His social history was relevant for anal and oral sex with men. The patient reported visiting an outpatient clinic earlier in the week and was told his facial rash was unlikely to be secondary to monkeypox and received a monkeypox vaccination. The facial rash worsened over the following days and the patient developed severe rectal pain with bowel movements and mild dysuria, prompting the ED visit. Physical exam was notable for multiple clustered, umbilicated lesions on the face, groin, penis, and peri-anal region. Vital signs were within normal limits. Leukocyte count was 9.7 k/ μ L (normal range: 4.8–10.8 k/ μ L). CD4 count was 48/mm³. Monkeypox PCR from a penile lesion swab was sent, subsequently positive. Gonorrhea and chlamydia DNA tests were negative. Rapid plasma reagin was performed to evaluate for syphilis and found to be negative. The patient was discharged from the ED with pain medication and stool softeners. The patient returned two days later to the ED with persistent abdominal pain, liquid bowel movements, a small amount of red blood after wiping, and increasing skin lesions. On clinical exam the patient was febrile with a temperature of 101 F and digital rectal examination was significant for exquisite tenderness but without frank blood. Leukocyte count was slightly elevated at 10.9 k/ μ L.

Contrast-enhanced CT scan of the abdomen and pelvis (Fig. 1) revealed severe anorectal proctitis with discrete large mural hypoattenuated anorectal ulcers, perirectal fat stranding, and pelvic free fluid. Additional findings included an increased number of small inguinal lymph nodes and a small right pleural effusion. There was no

abscess, peri-anal fistula, or extra-luminal air. Infectious Disease was consulted, and the patient admitted to the hospital and started on broad-spectrum antibiotics and Tecovirimat. General surgery and interventional radiology were also consulted for possible abscess drainage that was deferred secondary to lack of organized collection. The patient clinically improved with conservative management. A repeat CT scan (Fig. 2) performed 11 days after admission revealed improvement in anorectal mural thickening and ulcers with decrease in perirectal fat stranding, and resolution of pelvic ascites. The patient was discharged home to complete a 14-day course of Tecovirimat and one additional week of oral antibiotics.

2. Discussion

Monkeypox is a zoonotic infection caused by the Orthopox DNA monkeypox virus. Historically endemic to West and Central Africa, the global outbreak in May 2022 represents the first instance of sustained community transmission outside Africa.¹ As of September 19, 2022, there have been 62,406 cases of monkeypox worldwide, including 23,892 cases in the United States.²

Transmission of the virus has been considered to occur via prolonged respiratory droplet exposure, direct contact with body fluids of an infected individual, and by contact of mucosa with skin lesions. The present outbreak affects almost universally young men who identify predominantly as men who have sex with men, suggesting spread by sexual contact. Classically, monkeypox presents with a prodrome of fever, lethargy, myalgias and headache, as well as lymphadenopathy after an incubation period of 3–20 days.³ These findings are often followed by rash, typically first on the face, and particularly in this current

* Corresponding author.

E-mail address: MaMessina@montefiore.org (M.D. Messina).<https://doi.org/10.1016/j.clinimag.2022.10.008>

Received 30 September 2022; Received in revised form 7 October 2022; Accepted 18 October 2022

Available online 20 October 2022

0899-7071/© 2022 Elsevier Inc. All rights reserved.

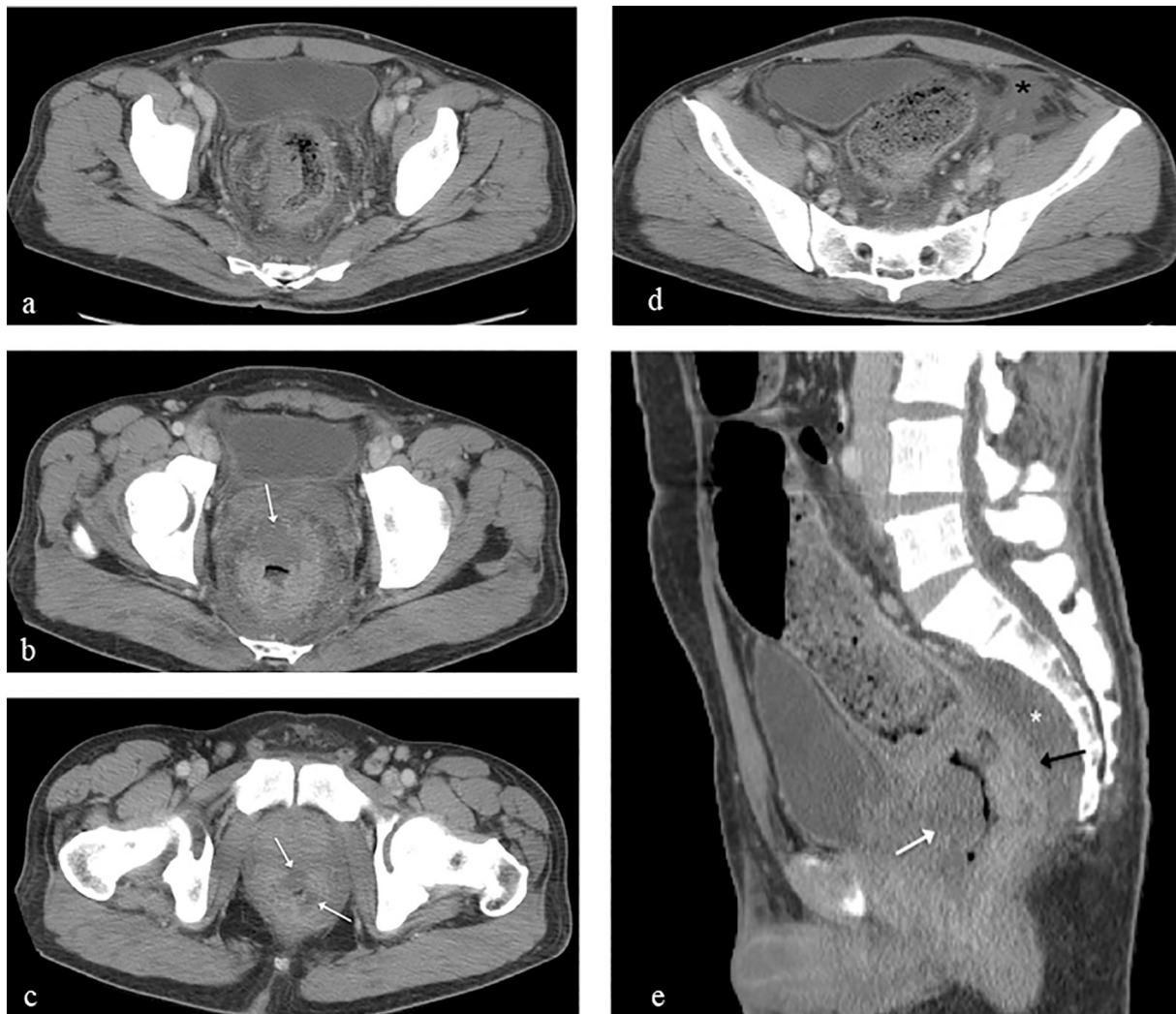


Fig. 1. Axial images from contrast-enhanced CT scan of the abdomen and pelvis reveal (a) diffuse circumferential rectal mural thickening, hazy infiltrated perirectal fat, and presacral edema with discrete geographic non-enhancing hypoattenuated zones (white arrows) in the rectal (b) and anal wall (c) due to large ulcerations and (d) pelvic ascites (black asterisk). Several bilateral inguinal lymph nodes measuring up to 1 cm are seen on (c). Sagittal image (e) reveals the thickened enhancing posterior rectal wall (black arrow) contrasting a large anterior wall hypoattenuated ulcer (white arrow). Note prominent presacral edema (white asterisk). A small right pleural effusion is not shown.

outbreak, in the genital area, often with mucosal lesions. The lesions are often papular, pustulovesicular, or ulcerated, and often umbilicate. Pharyngitis and proctitis have also been reported as presenting symptoms.⁴ The incidence of proctitis and/or proctalgia in patients with monkeypox in different series have ranged from 22% to 37%.^{5–7} Additional relatively common clinical manifestations include peri-anal and penile ulcerative lesions.^{1,8}

This case highlights that monkeypox can present clinically with severe proctitis and has distinctive imaging findings on CT scan not typically seen in other causes of proctitis. Severe circumferential anorectal mural thickening with broad discrete non-enhancing hypoattenuated zones due to intramural ulcers on CT scan in young men with associated rash and sexual history should invoke consideration for monkeypox infection, and can be suggested by the radiologist. Additional findings of severe anorectal proctitis were also seen in this patient, including perirectal fat infiltration, presacral edema, ascites, and an increased number of small inguinal lymph nodes. The imaging differential diagnosis includes other causes of infectious proctitis, namely gonorrhea, syphilis, HSV, and CMV, as well as radiation-induced proctitis, ischemic proctitis, and neoplasm. Radiologic literature on this topic is scarce due to the recent onset of the monkeypox pandemic. Reported MRI descriptions

include rectal wall thickening, rectal wall perforation, enlarged mesorectal space lymph nodes, and inflammatory change of the lower anal canal mucosa representing peri-anal ulcers.^{8,9} Reported CT descriptions include sigmoid, rectal, and anal wall thickening, infiltrated peri-rectal fat, and enlarged peri-rectal and iliac chain lymph nodes.^{7,10} Reported proctoscopic features include severe proctitis with or without anal or rectal ulcers.^{1,10,11} The primary presenting symptoms in this case were painful defecation and rectal pain, though symptoms of proctitis in the monkeypox population have also included rectal bleeding, fecal urgency, tenesmus, and abdominal pain.^{5,9} Imaging findings improved on follow up CT scan performed 11 days later after the patient was treated with Tecovirimat and antibiotics, given to treat potential secondary bacterial abscess.

CRediT authorship contribution statement

Zina Ricci- Conceptualization, Visualization, Writing- Original draft preparation, Writing- Reviewing and Editing. **Mark Messina**- Visualization, Writing- Original draft preparation, Writing- Reviewing and Editing. **Peter Alpert**- Writing- Reviewing and Editing. **Devaraju Kanmaniraja**- Writing- Reviewing and Editing. **Ellen Wolf**

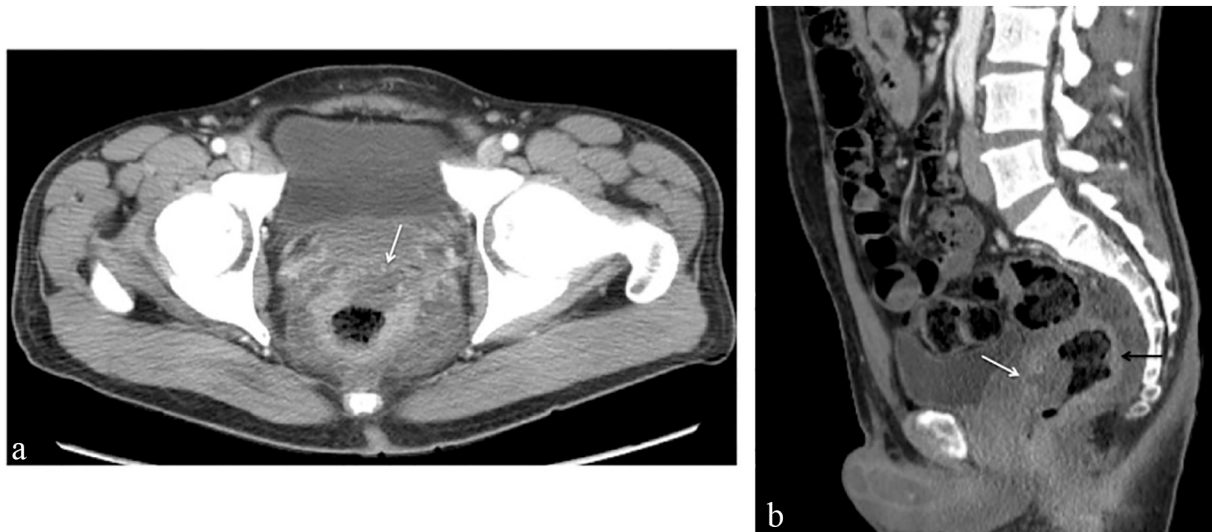

Fig. 2. Axial image from contrast-enhanced CT scan 11 days later (a) shows decrease in mural thickening and anterior hypoattenuated ulcer. Sagittal image (b) shows decrease in enhancing posterior rectal wall (black arrow) and large anterior wall hypoattenuated ulcer (white arrow) compared with prior exam. Pelvic ascites resolved (not shown).

Conceptualization, Writing- Reviewing and Editing.

Declaration of competing interest

The authors have no conflicts of interest to declare.

References

- Iabkriman A, Denis MA, Moreels T. Clinical image : an unusual cause of anal pain. *Gastroenterology* Aug 18 2022. <https://doi.org/10.1053/j.gastro.2022.08.032>.
- Center for Disease Control and Prevention, National Center for Emerging and Zoonotic Infectious Diseases, Division of High-Consequence Pathogens and Pathology. 2022 Monkeypox Outbreak Global Map. United States Department of Health and Human Services. Accessed 20 September 2022, <https://www.cdc.gov/poxvirus/monkeypox/response/2022/world-map.html>.
- Thornhill JP, Barkati S, Walmsley S, et al. Monkeypox virus infection in humans across 16 countries - april-june 2022. *N. Engl. J. Med.* 2022;387(8):679–91. <https://doi.org/10.1056/NEJMoa2207323>.
- World Health Organization. Surveillance, case investigation and contact tracing for monkeypox: interim guidance. WHO Health Emergencies Programme 25 August 2022:1–12. <https://www.who.int/publications/i/item/WHO-MPX-Surveillance-2022.3>. [Accessed 20 September 2022].
- Tarin-Vicente EJ, Alemany A, Agud-Dios M, et al. Clinical presentation and virological assessment of confirmed human monkeypox virus cases in Spain: a prospective observational cohort study. *Lancet* 2022;400(10353):661–9. [https://doi.org/10.1016/S0140-6736\(22\)01436-2](https://doi.org/10.1016/S0140-6736(22)01436-2).
- Catala A, Clavo-Escribano P, Riera-Monroig J, et al. Monkeypox outbreak in Spain: clinical and epidemiological findings in a prospective cross-sectional study of 185 cases. *Br. J. Dermatol.* Aug 2 2022. <https://doi.org/10.1111/bjd.21790>.
- Yakubovsky M, Shasha D, Reich S, et al. Monkeypox presenting as proctitis in men who have sex with men. *Clin. Infect. Dis.* Sep 6 2022. <https://doi.org/10.1093/cid/ciac737>.
- Gedela K, Da Silva Fontoura D, Salam A. Infectious proctitis due to human monkeypox. *Clin. Infect. Dis* Sept 2 2022. <https://doi.org/10.1093/cid/ciac713>.
- Patel A, Bilinska J, Tam JCH, et al. Clinical features and novel presentations of human monkeypox in a Central London Centre during the 2022 outbreak: descriptive case series. *BMJ* Jul 28 2022;378:e072410. <https://doi.org/10.1136/bmj-2022-072410>.
- Pfafflin F, Wendisch D, Scherer R, et al. Monkeypox in-patients with severe anal pain. *Infection* Aug 12 2022. <https://doi.org/10.1007/s15010-022-01896-7>.
- Lucar J, Roberts A, Saardi KM, Yee R, Siegel MO, Palmore TN. Monkeypox virus-associated severe proctitis treated with oral tecovirimat: a report of two cases. *Ann. Intern. Med.* Aug 18 2022. <https://doi.org/10.7326/L22-0300>.