

Received: 2010.08.04
Accepted: 2011.01.13
Published: 2011.08.01

Authors' Contribution:

- A** Study Design
- B** Data Collection
- C** Statistical Analysis
- D** Data Interpretation
- E** Manuscript Preparation
- F** Literature Search
- G** Funds Collection

RCAS1 expression in mobile tongue squamous cell carcinoma: An immunohistochemical study

Stamatios Theocharis^{1,2ADEF}, Jerzy Klijanienko^{1B},
Constantinos Giaginis^{2GDEI}, Jose Rodriguez^{1B}, Thomas Jouffroy^{1B},
Angelique Girod^{1B}, Gerasimos Tsourouflis^{2FG}, Xavier Sastre-Garau^{1A}

¹ Department of Pathology, Head and Neck Surgery, Institute Curie, Paris, France

² Department of Forensic Medicine and Toxicology, Medical School, University of Athens, Athens, Greece

Source of support: Departmental sources

Summary

Background:

The receptor-binding cancer antigen expressed on SiSo cells (RCAS1) is a human tumor-associated antigen that has been considered to play a crucial role in tumor progression by enabling cancer cells to evade immune surveillance. The present study aimed to evaluate the clinical significance of RCAS1 expression in mobile tongue squamous cell carcinoma (SCC).

Material/Methods:

RCAS1 protein expression was assessed immunohistochemically on 49 mobile tongue SCC tissue samples obtained from an equal number of patients and was statistically analyzed with clinicopathological characteristics and overall and disease-free patients' survival.

Results:

Enhanced RCAS1 expression was significantly associated with reduced depth of invasion ($p=0.0069$), low mitotic index ($p=0.0251$) and no evidence of muscular invasion ($p=0.0098$). A borderline association between RCAS1 expression and stromal inflammatory reaction was also noted ($p=0.0660$). RCAS1 expression was not associated with overall and disease-free survival.

Conclusions:

Our data support evidence for possible implication of RCAS1 at the early stage of tumor progression in mobile tongue SCC, whereas the survival prediction using RCAS1 expression as a clinical marker seems uncertain for this type of malignancy.

key words:

RCAS1 • mobile tongue squamous cell carcinoma • immunohistochemistry • clinicopathological parameters

Full-text PDF:

<http://www.medscimonit.com/fulltxt.php?ICID=881902>

Word count:

2742

Tables:

3

Figures:

2

References:

39

Author's address:

Stamatios Theocharis, Department of Forensic Medicine and Toxicology, Medical School, University of Athens, 75 M, Asias str., Goudi, Athens, Greece, GR11527, e-mail: theocharis@ath.forthnet.gr

BACKGROUND

Receptor-binding cancer antigen expressed on SiSo cells (RCAS1) was initially recognized by the mouse monoclonal antibody, 22-1-1, which was raised by immunization of mice with the human uterine cervical adenocarcinoma cell line SiSo [1]. It is a 40-kd type II membrane protein that forms homooligomers through its C-terminal coiled-coil structures, but it also exists in soluble form, probably by alternative splicing [2]. RCAS1 has recently been considered as a novel tumor-associated antigen that induces cell-cycle arrest and/or apoptosis in RCAS1 receptor-bearing human cells [3]. Substantial evidence supports that RCAS1 can function as ligand for a putative receptor present on various human cell lines, such as erythroid leukaemia and normal peripheral lymphocytes, inhibiting cell growth and inducing apoptosis [4]. Thus, RCAS1 up-regulation is considered to play a crucial role in tumor progression by enabling cancer cells to evade immune surveillance [5,6].

Mobile tongue Squamous Cell Carcinoma (SCC) is an aggressive malignancy with increasing incidence in Western communities, and is frequently associated with poor prognosis [7,8]. Although new advanced therapeutic strategies have been applied to date, the 5-year survival rates have not been considerably improved due to the increased rate of lymph node metastasis [9–11]. The detection of occult metastasis remains difficult, thus the establishment and validation of prognostic markers in primary tumor specimens has been a high priority [12,13]. Substantial evidence has suggested that clinicopathological parameters in mobile tongue SCC provide crucial clinical information regarding disease prognosis and further adjuvant therapeutic approaches [14,15]. Tongue carcinoma has been shown to present high local failure and poor survival rates compared to other anatomic sites of the oral cavity [10]. This difference is less related with the inherent tumor biology and is mostly ascribed to anatomic factors, such as tumor proximity to bone, density of regional lymphatics and tumor accessibility to inspection and hence earlier detection [16].

In the last few years, RCAS1 protein expression has been described in a variety of human malignancies, including breast, lung, neurological, pancreatic, gastrointestinal, colorectal, urothelial, endometrial, cervical and ovarian carcinoma [17]. Notably, RCAS1 expression has been shown to be associated with important clinicopathological parameters for patient management and prognosis, being considered as an informative biomarker in several types of the above malignancies [17]. RCAS1 has also been reported to be expressed in several types of head and neck neoplasia, including oral and esophageal SCC and thyroid carcinoma [18–25]. However, to our knowledge, there are no available studies so far evaluating RCAS1 expression in human mobile tongue SCC. In view of above considerations, the present study aimed to immunohistochemically assess RCAS1 expression in 49 mobile tongue SCC specimens. We also aimed to evaluate the association of RCAS1 expression with clinicopathological parameters, mitotic index and overall and disease-free patient survival.

MATERIAL AND METHODS

Patients

Medical records and archival histopathological material of 49 mobile tongue SCC patients who were initially treated

at the Department of Otorhinolaryngology-Head and Neck Surgery of Institut Curie, Paris, France, within the period 2000 to 2009 were included in this study. All patients underwent initial partial glossectomy as primary treatment, and 39 patients had elective neck dissections. The surgical specimens were examined at the Department of Pathology of the Institut Curie, according to standard histopathological protocols. Patients with prior radiotherapy, chemotherapy or surgery for malignancy were not included in the study.

Of the total 49 patients that were included in the study, 26 were male and 23 female, with male to female ratio 1.13. Patient age at first diagnosis ranged between 33 and 94 years (median age 60 years, IQR: 53–72 years). Clinical and histopathological parameters, including grade of histopathological differentiation, tumor thickness, tumor shape (well defined *vs.* ill defined), nodal status, perineural invasion, and the presence of lymphovascular emboli were assessed [26]. For the histopathological tumor grade of differentiation, the 3-level grading of WHO classification was applied: well, moderate and poorly differentiated, according to a subjective assessment of keratinization, cellular and nuclear pleomorphism and mitotic activity [27]. Tumor thickness was measured from the surface of the tumor to the deepest point of invasion [14,28]. Chronic inflammatory infiltration was identified as small mononuclear cells in the stroma of the entire tumor. The degree of infiltration was classified as mild, moderate and intense according to the density of inflammatory cells [26]. The patients were followed-up for a time interval between 2 and 116 months (median 40 months, IQR: 13–66 months). Overall survival was defined as the time interval between the date of surgery and the date of death due to mobile tongue SCC. Disease-free survival was defined as the time interval between the date of surgery and the date of detection of recurrence or the date of last follow-up without recurrence for mobile tongue SCC. At the time of the last follow-up, 14 (28.57%) patients had died from disease, 4 (8.16%) were alive with disease and 31 (63.27%) were alive and disease-free.

Immunohistochemistry

RCAS1 immunostaining was performed on formalin-fixed, paraffin-embedded mobile tongue tissue sections using a mouse monoclonal anti-RCAS1 antibody that reacts with RCAS1 protein (MBL International Co, Nagoya, Japan). Briefly, 4 μ m-thick tissue sections were dewaxed in xylene and were brought to water through graded alcohols. Antigen retrieval was performed by microwaving slides in 10 mM citrate buffer (pH 6.1) for 20 minutes (min) at high power, according to the manufacturer's instructions. To remove the endogenous peroxidase activity, sections were treated with freshly prepared 0.3% hydrogen peroxide in methanol in the dark, for 30 min, at room temperature. Non-specific antibody binding was blocked using Sniper, a specific blocking reagent for mouse primary antibodies (Sniper, Biocare Medical, Walnut Creek, CA, USA) for 5 min. The sections were incubated for 1 hour (h) at room temperature, with the primary antibody against RCAS1, diluted 1:750 in phosphate buffered saline (PBS). After washing 3 times with PBS, sections were incubated at room temperature with biotinylated linking reagent (Biocare Medical) for 10 min, followed by incubation with peroxidase-conjugated streptavidin label (Biocare Medical) for 10 min. The resultant immune peroxidase activity was developed using a DAB substrate kit (Vector Laboratories, USA) for 10 min. Sections

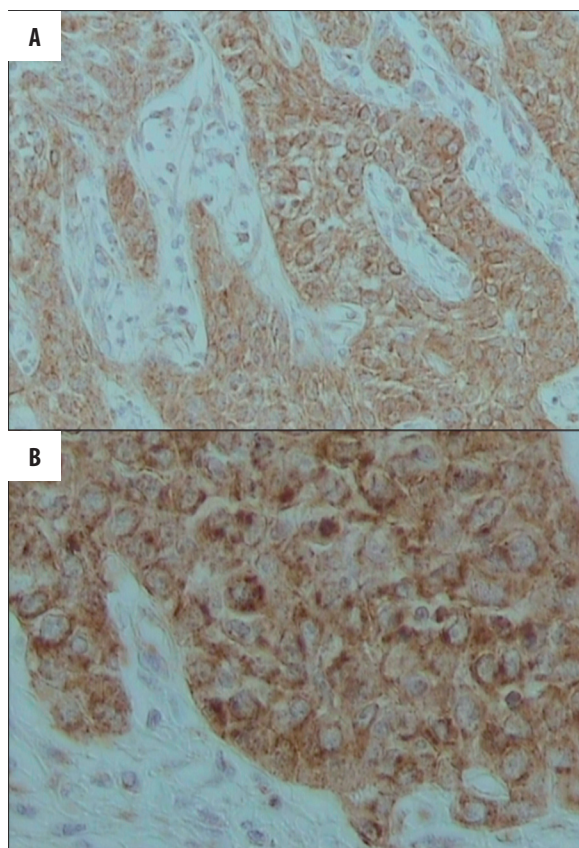


Figure 1. Representative immunostainings for cytoplasmic and membranous RCAS1 expression in tumor cells of mobile tongue SCC. Streptavidin-biotin-peroxidase, DAB chromogen, Harris hematoxylin counterstain. (A) Original magnification $\times 200$ and (B). Original magnification $\times 400$.

were counterstained with Harris' hematoxylin and mounted in Entellan (Merck, Darmstadt, Germany). Appropriate negative controls were performed by omitting the primary antibody and/or substituting it with an irrelevant anti-serum. Pancreatic cancer tissue sections with known increased RCAS1 immunoreactivity were used as positive control [29].

Evaluation of immunohistochemistry

Stained sections were independently assessed by observers S.T. and J.K., blinded to the clinical data, with complete observers' agreement. Specimens were considered "positive" for RCAS1 when more than 5% of tumor cells within the section were positively stained [29,30]. The extent of RCAS1 expression was calculated by the percentage of the positive cells in the total number of tumor cells within each specimen. The specimens were characterized as presenting "high expression" for RCAS1 when the percentage of the positively stained tumor cells exceeded the mean percentage value [29,30]. In RCAS1-positive cases, the intensity of immunostaining was also estimated and graded in a 3-step scale as mild (+), moderate (++) and intense (+++) [29,30].

Statistical analysis

Chi-square test was used to assess the associations of RCAS1 expression with clinicopathological variables. Survival curves

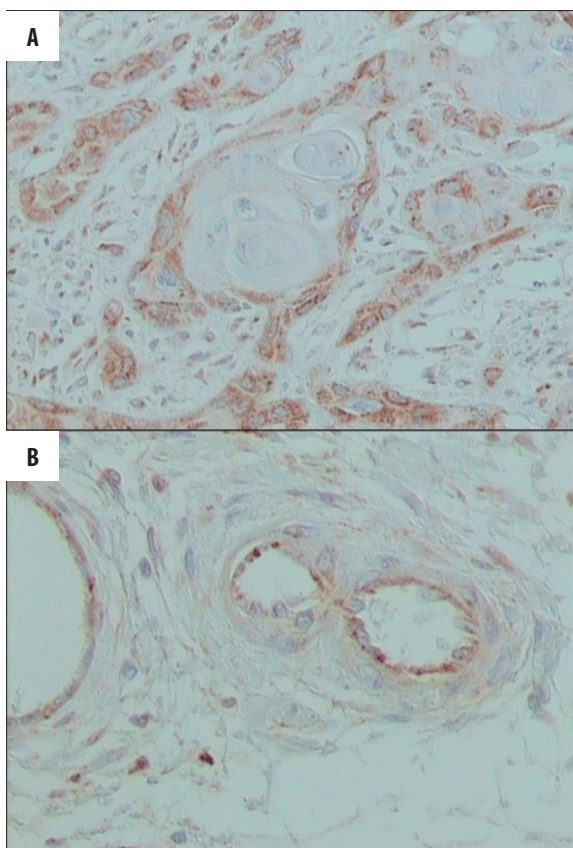


Figure 2. RCAS1 expression in (A) peripheral cell layers around keratin pearl (original magnification $\times 200$) and (B) endothelial cells in the vicinity of tumor nests (original magnification $\times 400$). Streptavidin-biotin-peroxidase, DAB chromogen, Harris hematoxylin counterstain.

were constructed using the Kaplan-Meier method and the differences between the curves were compared by the log rank test. A Cox proportional-hazard regression model was developed to evaluate the association between the potential prognostic marker and overall and disease-free survival. Cox regression analysis was conducted at both univariate and multivariate levels. A p-value less than 0.05 was considered the limit of statistical significance. SPSS for Windows software was used for all analyses (SPSS Inc., 2003, Chicago, USA).

RESULTS

RCAS1 positivity was noted in all of the mobile tongue SCC cases examined (49/49, 100%). The pattern of RCAS1 distribution was both cytoplasmic and membranous (Figure 1). RCAS1 immunoreactivity was more frequently detected in the peripheral cell layers around keratin pearl where the tumor cells were less differentiated, whereas the cell layers inside the keratin pearl where the tumor cells were more differentiated and keratinized did not show positive RCAS1 immunoreactivity (Figure 2A). Weak RCAS1 immunoreactivity was also occasionally detected in endothelial cells in the vicinity of tumor nests (Figure 2B). Tongue epithelium with normal appearance adjacent to tumor was found negative for RCAS1.

High RCAS1 expression was noted in 27 (55.10%) out of 49 mobile tongue SCC cases. The intensity of RCAS1

immunostaining was classified as mild in 6 (12%), moderate in 37 (76%) and intense in 6 (12%) out of 49 mobile tongue SCC cases. High RCAS1 expression was significantly more frequently observed in mobile tongue SCC cases presenting no evidence of muscular invasion (Table 1, $p=0.0098$). Mobile tongue SCC cases presenting reduced depth of invasion showed significantly increased incidence of high RCAS1 expression (Table 1, $p=0.0069$). Mobile tongue SCC cases presenting reduced mitotic index also showed significantly increased incidence of high RCAS1 expression (Table 1, $p=0.0251$). A positive borderline association between RCAS1 expression and stromal inflammatory reaction was noted (Table 1, $p=0.0660$). SCC cases presenting no evidence of vascular and perineural invasion, as well as absence of lymph node metastases, showed increased incidence of high RCAS1 expression without reaching statistical significance (Table 1, $p>0.05$). RCAS1 expression did not show statistically significant associations or trends of correlation with patients' age and sex, histopathological grade of differentiation and tumor shape (Table 1, $p>0.05$). RCAS1 staining intensity was not associated with any clinicopathological parameters examined (data not shown).

Univariate analysis was performed to assess the strength of the association of each clinicopathological parameter and RCAS1 expression (low vs. high) with overall and disease-free survival. Patients' sex and depth of invasion were identified as significant prognostic factors of overall survival (Table 2, $p=0.0135$ and $p=0.0438$, respectively). Patients' sex and histopathological grade were identified as significant prognostic factors of disease-free survival (Table 2, $p=0.0090$ and $p=0.0388$, respectively). RCAS1 expression was not associated with overall and disease-free survival (Table 2, $p=0.9077$ and $p=0.7042$, respectively). In multivariate analysis, patients' sex was identified as independent prognostic factor of overall survival (Table 3, $p=0.0167$). Patients' sex and grade of differentiation proved to be independent prognostic factors of disease-free survival (Table 3, $p=0.0070$ and $p=0.0165$, respectively).

DISCUSSION

It is well-established that RCAS1 is overexpressed in various tumors and that it may thus affect many aspects of cancer biology, such as differentiation, proliferation, invasion and angiogenesis [6,17]. Elevated RCAS1 expression has been associated with the malignant state of several tissue types and may play a crucial role in tumor progression by enabling cancer cells to evade immune surveillance [6,17]. However, few studies have assessed the clinical significance of RCAS1 expression in head and neck neoplasia remains, as the available studies have been restricted to oral and esophageal SCC and thyroid carcinoma [18–25]. It should be taken into account that head and neck malignancies arise in various sites, such as the oral cavity and the oropharynx. Thus, tumors from these different anatomic sites have distinct clinical presentations and outcomes and are associated with different risk factors and genetic characteristics, which may complicate the evaluation of potential prognostic markers [31,32].

In view of the above considerations, the present study aimed to focus on 1 anatomic site, assessing for the first time the clinical significance of RCAS1 expression in mobile tongue SCC. In fact, we found that all the examined mobile tongue

SCC cases were RCAS1-positive. This incidence of RCAS1 positivity is among the highest reported incidences for all types of head and neck malignancies, including oral and esophageal SCC [18–25]. A similar incidence of RCAS1 positivity was reported in laryngeal and pharyngeal SCC, in which RCAS1 protein was detected in all the examined tissue samples [33]. To this respect, current substantial evidence supports that RCAS1 may be considered as a promising target for future (gene) therapeutic approaches [6,17]. The increased frequency of RCAS1 positivity in mobile tongue SCC reinforces the therapeutic utility of this receptor in tongue cancer chemoprevention and treatment. In this aspect, the recent evidence that RCAS1 siRNA suppressed RCAS1 mRNA and protein expression and delayed tumor growth, *in vivo*, has already opened-up new perspectives for the development of future inhibitors to target RCAS1 receptor [34]. Anti-estrogens may also employ RCAS1 as a molecular switch to activate immune cytotoxicity against tumor cells [35].

The present study further showed that RCAS1 expression was associated with clinicopathological characteristics, which are considered crucial for patient management. More to the point, high RCAS1 expression was significantly more frequently observed in mobile tongue SCC cases presenting no evidence of muscular invasion and reduced depth of invasion. Mobile tongue SCC cases presenting low mitotic index also showed significantly increased incidence of high RCAS1 expression. These findings further support evidence implicating RCAS1 at the early stage of tumor progression in mobile tongue SCC. We also found a borderline positive association between RCAS1 expression and stromal inflammatory reaction. In this context, RCAS1 was reported to facilitate tumor cell invasion of connective tissue via enhancement of invasive potency by induction of stromal tissue remodeling [5]. Recent studies have also documented that RCAS1 expression is significantly associated with tumor histopathological stage, tumor size or lymph node positivity in oral and esophageal SCC [18,20,21,24,25]. Moreover, in laryngeal and pharyngeal SCC, RCAS1 expression was significantly greater in the cancerous areas than in the clear surgical margins, and was associated with tumor histopathological grade and presence of lymph node metastases [33]. Most of the above studies also showed that RCAS1 expression was associated with patients' survival, which was not seen in the case of mobile tongue SCC of the present study. This discrepancy may be ascribed to the fact that the different anatomic sites of the oral cavity generally have distinct clinical presentations and outcomes and are associated with different risk factors and genetic characteristics [31,32].

Substantial evidence further suggests that up-regulation of RCAS1 expression may play a crucial role in tumor progression by enabling cancer cells to evade immune surveillance [3,36]. More to the point, RCAS1 receptor expression was enhanced by activation of lymphocytes, and secreted RCAS1 in turn inhibited the *in vitro* growth of such activated cells, inducing their apoptotic cell death. Thus, tumor cells may evade immune surveillance by expressing RCAS1. In this context, Nakashima et al demonstrated that RCAS1 induced apoptosis in both cultured human lymphoma cell lines and normal peripheral lymphocytes, which express RCAS1 receptor [3]. This apoptotic effect was shown to be mediated through induction of genes or caspase molecules, which strongly abrogated RCAS1-induced apoptosis, *in vitro* [3].

Table 1. Associations of RCAS1 expression with clinicopathological parameters in 49 mobile tongue squamous cell carcinoma patients.

Clinicopathological characteristics	RCAS1 expression		p-value
	Low (%)	High (%)	
N=49	22 (45)	27 (55)	
Age (mean \pmSD; yrs)			0.8012
$\leq 62.23 \pm 14.89$ yrs	13 (27)	15 (31)	
$> 62.23 \pm 14.89$ yrs	9 (18)	12 (24)	
Gender			0.6983
Male	11 (22)	15 (31)	
Female	11 (22)	12 (24)	
Histopathological grade			0.6826
I	16 (33)	21 (43)	
II	6 (12)	6 (12)	
Stromal inflammatory reaction			0.0660
Mild	4 (8)	0 (0.00)	
Moderate	4 (8)	5 (10)	
Dense	14 (29)	22 (45)	
Muscular invasion			0.0098
Yes	22 (45)	20 (41)	
No	0 (0)	7 (14)	
Shape			0.5862
Diffuse	17 (35)	19 (39)	
Well defined	5 (10)	8 (16)	
Vascular invasion			0.4768
Yes	5 (10)	4 (8)	
No	17 (35)	23 (47)	
Perineural invasion			0.3864
Yes	10 (20)	9 (18)	
No	12 (25)	18 (37)	
Depth of invasion			0.0069
I	1 (2)	12 (25)	
II	12 (25)	8 (16)	
III	9 (18)	7 (14)	
Lymph node metastases			0.6170
Yes	8 (16)	8 (16)	
No	14 (29)	19 (39)	
Mitotic index			0.0251
\leq Median value	6 (12)	16 (33)	
$>$ Median value	16 (33)	11 (23)	

Table 2. Association of clinicopathological parameters and RCAS1 expression with patients' survival: Univariate analysis.

Clinicopathological variables	Overall survival		Disease free survival	
	HR (95% CI)	p-value	HR (95% CI)	p-value
Age (<60/≥60 yrs)	2.11 (0.70–6.41)	0.1837	1.67 (0.63–4.46)	0.3004
Gender (Male/Female)	5.04 (1.39–18.23)	0.0135	4.49 (1.45–13.88)	0.0090
Histopathological grade (I/II)	0.44 (0.14–1.39)	0.1634	0.34 (0.12–0.94)	0.0388
Stromal inflammatory reaction (Mild+Moderate/Dense)	2.35 (0.82–6.74)	0.1106	2.12 (0.81–5.52)	0.1221
Muscular invasion (Yes/No)	1.76 (0.22–13.76)	0.5860	0.96 (0.21–4.34)	0.9642
Shape (III/Well defined)	5.05 (0.66–38.69)	0.1188	6.21 (0.82–46.95)	0.0763
Vascular invasion (Yes/No)	1.69 (0.52–5.44)	0.3752	1.36 (0.44–4.23)	0.5864
Perineural invasion (Yes/No)	0.78 (0.27–2.25)	0.6481	0.56 (0.20–1.53)	0.2613
Depth of invasion (I+II/III)	0.33 (0.11–0.97)	0.0438	0.49 (0.18–1.27)	0.1451
Lymph node metastases (Yes/No)	1.42 (0.49–4.11)	0.5129	1.35 (0.51–3.56)	0.5390
Mitotic index (Low/High)	1.06 (0.37–3.06)	0.9013	1.20 (0.46–3.14)	0.7024
RCAS1 expression (Low/High)	1.06 (0.32–2.95)	0.9077	1.20 (0.47–3.20)	0.7042

Table 3. Multivariate analysis for patients' gender, depth of invasion and histopathological grade of differentiation.

Clinicopathological variables	Overall survival		Disease free survival	
	HR (95% CI)	p-value	HR (95% CI)	p-value
Gender (Male/Female)	0.20 (0.10–0.97)	0.0167	0.20 (0.12–0.98)	0.0070
Histopathological grade (I/II)	2.88 (1.08–6.88)	0.0885	3.77 (1.30–7.45)	0.0165
Depth of invasion (I+II/III)	2.31 (0.98–5.02)	0.1241	0.95 (0.31–2.86)	0.3281

RCAS1 was also shown to facilitate tumor cell invasion of connective tissue in uterine cervical cancer via enhancement of invasive potency by induction of stromal tissue remodeling, as well as through evasion of antitumor immune surveillance by an apoptotic counter-attack mechanism against lymphocytes [5]. Moreover, RCAS1 was shown to be secreted through ectodomain shedding, and its expression was related to alterations of extracellular matrix characteristics and to a reduced number of vimentin-positive tumor stromal cells, supporting evidence that RCAS1 may induce connective tissue remodeling [6,37]. RCAS1 may also modulate surface expression of tumor-associated O-linked glycan structures, which are thought to participate in cell adhesion, invasion, and metastasis of cancer cells [38]. Taking into account the above considerations, further studies should be conducted to evaluate the relationship between RCAS1 expression and the frequency of tumor-infiltrating lymphocytes (TILs) apoptosis in mobile tongue SCC in order to determine whether RCAS1-positive tumor cells may induce apoptosis to their surrounding TILs. As RCAS1 is easily detectable in biofluids [39], further research efforts should focus on the determination of RCAS1 levels in serum or saliva during and after the treatment of mobile tongue SCC patients, with the aim of recognizing patients' recurrence.

CONCLUSIONS

We demonstrated for the first time that RCAS1 was expressed in human mobile tongue SCC, and that it is correlated with clinicopathological characteristics crucial for patient management. Enhanced RCAS1 expression was associated with reduced depth of invasion, low mitotic index and no evidence of muscular invasion, supporting evidence for possible implication of RCAS1 at the early stage of tumor progression in mobile tongue SCC. On the other hand, the survival prediction using RCAS1 expression as a clinical marker seems uncertain for this type of cancer, and needs to be assessed by larger cohort studies to allow precise conclusions to be drawn. Further studies are required in order to assess whether RCAS1 may be considered as a useful biomarker in mobile tongue SCC, as well as evaluating its therapeutic utility in tongue cancer chemoprevention and treatment.

Acknowledgment

We thank Mr. Vassileios Stolakis for his excellent technical assistance.

REFERENCES:

- Sonoda K, Nakashima M, Kaku T et al: A novel tumor-associated antigen expressed in human uterine and ovarian carcinomas. *Cancer*, 1996; 77: 1501-9
- Yamaguchi K, Enjoji M, Nakashima M et al: Novel serum tumor marker, RCAS1, in pancreatic diseases. *World J Gastroenterol*, 2005; 11: 5199-202
- Nakashima M, Sonoda K, Watanabe T: Inhibition of cell growth and induction of apoptotic cell death by the human tumor-associated antigen RCAS1. *Nat Med*, 1999; 5: 938-42
- Matsushima T, Nakashima M, Oshima K et al: Receptor binding cancer antigen expressed on SiSo cells, a novel regulator of apoptosis of erythroid progenitor cells. *Blood*, 2001; 98: 313-21
- Sonoda K, Miyamoto S, Hirakawa T et al: Association between RCAS1 expression and microenvironmental immune cell death in uterine cervical cancer. *Gynecol Oncol*, 2005; 97: 772-79
- Sonoda K, Miyamoto S, Nakashima M, Wake N: The biological role of the unique molecule RCAS1: a bioactive marker that induces connective tissue remodeling and lymphocyte apoptosis. *Front Biosci*, 2008; 13: 1106
- Canto MT, Devesa SS: Oral cavity and pharynx cancer incidence in the United States, 1975-1988. *Oral Oncol*, 2002; 38: 610-17
- Jemal A, Siegel R, Ward E et al: Cancer statistics. *CA Cancer J Clin*, 2007; 57: 43-66
- Brenner H: Long-term survival rates of cancer patients achieved by the end of the 20th century: a period analysis. *Lancet*, 2002; 360: 1131-35
- Shiboski CH, Schmidt BL, Jordan RC: Tongue and tonsil carcinoma: increasing trends in the U.S. population ages 20-44 years. *Cancer*, 2005; 103: 1843-49
- Sano D, Myers JN: Metastasis of squamous cell carcinoma of the oral tongue. *Cancer Metastasis Rev*, 2007; 26: 645-62
- Kantola S, Parikka M, Jokinen K et al: Prognostic factors in tongue cancer-relative importance of demographic, clinical and histopathological factors. *Br J Cancer*, 2000; 83: 614-19
- Wangsa D, Ryott M, Avall-Lundquist E et al: Ki-67 expression predicts locoregional recurrence in stage I oral tongue carcinoma. *Br J Cancer*, 2008; 99: 1121-28
- Po Wing Yen A, Lam KY, Lam LK et al: Prognostic factors clinically stage I and II oral tongue carcinoma: a comparative study of stage, thickness, shape, growth pattern, invasive front malignancy grading, Martinez-Gimeno score and pathologic features. *Head Neck*, 2002; 24: 513-20
- Patel R, Clark JR, Dirven R et al: Prognostic factors in the surgical treatment of patients with oral carcinoma. *ANZ J Surg*, 2009; 79: 19-22
- Bell RB, Kademani D, Homer L et al: Tongue cancer: is there a difference in survival compared with other subsites in the oral cavity. *J Oral Maxillofac Surg*, 2007; 65: 229-36
- Giaginis C, Giagini A, Theocharis S: Receptor-binding Cancer Antigen expressed on SiSo cells (RCAS1): a novel biomarker in the diagnosis and prognosis of human neoplasia. *Histol Histopathol*, 2009; 24: 761-76
- Fukuda M, Tanaka A, Hamao A et al: Expression of RCAS1 and its function in human squamous cell carcinoma of the oral cavity. *Oncol Rep*, 2004; 12: 259-67
- Toyoshima T, Nakamura S, Kumamaru W et al: Expression of tumor-associated antigen RCAS1 and its possible involvement in immune evasion in oral squamous cell carcinoma. *J Oral Pathol Med*, 2006; 35: 361-68
- Tsai TC, Yu CH, Cheng SJ et al: Expression of RCAS1 is significantly associated with the progression and prognosis of oral squamous cell carcinomas in Taiwan. *Oral Oncol*, 2008; 44: 759-66
- Nakakubo Y, Hida Y, Miyamoto M et al: The prognostic significance of RCAS1 expression in squamous cell carcinoma of the oesophagus. *Cancer Lett*, 2002; 177: 101-5
- Ikeguchi M, Ohoro S, Maeda Y et al: Protein and gene expression of tumor-associated antigen RCAS1 in esophageal squamous cell carcinoma. *Oncol Rep*, 2003; 10: 1891-94
- Ito Y, Yoshida H, Nakano K et al: Overexpression of human tumor-associated antigen, RCAS1, is significantly linked to dedifferentiation of thyroid carcinoma. *Oncology*, 2003; 64: 83-89
- Kato H, Nakajima M, Masuda N et al: Expression of RCAS1 in esophageal squamous cell carcinoma is associated with a poor prognosis. *J Surg Oncol*, 2005; 90: 89-94
- Tsujitani S, Saito H, Oka S et al: Prognostic significance of RCAS1 expression in relation to the infiltration of dendritic cells and lymphocytes in patients with esophageal carcinoma. *Dig Dis Sci*, 2007; 52: 549-54
- Brandwein-Gensler M, Teixeira MS, Lewis CM et al: Oral squamous cell carcinoma: histological risk assessment, but not margin status, is strongly predictive of local disease-free and overall survival. *Am J Surg Pathol*, 2005; 29: 167-78
- Barnes L, Eveson JW, Reichert P, Sidransky D: World Health Organization classifications tumours. Pathology and genetics of head and neck tumours. Lyon, IARC Press, 2005
- Po Wing Yen A, Lam K et al: A comparison of prognostic significance of tumor diameter, length, width, thickness area, volume and clinicopathological features of oral tongue carcinoma. *Am J Surg*, 2000; 180: 139-43
- Giaginis C, Davides D, Zarros A et al: Clinical significance of tumor-associated antigen RCAS1 expression in human pancreatic ductal adenocarcinoma. *Dig Dis Sci*, 2008; 53: 1728-34
- Giaginis C, Vgenopoulou S, Tsourouflis G et al: Expression and clinical significance of focal adhesion kinase (FAK) in the two distinct histological types, intestinal and diffuse, of human gastric adenocarcinoma. *Path Oncol Res*, 2009; 15: 173-81
- Döbrossy L: Epidemiology of head and neck cancer: magnitude of the problem. *Cancer Metastasis Rev*, 2005; 24: 9-17
- Tímár J, Csuka O, Remenár E et al: Progression of head and neck squamous cell cancer. *Cancer Metastasis Rev*, 2005; 24: 107-27
- Dutsch-Wicherek M, Tomaszewska R, Lazar A et al: The association between RCAS1 expression in laryngeal and pharyngeal cancer and its healthy stroma with cancer relapse. *BMC Cancer*, 2009; 9: 35
- Han Y, Qin W, Huang G: Knockdown of RCAS1 expression by RNA interference recovers T cell growth and proliferation. *Cancer Lett*, 2007; 257: 182-90
- Kino T, Chrousos GP: Tumor-associated, estrogen receptor-related antigen EBAG9: linking intracellular vesicle trafficking, immune homeostasis, and malignancy. *Mol Interv*, 2009; 9: 294-98
- Akashi T, Oimomi H, Nishiyama K et al: Expression and diagnostic evaluation of the human tumor-associated antigen RCAS1 in pancreatic cancer. *Pancreas*, 2003; 26: 49-55
- Sonoda K, Miyamoto S, Nakashima M, Wake N: Receptor-binding cancer antigen expressed on SiSo cells induces apoptosis via ectodomain shedding. *Exp Cell Res*, 2010; 316: 1795-803
- Engelsberg A, Hermosilla R, Karsten U et al: The Golgi protein RCAS1 controls cell surface expression of tumor-associated O-linked glycan antigens. *J Biol Chem*, 2003; 278: 22998-3007
- Giaginis C, Margeli A, Kouraklis G et al: Diagnostic and prognostic utility of serum Receptor-binding Cancer Antigen expressed on SiSo cells (RCAS1) levels in colon cancer patients. *Int J Biol Markers*, 2009; 24: 70-76