

Post-Transfusion Hemophagocytosis Without Hemophagocytic Lymphohistiocytosis

Eric McGinnis, MD; Nadia Medvedev, MD; Mikhyla J. Richards, MD; Luke Y.C. Chen, MD; and Michelle P. Wong, MD

Abstract

Hemophagocytosis refers to ingestion of hematopoietic elements or mature blood cells by another cell, typically by cells conventionally associated with phagocytic capacity. Although the finding of hemophagocytosis as a prominent feature in a patient's bone marrow might prompt consideration of a hemophagocytic syndrome (HPS) such as hemophagocytic lymphohistiocytosis (HLH) in a clinician's or pathologist's differential diagnosis, this morphologic feature can be nonspecific in the absence of other clinical and laboratory features of pathologic immune activation, which is the sine qua non of HPS/HLH. We describe three patients whose clinical presentations included transfusion-dependent anemia and whose bone marrow aspirates showed unexpectedly brisk hemophagocytosis of mature red blood cells. Despite striking morphologic hemophagocytosis, no patient met criteria for diagnosis of an HPS. Transfusion-associated hemophagocytosis and hyperferritinemia must be carefully distinguished from HLH through clinical and laboratory assessment. Biomarkers of pathologic immune activation are important diagnostic aids.

© 2019 THE AUTHORS. Published by Elsevier Inc on behalf of Mayo Foundation for Medical Education and Research. This is an open access article under the CC BY-NC-ND license (<http://creativecommons.org/licenses/by-nc-nd/4.0/>)

CASE 1

A 60-year-old woman was referred for evaluation of thrombocytopenia and progressive anemia requiring red blood cell (RBC) transfusion. Her history was remarkable for end-stage renal disease requiring hemodialysis and darbepoetin administration. At the time of consultation, her post-transfusion hemoglobin measured 84 g/L with macrocytosis (mean cell volume, 100 fL), thrombocytopenia (platelets $57 \times 10^9/L$), elevated lactate dehydrogenase of 456 U/L (upper limit of normal, 240 U/L), persistently low haptoglobin, negative direct antiglobulin test, and hyperferritinemia (Table, Case 1). She had no evidence of infection by HIV, Epstein-Barr virus (EBV), or cytomegalovirus (CMV). Autoimmune serology investigations were unremarkable.

The blood film was unremarkable aside from macrocytosis. Bone marrow aspiration and biopsy were performed to exclude an underlying bone marrow disorder and showed hyperplastic erythropoiesis and megakaryopoiesis as well as

features of dysplasia insufficient for diagnosis of myelodysplastic syndrome. Notable were numerous histiocytes showing florid hemophagocytosis of mature RBCs (Figure 1).

The patient was treated with a trial of prednisone 50 mg daily for 1 week for a presumed underlying immune etiology to her unexplained direct antiglobulin test-negative hemolytic anemia (a condition wherein case series have suggested a potential role for corticosteroid therapy) and thrombocytopenia.¹ In the absence of other features of hemophagocytic lymphohistiocytosis (HLH), the finding of prominent erythrophagocytosis was thought to most likely represent phagocytosis of donor cells transfused over the course of the preceding month. Her lactate dehydrogenase and haptoglobin levels normalized and her reticulocyte count decreased from $126 \times 10^9/L$ to her baseline of $54 \times 10^9/L$ with corticosteroid therapy, indicating resolution of her hemolysis, and her hemoglobin began to trend upward in the absence of transfusion. No further bone marrow examinations

From the Department of Pathology and Laboratory Medicine, University of British Columbia, Vancouver, Canada (E.M., N.M., M.P.W.); Vancouver General Hospital, Vancouver, British Columbia, Canada (N.M., L.Y.C.C.); Royal Columbian Hospital, New Westminster, Canada (M.J.R., M.P.W.); and the Division of Hematology, University of British Columbia, Vancouver, Canada (M.J.R., L.Y.C.C.).

TABLE. HLH-2004 Criteria Met and Corresponding HScore With Calculated Probability of the Presence of an HPS. Blood Counts Are Those Reported From the Time of Bone Marrow Examination With Identified Prominent Hemophagocytosis

HLH-2004 criteria met	Case 1	Case 2	Case 3
HLH-2004 criteria			
Fever	No	No	No
Splenomegaly	No	No	No
Cytopenias affecting ≥ 2 lineages:	No	No	Yes
Hemoglobin < 90 g/L	76 g/L	85 g/L	102 g/L
Platelets $< 100 \times 10^9/L$	$102 \times 10^9/L$	$449 \times 10^9/L$	$43 \times 10^9/L$
Neutrophils $< 1 \times 10^9/L$	$3.1 \times 10^9/L$	$12.7 \times 10^9/L$	$< 0.1 \times 10^9/L$
Hypertriglyceridemia and/or hypofibrinogenemia	No	No	No
Triglycerides ≥ 3 mmol/L	1.33 mmol/L	0.94 mmol/L	0.7 mmol/L
Fibrinogen ≤ 1.5 g/L	4.8 g/L	Not measured	5.9 g/L
Hemophagocytosis in bone marrow or lymph nodes	Yes	Yes	Yes
Ferritin ≥ 500 $\mu\text{g/L}$	Yes (1,310 $\mu\text{g/L}$)	No (161 $\mu\text{g/L}$)	Yes (1,970 $\mu\text{g/L}$)
sIL2R ^a ≥ 2400 U/mL	No (1,929 U/mL)	No (819 U/mL)	No (493 U/mL)
Low or absent NK ^a cell activity	Not measured	Not measured	Not measured
Number of criteria met:	2/8	1/8	3/8
Calculated HScore			
HScore	59	35	77
Probability of HPS ^a	0.119%	0.027%	0.363%

^aHLH = hemophagocytic lymphohistiocytosis; HPS = hemophagocytic syndrome; NK = natural killer; sIL2R = soluble interleukin-2 receptor.

were required, and she passed away 4 years after her treatment for hemolytic anemia from complications of her renal failure.

CASE 2

A 29-year-old woman with medical history remarkable for chylous ascites and lymphedema in association with cystic lymphangioma (previously reported by Al Zaki et al² in 2018) was referred for management of her anticoagulation after incidental discovery of pulmonary emboli. She had mild hyperferritinemia (Table, Case 2) and a normal complete blood

count aside from normocytic anemia, for which she had received several units of packed RBCs over the preceding 2 weeks, and mild thrombocytosis. HIV serology and molecular investigations for CMV and EBV were negative. Bone marrow aspiration and biopsy were performed to exclude underlying malignancy and showed no evidence of a neoplastic process involving the bone marrow. Hemophagocytosis, exclusively of mature RBCs, was a prominent feature (Figure 2).

Soluble interleukin-2 receptor (sIL2R) was subsequently measured and found to be

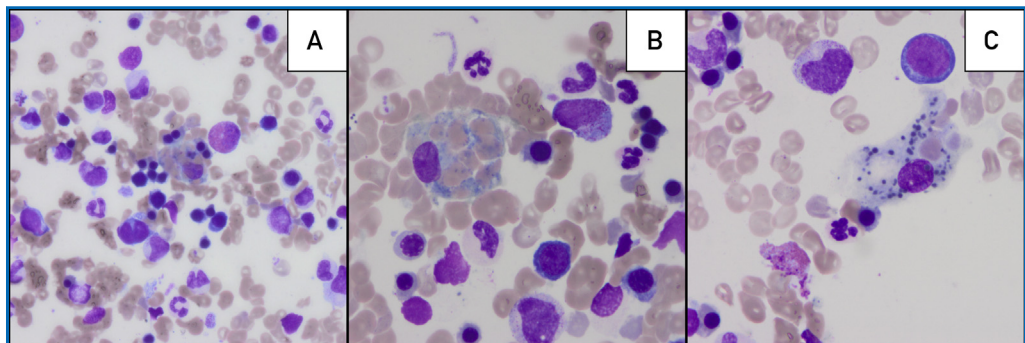


FIGURE 1. Bone marrow aspirate, May Grünwald-Giemsa stain. Prominent hemophagocytosis of mature red blood cells identified in case 1. Original magnification $\times 60$ (A) and $\times 100$ (B-C).

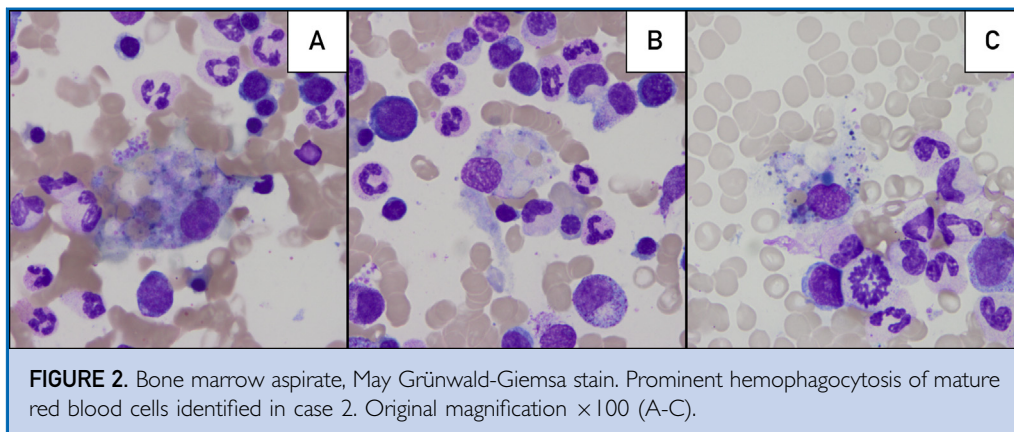


FIGURE 2. Bone marrow aspirate, May Grünwald-Giemsa stain. Prominent hemophagocytosis of mature red blood cells identified in case 2. Original magnification $\times 100$ (A-C).

819 U/mL, within institutional normal limits (241 to 846 U/mL). She was treated with prednisone and her ascites improved, allowing discharge home. The erythrophagocytosis identified in the bone marrow aspirate specimen, in the absence of identifiable underlying causes or further evidence of a syndrome of macrophage activation, was attributed to phagocytosis of transfused RBCs that she received over preceding weeks. She continues to be followed 4 years after her bone marrow biopsy with only mild ascites and no transfusion dependence.

CASE 3

A 70-year-old woman was referred for severe thrombocytopenia (platelets $13 \times 10^9/L$) and unexplained macrocytosis (mean cell volume, 107 fL) without anemia identified incidentally before partial mastectomy for ductal carcinoma in situ. A bone marrow aspirate and biopsy were performed and were unremarkable aside from markedly reduced megakaryopoiesis.

She was followed as an outpatient with thrombocytopenia responsive to platelet transfusions. A repeat bone marrow examination was performed 1 year later for progressive pancytopenia, which showed further reduction in her bone marrow cellularity without significant dysplasia. Cytogenetic studies revealed the presence of monosomy 7, leading to a working diagnosis of hypocellular myelodysplastic syndrome. Despite treatment with 5-azacitidine she continued to have progressive cytopenias. Investigations for EBV, CMV, and HIV were negative. A bone marrow examination was obtained following her sixth cycle of treatment. The patient was clinically well at

the time of sampling but was highly dependent on RBC and platelet transfusions (every 14 days and every 5 days, respectively). Her marrow cellularity had decreased markedly to less than 10%, and there was no morphologic evidence of dysplasia. Numerous histiocytes showing brisk hemophagocytosis of mature RBCs were a striking feature (Figure 3).

Cytogenetic assessment showed normal copy number for chromosome 7 but a new finding of isodicentric chromosome 18q. Further workup revealed normal sIL2R of 493 U/mL and undetectable CMV and EBV DNA, and in the absence of appropriate clinical features, HLH was thought to be clinically unlikely (Table, Case 3). The hemophagocytosis identified in the bone marrow was thought to most likely represent phagocytosis of transfused RBCs. She was followed as an outpatient and initiated treatment with eltrombopag for persistent severe thrombocytopenia with increasing platelet transfusion requirements. She unfortunately failed to respond to eltrombopag, developed platelet refractoriness, and suffered an intracranial hemorrhage, after which she opted for palliative treatment and passed away 1 year after the bone marrow biopsy showing erythrophagocytosis was performed.

DISCUSSION

Hemophagocytosis may involve ingestion of granulocytes, lymphocytes, plasma cells, platelets, and both nucleated and anucleate RBCs, and is typically undertaken by cells conventionally associated with phagocytic capacity (neutrophils and macrophages) but has also

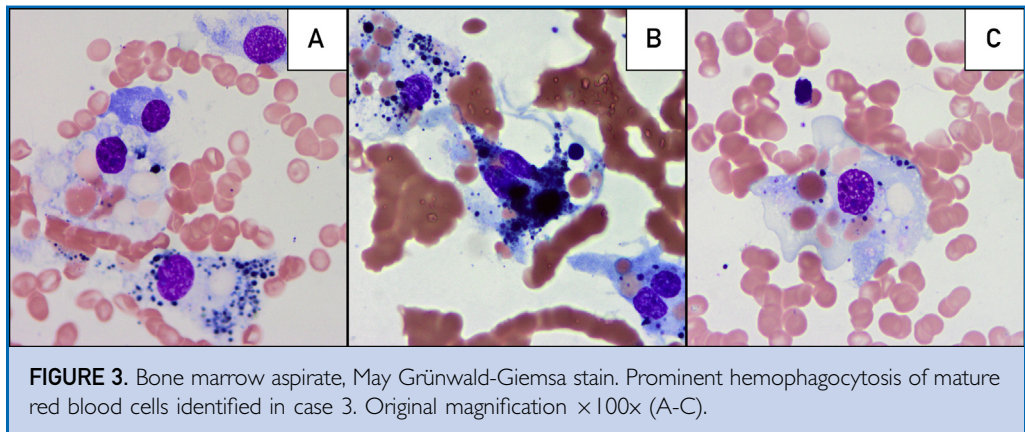


FIGURE 3. Bone marrow aspirate, May Grünwald-Giemsa stain. Prominent hemophagocytosis of mature red blood cells identified in case 3. Original magnification $\times 100\times$ (A-C).

been described in neoplastic cells in a range of malignancies.^{3,4} Although morphologic hemophagocytosis is a diagnostic criterion for HLH published in HLH-2004, it is a nonspecific finding that may be found in diverse clinical scenarios including sepsis, chemotherapy administration, conditions of ineffective hematopoiesis, and following transfusion.⁵⁻⁹ Hemophagocytosis is also detectable, albeit at lower frequency and with less intensity, in bone marrow aspirate specimens from healthy patients without clinical suspicion for disorders typically associated with hemophagocytosis.^{10,11} A recent study wherein the sensitivity and specificity of morphologic hemophagocytosis for HLH were assessed showed significant positive correlation between numbers of identifiable hemophagocytes and the presence of other diagnostic criteria for HLH, and concluded that erythrophagocytosis in isolation is a nonspecific finding, whereas identification of ingested granulocytes, nucleated RBCs, and lymphocytes was useful in diagnosing patients with HLH.¹² The authors showed that phagocytes ingesting mature RBCs, although not specific for HLH, is a more frequent finding among patients with HLH than in non-HLH bone marrows (mean 7.7 cells per 1000 versus 3.1 cells per 1000).¹²

When morphologic evidence of brisk hemophagocytosis is identified in bone marrow specimens, HLH might be considered in the treating physician's differential diagnosis, particularly in the context of other clinical features suggesting immune activation. HLH is a syndrome of pathologic immune

activation, with a familial form resulting from inheritance of defects in cell-mediated immunity and a secondary form typically resulting from a strong immune stimulus in a patient with underlying immune dysregulation.¹³ The diagnostic criteria most commonly used for hemophagocytic syndrome (HPS)/HLH are the Histiocyte Society's HLH-2004 pediatric criteria, which includes clinical findings (fever, splenomegaly), laboratory features (multiple cytopenias, hyperferritinemia, hypofibrinogenemia or hypertriglyceridemia, elevated sIL2R, low or absent natural killer cell activity, and morphologic hemophagocytosis in bone marrow, spleen, or lymph nodes), and identification of HLH-associated mutations.⁶

Given the lack of specificity of hemophagocytosis and several other diagnostic criteria outlined in HLH-2004, along with the rarity of HLH, it is critical to consider these features together with the clinical presentation of the patient to accurately diagnose this disorder. The threshold for hyperferritinemia of greater than 500 $\mu\text{g/L}$ used in the pediatric HLH-2004 study is very nonspecific in adults, and red cell transfusion is a common cause of extreme hyperferritinemia (eg, ferritin $>3000 \mu\text{g/L}$) in the absence of HPS.¹⁴ sIL2R is a promising diagnostic test for HLH, with a recent retrospective review of adult patients with HLH showing a high sensitivity with a threshold of 2400 U/mL (100%) and high specificity with a threshold of 10,000 U/mL (93%).^{15,16} The HScore developed by Fardet et al¹⁷ can be helpful in estimating the likelihood of secondary

HPS in a given patient using clinical and laboratory parameters. Although all three patients in this case series had a substantial degree of hemophagocytosis in their bone marrow and two of them had moderate hyperferritinemia ($>1000 \mu\text{g/L}$), none met five of eight HLH-2004 criteria for HLH and all had an HScore less than 90, which confers a less than 1% chance of having a secondary HPS.

Macrophages of the reticuloendothelial system have an important role in normal iron homeostasis, wherein senescent or damaged RBCs are phagocytosed and degraded, and their hemoglobin content is digested to liberate iron for storage or reutilization. Removal of senescent RBCs by macrophages is an incompletely understood process with several proposed mechanisms involving recognition of cell-surface molecules exposed during aging or damage of the RBC, ultimately facilitating phagocytosis (reviewed by de Back et al¹⁸). With storage, packed RBCs undergo changes in metabolic function and cell structure termed the “storage lesion,” and several studies have shown clearance of a larger proportion of transfused RBCs from units of blood stored for longer durations.^{19,20} Aged transfused RBCs have been shown to undergo phagocytosis in vivo in mouse models to a greater extent than fresh transfused RBCs, primarily by splenic red pulp macrophages but also by macrophages of the bone marrow.^{21,22}

It has been postulated that aged stored RBCs may be prone to phagocytosis as a result of exposure of cell surface signals — for example, stored RBCs more readily externalize phosphatidylserine, a membrane phospholipid involved in macrophage recognition.²³ Other investigators have shown comparable acute clearance of transfused RBCs between blood stored for shorter or longer durations (2 days or 35 days, respectively).²⁴

CONCLUSION

In the cases described, bone marrow aspirates revealed erythrophagocytosis to an extent not typically encountered in the routine hematopathology practice of the authors, prompting clinical consideration of the possibility of an HPS such as HLH. After further evaluation, none of these patients were ultimately diagnosed with a full-blown HPS. Although the origin of the phagocytosed cells cannot be determined

morphologically, we theorize that the brisk erythrophagocytosis identified represents ingestion of transfused RBCs by bone marrow macrophages in these multiply-transfused patients, similar to that documented in murine transfusion models.^{22,25} If this is indeed the case, erythrophagocytosis resulting from transfusion represents an important differential diagnostic consideration during evaluation of bone marrow specimens, comparable to medication-induced morphologic features of myelodysplasia (such as granulocyte nuclear abnormalities classically associated with mycophenolate mofetil administration).²⁶ The hyperferritinemia associated with RBC transfusion can cause difficulty in distinguishing post-transfusion hemophagocytosis from HLH. sIL2R is a more specific marker of pathologic immune activation and may help distinguish the post-transfusion state from HLH.

Although associated acute tissue iron deposition, inflammation, and iron-induced macrophage cell death have been documented in previous studies, whether transfusion-associated erythrophagocytosis is of clinical relevance in humans remains incompletely defined.^{21,24} The roles of reticuloendothelial macrophages in clearance of transfused RBCs and clinical sequelae thereof are not completely understood and warrant further investigation.

Abbreviations and Acronyms: HLH = hemophagocytic lymphohistiocytosis; HPS = hemophagocytic syndrome; RBC = red blood cell; sIL2R = soluble interleukin-2 receptor

Potential Competing Interests: The authors report no conflicts of interest.

Correspondence: Address to Michelle P. Wong, MD, Royal Columbian Hospital, 330 E Columbia St, New Westminster, British Columbia, Canada V3L 3W7 (michelle.wong@fraserhealth.ca).

REFERENCES

1. Ravindran A, Sankaran J, Shi M, et al. Characteristics and outcome of direct antiglobulin test-negative hemolytic anemia: a case series. *Blood*. 2016;128(22):2451.
2. Al Zaki AA, Mann SL, Carnuthers MN, Slack GW, Chen LYC. A young woman with steroid-responsive, IgG4-positive plasma cell-enriched cystic lymphangioma and chylous ascites. *Clin Case Rep*. 2018;6(6):1098-1100.
3. Ramos J, Lorsbach R. Hemophagocytosis by neoplastic plasma cells in multiple myeloma. *Blood*. 2014;123(11):1634.

4. Molad Y, Stark P, Prokocimer M, Joshua H, Pinkhas J, Sidi Y. Hemophagocytosis by small cell lung carcinoma. *Am J Hematol*. 1991;36(2):154-156.
5. Goel S, Polski JM, Imran H. Sensitivity and specificity of bone marrow hemophagocytosis in hemophagocytic lymphohistiocytosis. *Ann Clin Lab Sci*. 2012;42(1):21-25.
6. Henter JL, Home A, Arico M, et al. HLH-2004: Diagnostic and therapeutic guidelines for hemophagocytic lymphohistiocytosis. *Pediatr Blood Cancer*. 2007;48(2):124-131.
7. Ho C, Yao X, Tian L, Li FY, Podoltsev N, Xu ML. Marrow assessment for hemophagocytic lymphohistiocytosis demonstrates poor correlation with disease probability. *Am J Clin Pathol*. 2014;141(1):62-71.
8. Suster S, Hilsenbeck S, Rywlin AM. Reactive histiocytic hyperplasia with hemophagocytosis in hematopoietic organs: a reevaluation of the benign hemophagocytic proliferations. *Hum Pathol*. 1988;19(6):705-712.
9. Chandra H, Chandra S, Kaushik R, Bhat N, Shrivastava V. Hemophagocytosis on bone marrow aspirate cytology: single center experience in North Himalayan region of India. *Ann Med Health Sci Res*. 2014;4(5):692-696.
10. Marton PF. Erythrophagocytosis in the human bone marrow as disclosed by iliac bone biopsies. *Scand J Haematol*. 1975;14(3):153-159.
11. Risdal RJ, McKenna RW, Nesbit ME, et al. Virus-associated hemophagocytic syndrome: a benign histiocytic proliferation distinct from malignant histiocytosis. *Cancer*. 1979;44(3):993-1002.
12. Gars E, Purington N, Scott G, et al. Bone marrow histomorphological criteria can accurately diagnose hemophagocytic lymphohistiocytosis. *Haematologica*. 2018;103(10):1635-1641.
13. Hayden A, Park S, Giustini D, Lee AY, Chen LY. Hemophagocytic syndromes (HPSs) including hemophagocytic lymphohistiocytosis (HLH) in adults: a systematic scoping review. *Blood Rev*. 2016;30(6):411-420.
14. Chen LYC, Hayden A, Mattman A. Extreme hyperferritinemia, soluble interleukin-2 receptor, and haemophagocytic lymphohistiocytosis. *Br J Haematol*. 2019;185(3):605-606.
15. Lin M, Park S, Hayden A, et al. Clinical utility of soluble interleukin-2 receptor in hemophagocytic syndromes: a systematic scoping review. *Ann Hematol*. 2017;96(8):1241-1251.
16. Hayden A, Lin M, Park S, et al. Soluble interleukin-2 receptor is a sensitive diagnostic test in adult HLH. *Blood Adv*. 2017;1(26):2529-2534.
17. Fardet L, Galicier L, Lambotte O, et al. Development and validation of the HScore, a score for the diagnosis of reactive hemophagocytic syndrome. *Arthritis Rheumatol*. 2014;66(9):2613-2620.
18. de Back DZ, Kostova EB, van Kraaij M, van den Berg TK, van Bruggen R. Of macrophages and red blood cells; a complex love story. *Front Physiol*. 2014;5:9.
19. Hess JR. Red cell changes during storage. *Transfus Apher Sci*. 2010;43(1):51-59.
20. Luten M, Roerdinkholder-Stoelwinder B, Schaap NP, de Grip WJ, Bos HJ, Bosman GJ. Survival of red blood cells after transfusion: a comparison between red cells concentrates of different storage periods. *Transfusion*. 2008;48(7):1478-1485.
21. Gottlieb Y, Topaz O, Cohen LA, et al. Physiologically aged red blood cells undergo erythrophagocytosis in vivo but not in vitro. *Haematologica*. 2012;97(7):994-1002.
22. Youssef LA, Rebbaa A, Pampou S, et al. Increased erythrophagocytosis induces ferroptosis in red pulp macrophages in a mouse model of transfusion. *Blood*. 2018;131(23):2581-2593.
23. Bosman GJ, Cluitmans JC, Groenen YA, Werre JM, Willekens FL, Novotný VM. Susceptibility to hyperosmotic stress-induced phosphatidylserine exposure increases during red blood cell storage. *Transfusion*. 2011;51(5):1072-1078.
24. Peters AL, Beuger B, Mock DM, et al. Clearance of stored red blood cells is not increased compared with fresh red blood cells in a human endotoxemia model. *Transfusion*. 2016;56(6):1362-1369.
25. Hod EA, Zhang N, Sokol SA, et al. Transfusion of red blood cells after prolonged storage produces harmful effects that are mediated by iron and inflammation. *Blood*. 2010;115(21):4284-4292.
26. Wang E, Boswell E, Siddiqi I, et al. Pseudo-Pelger-Huët anomaly induced by medications: a clinicopathologic study in comparison with myelodysplastic syndrome-related pseudo-Pelger-Huët anomaly. *Am J Clin Pathol*. 2011;135(2):291-303.

CORRECTION

Correction to 'Respiratory Depression Following Ambulatory Urogynecologic Procedures: A Retrospective Analysis' [*Mayo Clinic Proceedings: Innovations, Quality & Outcomes* 3 (2019) 169–175/106]

Bhargavi Gali, MD; Sarah R. Gritzner, RN; Amy J. Henderson, RN; Mary E. Warner, MD; Sinokuthaba L. Sibanda, RN; Juraj Sprung, MD, PhD; and Toby N. Weingarten, MD

From the Department of Anesthesiology and Perioperative Medicine (B.G., M.E.W., J.S., T.N.W.), Mayo Clinic College of Medicine and Science, Mayo Clinic School of Health Sciences (S.R.G., A.J.H., S.L.S. [students]), Mayo Clinic, Rochester, MN.

In the Original Article titled "Respiratory Depression Following Ambulatory Urogynecologic Procedures: A Retrospective Analysis," published in the June issue of *Mayo Clinic Proceedings: Innovations, Quality & Outcomes* (*Mayo Clin Proc Inn Qual Out* 2019;3(2):169-175), Sinokuthaba Sibanda's name was spelled wrong in the acknowledgement.

In addition, Sarah R. Gritzner and Amy J. Henderson's affiliation was listed incorrectly. Their affiliation should be Mayo Clinic College of Medicine and Science, Mayo Clinic School of Health Sciences, Rochester, MN.

<https://doi.org/10.1016/j.mayocpiqo.2019.08.002>