



## ORIGINAL ARTICLE

# Synchronous microwave ablation followed by core-needle biopsy via a coaxial cannula for highly suspected malignant lung ground-glass opacities: A single-center, single-arm retrospective study

FanLei Kong<sup>1,2</sup>  | ZhiXin Bie<sup>1</sup> | YuanMing Li<sup>1</sup> | Bin Li<sup>1</sup> | RunQi Guo<sup>1</sup> | ChengEn Wang<sup>1</sup> | JinZhao Peng<sup>1,2</sup> | Sheng Xu<sup>1,2</sup> | XiaoGuang Li<sup>1,2</sup> 

<sup>1</sup>Department of Minimally Invasive Tumor Therapies Center, Beijing Hospital, National Center of Gerontology; Institute of Geriatric Medicine, Chinese Academy of Medical Sciences, Beijing, China

<sup>2</sup>Graduate School of Peking Union Medical College, Chinese Academy of Medical Science, Beijing, China

## Correspondence

XiaoGuang Li, Department of Minimally Invasive Tumor Therapies Center, Beijing Hospital, National Center of Gerontology; Institute of Geriatric Medicine, Chinese Academy of Medical Sciences, 1, Dahua street, Dongcheng district, Beijing 100730, P. R. China; Graduate School of Peking Union Medical College, China Academy of Medical Sciences, 9, Dongdan street, Dongcheng district, Beijing 100730, China.  
Email: xglee88@126.com

## Funding information

Clinical and Translational Medical Research Fund, Chinese Academy of Medical Sciences, Grant/Award Number: 2020-I2M-C&T-A-021; Central HealthCare Research Fund, Grant/Award Number: 2020YB10; the Youth Program of National Natural Science Foundation of China, Grant/Award Number: 81901858

## Abstract

**Background:** This study aimed to retrospectively explore the safety and feasibility of computed tomography (CT)-guided synchronous microwave ablation (MWA) followed by core-needle biopsy (CNB) via a coaxial cannula for highly suspected malignant lung ground-glass opacities (GGOs).

**Methods:** The clinical data of 66 patients (66 GGOs) treated with CT-guided synchronous MWA followed by CNB via a coaxial cannula from January 2019 to January 2021 were included in this study. The technical success rate, curative effect, and complications were evaluated.

**Results:** Technical success rates were 100%. The pneumothorax rate was 36.4% (24/66). 72.7% (48/66) patients had the bronchopulmonary hemorrhage, 81.3% of hemorrhage was attributable to CNB. 24.2% (16/66) patients had varying degrees of pleural effusion. The pathological results were adenocarcinomas ( $n = 44$ ), atypical adenomatous hyperplasia ( $n = 2$ ), chronic inflammation ( $n = 3$ ) and indeterminate pathological diagnosis ( $n = 17$ ) with a 69.7% (46/66) positive diagnosis rate. The therapeutic response rate was 100.0% (66/66).

**Conclusions:** Synchronous MWA followed by CNB via a coaxial cannula has a satisfactory ablation effectiveness and an acceptable biopsy positive rate, which is an alternative treatment for highly suspected malignant GGOs.

## KEYWORDS

ground-glass opacity, lung cancer, microwave ablation, pathological diagnosis, percutaneous core-needle biopsy

## INTRODUCTION

Lung cancer is a malignancy with the highest mortality among all cancers.<sup>1,2</sup> However, the implementation of lung cancer screening using low-dose CT has demonstrated a trend toward a significant reduction in lung cancer mortality. This is due to the increased detection rate of ground-glass opacities (GGOs).<sup>3–5</sup> Recent guidelines for the management of GGOs have been published by different societies, including the

Fleischner Society, National Comprehensive Cancer Network.<sup>6,7</sup> In general, for persistent GGOs with a solid component of more than 6 mm, or if the solid component or growth develops during follow-up, they should be suspected as malignant, and biopsy or surgical resection be considered.

The safety and effectiveness of thermal ablation for lung tumors, including GGOs, has been confirmed and is widely recognized, especially in poor surgical candidates.<sup>8–14</sup> Traditionally, a puncture biopsy is usually required for

pathological diagnosis before ablation, which is in line with the general clinical diagnosis and treatment process. However, biopsy performed in a separate session can potentially induce pneumothorax, hemorrhage, gas embolism, cancer seeding along the biopsy puncture tract and will increase patient discomfort. A lung biopsy performed immediately before thermal ablation during the same procedure carries the risk of potential difficulties in tumor targeting due to post-biopsy alteration on imaging, with hemorrhage that can blur the tumor (especially for GGOs) and alter the accuracy of ablation probe placement, or biopsy-induced pneumothorax that renders the puncture more difficult, which may ultimately affect the effectiveness of ablation. Some previous studies indicated that the apoptosis and necrosis of tumor cells in the ablation area occurred gradually, the morphological features of tumor cells are preserved after thermal ablation, at least during the first month.<sup>15,16</sup> Based on these studies, some scholars have proposed and demonstrated the feasibility of biopsy immediately after ablation for lung tumors.<sup>17–20</sup> However, because of the small size and low disease cell content of the lesion, it is still controversial whether the scheme of synchronous ablation followed by biopsy is suitable for GGOs or not.<sup>21</sup>

The purpose of this study was to retrospectively explore the safety and feasibility of synchronous microwave ablation (MWA) followed by core-needle biopsy (CNB) via a coaxial cannula for highly suspected malignant lung GGOs.

## METHODS

### Patients

This retrospective single-center study was approved by our institutional review board. The requirement for informed consent was waived. Written informed consent to perform lung MWA and percutaneous CNB was obtained from each patient before the procedure.

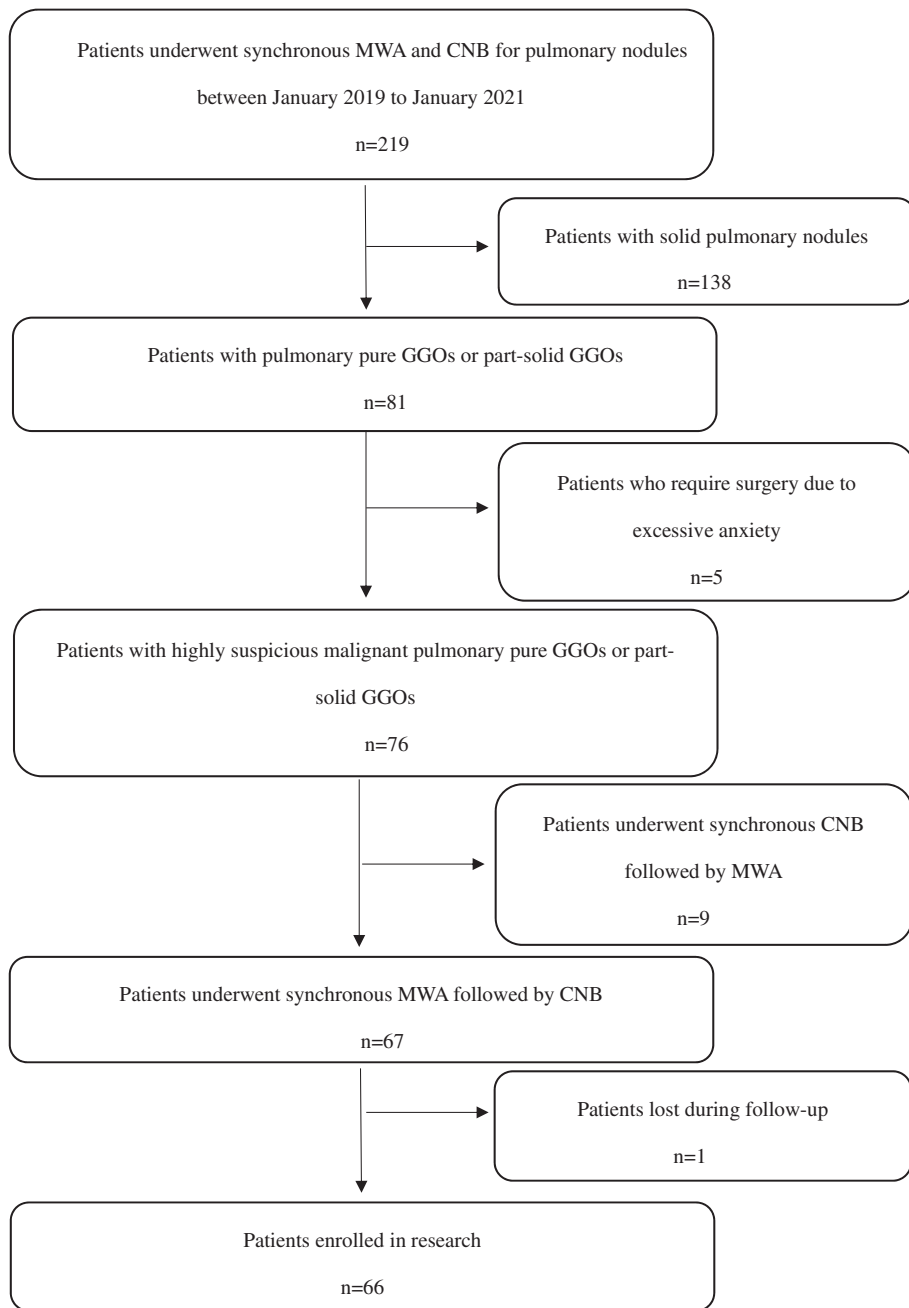
The indication was evaluated by a multidisciplinary team consisting of thoracic surgeons, oncologists, radiation and interventional radiologists. The inclusion criteria were as follows: (1) GGOs were suspected as malignant based on imaging findings (excluding nodules which were lobulated, with burrs on the edge, containing cystic components, or had higher uptake on positron emission tomography-CT compared to mediastinal blood pool) and/or changes in imaging follow-up (excluding the size of the GGOs were greater than or equal to 6 mm, and the nodule volume or solid component increased during the follow-up); (2) Eastern Cooperative Oncology Group performance status (ECOGs) of 0–2; (3) contrast-enhanced CT of thorax and abdomen or positron emission tomography-CT were performed to exclude lymph node metastasis and distance metastasis; (4) Patients who were poor candidates for surgery due to advanced age and/or complicated with serious underlying diseases, or who refused surgical intervention; (5) CNB performed immediately after MWA. Patients with abnormal coagulation tests or uncontrolled infections were excluded. The patient selection process was shown in Figure 1.

## Instrumentation and procedure

All procedures were performed with CT guidance (GE Discovery 16 Slice CT, GE Healthcare) under local anesthesia by the same interventional radiologist with 20 years of experience in thermal ablation. Continuous electrocardiograph monitoring, including heart rate, blood pressure, and pulse oximetry, was performed every 5 min throughout the procedure.

The main steps of the synchronous ablation followed by biopsy were as follows:

1. According to preoperative imaging, the patients were placed in prone, supine, or lateral positions, whichever provided access to the best puncture pathway.
2. Local CT images were obtained using 5-mm section thickness, and the nodule was reconstructed using 1-mm thickness.
3. The selected entry site was marked and prepared in a sterile fashion. Patients received analgesia (morphine 10 mg subcutaneous injection) and sedation (promethazine hydrochloride 25 mg intramuscular injection).
4. After local anesthesia with 5–10 ml of 2% lidocaine, a 15 G coaxial introducer needle (Argon Medical Devices) was advanced into the proximal edge of the lesion along a designed path avoiding vessels, bronchi, emphysema, and fissures, to minimize the risk of pulmonary bleeding and pneumothorax. Then another CT was performed to confirm the position of the needle tip.
5. After removal of the stylet, an 18G microwave antenna (Vision Medical Devices R&D Center) was advanced into the GGO through the cannula.
6. MWA was performed to achieve a complete ablation zone that encompassed the GGOs with an optimal circumferential margin of at least 1 cm. Sometimes, the antenna was adjusted into different parts of the GGO to achieve sufficient ablation area by shifting the direction of the cannula. The ablation power output was set at 20–60 W, and the duration ranged from 3 to 13 min. During the ablation, CT scans were performed every 2–5 min to monitor the ablation zone and identify any complications.
7. After MWA, the 18 G microwave antenna was pulled out with another 16 G biopsy needle (Argon Medical Devices) pierced into the lesion through the 15 G cannula. The strips of specimens were obtained and preserved in 10% formalin for pathological examination. CT scan was routinely performed immediately after the biopsy. If severe pulmonary hemorrhage occurred, the microwave antenna would be inserted again for ablation to promote hemostasis.
8. If the patient was judged to be at higher risk for pneumothorax, the sealant which was prepared by using 100 mg of 1400–2000  $\mu$ m gelatin sponge particle embolic agent and 5 ml of 50% glucose solution was injected gently during cannula removal to seal the track.
9. The patients underwent thoracic CT scan examination immediately and at 48 h post-procedure. If no



**FIGURE 1** Flow chart of the eligibility process for the research. GGOs, ground-glass opacities; CNB, core-needle biopsy; MWA, microwave ablation

complications were requiring further treatment, the patients were usually discharged 2–3 days after the ablation procedure.

### Pathological diagnosis

All specimens were sent for pathological examination by light microscopy after staining with hematoxylin and eosin (H&E). Immunostaining was added according to the judgment of the pathologist. For specimens that contained tumor cells, genetic mutation analysis was not performed routinely unless requested by the patient.

### Assessment

After discharge from hospital, patients underwent a CT scan at 1, 3, 6, and 12 months post-ablation and every 6 months thereafter to evaluate the safety and effectiveness of the procedure. The images obtained 1-month post-ablation were considered the baseline scans, with which subsequent images were compared. Data of complications and efficacy were recorded.

Treatment-related complications were defined as symptoms that occurred within 30 days of the procedure. Morbidity and mortality data were recorded according to the Common Terminology Criteria for Adverse Events (CTCAE v5.0).<sup>22</sup>

Technical success was defined as complete coverage of the lesion by the ablation zone and obtaining a biopsy specimen in accordance with the preoperative plan. The ablation range did not completely cover preoperative ground opacity signified residual tumor. Tumor seeding was defined as the appearance of tumor foci at the puncture route. Local tumor progression (LTP) was identified by enlargement of the ablation zone in comparison with the baseline CT (1 month after MWA) during imaging follow-up, provided that the primary technique efficacy was achieved. No LTP and tumor seeding during follow-up indicated effective treatment. The patients were followed up until August 31, 2021.

## Statistical analysis

All data were analyzed using SPSS for Windows Version 23.0 (IBM). All categorical variables were compared using the  $\chi^2$  test, and all continuous variables were compared using the *t*-test. *p*-values <0.05 were considered statistically significant.

## RESULTS

### Baseline characteristics

From January 2019 to January 2021, 66 patients with 66 highly suspected malignant pure GGOs or part-solid GGOs who underwent synchronous ablation followed by biopsy in our institution were enrolled. The baseline characteristics are shown in Table 1. Among these 66 patients, 36 (54.5%) were male, 30 (45.5%) were  $\geq 70$  years, and 16 (24.2%) had a history of smoking. The number of patients who had ECOGs of 1 and 2 was 26 (39.4%), and 1 (1.5%), respectively. A total of 18 (27.3%) patients were inoperable due to severe underlying disease (e.g., severe emphysema, pulmonary interstitial fibrosis, renal insufficiency, or cardiopulmonary insufficiency). The number of pure GGOs and part-solid GGOs was 55 (83.3%), and 11 (16.7%), respectively with a mean size of  $13.8 \pm 6.4$  mm.

### Procedure and complications

Table 2 summarizes the characteristics of the procedure and complications. Briefly, the mean power of MWA was  $36.0 \pm 8.7$  W, and the mean ablation time was  $6.3 \pm 2.3$  min.

All procedures were completed, and the technical success rates were 100%. A total of 24 (36.4%) pneumothorax occurred with two (3%) patients developing delayed pneumothorax three days after surgery, and seven (10.6%) patients requiring chest tube (CTCAE grade 2) with an average drainage time of 1.4 days. A total of 48 (72.7%) patients had bronchopulmonary hemorrhage (CTCAE grade 1) during the operation. Notably, 81.3% of hemorrhage occurred only after CNB. A total of 16 (24.2%) patients had varying

**TABLE 1** Baseline characteristics of enrolled patients and lung ground-glass opacity

Patient characteristics	
Gender	
Male	36 (54.5%)
Female	30 (45.5%)
Age (years)	
Mean $\pm$ SD	64.1 $\pm$ 14.7
$\geq 70$	28 (42.4%)
<70	38 (57.6%)
ECOGs	
0	39 (59.1%)
1	26 (39.4%)
2	1 (1.5%)
Reasons for patients not undergoing resection	
Severe comorbidities	18 (27.3%)
Refusal of surgery	48 (72.7%)
GGO characteristics	
GGO type	
Pure GGOs	55 (83.3%)
Part-solid GGOs	11 (16.7%)
Location	
Peripheral	39 (59.1%)
Parietal subpleural	8 (12.1%)
Interlobar subpleural	15 (22.7%)
Mediastinal subpleural	3 (4.5%)
Diaphragm subpleural	1 (1.5%)
Size (mm)	
Mean $\pm$ SD	13.8 $\pm$ 6.4
<10	15 (22.7%)
$\geq 10$ –<20	41 (62.1%)
$\geq 20$ –<30	8 (12.1%)
$\geq 30$	2 (3.0%)

Abbreviations: ECOGs, Eastern Cooperative Oncology Group performance status; GGOs, ground-glass opacities; MWA, microwave ablation; SD, standard deviation.

degrees of pleural effusion (CTCAE grade 1) and three (4.5%) had bilateral pleural effusion, but no chest tube drainage was required.

### Pathological findings

By analyzing 66 GGOs of 66 patients, 44 (66.7%) nodules were diagnosed as adenocarcinoma, two (3.0%) were diagnosed as atypical adenomatous hyperplasia, and three (4.5%) were diagnosed as chronic inflammation. A pathological diagnosis could not be achieved from the biopsy specimens of 17 patients (25.8%) indicating the possibility of false negative results, and these were defined as “indeterminate pathological diagnosis”. Most of the indeterminate pathological diagnosis cases were reported as normal lung

**TABLE 2** MWA procedure characteristics and complications

MWA parameter	Mean ± SD	Range
Power (W)	36.0 ± 8.7	20–60
Time (min)	6.3 ± 2.3	2–14
Complications	No.	%
Pneumothorax		
Grade 1	17	(25.8%)
Grade 2	7	(10.6%)
Hemorrhage		
Grade 1	48	(72.7%)
Hemorrhage attributable to CNB	39	(59.1%)
Hemorrhage attributable to MWA	9	(13.6%)
Not covering the contour of the lesion	22	(33.3%)
Covering the contour of the lesion	26	(39.4%)
Pleural effusion		
Grade 1	16	(24.2%)
Pleural effusion on the affected side	13	(19.7%)
Bilateral pleural effusion	3	(4.5%)

Abbreviations: CNB, core-needle biopsy; MWA, microwave ablation; SD, standard deviation.

tissue, only one “indeterminate pathological diagnosis” case was attributed to an inadequate sample and necrosis. Genetic mutation was also evaluated on the 19 specimens that contained tumor cells. The possibility of genetic analysis was 100%. *EGFR* mutation was detected in 10 patients and *BRAF* mutation in one patient.

## Efficacy

The mean follow-up duration was 14.5 months, and all patients underwent CT scan at the first, third, and sixth month, and every 6 months after MWA. No local tumor progression and tumor seeding were identified during the follow-up. No procedural or tumor-related death occurred during the follow-up.

## DISCUSSION

According to the new classification of the International Association for the Study of Lung Cancer/American Thoracic Society/European Respiratory Society in 2011, lung adenocarcinomas are classified as atypical adenomatous hyperplasia, adenocarcinoma in situ, minimally invasive adenocarcinoma, and invasive adenocarcinoma.<sup>23</sup> Most GGO-featured lung adenocarcinomas are adenocarcinoma in situ and minimally invasive adenocarcinoma, and the standard treatment for these patients is lobotomy. However, GGOs are difficult to accurately locate and resect during surgery. In addition, some patients are unable to tolerate surgery because of underlying diseases or advanced age, and

some patients are unwilling to undergo surgery. Stereotactic body radiation therapy has radiation dose limits and a pathological diagnosis cannot be obtained which is important for subsequent disease management. Studies have shown that GGOs and most mixed density nodules are usually inert in biological behavior, rarely accompanied by lymph node or distant metastases.<sup>3,4</sup> Therefore, CT-guided percutaneous core-needle biopsy and thermal ablation is a more suitable treatment method after confirmation that there is no mediastinal lymph node metastasis. For GGO-featured lung cancers, image-guided thermal ablation has achieved preliminary results comparable with surgical resection in terms of a 5-year overall survival rate.<sup>13,14</sup>

Biopsy is an essential procedure before or after ablation. The traditional sequence is to perform a biopsy to confirm the pathological results first and then perform selective ablation. A definitive pathological diagnosis can help to better determine the ablation goals and endpoints. However, the two steps method increases the patient's hospital stay, cost, and surgical risk especially in elderly patients and patients with severe underlying diseases.<sup>24,25</sup> Synchronous surgery has the same treatment effectiveness as asynchronous surgery; however, synchronous surgery has higher safety.<sup>26</sup>

When a biopsy is performed before ablation, pneumothorax and hemorrhage induced by biopsy may affect the efficacy of subsequent ablation, especially for GGOs.<sup>18</sup> Schneider et al.<sup>27</sup> reviewed the data of 28 patients with tumors that were radiologically suspected to be malignant but could not be treated surgically due to various risk factors. Radiofrequency ablation (RFA) was performed immediately after biopsy specimens were confirmed to be malignant by intraoperative frozen pathology. Results showed that 24% of pulmonary hemorrhage and 12% of pneumothorax occurred after biopsy, resulting in only 77% of local tumor control for subsequent radiofrequency ablation. This study also showed that 81.3% of the hemorrhage was caused by CNB, which means that in synchronous surgery if a biopsy was performed first, the pulmonary hemorrhage may blur the tumor and alter the accuracy of positioning the thermal ablation applicator. Moreover, a biopsy-induced pneumothorax will make the puncture more difficult.

Several studies have demonstrated that even after complete ablation, pathological diagnosis and genetic testing can be performed on biopsy-obtained specimens.<sup>18–20</sup> Some studies report that ablation can aggregate tumor cells inside GGOs, which may increase the positive rate of biopsy.<sup>28</sup> Meanwhile, vascular microthrombosis and small airway occlusion caused by thermal ablation can reduce the occurrence of hemorrhage and pneumothorax which makes the puncture more difficult, as well as the risk of air embolism.<sup>28,29</sup> In a study by Wang et al.,<sup>29</sup> 74 GGOs were biopsied before and after MWA to verify their diagnostic efficacy. The results showed that there was no statistical difference in the positive rate of biopsy before and after MWA (85.1% vs. 74.3%,  $p = 0.1$ ), but the comprehensive positive rate was 90.5%, which was higher than that before MWA ( $p < 0.05$ ). Thus, they concluded that combined application of CNB before and immediately after MWA can improve

the diagnostic ability of GGOs. In this study, the positive rate of post-MWA biopsies was 69.7% (46/66), which in line with the positive rate of post-MWA biopsies in the above studies.<sup>29</sup> Specimens of 1.5% (1/66) patients could not be used for diagnosis due to inadequate samples and necrosis, this suggested that biopsy sampling direction should deviate from the core of the ablation area which was severely damaged and carbonized, and sampling should be taken as much as possible under the premise of safety. For patients with indeterminate pathological diagnosis, the possibility of false negative cannot be ruled out. Thus, strictly followed the indications, fully informed the patient of the possibility of not obtaining a pathological diagnosis, and offered alternatives (e.g., follow-up, surgical resection, and biopsy alone) before surgery are essential. In addition, these patients also were required regular follow-up. The main complications rate of pneumothorax was 60.8% and hemoptysis was 32.4% in the study by Wang et al.<sup>29</sup> The incidence of pneumothorax in this study was 36.4%, which was lower than the above study. This might be due to the use of coaxial cannula in our study. The coaxial technique reduces the number of pleural punctures. Thus, the probability of damage to small pulmonary blood vessels and bronchial branches around the lesion is reduced, thereby greatly reducing puncture complications.<sup>21</sup> This study calculated the incidence of bronchopulmonary hemorrhage instead of the more severe hemoptysis reported in most articles. Any intraoperative reduction in pulmonary parenchymal transmittance other than post-ablation changes is considered as pulmonary hemorrhage. Thus, the rate of pulmonary hemorrhage was as high as 72.7%, and most of the hemorrhage (81.3%) occurred after the biopsy without affecting the accuracy of ablation.

No LTP and tumor seeding were identified during follow-up. This was mainly attributed to the surgical sequence of microwave ablation before biopsy in synchronous surgery, which is more advantageous in determining the adequacy of the ablation range. Whether MWA reduces the accuracy of subsequent biopsies remains controversial. However, for patients with highly suspicious early lung cancer, the effectiveness of treatment should be more important than the diagnosis.

However, there were also several limitations in the study. First, this was a single-center, retrospective evaluation of a small sample size. In addition, this single-arm study lacked a control group. Moreover, the follow-up time was relatively short.

In conclusion, synchronous MWA followed by CNB via a coaxial cannula can reduce the influence of pulmonary hemorrhage (mainly caused by biopsy) and pneumothorax on ablation effectiveness, with a satisfactory ablation effectiveness and an acceptable biopsy positive rate, which is an alternative treatment for highly suspected malignant GGOs.

## ACKNOWLEDGMENTS

This work was supported by Clinical and Translational Medical Research Fund, Chinese Academy of Medical Sciences (no. 2020-I2M-C&T-A-021), Central Healthcare

Research Fund (no. 2020YB10), the Youth Program of National Natural Science Foundation of China (no. 81901858).

## CONFLICT OF INTEREST

The authors report no conflict of interest.

## ORCID

FanLei Kong  <https://orcid.org/0000-0003-2501-4620>

XiaoGuang Li  <https://orcid.org/0000-0002-3345-1313>

## REFERENCES

1. Latest global cancer data: Cancer burden rises to 19.3 million new cases and 10.0 million cancer deaths in 2020. [cited 2018 Apr 18]. Available from: <https://www.iarc.fr/faq/latest-global-cancer-data-2020-qa/>
2. Sung H, Ferlay J, Siegel RL, Laversanne M, Soerjomataram I, Jemal A, et al. Global cancer statistics 2020: GLOBOCAN estimates of incidence and mortality worldwide for 36 cancers in 185 countries. *CA Cancer J Clin.* 2021;71(3):209–49. <https://doi.org/10.3322/caac.21660>
3. Migliore M, Fornito M, Palazzolo M, Criscione A, Gangemi M, Borrata F, et al. Ground glass opacities management in the lung cancer screening era. *Ann Transl Med.* 2018;6(5):90. <https://doi.org/10.21037/atm.2017.07.28>
4. Zha J, Xie D, Xie H, Zhang L, Zhou F, Ying P, et al. Recognition of "aggressive" behavior in "indolent" ground glass opacity and mixed density lesions. *J Thorac Dis.* 2016;8(7):1460–8. <https://doi.org/10.21037/jtd.2016.05.33>
5. International Early Lung Cancer Action Program Investigators, Henschke CI, Yankelevitz DF, Pasmantier MW, Smith JP, Miettinen OS. Survival of patients with stage I lung cancer detected on CT screening. *N Engl J Med.* 2006;355(17):1763–71. <https://doi.org/10.1056/NEJMoa060476>
6. National Comprehensive Cancer Network. (NCCN) Clinical Practice Guidelines in Oncology. Non-Small Cell Lung Cancer, Version 2. 2021. [cited 2020 Dec 15]. Available from: [https://www.nccn.org/professionals/physician\\_gls/default.aspx#nsl](https://www.nccn.org/professionals/physician_gls/default.aspx#nsl)
7. MacMahon H, Naidich DP, Goo JM, Lee KS, Leung ANC, Mayo JR, et al. Guidelines for management of incidental pulmonary nodules detected on CT images: from the Fleischner society 2017. *Radiology.* 2017;284(1):228–43. <https://doi.org/10.1148/radiol.2017161659>
8. Venturini M, Cariati M, Marra P, Masala S, Pereira PL, Carrafiello G. CIRSE standards of practice on thermal ablation of primary and secondary lung tumours. *Cardiovasc Intervent Radiol.* 2020;43(5):667–83. <https://doi.org/10.1007/s00270-020-02432-6>
9. Simon CJ, Dupuy DE, DiPetrillo TA, Safran HP, Grieco CA, Ng T, et al. Pulmonary radiofrequency ablation: long-term safety and efficacy in 153 patients. *Radiology.* 2007;243(1):268–75. <https://doi.org/10.1148/radiol.2431060088>
10. Dupuy DE. Image-guided thermal ablation of lung malignancies. *Radiology.* 2011;260(3):633–55. <https://doi.org/10.1148/radiol.11091126>
11. Iguchi T, Hiraki T, Gobara H, Fujiwara H, Matsui Y, Soh J, et al. Percutaneous radiofrequency ablation of lung cancer presenting as ground-glass opacity. *Cardiovasc Intervent Radiol.* 2015;38(2):409–15. <https://doi.org/10.1007/s00270-014-0926-x>
12. Kodama H, Yamakado K, Hasegawa T, Takao M, Taguchi O, Fukai I, et al. Radiofrequency ablation for ground-glass opacity-dominant lung adenocarcinoma. *J Vasc Interv Radiol.* 2014;25(3):333–9. <https://doi.org/10.1016/j.jvir.2013.11.035>
13. Yang X, Ye X, Lin Z, Jin Y, Zhang K, Dong Y, et al. Computed tomography-guided percutaneous microwave ablation for treatment of peripheral ground-glass opacity-lung adenocarcinoma: a pilot study. *J Cancer Res Ther.* 2018;14(4):764–71. [https://doi.org/10.4103/jcr.t.JCRT\\_269\\_18](https://doi.org/10.4103/jcr.t.JCRT_269_18)

14. Hertzanu Y, Ye X. Computed tomography-guided percutaneous microwave ablation: a new weapon to treat ground-glass opacity-lung adenocarcinoma. *J Cancer Res Ther.* 2019;15(2):265–6. [https://doi.org/10.4103/jcrt.JCRT\\_65\\_19](https://doi.org/10.4103/jcrt.JCRT_65_19)
15. Clasen S, Krober SM, Kosan B, Aebert H, Fend F, Bomches A, et al. Pathomorphologic evaluation of pulmonary radiofrequency ablation: proof of cell death is characterized by DNA fragmentation and apoptotic bodies. *Cancer.* 2008;113(11):3121–9. <https://doi.org/10.1002/cncr.23882>
16. Wang Q, Huang J, Ma K, Li T, Chen M, Wang S, et al. Evaluation of ghost cell survival in the area of radiofrequency ablation. *PLoS One.* 2012;7(12):e53158. <https://doi.org/10.1371/journal.pone.0053158>
17. Hasegawa T, Kondo C, Sato Y, Inaba Y, Yamaura H, Kato M, et al. Diagnostic ability of percutaneous needle biopsy immediately after radiofrequency ablation for malignant lung tumors: an initial experience. *Cardiovasc Intervent Radiol.* 2016;39(8):1187–92. <https://doi.org/10.1007/s00270-016-1324-3>
18. Tselikas L, de Baere T, Deschamps F, Hakimé A, Besse B, Teritehau C, et al. Diagnostic yield of a biopsy performed immediately after lung radiofrequency ablation. *Eur Radiol.* 2017;27(3):1211–7. <https://doi.org/10.1007/s00330-016-4447-7>
19. Wei Z, Wang Q, Ye X, Yang X, Huang G, Li W, et al. Microwave ablation followed by immediate biopsy in the treatment of non-small cell lung cancer. *Int J Hyperthermia.* 2018;35(1):262–8. <https://doi.org/10.1080/02656736.2018.1494856>
20. Hasegawa T, Kondo C, Sato Y, Inaba Y, Yamaura H, Kato M, et al. Pathologic diagnosis and genetic analysis of a lung tumor needle biopsy specimen obtained immediately after radiofrequency ablation. *Cardiovasc Intervent Radiol.* 2018;41(4):594–602. <https://doi.org/10.1007/s00270-017-1845-4>
21. Kong F, Wang C, Li Y, Li X. Advances in study of the sequence of lung tumor biopsy and thermal ablation. *Thorac Cancer.* 2021;12(3):279–86. <https://doi.org/10.1111/1759-7714.13795>
22. National Institute of Health. National Cancer Institute. Common terminology criteria for adverse events (CTCAE version 5) [internet]. Washington, DC: US Department of Health and Human Services; 2017. Available from: <http://evs.nci.nih.gov/ftp1/CTCAE/About.html>
23. Travis WD, Brambilla E, Noguchi M, Geisinger K, Ynag PC. The new IASLC/ATS/ERS international multidisciplinary lung adenocarcinoma classification. *J Thorac Oncol.* 2009;4(9):S86–9. <https://doi.org/10.1016/j.jtcvs.2009.05.043>
24. Khan MF, Straub R, Moghaddam SR, Maataoui A, Gurung J, Wagner TOF, et al. Variables affecting the risk of pneumothorax and intrapulmonary hemorrhage in CT-guided transthoracic biopsy. *Eur Radiol.* 2008;18(7):1356–63. <https://doi.org/10.1007/s00330-008-0893-1>
25. Yeow KM, Su IH, Pan KT, Tsay PK, Lui KW, Cheung YC, et al. Risk factors of pneumothorax and bleeding: multivariate analysis of 660 CT-guided coaxial cutting needle lung biopsies. *Chest.* 2004;126(3):748–54. <https://doi.org/10.1378/chest.126.3.748>
26. Wang D, Li B, Bie Z, Li Y, Li X. Synchronous core-needle biopsy and microwave ablation for highly suspicious malignant pulmonary nodule via a coaxial cannula. *J Cancer Res Ther.* 2019;15(7):1484–9. [https://doi.org/10.4103/jcrt.JCRT\\_721\\_18](https://doi.org/10.4103/jcrt.JCRT_721_18)
27. Schneider T, Puderbach M, Kunz J, Bischof A, Giesel FL, Dienemann H, et al. Simultaneous computed tomography-guided biopsy and radiofrequency ablation of solitary pulmonary malignancy in high-risk patients. *Respiration.* 2012;84(6):501–8. <https://doi.org/10.1159/000342874>
28. Li X, Ye X. Computed tomography-guided percutaneous core-needle biopsy after thermal ablation for lung ground-glass opacities: is the method sound? *J Cancer Res Ther.* 2019;15(7):1427–9. [https://doi.org/10.4103/jcrt.JCRT\\_926\\_19](https://doi.org/10.4103/jcrt.JCRT_926_19)
29. Wang J, Ni Y, Yang X, Huang G, Wei Z, Li W, et al. Diagnostic ability of percutaneous core biopsy immediately after microwave ablation for lung ground-glass opacity. *J Cancer Res Ther.* 2019;15(4):755–9. [https://doi.org/10.4103/jcrt.JCRT\\_399\\_19](https://doi.org/10.4103/jcrt.JCRT_399_19)

**How to cite this article:** Kong FL, Bie ZX, Li YM, Li B, Guo RQ, Wang CE, et al. Synchronous microwave ablation followed by core-needle biopsy via a coaxial cannula for highly suspected malignant lung ground-glass opacities: A single-center, single-arm retrospective study. *Thorac Cancer.* 2021;12:3216–22. <https://doi.org/10.1111/1759-7714.14189>