

CASE REPORT

Open Access



Compound heterozygous mutations in the *LTBP2* gene associated with microspherophakia in a Chinese patient: a case report and literature review

Manhua Xu^{1,2}, Kaiming Li² and Weimin He^{1*}

Abstract

Background: Microspherophakia (MSP, OMIM 251,750) is a rare inherited autosomal recessive eye disorder characterized by small spherically shaped lens. Several studies have indicated that the transforming growth factor-beta (TGF-beta) binding proteins (*LTBP2*) gene mutation is the predominant cause of MSP. In our study, novel compound heterozygous mutations in the *LTBP2* gene associated with MSP were reported, which was different from previous reported homozygous mutations.

Case presentation: The proband was an 18-year-old male in Western China with bilateral MSP, accompanied by ectopia lentis, secondary glaucoma and blindness in both eyes. In our hospital, he received bilateral lens resection and trabeculectomy combined with peripheral iridotomy. Using next-generation sequencing (NGS)-based gene panel tests, we identified pathogenic mutations in the peripheral blood DNA sample from the proband: c.3614_3618dupCTGGC (exon24, NM_000428) and c.2819G > A (exon18, NM_000428). The presence of the novel compound heterozygous mutations in the *LTBP2* gene was linked with the development of MSP. Sanger sequencing confirmed the existence of one of the two variants in each parent respectively.

Conclusion: Our results demonstrated a rare case of MSP phenotype associated with novel compound heterozygous mutations in the *LTBP2* gene using NGS technology.

Keywords: Microspherophakia, *LTBP2*, Compound heterozygous mutations, Ectopia lentis, Secondary glaucoma

Background

Microspherophakia (MSP, OMIM 251,750) is a rare autosomal recessive ocular disorder characterized by an abnormally small spherical lens shape. Due to insufficient force generated by the hypoplastic suspensory ligaments the lens fails to form a normal oval shape [1]. MSP can cause ocular anomalies such as megalocornea,

ectopia lentis and secondary glaucoma, and is related to hereditary systemic diseases such as Marfan syndrome (MFS) and Weill-Marchesani syndrome (WMS) [2, 3]. The homozygous mutation in latent transforming growth factor beta binding protein 2 (*LTBP2*) gene is considered the predominant cause for MSP [4]. In this study, we identified a novel *LTBP2* compound heterozygous mutation in a Chinese family through next-generation sequencing (NGS) technology. To the best of our knowledge, this case reported for the first time that MSP was associated with potentially causative *LTBP2* heterozygous mutations.

*Correspondence: hewm888@hotmail.com

¹ Research Laboratory of Ophthalmology and Vision Sciences, State Key Laboratory of Biotherapy, West China Hospital of Sichuan University, Chengdu 610000, Sichuan Province, China

Full list of author information is available at the end of the article



Case presentation

Case description

This study was approved by the Ethics Committee of Yanyuan People’s Hospital (Xichang, Sichuan Province, China). Informed consent was obtained from each participant. The proband was an 18-year-old male from Southwest China (Fig. 1), born with blurred vision in both eyes. Six years ago, he experienced swollen pain in the left eye, accompanied by a headache on the left side and subsequent vision loss in a few months. Two years later, he had similar vision loss in the right eye. The medical history of the proband was unremarkable. He presented to our hospital with the complaint of long-term complete blindness, and severe pain in the left eye persistent in the past two months. Detailed interview revealed no systemic involvement, family history, trauma or surgery. An eye exam showed loss of light perception in binocular vision. Slit-lamp examination of the right eye showed no conjunctival hyperemia or edema. The right eye had a clear cornea with a normal diameter of 12 mm (Fig. 2a), a large round pupil ($\Phi=7$ mm) without light reflex, and a transparent, small spherical lens (Fig. 2b). The suspensory ligaments and the equator of the lens could be recognized through the dilated pupil under high magnification with a slit-lamp microscope, and the cell density of corneal endothelial cells was normal (2277 cells/mm²; Fig. 2c). Anterior segment optical coherence tomography (AS-OCT) showed thin central corneal thickness (448 μ m) and narrow anterior chamber (1046 μ m) (Fig. 2d). Posterior segment OCT (PS-OCT) revealed pale and atrophic optic disc (Fig. 2e). No abnormalities were found in the retina, but hyperemia and slight edema were seen in the conjunctiva. In left eye clinical examination, severe edema and opacity were observed throughout the cornea despite of normal corneal diameter (Fig. 3a), making it impossible to detect the corneal endothelial cell density. In addition, anterior chamber disappeared and

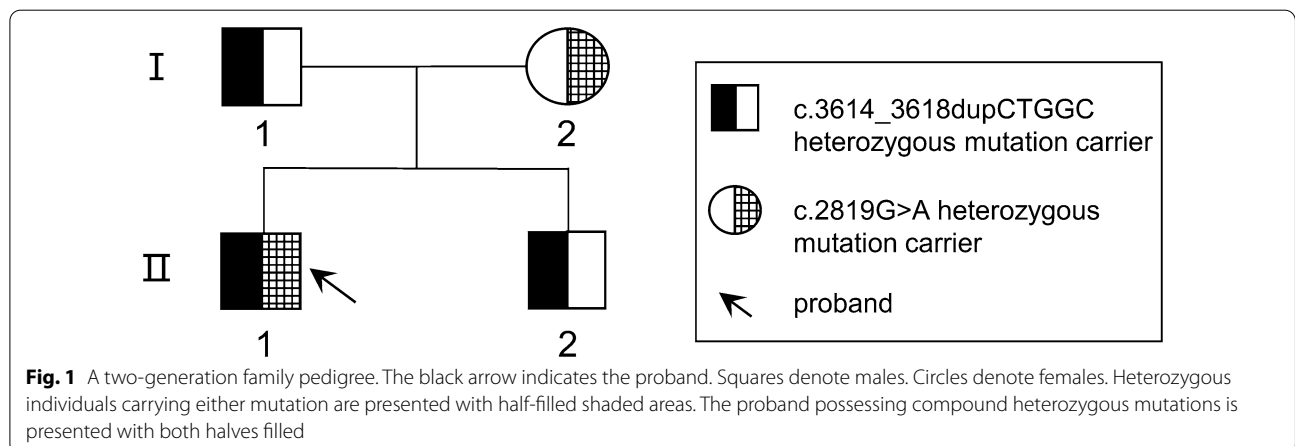
the lens dislocated (Fig. 3b). AS-OCT revealed synchia between the thickened cornea and the swollen lens (Fig. 3c). The pupil was found to be round and large ($\Phi=7$ mm) without reflex to light, and the fundus was invisible due to corneal opacity. PS-OCT revealed a pale and atrophic optic disc (Fig. 3d). High intraocular pressures (IOP) was seen in this case, with the right and left eye measured 47 mmHg and 50 mmHg, respectively. Binocular B-ultrasound imaging showed that the prolongations of the axial axis were 28.73 mm in the right eye and 28.38 mm in the left eye (Fig. 4).

No systemic abnormality was observed in this proband. The results of blood and metabolic tests (including liver and kidney function tests, homocysteine detection, plasma electrolyte test and contagion test) were all negative. Abdominal ultrasound, chest X-ray, brain CT and cardiac color Doppler ultrasound revealed no other abnormalities. No family members exhibited MSP phenotypes.

The proband was diagnosed with: 1. binocular MSP; 2. anterior lens subluxation of the left eye; 3. binocular secondary glaucoma; 4. corneal endothelial dysfunction of the left eye; and 5. binocular blindness. After hospitalization, the patient received binocular lens extraction and trabeculectomy combined with peripheral iridotomy to reduce intraocular pressure and ease the pain. After surgery, the proband still had no vision, but the pain disappeared.

Genetic analysis

Genetic analyses were performed using the blood samples from the proband, his family members including parents and brother, and 100 ethnically matched healthy controls. Peripheral blood sample (5 mL) was collected from each participant into an EDTA-containing tube. Genomic DNA was isolated from peripheral blood lymphocytes using a DNA extraction kit (CWBio, Beijing,



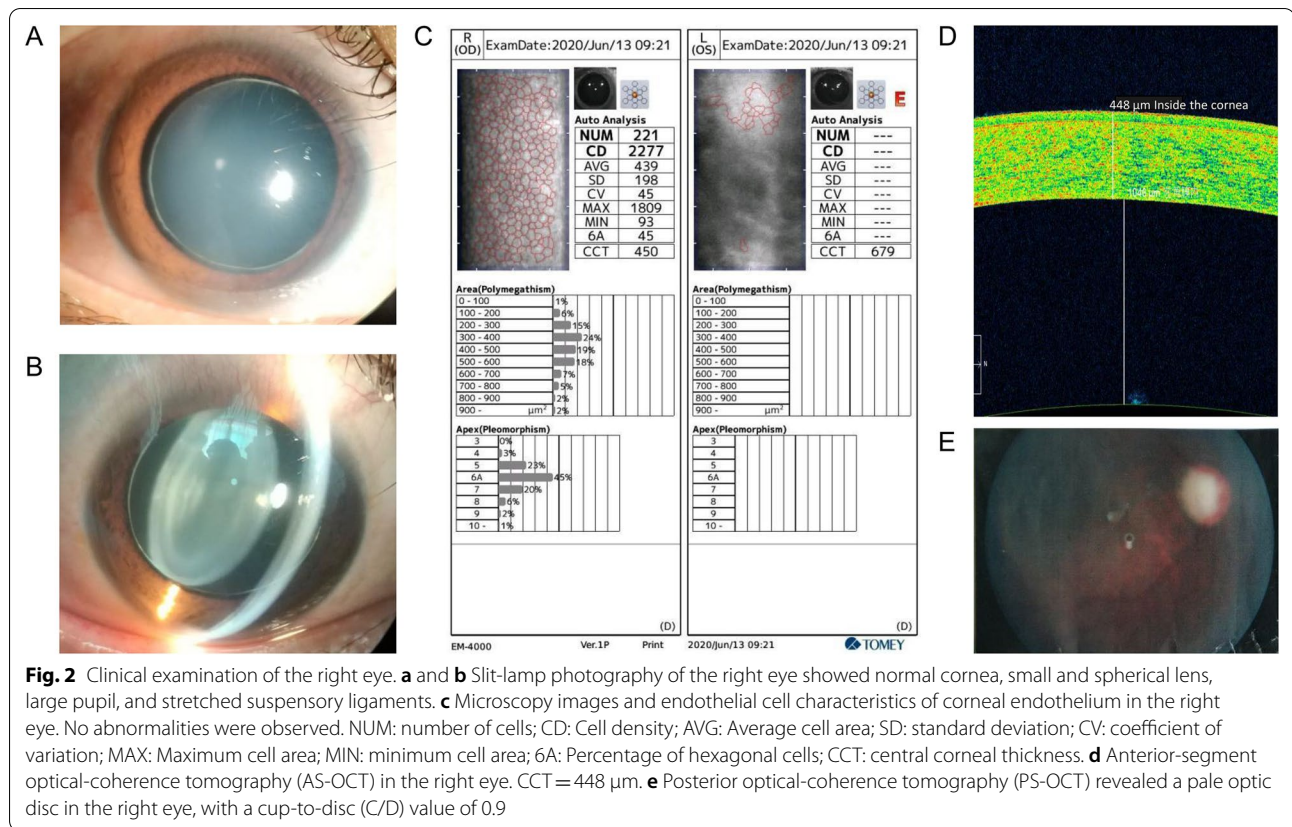


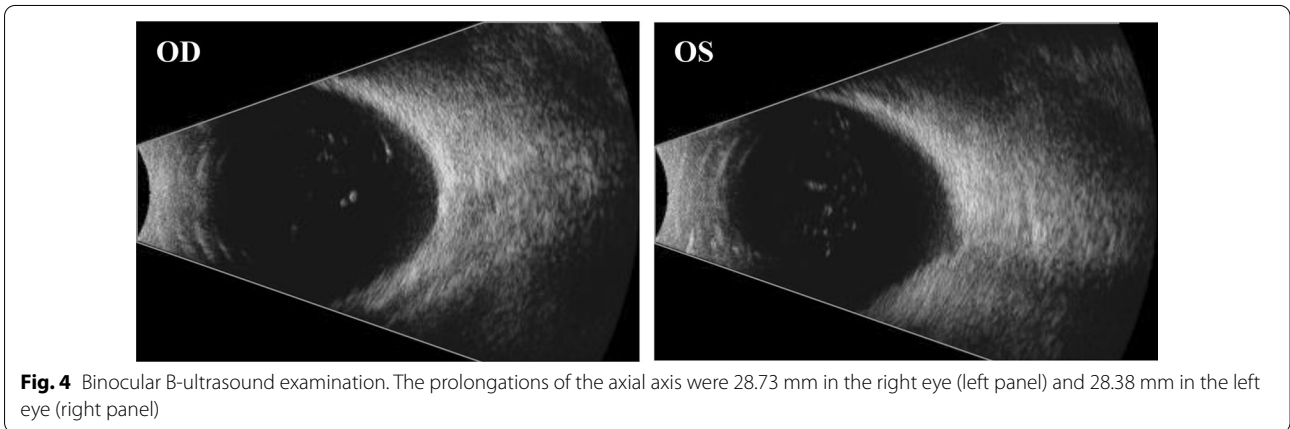
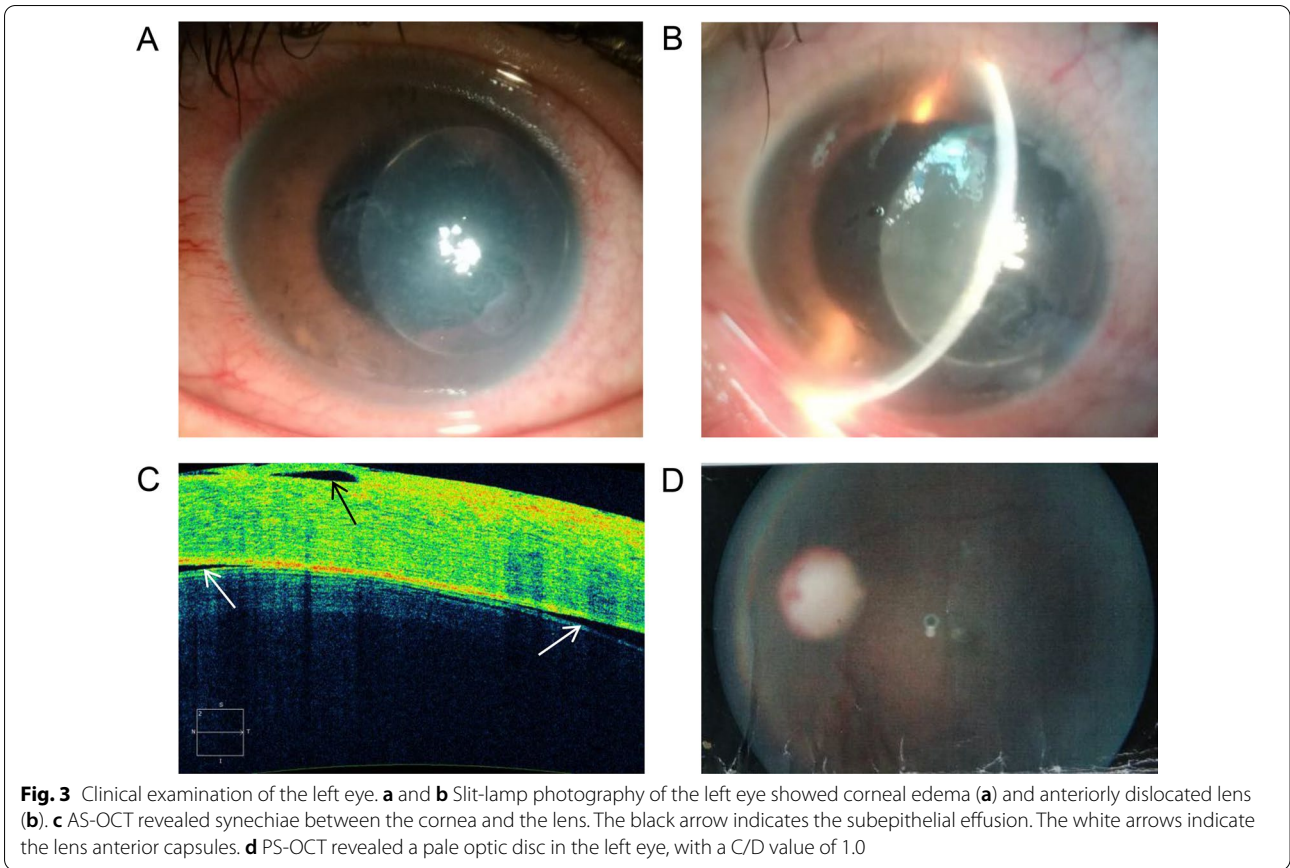
Fig. 2 Clinical examination of the right eye. **a** and **b** Slit-lamp photography of the right eye showed normal cornea, small and spherical lens, large pupil, and stretched suspensory ligaments. **c** Microscopy images and endothelial cell characteristics of corneal endothelium in the right eye. No abnormalities were observed. NUM: number of cells; CD: Cell density; AVG: Average cell area; SD: standard deviation; CV: coefficient of variation; MAX: Maximum cell area; MIN: minimum cell area; 6A: Percentage of hexagonal cells; CCT: central corneal thickness. **d** Anterior-segment optical-coherence tomography (AS-OCT) in the right eye. CCT = 448 µm. **e** Posterior optical-coherence tomography (PS-OCT) revealed a pale optic disc in the right eye, with a cup-to-disc (C/D) value of 0.9

China) and sheared into 150-bp fragments (3 µg). The DNA library was constructed using the NEBNext DNA library prep reagent set (NEB, Ipswich, MA, USA). The target ophthalmological genes were captured using a GenCap capture kit (MyGenostics, Beijing, China) containing probes for 188 genes related to lens disease, iris disease, homocysteinosis, metabolic diseases and deafness. The DNA library was enriched by mixing 1 µg genomic DNA and the probes, followed by PCR amplification. NGS was performed on a DNBSEQ-T7RS sequencer (MGI, China) for paired read 150 bp (average sequencing depth: 1485.68; target area coverage: 10X: 99.93 20X: 99.87).

After removing the low-quality reads (<80 bp), contamination and linkers from the raw data, the clean reads were mapped to the human reference genome hg19 using the BWA software. The single nucleotide variations (SNVs) as well as inserts and deletions (INDEL) were identified using GATK software, followed by annotation using ANNOVAR software. The mutations with minor allele frequencies (MAF) less than 0.02 were excluded. The pathogenicity and conservatism of missense mutations were predicted using SIFT, PolyPhen-2, MutationTaster, GERP++ and REVEL. The pathogenicity of splice site changes was analyzed using

SPIDEX. Suspicious mutations were assessed according to the variation interpretation guideline of American College of Medical Genetics and Genomics (ACMG). Finally, six suspicious mutations were identified. After excluding four mutations in *ABHD12*, *PXDN*, *ERCC6* and *RECQL4* that are unrelated to MSP, two mutations in MSP-related *LTBP2* were selected, including a frameshift mutation c.3614_3618dupCTGGC (exon24, NM_000428) (chr14:74975340–74975340) (Fig. 5) and a missense mutation c.2819G>A (exon18, NM_000428) (chr14:74983614) (Fig. 6). Protein prediction revealed that the two mutations might cause coding changes in *LTBP2* protein, yielding p.F1207Lfs*100 and p.C940Y, respectively. These two sites are highly conserved in mammalian species (Fig. 7).

The two *LTBP2* mutations were found not to be reported in the 1000 Genomes Project, EXAC, gnomAD and dbSNP databases. MutationTaster predicted both mutations as “Disease causing”. ACMG also predicted the c.3614_3618dupCTGGC variant as “pathogenic”. The c.2819G>A variant was predicted as “deleterious” by SIFT, indicating that the mutation might affect protein function. PolyPhen-2 score of c.2819G>A was 0.999 (>cut-off value 0.95), suggesting that the mutation might influence protein structure and function. GERP++ score



of c.2819G>A mutation was 4.79 (> cut-off value 2), suggesting that it was highly conserved and might exert great effects on protein structure and function. Besides, the REVEL score of c.2819G>A was 0.74, which demonstrated that the mutation was deleterious. Thus, the two *LTBP2* variants were considered pathogenic.

The DNA samples of the proband, his family members, and 100 healthy controls were subjected to Sanger

sequencing to validate the variants. The proband's father and brother were found to harbor a heterozygous c. 3614_3618dupCTGGC mutation, the mother harbored a heterozygous c.2819G>A mutation, and the proband carried both mutations (Figs. 5, 6). The two *LTBP2* genetic variants were not found in healthy controls.

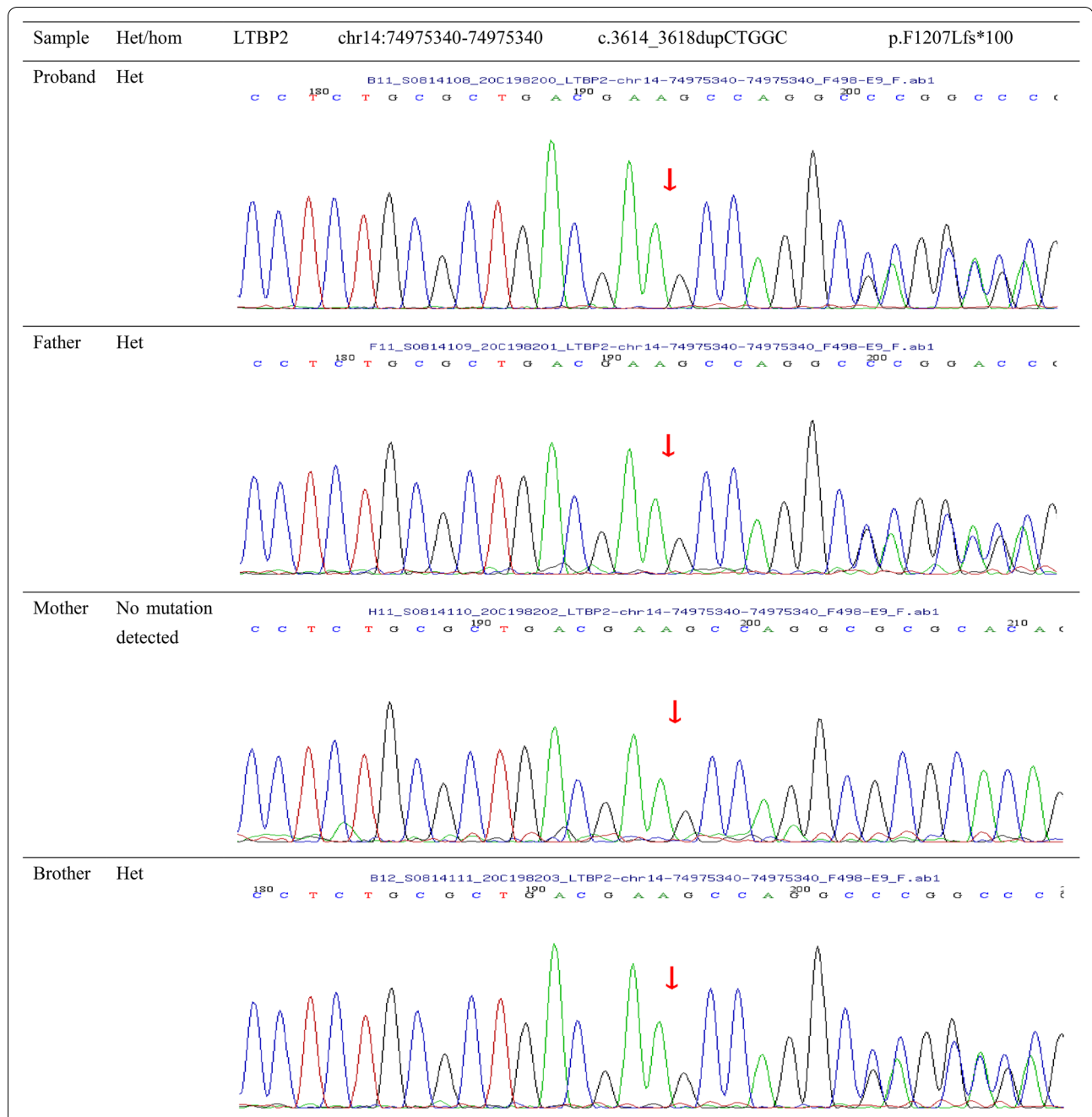


Fig. 5 Pedigree analysis of c.3614_3618dupCTGGC(p.F1207Lfs*100) in *LTBP2*. Sanger sequencing identified a heterozygous c.3614_3618dupCTGGC (p.F1207Lfs*100) mutation in the *LTBP2* gene of the proband, his father and the brother, but not his mother. The mutation is in exon 24 of *LTBP2* gene. The red arrows indicate the start point of the mutation. Duplication of CTGGC at position 3614 may result in a phenylalanine-to-leucine substitution at phenylalanine-1207, followed by a stop codon at position +99

Discussion and conclusion

The proband had a typical clinical phenotype and pathogenic progress of MSP. With increasing age, the suspensory ligaments of the lens stretched and broke, spontaneously subluxed, leading to corneal endothelial

dysfunction and secondary glaucoma. High IOP contributed to optic atrophy, causing bilateral blindness of the patient.

Studies have shown that various microfibril-associated gene mutations were related to lens diseases.

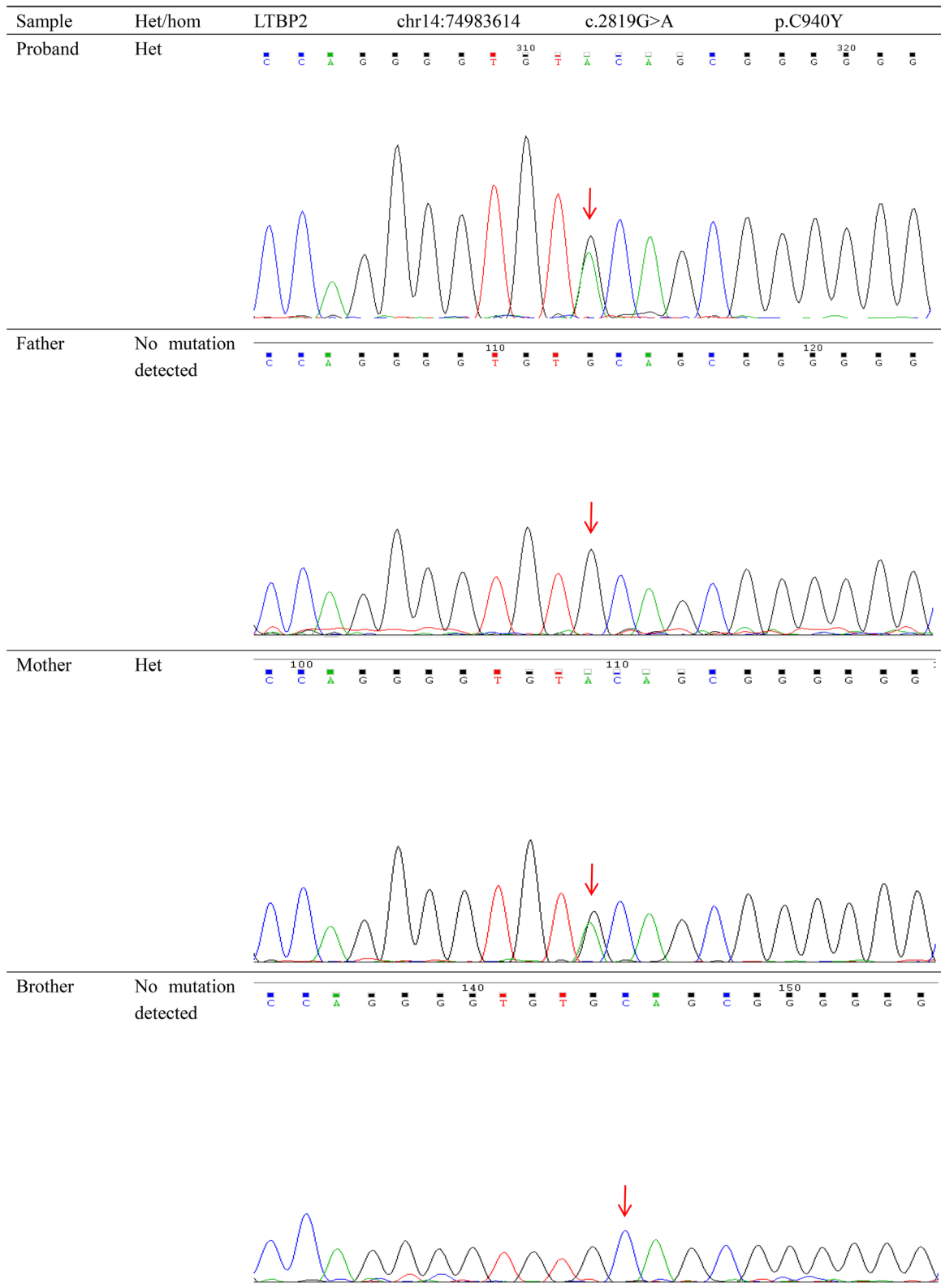
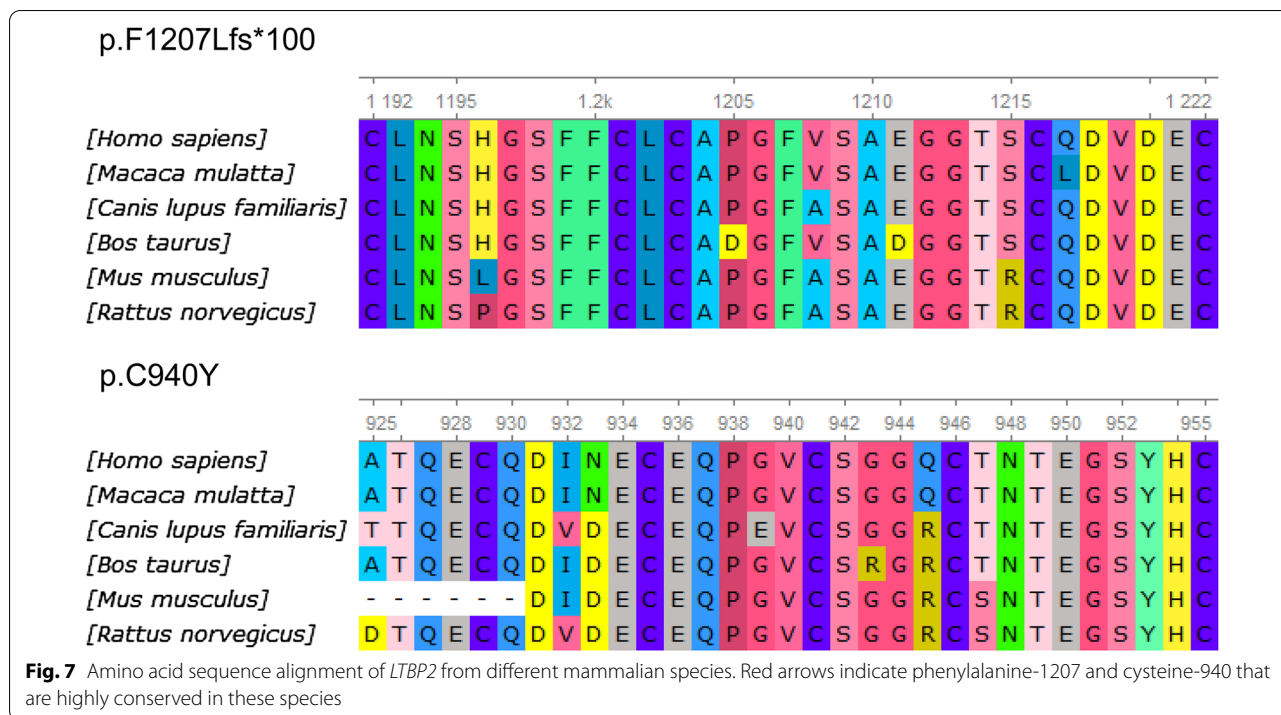


Fig. 6 Pedigree analysis of c.2819G>A (p.C940Y) in *LTBP2*. Sanger sequencing identified a heterozygous c.2819G>A (p.C940Y) mutation in *LTBP2* gene of the proband and the mother, but not the father and brother. The mutation is in exon 18 of *LTBP2* gene. The red arrow indicates the mutation site. The G-to-A mutation at position 2819 may result in a cysteine-to-tyrosine substitution at position 940 in *LTBP2* protein



Ectopia lentis Ectopia lentis is a common feature of several syndromic disorders such as MFS, homocystinuria and MSP. Isolated ectopia lentis is frequently caused by genetic alterations, mainly *ADAMTSL4* mutations [7–9]. *ADAMTSL10/17*, fibrillin-1 (*FBN1*), *CBS*, *CPAMD8* and *LEPREL1* gene variations are also associated with ectopia lentis [10–12].

Marfan syndrome (MFS) MFS is an autosomal dominant connective tissue disorder characterized by tall and thin stature, long arms, legs, fingers and toes, and sometimes accompanied by cardiovascular disorders [13]. Lens subluxation, myopia and blurred vision are common manifestations in patients with MFS. Approximately 90% of MFS cases are caused by mutations in the *FBN1* gene [14, 15].

Weill-Marchesani syndrome (WMS) WMS is a rare inherited autosomal recessive or dominant disorder of the connective tissue, characterized by short stature, short fingers, brachydactyly, joint stiffness, sometimes heart defects, and eye anomalies such as MSP, lens subluxation, severe myopia and glaucoma. *FBN1*, *LTBP2*, *ADAMTSL10*, *ADAMTSL17* gene mutations have been reported to be associated with the occurrence and development of WMS [16–19].

Homocystinuria (HCU) Classic HCU due to cystathionine β-synthase (*CBS*) deficiency is a genetic disorder of sulfur metabolism following an autosomal recessive inheritance. Its clinical manifestations include mental retardation, intraocular lens dislocation, skeletal

abnormalities, and a tendency to thromboembolic episodes. *CBS* gene mutations are the predominant cause of HCU [20–22].

MSP So far, there have been few reports on MSP pathogenic genes, and *LTBP2* (OMIM 602,091) is the only known causative gene for MSP [4]. *LTBP2*, located in 14q24.3, contains 35 exons and encodes a protein composed of 1821 amino acids. The function of *LTBP2* protein still remains unclear. Some studies have shown that *LTBP2* may play a critical role in eye development. Narooie-Nejad et al. [23] reported that human eyes had high *LTBP2* expression levels in the trabecular meshwork, ciliary process, Descemet membrane and lens capsule, but minimal expressions in the corneal stroma, sclera and iris. *LTBP2* is structurally and functionally homologous to *FBN1* and *FBN2*. Additionally, *LTBP2* is essential for the development of the ciliary zonule microfibrils that are required for assembling elastic fibers and suspending lenses. *LTBP2* deficiency causes lens luxation due to ciliary zonule fragmentation [4, 24, 25]. Ocular diseases associated with *LTBP2* include WMS, MSP, megalocornea, and ectopia lentis [26–29]. Kumar et al. [30] found that a homozygous duplication mutation (c.5446dupC) in exon 36 of *LTBP2* could lead to isolated MSP. Alías et al. [28] detected the insertion of an adenine (c.5439_5440insA) in exon 36 of *LTBP2* in a Spanish family with MSP. Shahzadi et al. [31] presented a genetic linkage between MSP and *LTBP2* locus in a large consanguineous Pakistani family.

In our study, we identified two *LTBP2* variants in the pedigree. The frameshift mutation c.3614_3618dupCTGGC changed the reading frame starting from phenylalanine-1207 (phenylalanine-to-leucine), and the new reading frame stopped at the 100th codon downstream of phenylalanine-1207. The missense mutation c.2819G > A caused a cysteine-to-tyrosine substitution in *LTBP2* protein. Mutation-Taster and ACMG predicted c.3614_3618dupCTGGC as “Disease causing” and “pathogenic”, respectively. SIFT identified c.2819G > A as “deleterious”. Mutation-Taster assessed c.2819G > A as “disease causing”. The PolyPhen-2 score of c.2819G > A was 0.999, greater than the cut-off value of 0.95, suggesting that this variant might affect the structure and function of *LTBP2* protein. The GERP ++ score of c.2819G > A was 4.79, greater than the cut-off value of 2. This finding suggested that this site was highly conserved, and the variant was highly likely to impair the function of *LTBP2* protein. Besides, the REVEL score of c.2819G > A was 0.74, indicating that the mutation was deleterious. These results collectively suggested that the two *LTBP2* variants were pathogenic. Furthermore, by searching the Conserved Domain Database of NCBI, we found that the two sites of the *LTBP2* gene were highly conserved in different species, including *homo sapiens*, *mus musculus*, *macaca fascicularis*, *canis lupus*, *bos taurus*, *mus musculus*, and *rattus norvegicus*, suggesting that mutations in these sites may significantly affect the function of *LTBP2* protein. Importantly, neither of these two mutations has been reported in 1000 Genomes Project, EXAC, gnomAD and dbSNP databases.

We further verified the two *LTBP2* genetic variants in the pedigree and ethnically matched healthy controls using Sanger sequencing (Fig. 1). Neither mutation was present in the healthy controls. The father and brother of the proband carried c.3614_3618dupCTGGC mutation, and the mother carried c.2819G > A mutation. Compound heterozygous mutations containing both the paternal and maternal variants were detected in the proband [30]. Only the proband presented MSP-related clinical phenotypes. Thus, we concluded that the *LTBP2* compound heterozygous mutations were potentially causative genetic variants for MSP.

In summary, we identified novel compound heterozygous mutations of *LTBP2* gene (c.3614_3618dupCTGG and c.2819G > A) that were associated with MSP risk. This finding highlighted the significance of *LTBP2* gene in the etiology of MSP, expanded the mutation spectrum of *LTBP2*, providing a new reference for further research on MSP.

Abbreviations

MSP: Microspherophakia; MFS: Marfan syndrome; WMS: Weill–Marchesani syndrome; *LTBP2*: Latent transforming growth factor beta Binding Protein 2; NGS: Next-generation sequencing; AS-OCT: Anterior segment optical coherence tomography; PS-OCT: Posterior segment OCT; IOP: Intraocular pressure; SNV: Single nucleotide variation; INDEL: Inserts and deletion; MAF: Minor allele frequency; ACMG: American College of Medical Genetics and Genomics; FBNI: Fibrillin-1; HCU: Homocystinuria; CBS: Cystathionine β-synthase.

Acknowledgements

We would like to thank the patient and his families whose participation made this study possible.

Authors' contributions

MX, KL, and WH designed the research. MX collected the data and drafted the manuscript. KL performed clinical examination and contributed to writing and intellectual content of the manuscript. WH revised the manuscript and had primary responsibility for the final content. All the authors approved the submitted version and the modified version.

Funding

No funding was received by any of the authors in the writing of this manuscript.

Availability of data and materials

The datasets generated and/or analysed during the current study are available in the NCBI BioProject database under the accession number PRJNA753875 (<https://www.ncbi.nlm.nih.gov/Traces/study/?acc=PRJNA753875>). Public databases used in this study included Human reference genome (GRCh37/hg19) (https://www.ncbi.nlm.nih.gov/assembly/GCF_000001405.13/), 1000 genomes database (<http://www.1000genomes.org/>), EXAC (<http://exac.broadinstitute.org/>), gnomAD (<http://gnomad.broadinstitute.org/about>), and dbSNP (<http://www.ncbi.nlm.nih.gov/projects/SNP/>).

Declarations

Ethics approval and consent to participate

Approval to this study was obtained from the Ethics Committee of Yanyuan People's Hospital Ethics Committee (Xichang, China). All the participants signed informed consent documents before enrollment. This study was conducted according to the Declaration of Helsinki.

Consent for publication

Written informed consent was obtained from all participants for publication of this case report and accompanying images.

Competing interests

The authors declare that they have no competing interests.

Author details

¹Research Laboratory of Ophthalmology and Vision Sciences, State Key Laboratory of Biotherapy, West China Hospital of Sichuan University, Chengdu 610000, Sichuan Province, China. ²Affiliated Hospital of Southwest Medical University, No.25, Taiping Street, Jiangyang District, Luzhou 646000, Sichuan Province, China.

Received: 23 January 2021 Accepted: 9 September 2021

Published online: 17 September 2021

References

- Nirankari MS, Maudgal MC. Microphakia. *Br J Ophthalmol*. 1959;43(5):314–6.
- Malik KP, Goel R, Jain K, Nagpal S, Singh S. Management of bilateral microspherophakia with secondary angle closure glaucoma. *Nepal J Ophthalmol*. 2015;7:69–73.

3. Muralidhar R, Ankush K, Vijayalakshmi P, George VP. Visual outcome and incidence of glaucoma in patients with microspherophakia. *Eye (Lond)*. 2015;29:350–5.
4. Inoue T, Ohbayashi T, Fujikawa Y, Yoshida H, Akama TO, Noda K, Horiguchi M, Kameyama K, Hata Y, Takahashi K, et al. Latent TGF- β binding protein-2 is essential for the development of ciliary zonule microfibrils. *Hum Mol Genet*. 2014;23(21):5672–82.
5. Chan RT, Collin HB. Microspherophakia. *Clin Exp Optom*. 2002;85(5):294–9.
6. Yu X, Chen W, Xu W. Diagnosis and treatment of microspherophakia. *J Cataract Refract Surg*. 2020;46(12):1674–9.
7. Neuhann TM. Hereditary ectopia lentis. *Klin Monbl Augenheilkd*. 2015;232(3):259–65.
8. Reinstein E, Smirin-Yosef P, Lagovsky I, Davidov B, Peretz Amit G, Neumann D, Orr-Urtreger A, Ben-Shachar S, Basel-Vanagaite L. A founder mutation in ADAMTSL4 causes early-onset bilateral ectopia lentis among Jews of Bukharian origin. *Mol Genet Metab*. 2016;117(1):38–41.
9. Safi M, Nejad SK, O'Hara M, Shankar SP. Ectopia lentis et pupillae caused by ADAMTSL4 pathogenic variants and an algorithm for work-up. *J Pediatr Ophthalmol Strabismus*. 2019;56:e45–8.
10. Overwater E, Floor K, van Beek D, de Boer K, van Dijk T, Hillhorst-Hofstee Y, Hoogeboom AJM, van Kaam KJ, van de Kamp JM, et al. NGS panel analysis in 24 ectopia lentis patients; a clinically relevant test with a high diagnostic yield. *Eur J Med Genet*. 2017;60(9):465–73.
11. Tang SZ, Liu YN, Hu SH, Chen H, Zhao H, Feng XM, Pan XJ, Chen P. Mutation analysis of FBN1 gene in two Chinese families with congenital ectopia lentis in northern China. *Int J Ophthalmol*. 2019;12(11):1674–9.
12. Khan AO. Further phenotypic characterization of LEPREL1-related ectopia lentis. *Ophthalmic Genet*. 2019;40(1):80–2.
13. Bitterman AD, Sponseller PD. Marfan syndrome: a clinical update. *J Am Acad Orthop Surg*. 2017;25(9):603–9.
14. Sakai LY, Keene DR, Renard M, De Backer J. FBN1: the disease-causing gene for Marfan syndrome and other genetic disorders. *Gene*. 2016;591(1):279–91.
15. Coelho SG, Almeida AG. Marfan syndrome revisited: from genetics to the clinic. *Rev Port Cardiol*. 2020;39(4):215–26.
16. Tsilou E, MacDonald IM. Weill-Marchesani syndrome. In: *GeneReviews*. Seattle (WA): University of Washington, Seattle; 1993–2020. 2007 Nov 1.
17. Hubmacher D, Apte SS. ADAMTS proteins as modulators of microfibril formation and function. *Matrix Biol*. 2015;47:34–43.
18. Karoulias SZ, Beyens A, Balic Z, Symoens S, Vandersteen A, Rideout AL, Dickinson J, Callewaert B, Hubmacher D. A novel ADAMTS17 variant that causes Weill-Marchesani syndrome 4 alters fibrillin-1 and collagen type I deposition in the extracellular matrix. *Matrix Biol*. 2020;88:1–18.
19. Yi H, Zha X, Zhu Y, Lv J, Hu S, Kong Y, Wu G, Yang Y, He Y. A novel nonsense mutation in ADAMTS17 caused autosomal recessive inheritance Weill-Marchesani syndrome from a Chinese family. *J Hum Genet*. 2019;64(7):681–7.
20. Poloni S, Sperb-Ludwig F, Borsatto T, Weber Hoss G, Doriqoui MJR, Embirçu EK, Boa-Sorte N, Marques C, Kim CA, Fischinger Moura de Souza C, et al. CBS mutations are good predictors for B6-responsiveness: a study based on the analysis of 35 Brazilian Classical Homocystinuria patients. *Mol Genet Genomic Med*. 2018;6(2):160–70.
21. Sacharow SJ, Picker JD, Levy HL. Homocystinuria caused by cystathionine beta-synthase deficiency. In: *GeneReviews*. Seattle (WA): University of Washington, Seattle, 1993–2020.
22. Ibrahim S, Maqbool S, Azam M, Iqbal MP, Qamar R. CBS mutations and MTFHR SNPs causative of hyperhomocysteinemia in Pakistani children. *Mol Biol Rep*. 2018;45(3):353–60.
23. Naroioe-Nejad M, Paylakhi SH, Shojaee S, Fazlali Z, Rezaei Kanavi M, Nilforushan N, Yazdani S, Babrzadeh F, Suri F, Ronaghi M, et al. Loss of function mutations in the gene encoding latent transforming growth factor beta binding protein 2, LTBP2, cause primary congenital glaucoma. *Hum Mol Genet*. 2009;18(20):3969–77.
24. Steven Bassnett. Zinn's zonule. *Prog Retin Eye Res*. Epub ahead of print. 2020 Sep 25:100902.
25. Fujikawa Y, Yoshida H, Inoue T, Ohbayashi T, Noda K, von Melchner H, Iwasaka T, Shiojima I, Akama TO, Nakamura T. Latent TGF- β binding protein 2 and 4 have essential overlapping functions in microfibril development. *Sci Rep*. 2017;7:43714.
26. Désir J, Sznajder Y, Depasse F, Roulez F, Schrooyen M, Meire F, Abramowicz M. LTBP2 null mutations in an autosomal recessive ocular syndrome with megalocornea, spherophakia, and secondary glaucoma. *Eur J Hum Genet*. 2010;18(7):761–7.
27. Haji-Seyed-Javadi R, Jelodari-Mamaghani S, Paylakhi SH, Yazdani S, Nilforushan N, Fan JB, Klotzle B, Mahmoudi MJ, Ebrahimi MJ, Chelich N, et al. LTBP2 mutations cause Weill-Marchesani and Weill-Marchesani-like syndrome and affect disruptions in the extracellular matrix. *Hum Mutat*. 2012;33(8):1182–7.
28. Alías L, Crespi J, González-Quereda L, Téllez J, Martínez E, Bernal S, Gallano MP. Next-generation sequencing reveals a new mutation in the LTBP2 gene associated with microspherophakia in a Spanish family. *BMC Med Genet*. 2018;19(1):77.
29. Khan AO, Aldahmesh MA, Alkuraya FS. Congenital megalocornea with zonular weakness and childhood lens-related secondary glaucoma—a distinct phenotype caused by recessive LTBP2 mutations. *Mol Vis*. 2011;17:2570–9.
30. Kumar A, Duvvari MR, Prabhakaran VC, Shetty JS, Murthy GJ, Blanton SH. A homozygous mutation in LTBP2 causes isolated microspherophakia. *Hum Genet*. 2010;128(4):365–71.
31. Shahzadi M, Firasat S, Kaul H, Afshan K, Afzal R, Naz S. Genetic mapping of autosomal recessive microspherophakia to chromosome 14q24.3 in a consanguineous Pakistani family and screening of exon 36 of LTBP2 gene. *J Pak Med Assoc*. 2020;70(3):515–8.

Publisher's Note

Springer Nature remains neutral with regard to jurisdictional claims in published maps and institutional affiliations.

Ready to submit your research? Choose BMC and benefit from:

- fast, convenient online submission
- thorough peer review by experienced researchers in your field
- rapid publication on acceptance
- support for research data, including large and complex data types
- gold Open Access which fosters wider collaboration and increased citations
- maximum visibility for your research: over 100M website views per year

At BMC, research is always in progress.

Learn more biomedcentral.com/submissions

