



Factors associated with postoperative muscle reconnection in children's congenital muscular torticollis

Shangyu Guo^{1#^}, Yiming Zheng^{1#^}, Zhiqiang Zhang^{1^}, Chuang Qian^{1^}, Dong Fu¹, Haodong Li^{1^}, Ying Liu^{2^}, Huan Wu^{3^}, Haixin Ju^{1^}, Xueting Yu^{3^}, Dahui Wang^{1*^}, Jun Song^{1*}

¹Department of Orthopedics, Children's Hospital of Fudan University, National Children's Medical Center, Shanghai, China; ²Huashan Hospital of Fudan University, Shanghai, China; ³Zhongshan Hospital of Fudan University, Shanghai, China

Contributions: (I) Conception and design: D Wang; (II) Administrative support: J Song; (III) Provision of study materials or patients: S Guo, Y Zheng; (IV) Collection and assembly of data: Y Liu, H Ju, X Yu, H Wu; (V) Data analysis and interpretation: Z Zhang, C Qian, H Li; (VI) Manuscript writing: All authors; (VII) Final approval of manuscript: All authors.

[#]These authors contributed equally to this work and should be considered as co-first authors.

^{*}These authors are co-corresponding authors.

Correspondence to: Dahui Wang, MD; Jun Song, MD. Department of Orthopedics, Children's Hospital of Fudan University, National Children's Medical Center, Wanyuan Road, Shanghai 201102, China. Email: wangdahui@fudan.edu.cn; song_jun@fudan.edu.cn.

Background: In prior studies, there has been no report of clinical observation of postoperative reconnection of the sternocleidomastoid muscle (SCM) in children with congenital muscular torticollis (CMT). Therefore, the objective of this study is to investigate the factors associated with postoperative reconnection of the SCM in children with CMT, and to provide clinical evidence.

Methods: A retrospective study was conducted, wherein 83 CMT children without any missing data were followed up from November 2019 to June 2021. The age at the time of surgery, sex, preoperative and postoperative follow-up duration, laterality, neck mass history, preoperative physical therapy history, and severity type were recorded. The severity classification of CMT was based on clinical features and ultrasound images of SCM. The postoperative reconnection of SCM was measured.

Results: Out of 83 patients, ten had postoperative reconnection. The rate of postoperative reconnection of SCM in children with CMT who had undergone unipolar SCM release surgery was 18.994 times higher than in patients who had not undergone such surgery. This difference was statistically significant [odds ratio (OR) =18.994, 95% confidence interval (CI): 1.583 to 227.897, P=0.020].

Conclusions: The history of SCM release surgery in CMT children can predict the postoperative reconnection of SCM, which will aid in determining the optimal surgical approach for recurrent CMT patients.

Keywords: Congenital muscular torticollis (CMT); sternocleidomastoid muscle (SCM); unipolar release surgery; reconnection

Submitted Mar 10, 2023. Accepted for publication Jul 28, 2023. Published online Sep 04, 2023.

doi: 10.21037/tp-23-144

View this article at: <https://dx.doi.org/10.21037/tp-23-144>

[^] ORCID: Shangyu Guo, 0000-0002-3636-387X; Yiming Zheng, 0000-0002-7947-2769; Zhiqiang Zhang, 0000-0001-7698-7655; Chuang Qian, 0000-0003-2375-3614; Haodong Li, 0009-0000-5822-7353; Ying Liu, 0000-0002-9341-2674; Huan Wu, 0000-0001-5391-4576; Haixin Ju, 0000-0002-2238-651X; Xueting Yu, 0000-0003-3535-248X; Dahui Wang, 0000-0002-3101-702X.

Introduction

Congenital muscular torticollis (CMT) is a common congenital condition in children characterized by head tilt, facial and cranial asymmetries, limited cervical rotation, and potential presence of flatter cheek and smaller eye. The incidence rate ranges from 0.3% to 3.92% (1-3). A higher prevalence of involvement on the right side was observed compared to the left. Furthermore, a male-to-female ratio of 3:2 was noted (4). Plagiocephaly, facial asymmetry, primiparity, and birth trauma are among the factors that have been proposed as potential causes of CMT (5).

It is widely acknowledged that early physical therapy is crucial for the effective treatment and management of CMT. When diagnosed early and treated non-surgically, the cure rate of CMT can exceed 90%, and the prognosis is favorable (5). However, in cases where conservative methods are ineffective, additional therapies, including non-invasive and surgical interventions, are necessary (6,7). For optimal outcomes, surgical intervention is recommended within the age range of one to four years (8-10). Indications for surgical intervention in CMT include children who are more than one year old with cervical passive or active limitations in

rotation or/and side flexion ranging from ten to fifteen degrees, those who are more than seven months old with sternocleidomastoid muscle (SCM) mass, and those who have shown poor response to conservative treatment (11). A variety of surgical techniques have been developed for treating CMT, including but not limited to unipolar release, bipolar release, and transaxillary subcutaneous endoscopic release of the SCM (9,12,13). In our study, the unipolar release surgical technique was universally employed for all pediatric patients diagnosed with CMT.

Torticollis recurrence is a frequent complication following surgical release (10). As outlined in Chotigavanichaya's article, recurrence was defined as a significant head tilt caused by the SCM, resulting in a 50% reduction in range of motion when compared to the initial 12-week postoperative period (10). The recurrence of torticollis after surgery does not necessarily indicate reconnection of CMT. Reconnection of the SCM refers to the appearance of a previously severed SCM with or without accompanying clinical symptoms. Our study revealed that some CMT patients experienced SCM reconnection after surgery, yet achieved favorable surgical outcomes with an average follow-up duration of 1.36 years. The objective of this study was to analyze the factors associated with postoperative SCM reconnection. We present this article in accordance with the STROBE reporting checklist (available at <https://tp.amegroups.com/article/view/10.21037/tp-23-144/rc>).

Highlight box

Key findings

- The present study has uncovered a significant finding that postoperative sternocleidomastoid muscle (SCM) reconnection can occur in cases of congenital muscular torticollis (CMT) after unipolar release surgery, which marks a novel discovery. Our research revealed that children with CMT who underwent unipolar SCM release surgery experienced a postoperative SCM reconnection rate 18.994 times higher than those who did not undergo the surgery. This observed difference was statistically significant, with a P value of 0.020.

What is known and what is new?

- Previous research has indicated that different surgical methods may have varying rates of recurrence for CMT. Unipolar surgery had a higher recurrence rate of 5.5–7%, while bipolar release surgery had a lower recurrence rate of 2–2.9%. However, it is crucial to note that SCM reconnection without clinical symptoms does not necessarily equate to CMT recurrence with obvious symptoms.

What is the implication, and what should change now?

- Our manuscript represents a pioneering study in the field, being the first to report on postoperative SCM reconnection and its associated factors. The implications of this study are that for children diagnosed with CMT who had undergone unipolar SCM release surgery, bipolar release surgical approach may be advisable.

Methods

Subjects

Ninety-six CMT inpatient children with CMT who met the surgical criteria and underwent unipolar SCM release surgery were enrolled from the clinics between November 2019 and June 2021, and ultimately 83 patients without missing follow-up data were included for analysis (as shown in *Figure 1*).

The following were the inclusion criteria for the study: (I) diagnosis of CMT; (II) lack of response to conservative treatment; (III) treatment with unipolar release surgery at our hospital between November 2019 and June 2021; (IV) follow-up duration of at least one year; and (V) completion of in-patient records.

The study's exclusion criteria included the following: (I) presence of other conditions causing torticollis, such as ophthalmic torticollis, bony torticollis, and syndromic torticollis; (II) surgical methods other than unipolar release;

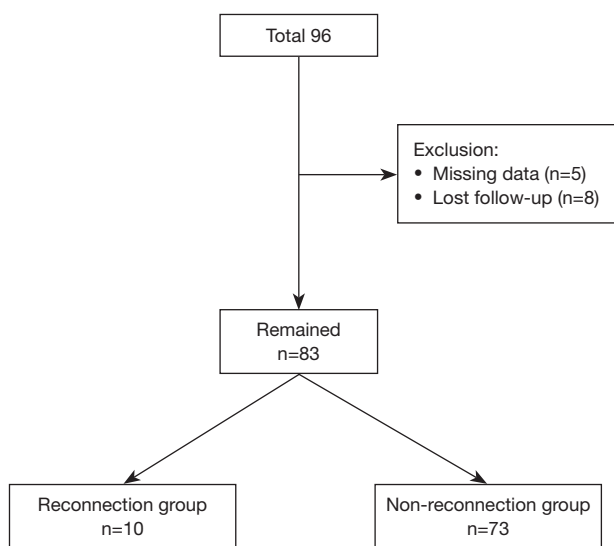


Figure 1 Flowchart inclusion.

(III) age below one year; (IV) follow-up duration of less than one year; and (V) incomplete in-patient records.

The head tilt angle was measured using traditional goniometers and the toriCAM software (Graham Barrett, AppStore, USA) (14), which is a smartphone application available on the App Store (Apple Inc., Cupertino, CA, USA) (Figure 2A).

The diagnosis of SCM reconnection was established based on the following criteria: (I) the patients were previously diagnosed with CMT; (II) all patients underwent unipolar SCM release surgery; (III) a prominent SCM was visible on the surgical side (Figure 2B,2C) and ultrasonography revealed diffuse hyperechogenicity throughout the muscle.

Of these patients, reconnection group (n=10) and non-reconnection group (n=73), 31 were female and 52 were male, with a mean age of 2.43 ± 1.81 years (range, 1.04 to 11.35 years), and a mean follow-up time of 1.36 ± 0.41 years. Skeletal torticollis, ophthalmologic torticollis, immune system disorders, and other congenital malformations were excluded in all patients through examinations such as cervical X-ray and ophthalmologic examination. Patient information was obtained from medical records and a follow-up questionnaire.

The diagnosis of CMT was established based on the following criteria: (I) characteristic clinical manifestations of head tilts to the affected side and rotation of the mandible to the healthy side; (II) restricted neck movement; (III) ultrasound examination revealing focal or diffuse thickening

of the affected SCM when compared to adjacent normal tissue or the contralateral SCM.

Severity classification

The severity classification was determined as follows: for the mild type, (I) diffuse hyperechogenicity along the entire muscle with hypoechogenic was seen in ultrasound images of the affected SCM; (II) palpation of the affected SCM was soft; (III) less than 50% fibrosis was seen in the affected SCM on Masson staining; (IV) no history of CMT surgery was present. For the moderate type, (I) diffuse hyperechogenicity along the entire muscle with almost no hypoechoic was seen in ultrasound images of the affected SCM; (II) palpation of the affected SCM was rigid; (III) 50–75% fibrosis was seen in the affected SCM on Masson staining; (IV) no history of CMT surgery was present. For the severe type, (I) a localized well-defined hetero-echoic mass/hyperechogenic band was seen in the entire involved SCM; (II) palpation of the affected SCM revealed a hard, palpable mass; (III) more than 75% fibrosis was seen in the affected SCM on Masson staining; (IV) no history of CMT surgery was present. Recurrent type referred to patients with a history of CMT surgery (Table 1, Figure S1).

Surgical procedures

The patients underwent unipolar SCM release performed by the same skilled pediatric orthopedic surgeon. Patient are positioned supine with the head facing the side unaffected by torticollis. An interscapular pad was used to elevate the upper thorax, and a padded ring was used to support neck extension for better visualization and operability of the affected SCM. A transverse skin crease incision was made two centimeters above the sternoclavicular end of the SCM. The platysma was incised, and the skin and subcutaneous tissue were excised. The sternal and clavicle head of the SCM, along with any tense fibrosis fascial and muscular bands, were released. A distal 0.5 cm of the SCM was excised and sent for pathological analysis. The incision was then sutured in layers.

Statistical analysis

The statistical analysis was performed using SPSS version 22.0 (Statistical Product and Service Solutions, NY, USA). The quantitative data were expressed as median (interquartile range) or mean \pm standard deviation (SD).

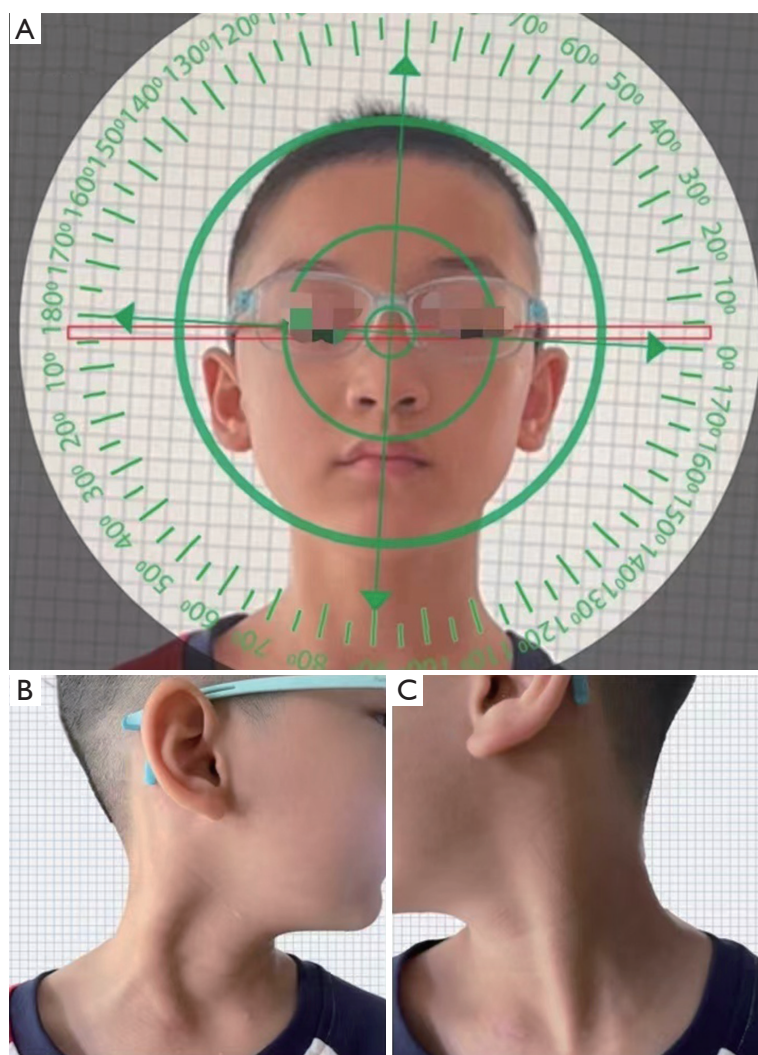


Figure 2 Postoperative photograph of a child with sternocleidomastoid muscle reconnection. This image is published with the patient's parents/legal guardians' consent. (A) A head tilt angle of 3°; (B) the reconnected sternocleidomastoid muscle; (C) the normal sternocleidomastoid muscle.

Non-parametric tests, including Kruskal-Wallis and Mann-Whitney U tests, were employed to compare independent groups. The normality of the data distribution was assessed using PPlot and the Kolmogorov-Smirnov test. A Chi-square test or Fisher's exact test was conducted where appropriate. To analyze between-group differences in outcomes, a Cox regression analysis was conducted using a Wald test for testing significance. A two-sided P value of less than 0.05 was considered statistically significant.

Sensitivity analysis was carried out by excluding the

included items gradually to identify the influences on the results.

Ethical statement

The study was conducted in accordance with the Declaration of Helsinki (as revised in 2013). The study was approved by institutional ethics committee of the Children's Hospital of Fudan University (No. 2021-492) and informed consent was signed by the patients' parents or legal guardians.

Table 1 Severity grading of congenital muscular torticollis

Type	B ultrasonography	Palpation	Fibrosis	CMT surgery history
Mild	Diffuse hyperechogenicity along the entire muscle with hypoechogenic	Soft	Less than 50%	No
Moderate	Diffuse hyperechogenicity along the entire muscle with almost no hypoechoic	Rigid	50% or more but less than 75%	No
Severe	Localized well-defined heteroechoic mass/ a hyperechogenic band in the entire involved muscle	Hard or palpable mass	75% or more	No
Recurrent	–	–	–	Yes

CMT, congenital muscular torticollis.

Results

A total of 83 subjects were included in the study, as shown in *Figure 1*. The mean age of the patients was 2.43 ± 1.81 years, and the mean follow-up time was 1.36 ± 0.41 years. There were no statistically significant differences between the reconnection group ($n=10$) and non-reconnection group ($n=73$) in terms of sex, side, presence or absence of mass in SCM, preoperative physical therapy history, postoperative neck brace, postoperative limitation of neck movement, and postoperative head tilt ($P>0.05$). However, significant differences were observed between the two groups in age at the time of surgery, follow-up time, and classification ($P<0.05$), as detailed in *Table 2*. A multivariate Cox regression analysis was conducted with surgery age and classification, the two significant factors ($P<0.05$), included. The severity classification was identified as the statistically significant contributing factor ($P=0.002$), with CMT patients with a recurrent type having an 18.994 times higher risk of postoperative SCM reconnection than those with a mild type [odds ratio (OR) =18.994, 95% confidence interval (CI): 1.583 to 227.897, $P=0.020$], as presented in *Table 3*.

Discussion

CMT is a prevalent musculoskeletal condition among children, with an incidence ranging from 0.3% to 3.9% (1-3). Clinical manifestation of CMT is head tilt, limited cervical range of motion. In the absence of intervention, the head may tilt towards the affected side while the face tilts towards the intact side. Apart from forward tilt and atrophy of the affected SCM, patients may also exhibit asymmetrical facial development, along with bilateral unequal eye splitting.

Our classification of torticollis mainly refers to the degree of fibrosis of the SCM in the ultrasound image and the palpation of its hardness (*Table 1*). Our classification is based on relevant studies conducted by previous researchers. As per the findings of Gong *et al.*, there exists a positive correlation between tissue hardness and fibrosis, implying that tissue becomes harder as the severity of fibrosis increases (15). Furthermore, excessive expression of type I, III, and IV collagen fibers in patients with CMT leads to fibrosis of the SCM, which can be observed through light microscopy (16). Based on the aforementioned criteria, we classify the severity of the disease into four distinct types: mild, moderate, severe, and recurrent. Similarly, Tatli *et al.* proposed a classification system for the degree of SCM fibrosis observed on ultrasonography in children with CMT (17).

For all children diagnosed with CMT in our study, we opted to utilize the unipolar release surgery technique. In this study, a higher prevalence of SCM reconnection was observed in the recurrent group, who had undergone CMT surgery previously ($P=0.002$). For patients with recurrent type, utilizing bipolar release technique during subsequent surgeries may be a preferable choice. Because unipolar surgery was found to have a higher recurrence rate of 5.5–7%, while bipolar release surgery had a lower recurrence rate of 2–2.9% (18-20). The lower recurrence rate in bipolar release technique can be attributed to the thorough release of the SCM at both its origin and insertion points, resulting in a more comprehensive muscle release.

Furthermore, the reconnection prevalence was found to be independent of the patient's sex, side of deformity, and age at operation, which is consistent with previous research (10). The study results indicated that the postoperative outcomes in the group with SCM

Table 2 Characteristics of participants at baseline

Demographic characteristics	Reconnection group (n=10)	Non-reconnection group (n=73)	P value
Sex [†]			0.227
Male	8	44	
Female	2	29	
Age (years) [‡] , median (IQR)	2.62 (1.88, 6.03)	1.73 (1.31, 2.32)	0.008
Follow-up time (years) [‡] , median (IQR)	1.33 (1.05, 1.51)	1.55 (1.14, 1.69)	0.012
Torticollis side [†]			0.316
Left	7	36	
Right	3	37	
Neck mass history [‡]			1.000
Yes	9	67	
No	1	6	
Preoperative physical therapy history [‡]			1.000
Yes	9	67	
No	1	6	
Severity type [‡]			0.023
Mild	1	6	
Moderate	2	18	
Severe	5	49	
Recurrent	2	0	
Postoperative neck brace [†]			0.187
<2 weeks	3	10	
≥2 weeks	7	63	
Postoperative limitation of neck movement [‡]			1.000
≥5°	1	12	
<5°	9	61	
Postoperative head tilt [†]			0.633
≥5°	2	10	
<5°	8	63	

Bilateral accurate test, $P < 0.05$ was statistically significant. [†], Pearson Chi-square test; [‡], Fisher's exact test. IQR, interquartile range.

reconnection were comparable to those in the non-reconnection group ($P > 0.05$). During the follow-up period, pediatric patients who underwent reconnection surgery did not exhibit significant symptoms of torticollis, and their neck mobility showed no statistically significant differences compared to the non-reconnection group. The current surgical effect in the reconnection group resembled that of

Z-plastic surgery in CMT, which effectively restored the V-shaped structure of the neck and released the contracture of SCM (21).

There are several limitations in this study: (I) the sample size of CMT patients in both the reconnection and non-reconnection groups was relatively small; (II) the follow-up period was insufficiently long; (III) there was

Table 3 The results of the multivariate Cox regression analyses

Severity type	P	OR	95% CI	
			Lower	Upper
Total	0.002	–	–	–
Moderate	0.762	0.689	0.062	7.666
Severe	0.667	0.623	0.072	5.371
Recurrent	0.020	18.994	1.583	227.897

Mild is the reference item. Bilateral accurate test, $P < 0.05$ was statistically significant. OR, odds ratio; CI, confidence interval.

no quantitative indicator provided for the classification of CMT patients in palpation items. Therefore, the results need to be verified by larger-scale studies with longer follow-up periods.

Conclusions

In this study, an increased risk of postoperative SCM muscle reconnection was observed in recurrent CMT children who had previously undergone SCM release surgery (recurrent type). Further studies are needed to explore the long-term association between reconnection and disease recurrence, which will aid in determining the optimal surgical approach for recurrent CMT patients.

Acknowledgments

Funding: This study was supported by the National Key Research and Development Program of China (No. 2021YFC2701003) and the Science and Technology Commission of Shanghai Municipality (No. 21Y11911500).

Footnote

Reporting Checklist: The authors have completed the STROBE reporting checklist. Available at <https://tp.amegroups.com/article/view/10.21037/tp-23-144/rc>

Data Sharing Statement: Available at <https://tp.amegroups.com/article/view/10.21037/tp-23-144/dss>

Conflicts of Interest: All authors have completed the ICMJE uniform disclosure form (available at <https://tp.amegroups.com/article/view/10.21037/tp-23-144/coif>). The authors have no conflicts of interest to declare.

Ethical Statement: The authors are accountable for all aspects of the work in ensuring that questions related to the accuracy or integrity of any part of the work are appropriately investigated and resolved. The study was conducted in accordance with the Declaration of Helsinki (as revised in 2013). The study was approved by institutional ethics committee of the Children's Hospital of Fudan University (No. 2021-492) and informed consent was signed by the patients' parents or legal guardians.

Open Access Statement: This is an Open Access article distributed in accordance with the Creative Commons Attribution-NonCommercial-NoDerivs 4.0 International License (CC BY-NC-ND 4.0), which permits the non-commercial replication and distribution of the article with the strict proviso that no changes or edits are made and the original work is properly cited (including links to both the formal publication through the relevant DOI and the license). See: <https://creativecommons.org/licenses/by-nc-nd/4.0/>.

References

- Bredenkamp JK, Hoover LA, Berke GS, et al. Congenital muscular torticollis. A spectrum of disease. Arch Otolaryngol Head Neck Surg 1990;116:212-6.
- Chen MM, Chang HC, Hsieh CF, et al. Predictive model for congenital muscular torticollis: analysis of 1021 infants with sonography. Arch Phys Med Rehabil 2005;86:2199-203.
- COVENTRY MB, HARRIS LE. Congenital muscular torticollis in infancy; some observations regarding treatment. J Bone Joint Surg Am 1959;41-A:815-22.
- Cheng JC, Au AW. Infantile torticollis: a review of 624 cases. J Pediatr Orthop 1994;14:802-8.
- Gundrathi J, Cunha B, Mendez MD. Congenital Torticollis. 2023.
- Petronic I, Brdar R, Cirovic D, et al. Congenital muscular torticollis in children: distribution, treatment duration and outcome. Eur J Phys Rehabil Med 2010;46:153-7.
- Fradette J, Gagnon I, Kennedy E, et al. Clinical decision making regarding intervention needs of infants with torticollis. Pediatr Phys Ther 2011;23:249-56.
- Pan P. The Transaxillary Subcutaneous Endoscopic Sternocleidomastoid Muscle Division as an Approach for the Surgical Treatment of Congenital Muscular Torticollis in Children. Indian J Otolaryngol Head Neck Surg 2020;72:123-7.
- Lee GS, Lee MK, Kim WJ, et al. Adult Patients with

- Congenital Muscular Torticollis Treated with Bipolar Release: Report of 31 Cases. *J Korean Neurosurg Soc* 2017;60:82-8.
10. Chotigavanichaya C, Phongprapapan P, Wongcharoenwatana J, et al. Prognostic Factors in Recurrent Congenital Muscular Torticollis. *Malays Orthop J* 2021;15:43-7.
 11. Sargent B, Kaplan SL, Coulter C, et al. Congenital Muscular Torticollis: Bridging the Gap Between Research and Clinical Practice. *Pediatrics* 2019;144:e20190582.
 12. Patwardhan S, Shyam AK, Sancheti P, et al. Adult presentation of congenital muscular torticollis: a series of 12 patients treated with a bipolar release of sternocleidomastoid and Z-lengthening. *J Bone Joint Surg Br* 2011;93:828-32.
 13. Sasaki S, Yamamoto Y, Sugihara T, et al. Endoscopic tenotomy of the sternocleidomastoid muscle: new method for surgical correction of muscular torticollis. *Plast Reconstr Surg* 2000;105:1764-7.
 14. Chung SA, Yim SY, Park A. Sternocleidomastoid muscle asymmetry in unilateral congenital superior oblique palsy. *Eye (Lond)* 2021;35:1954-60.
 15. Gong X, Wang Y, Xu P. Application of real-time ultrasound elastography for differential diagnosis of breast tumors. *J Ultrasound Med* 2013;32:2171-6.
 16. BROWN JB, McDOWELL F. Wry-neck facial distortion prevented by resection of fibrosed sternomastoid muscle in infancy and childhood. *Ann Surg* 1950;131:721-33.
 17. Tatli B, Aydinli N, Caliskan M, et al. Congenital muscular torticollis: evaluation and classification. *Pediatr Neurol* 2006;34:41-4.
 18. Canale ST, Griffin DW, Hubbard CN. Congenital muscular torticollis. A long-term follow-up. *J Bone Joint Surg Am* 1982;64:810-6.
 19. Chen CE, Ko JY. Surgical treatment of muscular torticollis for patients above 6 years of age. *Arch Orthop Trauma Surg* 2000;120:149-51.
 20. Wirth CJ, Hagena FW, Wuelker N, et al. Biterminal tenotomy for the treatment of congenital muscular torticollis. Long-term results. *J Bone Joint Surg Am* 1992;74:427-34.
 21. Ekici NY, Kizilay A, Akarcay M, et al. Congenital muscular torticollis in older children: treatment with Z-plasty technique. *J Craniofac Surg* 2014;25:1867-9.

Cite this article as: Guo S, Zheng Y, Zhang Z, Qian C, Fu D, Li H, Liu Y, Wu H, Ju H, Yu X, Wang D, Song J. Factors associated with postoperative muscle reconnection in children's congenital muscular torticollis. *Transl Pediatr* 2023;12(9):1707-1714. doi: 10.21037/tp-23-144