

## Transcatheter closure of PDA in premature babies less than 2 kg

Nazmi Narin, Özge Pamukçu, Ali Baykan, Mustafa Argun, Abdullah Özyurt, Adnan Bayram\*, Kazım Üzümlü

Departments of Pediatric Cardiology, \*Anesthesiology, Faculty of Medicine, Erciyes University; Kayseri-Turkey

### ABSTRACT

**Objective:** Our hypothesis was that percutaneous PDA closure in babies less than 2 kg was a safe and effective method. The aim of this study is to share our experience in transcatheter PDA closure in infants whose body weight is less than 2 kg in order to support our hypothesis.

**Methods:** Between July 1997 and October 2014, 382 percutaneous PDA closures were done in our center. Nineteen patients who weighed less than 2 kg were included in this retrospectively study. The other inclusion criteria were 1) being symptomatic and PDA was thought as a possible contributor of medical state and 2) persistence of PDA after medical closure treatment. Patients who had sepsis and bleeding diathesis were excluded. According to size and shape of PDA, different types of devices were used such as detachable coils and Amplatzer duct occluders. Data was expressed as mean (SD) or median (minimum–maximum). Comparisons of means and medians were performed with Student's t-test and with Mann–Whitney U test, respectively.

**Results:** The median patient age and weight were 32 days and 1603 g (range 910–2000 g) respectively. Mean PDA diameter was  $3.2 \pm 1.3$  mm. Morphology of PDA was type A in 7 patients, type C in 10, type E in 1, and type B in 1 patient. There were no reported major complications. Stenosis of left pulmonary artery was detected in four patients, all of which resolved in 6 months follow-up.

**Conclusion:** Percutaneous PDA closure in babies less than 2 kg is a safe and effective method that can be an alternative to surgery. Main distinguishing feature of this study is that it includes the largest cohort of patients less than 2 kg whose PDA closed percutaneously. (*Anatol J Cardiol* 2017; 17: 147-53)

**Keywords:** PDA, low birth weight, preterm, transcatheter closure

### Introduction

The patent ductus arteriosus (PDA) incidence is very high in preterms with low birth weight and it is known to be increased with some factors. These factors are (a) prostaglandin sensitivity is higher and the duration is longer (b) increased incidence of hypoxia and acidosis (d) anatomical closure is compromised resulting defective smooth muscle migration in preterms (1). Significant left-to-right shunt increases risk of complications such as pulmonary edema, bronchopulmonary dysplasia, intraventricular hemorrhage, and necrotizing enterocolitis; therefore, management of the PDA of these infants is critically important. The decision should be given as quickly as possible because clinical status of the infant may deteriorate rapidly. Conservative measures are attempted initially; if not successful, pharmacological methods are employed. Traditional approach in non-responders is the surgery; however, surgical ligation is not an innocent procedure as previously believed. It has risks of blood pressure fluctuations, respiratory compromise, infection, intraventricular hemorrhage, chylothorax, recurrent laryngeal nerve paralysis, bronchopulmonary

dysplasia (BPD), and death (2, 3). Percutaneous PDA closure in preterms is an ever-evolving issue; the main objective of this study is to emphasize the safety and efficacy of percutaneous PDA closure in premature babies weighing less than 2 kg. There is not such a study in the literature that includes the largest cohort of infants less than 2 kg who had percutaneous PDA closure in English references.

### Methods

#### Patient population

This retrospective study was performed in Erciyes University Pediatric Cardiology Department. Three hundred eighty-two PDA closures were accomplished between July 1997 and November 2014; 19 patients whose weight less than 2 kg were included in this retrospectively study. Local research Ethics Committee approved the study. All patients were symptomatic, requiring respiratory support (nasal oxygen, nasal continuous positive airway pressure, or intermittent positive pressure ventilation) and PDA was considered to contribute significantly to the medical state of the patient by the consulting neonatologist. Transthoracic echocardiography was

**Address for correspondence:** Dr. Özge Pamukçu, Erciyes Üniversitesi Tıp Fakültesi

Pediyatrik Kardiyoloji Bölümü, Kayseri- Türkiye

Phone: +90 352 24 532 22 Fax: +90 352 437 58 25 E-mail: ozgepamukcu2002@yahoo.com

**Accepted Date:** 20.06.2016 **Available Online Date:** 02.09.2016

©Copyright 2017 by Turkish Society of Cardiology - Available online at [www.anatoljcardiol.com](http://www.anatoljcardiol.com)  
DOI:10.14744/AnatolJCardiol.2016.6847



used to prove significant left-to-right shunting and to calculate the size of the PDA. In echocardiographic evaluation, we evaluated left atrium (LA), left ventricle (LV) end-diastolic and end-systolic dimensions, LV systolic function with ejection fraction, fraction of shortening, flow in left pulmonary artery, and descending aorta. Seventeen patients had patent foramen ovale and left-to-right shunt, which did not change after the procedure. The patients with PDA were selected for transcatheter closure according to the shape and the size of PDA diameter measured on aortogram. The following patient characteristics were recorded: age, weight, sex, presence of associated noncardiac problems, and hemodynamic data (Aorta and pulmonary artery pressures were measured before the procedure). Physical examination, chest radiography, electrocardiogram, and transthoracic echocardiography were done before the procedure. Written consents were taken from the parents after informing about the procedure and complications.

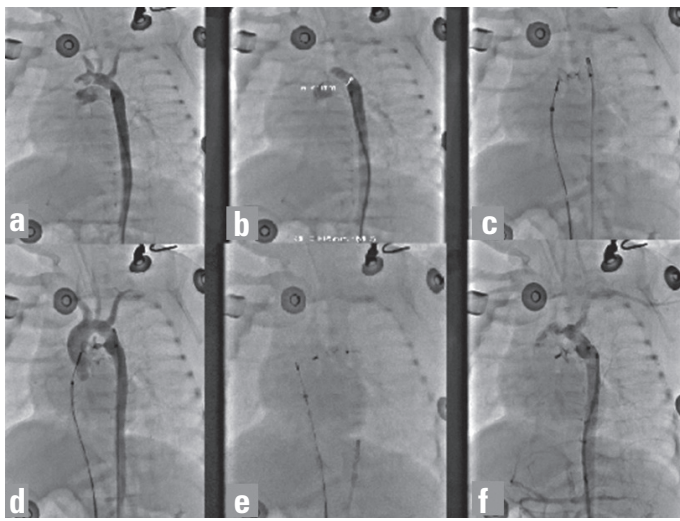
#### Device and catheterization

Hemodynamic measurements were done by cardiac catheterization in all patients. The procedures were performed under sedation. In our center for the ones who were not intubated, 40% oxygen was given by mask and sedation was done with 0.005 mg/kg midazolam and 1 mg/kg ketamine. Muscle relaxants and narcotics were not used before or during the procedure. But the ones who were intubated, 50% oxygen was given, and midazolam and ketamine were applied in the same dosages. We did not intubate the patients for the catheterization procedure.

Intubation was only done for respiratory insufficiency because of their clinical status. Percutaneous access was obtained by the Seldinger technique to a femoral artery and vein [4 French and 5 French (E), respectively]. We did not have access to femoral artery in all patients. We had both arterial and venous access in eight patients, and the rest of the patients had only venous catheter. In recent years, as the devices have improved and we have gained more experience, we have started to use only the venous route for PDA closure. Vascular accesses used in the procedure for each patient are mentioned in Table 1. Following heparinization and intravenous antibiotic administration, hemodynamic and angiographic evaluations were done. Hemodynamic measurements of systolic, diastolic, and mean pressures of pulmonary artery and aorta also oxygen saturation were obtained from the inferior, superior vena cava, right atrium, pulmonary artery, right ventricle (RV), and the aorta. Multipurpose, hydrophilic, and pigtail catheters were used to measure the ventricle/atrium and great artery pressures. Fick's principle was used to calculate the ratio of pulmonary to systemic blood flow ( $Q_p/Q_s$ ). Descending aorta angiograms in the right anterior oblique and lateral projections performed with a 4F pigtail catheter were used to determine the size and morphology of ductus. In patients, we did not have arterial access; aortography was done with a catheter extended from the pulmonary artery to the aorta through PDA. Ducti were categorized based on their morphology, according to the classification of Kritchenko et al. (4). Type A: conical ductus, with a prominent aortic ampulla and

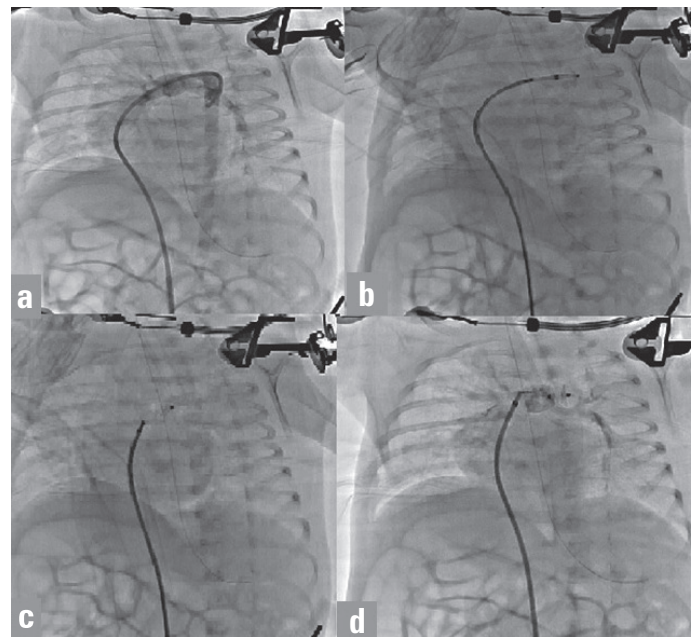
**Table 1. Demographic features of patients**

Pt no	Gestational, weeks	Sex	Age, days	Weight, g	Associated cardiac anomalies	Vascular access	PDA Type
1	30	Female	20	1800	None	Both (arterial, venous)	Conical
2	28	Male	15	980	None	Only venous	Conical
3	29	Male	24	910	None	Only venous	Conical
4	32	Female	40	1650	None	Both	Tubular
5	34	Male	60	1980	None	Both	Tubular
6	30	Female	30	2000	None	Both	Conical
7	30	Male	27	1350	VSD	Only venous	Tubular
8	33	Male	24	1975	None	Both	Tubular
9	30	Female	54	1600	None	Only venous	Tubular
10	31	Male	21	2000	None	Both	Tubular
11	29	Male	47	1590	Pulmonary valvular stenosis	Only venous	Tubular
12	30	Male	49	1875	None	Both	Elongated
13	32	Female	38	1410	None	Only venous	Conical
14	31	Male	38	2000	None	Both	Tubular
15	28	Male	35	1440	None	Only venous	Tubular
16	27	Male	10	978	None	Only venous	Tubular
17	29	Female	18	1470	None	Both	Conical
18	32	Male	32	1850	None	Both	Window
19	28	Female	21	930	None	Only venous	Conical



**Figure 1.** Main steps of percutaneous closure with ADO II AS: (a) Radiocontrast was given in descending aorta and PDA was visualized. (b) Device was delivered by venous route. (c, d) When the positioned appropriate and no residual shunt was seen in aortogram, the device was released

narrow pulmonary arterial end, Type B: “window” ductus, with short length, Type C: tubular in shape, without constrictions, Type D: multiple constrictions and complex in shape, Type E: elongated ductus. Aortic and pulmonary side dimensions and lengths were measured. A device with proper type and size was chosen according to these measurements. Detachable coils were preferred for small ducts (1.5–3 mm) and Amplatzer ductal occluders (ADO) (St Jude Medical, St. Paul, Minnesota) were used for moderate-sized ducts (3–5 mm). However, with advanced time and improved technology during the study period, our preferences in device selection have slightly changed as new versions of ADO were produced (such as ADO II-AS) for small ducts. The main types of the devices used in our study for percutaneous PDA closure were vascular coils (MReye® Flipper® Cook Medical, Bloomington, IN) and Amplatzer ductal occluders (ADO I, ADO II, ADO II Additional sizes (St Jude Medical, St. Paul, Minnesota)). Main steps of percutaneous closure procedure with ADO I, ADO II, ADO II AS was shown in Figures 1–3 respectively. The narrowest point of duct was measured and the size of Amplatzer ductal occluder was determined by adding 1–1.5 mm to that value. PDA closure was done from the pulmonary or aortic side using the 4 French Amplatzer TorqVue LP catheters. Delivery cable was mildly pushed and pulled in order to test the stability of the device. Radiocontrast injection was done before the release of device to check the position of the device. Presence of residual shunts was evaluated with Angiography done after the release of the device. After implantation of the device, it was checked for whether there is a pressure gradient on pullback from ascending aorta to the descending aorta to exclude the presence of obstruction on the aortic side. However, the ones that we did not have arterial access pressure gradient on aortic side were checked only with transthoracic echocardiography. Transthoracic echocardiography was per-



**Figure 2.** Main steps of percutaneous closure: (a) device was delivered from venous route; (b, c) Control aortograms were done in different positions; (d) The device was released

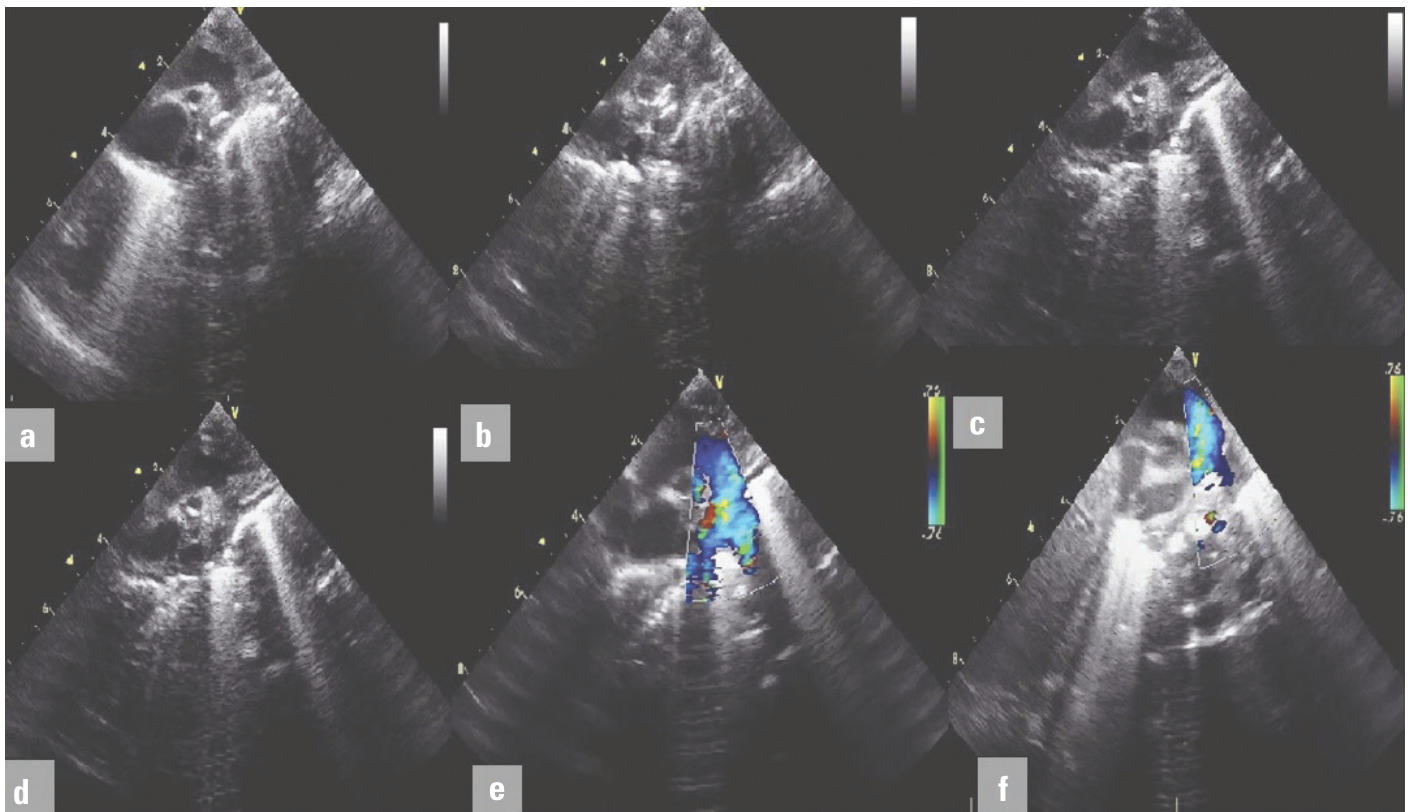
formed to control whether there is a stenosis of the left pulmonary artery and descending aorta just after implantation. Follow up echocardiography was performed on the next day, 1<sup>st</sup>, 3<sup>rd</sup>, 6<sup>th</sup> months after implantation, and yearly thereafter. Complications related to ADO implantation were noted at each follow-up visit.

### Statistical analysis

All tests were performed using SPSS for Windows 16.0 and Sigma Stat 3.1. First, the distributions of all parameters were determined by using the Shapiro–Wilk test. The parameters with normal distribution were expressed as mean (SD), and the parameters with abnormal distribution were expressed as median (minimum–maximum). Comparisons of means were performed with Student’s t-test. Comparisons of medians were performed with the Mann–Whitney U test. Correlations were calculated with the Pearson product moment or Spearman rank order, as determined by the normality of data distribution. A p value <0.05 was accepted as statistically significant.

### Results

The transcatheter closure was attempted in 382 patients in our center between July 1997 to November 2014, and 19 of them (who were less than 2 kg) were included in this study. Demographic data of the patients were summarized in Table 1. There were 7 female patients and 12 male patients. The median patient age was 32 days (range 10–60 days). The median weight was 1603 g (range 910–2000 g). Associated cardiac deformities were detected in two patients: perimembranous ventricular septal defect and pulmonary valvular stenosis. There were 13 patients that had mechanical ventilator support. None of the patients required ino-



**Figure 3.** Transthoracic echocardiography images after percutaneous closure with ADO device. First four pictures (a–d) show the device position in descending aorta, 5<sup>th</sup> and 6<sup>th</sup> (e, f) pictures show Doppler views in descending aorta and peripheral pulmonary artery, respectively. No pressure gradient was detected in descending aorta and peripheral pulmonary artery

tropic support before or at the time of the procedure. All cases were given three courses of ibuprofen treatment, with the exception of three patients with necrotizing enterocolitis or thrombocytopenia. Angiographic data of the patients were shown in Table 2 (diameter of PDA measured in aortogram, morphology of PDA, type of the device, closure side whether arterial or venous, major and minor complications). The mean PDA diameter was  $3.2 \pm 1.3$  mm. Morphology of PDA was determined as Type A in 7 patients, Type C in 10 patients, Type E in 1 patient, and Type B ductus in 1 patient. Types of the devices that we used were detachable coils (Cook Medical, Bloomington, IN) in 2 patients, ADO I in 2 patients, ADO II in 3 patients, and ADO II AS in 12 patients. Successful transcatheter ductal closure was performed in cases with median fluoroscopy time of 8.6 min (8–19 min), procedural time of 37 min (30–42 min), and amount of radiation exposure was 128.9 (98.5–285.7) cGycm<sup>2</sup>. Aorta and pulmonary artery pressures were measured before the procedure. The mean value of pulmonary artery pressure was 21 (17–26) mm Hg. Mean aorta pressure was  $35 \pm 10$  mm Hg. However, we did not measure after the procedure. In 9 cases, we used only the venous route and did not have an arterial access, because we tried to do all the procedures as quick as possible and keep the procedure time as short as possible. As the time period of having sheaths elongates the chance of having increased vascular problems this was probably why we did not face with any vascular problems during or after the procedure.

Eighteen cases were closed successfully. Therefore, total success rate was 94.7 %. One case had a large window type PDA with 4.5 mm width; closure with an ADO II device was attempted, but it had to be retaken as it compressed the aorta and the PDA was closed surgically.

No major complications, such as death, vascular complications, device embolizations, malposition, hemolysis, thromboembolism, and infective endocarditis, were reported during the study period. There were minor complications such as device-related left pulmonary stenosis in four patients. Pressure gradient in the left pulmonary artery was checked by transthoracic echocardiography before deploying the device in each case. Mild left pulmonary arterial stenosis was detected echocardiographically in four patients after implantation of the device, although pressure gradients were not observed during the procedure. The Doppler gradient did not exceed 14 mm Hg and all resolved spontaneously in 6 months. Residual shunt was checked immediately, 1 day, 1 month, 3 months, and 6 months after implantation of the device. No residual shunts were reported. After the implantation of the device, no pressure gradients were detected on pullback recordings from the ascending to the descending aorta in any patient. Follow-up transthoracic echocardiography also did not show any residual aortic gradients. Since these patients weighed less than 2 kg, most of them required additional medical support. Mechanical ventilatory support was needed

**Table 2. Angiographic data of patients**

Pt no	PDA diameter, mm	Qp/Qs	Type of device	Device size	Major complication	Minor complication	Vascular access	Closure side
1	3	1.36	ADO II AS	5x2	none	None	Only venous	Venous
2	3.5	1.9	ADO II AS	5x2	none	None	Only venous	Venous
3	2.4	1.5	ADO II AS	3x2	none	Left pulmonary stenosis	Both arterial and venous	Venous
4	2.5	1.6	ADO II AS	3x4	none	None	Only venous	Venous
5	3	1.6	ADO II AS	4x2	none	None	Only venous	Venous
6	2.5	2	ADO II AS	4x4	none	None	Both arterial and venous	Venous
7	3	1.5	ADO II AS	4x4	none	Left pulmonary stenosis	Only venous	Venous
8	4.1	1.6	ADO II	5x6	none	None	Both arterial and venous	Venous
9	2.2	1.72	ADO II	3x4	none	None	Both arterial and venous	Venous
10	3	1.6	ADO I	5x4	none	None	Both arterial and venous	Venous
11	2.4	2	ADO I	5x4	none	None	Both arterial and venous	Venous
12	2.2	1.5	Cook coil	3x4	none	None	Both arterial and venous	Arterial
13	2.5	2.1	ADO II AS	3x2	none	Left pulmonary stenosis	Only venous	Venous
14	2.5	1.8	Cook Coil	5x3	none	None	Only venous	Venous
15	2	1.8	ADO II AS	4x2	none	None	Both arterial and venous	Venous
16	1.7	1.66	ADO II-AS	3x2	none	none	Only venous	Venous
17	2	1.69	ADO II-AS	4x4	none	Left pulmonary stenosis	Only venous	Venous
18*	4.5	2	ADOII	5x4	none	None	Both arterial and venous	Venous
19	2.5	2.1	ADO II-AS	4x5	none	none	Both arterial and venous	Venous

\*In the case 18, the device protruded to the aorta therefore it was taken. PDA was closed surgically

for 13 patients. We were able to decrease the ventilatory settings and finally extubated seven patients after the procedure but the remaining six remained intubated: one of them was weaned to continuous positive airway pressure (CPAP). The others continued due to chronic lung disorders, and two of them died. Ventilatory settings remained high for three patients for a long time and their oxygen requirement persisted. We discharged all these patients to their homes with oxygen. The longest period of hospitalization was 294 days. There was no procedure-related death, but in the follow-up period, two patients died because of associating diseases. One died one month after PDA closure because of severe lung problems and sepsis. The other died 50 days after PDA closure because of necrotizing enterocolitis, sepsis, and multiorgan failure. None of the patients required inotropic support before or at the time of the procedure.

## Discussion

In this study, we report our experience in transcatheter PDA closure of patients weighing less than 2 kg. This study is valuable because it includes the largest cohort of infants less than 2 kg in the literature whose PDA were closed percutaneously. Previously Backes et al. (5) reported PDA closure of babies smaller than 32 weeks of gestation. Total number of patients was 52 and only 13 of them were less than 2.5 kg (5). The incidence of PDA in term

infants has been reported to be approximately 1 in 2000 births (6). In premature babies, incidence varies between 40–60 % on the third day of life, depending on the estimated gestational age (7). Complications related to prematurity, such as bronchopulmonary dysplasia, intracranial hemorrhage, or necrotizing enterocolitis increase morbidity, mortality, and the duration of hospitalization. Therefore, early intervention is required in order to decrease the complications. Surgical closure of PDA is reserved for infants who do not respond to medical management. However, patients are at risk postoperatively for a significant decrease in LV output and hypoperfusion because of decreased LV preload and increased systemic vascular resistance (8). It has also been proposed that surgical ligation may contribute to brain injury due to intraoperative compromise of cerebral oxygen saturation and postoperative hemodynamic instability. There are reports suggesting that surgery impedes lung growth and neurologic development, increases the risk for bronchopulmonary dysplasia, and retinopathy of prematurity (ROP) (9–11). Interventional catheterization procedures are more commonly used because of the risks of surgery. The main advantages of percutaneous PDA closure are high success, low morbidity rate, short length of hospital stay, and less blood loss. Since the length of hospital stay decreases with catheterization, it is much more cost-effective than surgery. Previously coils and more recently Amplatzer duct occluders were used for percutaneous PDA closure, which

is a safe and effective treatment method. Proper device selection has an important role. The use of coils for ductal closure is cheaper when compared to other devices. However, the residual leak ratio is higher in large defects and lower in small ducti (12). In such cases, additional coils may be required that increase the duration of process, amount of fluoroscopy, and complication rate (13, 14). Amplatzer ductal occluders (ADO): ADO I and ADO II, are suitable for larger ducti and commonly used. In preterm and low birthweight infants, the main problems are the size of sheaths and protrusion of discs into the aorta and pulmonary artery. Therefore, new devices were developed to reduce this protrusion (ADO II-AS, St. Jude Medical, Plymouth, MN), with smaller angled retention disks and reduced occlusive materials to allow for a smaller profile and flexibility making delivery from the aortic or pulmonary side possible. In our study, we used the following types of devices: detachable coils (Cook Medical, Bloomington, IN) in 2 patients, ADO I in 2, ADO II in 3, and ADO II AS in 12 patients.

First, successful closures with ADO II-AS devices in eight small pigs were demonstrated by Bass and Wilson (15). Limited numbers of human studies concerning the use of this device are present. One of these reports is a multicenter study, which explains the percutaneous PDA closure with ADO II-AS device in children (16). They have explained that the ADO II AS device could be used for all types of PDA less than 4 mm in the children of different ages. Closure rates were checked with angiography and echocardiography. The success rate in the infants less than 6 kg was 87.5%, and 97% in those greater than 6 kg. Bruckheimer et al. (17) shared their large single center experience about the efficacy and safety of ADO II-AS in PDA closure (17). A total of 56/60 (93.3%) ADO II-AS devices were used successfully. It was found that PDA was closed in 55/56 (98.2%), on the next day. However, these studies represent procedures on older children and body weights over 2 kg. In the literature, there are usually individual case reports of percutaneous PDA closure in preterm infants and a limited number of studies. First, Roberts et al. (18) reported successful percutaneous PDA closure in 9 of 10 preterm infants. In this study, the body weights were over 2.5 kg and the diameter of the PDAs ranged between 2 to 3.6 mm. Our study differs in that a) the number of cases is more, b) body weights are less than 2 kg, and c) diameters of PDAs were larger (range 2.2 to 4.5 mm). Also, stenosis of left pulmonary artery (LPA) was observed in 5/9 infants in the study of Roberts et al. (18); whereas, we had LPA stenosis in four patients, and all of which resolved during follow-up probably as a result of utilization of new generation devices and proper device selection. A second study was done by Zahn et al. (19), and they closed PDA of six extremely low birth babies percutaneously. Complete closure succeeded in all patients without any major complications in that study. In the previous studies that compare the results of PDA ligation with percutaneous PDA closure, residual shunt rates have been higher in the catheter group (20). However, these data belonged to the earlier times when mostly coils were used for closure. Nowadays with

the improvement of devices, residual shunt rates have significantly decreased. In our study, PDA was closed successfully in 18 patients without residual shunting, protrusion, or obstruction. We did not observe any procedure related to major complications. The only untoward consequence was mild left pulmonary artery stenosis in four patients, and all of which resolved spontaneously in 6 months. With the introduction of better qualified devices and accumulation of experience, it has been possible to close the PDAs via only the venous route, further decreasing the risks of vascular complications related to arterial damage (occlusion, embolism, dissection, pseudoaneurysm formation, and bleeding). We also tried to do all the procedures as quick as possible and keep the procedure time as short as possible. As the time period of having sheaths elongates the chance of having vascular problems increase, this was probably why we did not face any vascular problems during or after the procedure. The major drawback of this approach is that we could not visualize angiographically before the release of the device. However, our experience showed that good echocardiographic imaging is enough for procedure safety.

During the echo imaging, we have checked for the obstruction of the descending aorta and both pulmonary arteries. In the literature, there are reports of PDA closure using only the venous route in children weighing less than 10 kg (21, 22). We have previously reported effective and reliable transvenous closure of PDA in selected cases with ADO I without femoral arterial access under the guidance of transthoracic echocardiography and aortogram in the return phase (23).

### Study limitations

Hospital stay after PDA closure is not recorded in our study. The number of patient was limited and it is a retrospective study. Also, we cannot rely on transthoracic echocardiography in the diagnosis of LPA stenosis; lung perfusion scans should be done on the follow-up. Another limitation of the study is that follow-up of the patients for the patency of femoral vessels with Doppler ultrasound was not done.

### Conclusion

Our study is clinically valuable as it is the first report to discuss the efficacy and safety of transcatheter PDA closure in babies less than 2 kg. Patients less than 2 kg are all preterms and they mostly have other medical problems rendering surgical procedures risky, where catheterization can be a safer option.

**Acknowledgements:** Our study does not bear any conflict. There is not any honorarium, grant, or payment given to any author of this manuscript. There is no external financial support.

**Conflict of interest:** None declared.

**Peer-review:** Externally peer-reviewed.

**Authorship contributions:** Concept – N.N.; Design – Ö.P.; Supervision – N.N., A.B.; Fundings – M.A.; Materials – Ö.P.; Data collection &/or processing – Ö.P.; Analysis and/or interpretation – A.Ö., Ö.P.; Literature search – A.Bayram., S.S.; Writing – Ö.P.; Critical review – K.Ü.

## References

1. Alan S, Karadeniz C, Okulu E Kılıç A, Erdeve O, Uçar T, et al. Management of patent ductus arteriosus in preterm infants: clinical judgment might be a fair option. *J Matern Fetal Neonatal Med* 2013; 26: 1850-4.
2. Ohlsson A, Walia R, Shah SS. Ibuprofen for the treatment of patent ductus arteriosus in preterm or low birth weight (or both) infants. *Cochrane Database Syst Rev* 2015; 2: CD003481.
3. Clyman RI. The role of patent ductus arteriosus and its treatments in the development of bronchopulmonary dysplasia. *Semin Perinatol* 2013; 37: 102-7.
4. Krichenko A, Benson LN, Burrows P, Moes CA, McLaughlin P, Freedom RM. Angiographic classification of the isolated, persistently patent ductus arteriosus and implications for percutaneous catheter occlusion. *Am J Cardiol* 1989; 63: 877-9.
5. Backes CH, Cheatham SL, Deyo GM, Leopold S, Smith CV, Garg V, et al. Percutaneous Patent Ductus Arteriosus (PDA) closure in very preterm infants: Feasibility and complications. *J Am Heart Assoc* 2012; 12: 5.
6. Rozé JC, Cambonie G, Marchand-Martin L. Association Between Early Screening for Patent Ductus Arteriosus and In-Hospital Mortality Among Extremely Preterm Infants. *JAMA* 2015; 313: 2441-8.
7. Evans N. Preterm patent ductus arteriosus: should we treat it? *J Paediatr Child Health* 2012; 48: 753-8.
8. El-Khuffash AF, Jain A, McNamara PJ. Ligation of the patent ductus arteriosus in preterm infants: understanding the physiology. *J Pediatr* 2013; 162: 1100-6.
9. Chang LY, McCurnin D, Yoder B, Shaul PW, Clyman RI. Ductus arteriosus ligation and alveolar growth in preterm baboons with a patent ductus arteriosus. *Pediatr Res* 2008; 63: 299-302.
10. Saldeño YP, Favareto V, Mirpuri J. Prolonged persistent patent ductus arteriosus: potential perdurable anomalies in premature infants. *J Perinatol* 2012; 32: 953-8.
11. Kabra NS, Schmidt B, Roberts RS, Doyle L, Papile A, Fanaroff, Neurosensory impairment after surgical closure of patent ductus arteriosus in extremely low birth weight infants: results from the Trial of Indomethacin Prophylaxis in Preterms. *J Pediatrics* 2007; 150: 229-34.
12. Chaurasia AK, Harikrishnan S, Bijulal S, Krishnamoorthy KM, Sivasankaran S, Tharakan JA. Usefulness of Doppler derived end-diastolic flow gradient across the patent ductus arteriosus in selecting coils for ductal occlusion. *Pediatr Cardiol* 2012; 33: 290-4.
13. Tomita H, Uemura S, Haneda N. Coil occlusion of PDA in patients younger than 1 year: risk factors for adverse events. *J Cardiol* 2009; 53: 208-13.
14. Sultan M, Ullah M, Sadiq N, Akhtar K, Akbar H. Transcatheter device closure of patent ductus arteriosus. *J Coll Physicians Surg Pak* 2014; 24: 710-3.
15. Bass JL, Wilson N. Transcatheter occlusion of the patent ductus arteriosus in infants—Experimental testing of a new amplatzer device. *Catheter Cardiovasc Interv* 2014; 83: 250-5.
16. Sungur M, Karakurt C, Özbarlas M, Başpınar O. Closure of Patent Ductus Arteriosus in Children, Small Infants, and Premature Babies with Amplatzer Duct Occluder II Additional Sizes: Multicenter Study. *Catheter Cardiovasc Interv* 2013; 82: 245-52.
17. Bruckheimer E, Godfrey M, Dagan T, Levinzon M. The Amplatzer Duct Occluder II Additional Sizes Device for Transcatheter PDA Closure: Initial Experience. *Catheter Cardiovasc Interv* 2014; 83: 1097-101.
18. Roberts P, Adwani S, Archer N, Wilson N. Catheter closure of the arterial duct in preterm infants. *Arch Dis Child Fetal Neonatal Ed* 2007; 92: 248-50.
19. Zahn EM, Nevin P, Simmons C, Garg R. A novel technique for transcatheter patent ductus arteriosus closure in extremely preterm infants using commercially available technology. *Catheter Cardiovasc Interv* 2015; 85: 240-8.
20. Baruteau AE, Hascoët S, Baruteau J, Boudjemline Y, Lambert V, Angel CY, et al. Transcatheter closure of patent ductus arteriosus: past, present and future. *Arch Cardiovasc Dis* 2014; 107: 122-32.
21. Kusa J, Raś M, Czeńiewicz P, Nahirny R. Less invasive percutaneous closure of persistent arterial duct in children below 10 kilos. *Postępy Kardioi Interwencyjnej* 2013; 9: 132-5.
22. Başpınar O, Şahin DA, Sulu A, İrdem A, Gökaslan G, Sivaslı E, et al. Transcatheter closure of patent ductus arteriosus in under 6 kg and premature infants. *J Interv Cardiol* 2015; 28: 180-9.
23. Baykan A, Narin N, Özyurt A, Argun M, Pamukçu O, Onan SH, et al. Do we need a femoral artery route for transvenous PDA closure in children with ADO-I?. *Anatol J Cardiol* 2015; 15: 242-7.