

high prevalence of sensitization in other countries, such as methylisothiazolinone, methyltribromo glutaronitrile, and cocamidopropyl betaine could be considered.

Financial support

None declared.

Authors' contributions

Ana Luiza Castro Fernandes Villarinho: Statistical analysis; design and planning of the study; drafting and editing of the manuscript; collection, analysis, and interpretation of data; intellectual participation in the propaedeutic and/or therapeutic conduct of the studied cases; critical review of the literature.

Maria das Graças Mota Melo: Drafting and editing of the manuscript; effective participation in research orientation; intellectual participation in the propaedeutic and/or therapeutic conduct of the studied cases; critical review of the literature; critical review of the manuscript.

Liliane Reis Teixeira: Statistical analysis; approval of the final version of the manuscript; effective participation in research orientation; critical review of the manuscript.

Conflicts of interest

None declared.

References

- Zaragoza-Ninet V, Encinas RB, Vilata-Corell JJ, Pérez-Ferriols A, Sierra-Talamantes C, Esteve-Martínez A, et al. Allergic contact dermatitis due to cosmetics: a clinical and epidemiological study in a tertiary hospital. *Actas Dermosifiliogr*. 2016;107:329–36.
- Boonchai W, Desomchoke R, Iamtharachai P. Trend of contact allergy to cosmetic ingredients in Thais over a period of 10 years. *Contact Derm*. 2011;65:311–6.
- Davies RF, Johnston GA. New and emerging cosmetic allergens. *Clin Dermatol*. 2011;29:311–5.
- Herman A, Aerts O, Montjoye L, Tromme I, Goossens A, Baeck M. Isothiazolinone derivatives and allergic contact dermatitis: a review and update. *J Eur Acad Dermatol Venereol*. 2019;33:267–76.
- Scherrer MAR, Rocha VB, Andrade ARC. Contact dermatitis to methylisothiazolinone. *An Bras Dermatol*. 2015;90:912–4.
- Murad A, Marren P. Prevalence of methylchloroisothiazolinone and methylisothiazolinone contact allergy in facial dermatitis: a single centre Irish study. *J Eur Acad Dermatol Venereol*. 2016;30:60–2.
- Cheng J, Zug KA. Fragrance allergic contact dermatitis. *Dermatitis*. 2014;25:232–45.
- Durán BE, Romero-Pérez D, Salvador JFS. Allergic contact dermatitis due to paraphenylenediamine: an update. *Actas Dermosifiliogr (Engl Ed)*. 2018;109:602–9.
- diariodasleis.com.br [Internet]. Osasco: Diário das Leis; c2022. Portal de Legislação – ANVISA. Resolução de Diretoria Colegiada Nº 15, de 26 de março de 2013. Aprova o regulamento técnico e lista as substâncias de uso cosmético: acetato de chumbo, pirogalol, formaldeído e paraformaldeído e dá outras providências. Diário Oficial da União mar 27, 2013. Available from: <https://www.diariodasleis.com.br/legislacao/federal/222613-lista-de-substancias-de-uso-cosmutico-aprova-o-regulamento-tucnico-lista-de-substancias-de-uso-cosmutico-acetato-de-chumbo-pirogalol-formaldeudo-e-paraformaldeudo-e-du-outr.html>.
- Johansen JD, Aalto-Korte K, Agner T, Andersen KE, Bircher A, Bruze M, et al. European Society of Contact Dermatitis guideline for diagnostic patch testing – recommendations on best practice. *Contact Derm*. 2015;73:195–221.

Ana Luiza Castro Fernandes Villarinho *,
Maria das Graças Mota Melo , Liliane Reis Teixeira 

Department of Work-related Dermatology, Centro de Estudos da Saúde do Trabalhador e Ecologia Humana, Escola Nacional de Saúde Pública Sergio Arouca, Fundação Oswaldo Cruz, Rio de Janeiro, RJ, Brazil

*Corresponding author.

E-mail: ana.villarinho@ensp.fiocruz.br (A.L. Villarinho).

Received 18 February 2021; accepted 11 June 2021
Available online 25 June 2022

<https://doi.org/10.1016/j.abd.2021.06.009>
0365-0596/ © 2022 Published by Elsevier España, S.L.U. on behalf of Sociedade Brasileira de Dermatologia. This is an open access article under the CC BY license (<http://creativecommons.org/licenses/by/4.0/>).

Dermoscopic characteristics of congenital melanocytic nevi in a cohort study in southern Brazil[☆]



Dear Editor,

Congenital melanocytic nevi (CMN) are benign proliferations of melanocytes present at birth or which appear during the first two years of life.¹ They are classically classified

according to their largest diameter, as small (less than 1.5 cm), medium (between 1.5–20 cm), and large or giant (greater than 20 cm).² Larger lesions are more frequently associated with the development of melanoma and have a higher risk of extracutaneous complications (neurocutaneous melanocytosis). Regarding malignancy, prospective studies have established that the overall incidence of melanomas in CMN is low (1%–2%). However, this incidence varies greatly according to the phenotype severity.^{3–5}

Digital dermoscopy is a noninvasive test. The knowledge of dermoscopic characteristics is important so that this method can be used for patient diagnosis, follow-up, and management. There are few studies evaluating the evolution of the dermoscopic pattern of these nevi over time

[☆] Study conducted at the Universidade Federal de Ciências da Saúde de Porto Alegre, Porto Alegre, RS, Brazil.



Figure 1 Brownish macula on dermoscopy showing a typical reticular pattern.

and its association with clinical and epidemiological characteristics. There is no standardization regarding the ideal period between assessments.^{4,6-9} The aim of the present study was to assess the clinical and dermoscopic characteristics of patients with CMN, comparing the dermoscopic findings at two medical consultations.

A retrospective cohort study was carried out to analyze the medical and photographic records obtained with digital videodermoscopy (Fotofinder Systems, GmbH, Bad Birnbach, Germany) of patients with CMN referred to the Dermoscopy Sector of a reference service in southern Brazil between 2016 and 2018. Data were collected on the patients general health status, dermatological anamnesis, the evolution of the congenital lesions, and stored macroscopic and microscopic photographic records. The description of variables and possible associations between clinical and dermoscopic aspects were verified.

The results were presented as central tendency measures (mean and median) and variability (standard deviation and interquartile range), in addition to absolute and relative distribution (n, %). The symmetry of continuous distributions was evaluated using the Kolmogorov-Smirnov test; Pearson's chi-square test (χ^2) was used for the bivariate analysis of the qualitative variables.

Dermoscopic data were analyzed by two experienced evaluators and were based on the analysis of patterns classified as reticular (Fig. 1), globular (Fig. 2), homogeneous, reticular-homogeneous, globular homogeneous, reticular-globular, and acral patterns (parallel ridges or furrows, fibrillar, lattice and homogeneous). The evaluation was performed in two ways: a descriptive analysis of dermoscopic data of all lesions (those with only one record and those with follow-up; n = 82) and a comparative analysis of dermoscopic data of lesions that were followed over time. (n = 70). Both authors analyzed all recorded lesions and the final diagnostic definitions were attained by consensus. McNemar's test was used to compare the data. The present study was approved by the Research Ethics Committee of the institution.

Eighty-two CMN were observed in 72 patients. Most individuals were phototype III (62.5%), had dark brown/black eyes (67.6%); medium/dark brown hair (38.9%) and 45.1% of the lesions were located on the extremities. Most lesions were small (58.5%; Table 1). The reticular pattern was the predominant dermoscopic pattern (31.7%), with the pigment network being the most common dermoscopic structure

Table 1 Clinical and epidemiological characterization of patients with congenital melanocytic nevi (n = 72).

Variable	Total sample (n = 72)	
	n	%
Sex		
Male	30	41.7
Female	42	58.3
Age (years)		
Mean \pm standard deviation (range)	27.2 \pm 21.9 (1.0–76)	
Median (1 st –3 rd quartile)	16.0 (10.3–43.7)	
Phototype		
II	6	8.3
III	45	62.5
IV	16	22.2
V	4	5.6
VI	1	1.4
Eye color		
Dark brown/black	48	67.6
Light brown/hazel	13	18.3
Light green	5	7.0
Blue	5	7.0
Skin color/ethnicity		
White	63	87.5
Brown	7	9.7
Black	2	2.8
Hair color		
Black	22	30.6
Dark/medium brown	28	38.9
Light brown	15	20.8
Blond	7	9.7
Sunburns		
Never	33	45.8
Once or more	39	54.2
Use of sunscreen		
Never	5	6.9
Occasionally	59	81.9
Always/daily	8	11.1
Family history of skin cancer		
No	54	75.0
Yes	18	25.0
Number of CMN		
More than one	9	12.5
One	63	87.5
Location of the main CMN		
Head and neck	7	8.5
Trunk	33	40.3
Extremities	37	45.1
Gluteal region	3	3.7
Inguinal region	2	2.4
Classification of the main CMN		
Small	48	58.5
Medium-sized	30	36.6
Large/Giant	4	4.9
Recent modification		
No	65	90.3
Yes	7	9.7
Histopathological evaluation		
No	68	94.4
Yes	4	0.6

Table 2 Dermoscopic pattern of congenital melanocytic nevi (n = 82).

Characteristics	Lesions assessed only once (n = 82) Before		Lesions with follow-up (n = 70)				p ^b
	n	%	After		n	%	
Dermoscopic pattern							
Reticular	26	31.7	23	32.9	23	32.9	>0.999
Globular	14	17.1	12	17.1	12	17.1	
Reticulo-globular	12	14.6	9	12.9	9	12.9	
Homogeneous	17	20.7	15	21.4	15	21.4	
Reticular-homogeneous	12	14.6	11	15.7	11	15.7	
Parallel ridge	1	1.2					
Color							
Light brown	60	73.2	54	77.1	54	77.1	0.815
Dark brown	62	75.6	54	77.1	53	75.7	0.869
Black ^a	3	3.7	1	1.4	1	1.4	>0.999
Red ^a	4	4.9	3	4.3	3	4.3	>0.999
Blue ^a					1	1.4	>0.999
White ^a	3	3.7	2	2.9	2	2.9	>0.999
Blue-gray	7	8.5	6	8.6	6	8.6	>0.999
Color symmetry^a							
Yes	77	93.9	65	95.6	65	95.6	>0.999
No	5	6.1	3	4.4	3	4.4	
Symmetry of structures							
Yes	76	92.7	66	94.3	66	94.3	>0.999
No	6	7.3	4	5.7	4	5.7	
Pigment network							
Yes	58	70.7	49	70.0	49	70.0	>0.999
No	24	29.3	21	30.0	21	30.0	
Dots							
Yes	49	59.8	41	58.6	41	58.6	>0.999
No	33	40.2	29	41.4	29	41.4	
Globules							
Yes	51	62.2	45	64.3	45	64.3	>0.999
No	31	37.8	25	35.7	25	35.7	
Striae							
No	82	100.0	70	100.0	70	100.0	-
Irregular striae							
No	82	100.0	70	100.0	70	100.0	-
Structureless areas							
Yes	9	11.0	6	8.6	6	8.6	>0.999
No	73	89.0	64	91.4	64	91.4	
Regression^a							
Yes	1	1.2	1	1.4	1	1.4	>0.999
No	81	98.8	68	98.6	68	98.6	
Hyperchromic macules							
Yes	3	3.7	2	2.9	2	2.9	>0.999
No	79	96.3	68	97.1	68	97.1	
Pseudocysts							
Yes	5	6.1	5	7.1	5	7.1	>0.999
No	77	93.9	65	92.9	65	92.9	
Perifollicular hyperpigmentation^a							
No	82	100.0	69	100.0	69	100.0	-
Perifollicular hypopigmentation							
Yes	19	23.2	19	27.1	18	25.7	0.978
No	63	76.8	51	72.9	52	74.3	
Hypertrichosis							
Yes	19	23.2	15	21.4	14	20.0	>0.999
No	63	76.8	55	78.6	56	80.0	

Table 2 (Continued)

Characteristics	Lesions assessed only once (n = 82)		Lesions with follow-up (n = 70)				p ^b
	n	%	After		n	%	
			n	%			
Blue-gray veil							
No	82	100.0	70	100.0	70	100.0	-
Vascular structures							
Yes	1	1.2	1	1.4	1	1.4	>0.999
No	81	98.8	69	98.6	69	98.6	
Shiny white structures^a							
No	82	100.0	69	100.0	69	100.0	-
Negative pigment network^a							
Yes	4	4.9	4	5.8	4	5.8	>0.999
No	78	95.1	65	94.2	65	94.2	

^a Missing data – Black color, Red color, blue color, white color, regression, perifollicular hyperpigmentation; shiny white structures, pigment network, atypical vascular pattern (1 [1.6%]); color symmetry, globules (2 [3,2]).

^b McNemar-Bowker Test.

Table 3 Dermoscopic characteristics and follow-up interval.

Characteristics	Time of interval - months (n = 70)						p ^b		
	Up to 10 months (n = 47)				>10 months (n = 23)				
	Before		After		Before			After	
	n	%	n	%	n	%		n	%
Dermoscopic pattern									
Reticular	15	31.9	15	31.9	8	34.8	8	34.8	-
Globular	9	19.1	9	19.1	3	13.0	3	13.0	
Reticulo-globular	5	10.6	5	10.6	4	17.4	4	17.4	
Homogeneous	8	17.0	8	17.0	7	30.4	7	30.4	
Reticular-homogeneous	10	21.3	10	21.3	1	4.3	1	4.3	
Homogeneous pattern									>0.999
Yes	19	40.4	19	40.4	8	34.8	9	39.1	
No	28	59.6	28	59.6	15	65.2	14	60.9	
Color symmetry^a									
Yes	44	93.6	43	93.5	23	100.0	22	100.0	-
No	3	6.4	3	6.5					
Structure symmetry									
Yes	45	95.7	45	95.7	21	91.3	21	91.3	-
No	2	4.3	2	4.3	2	8.7	2	8.7	
Pigment network									
Yes	34	72.3	34	72.3	15	65.2	15	65.2	-
No	13	27.7	13	27.7	8	34.8	8	34.8	
Dots									
Yes	24	51.1	24	51.1	17	73.9	17	73.9	-
No	23	48.9	23	48.9	6	26.1	6	26.1	
Globules									
Yes	30	63.8	30	63.8	15	65.2	15	65.2	-
No	17	36.2	17	36.2	8	34.8	8	34.8	

^a Missing data – Pigment network, Color symmetry, globules (2 [3,2%]).

^b McNemar-Bowker Test.

(70.7%; Table 2). The comparison between the first and the last clinical and dermoscopic examinations included 70 lesions, with a mean interval between them of 12.49 months and a median of 10 months (1st-3rd quartile: 8.0-12.0), with

the minimum period between the two assessments being 4 months and a maximum of 21 months. No morphological and structural differences were detected at the follow-up ($p > 0.05$; Table 3).

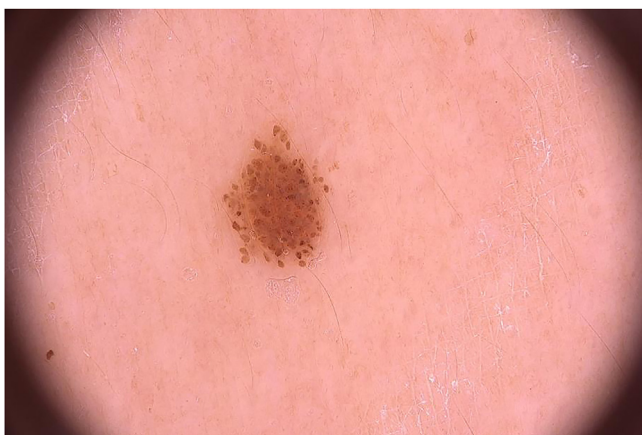

Figure 2 Small brownish papule on dermoscopy showing a typical globular pattern.

The lesions of four patients were submitted to histopathological analysis. The indications in these cases were as follows: the presence of a central papule in a medium-sized CMN located on the right shoulder of a 10-year-old patient, the presence of a central papule in a small lesion located on the fifth left toe of a 10-year-old patient, a satellite lesion in a patient with a large CMN located on the lumbar region and a lesion with structure asymmetry and a homogeneous pattern with predominant blue-gray color, located on the left thigh of a 10-year-old patient. All histopathological diagnoses were of compound melanocytic nevi. None of the assessed patients developed melanoma. Of the four patients with large/giant CMN included in the study, three had an indication for imaging examination and two had already undergone nuclear magnetic resonance with normal results.

Some studies have sought to describe specific dermoscopic features of CMN. Light brown globules with a central dot (target globules), target pigment network, focal pigment network thickening, perifollicular/focal hypopigmentation, and target vessels have been described as characteristics present in congenital lesions, although they were not specific. In the case of lesions that must be monitored over time, digital dermoscopy appears as an important tool. There are only a few studies describing the evolution and comparison of the dermoscopic features of these lesions and their correlations with the histopathological diagnoses.¹⁰ Regarding the clinical data of patients in the present study, it was observed that small nevi predominated, a result consistent with other published data.^{8,9} The predominant dermoscopic pattern was the reticular one, regardless of the nevus location, unlike the data found in the literature, which found the globular pattern to be the most common. When comparing the predominant dermoscopic pattern with age, it was observed that the globular pattern was related to patients younger than 12 years, whereas the reticular pattern was related to those over this age, corroborating the data found in the literature.^{10,11}

A recent study found characteristics of atypical nevi present in CMN, such as radiating striae, focal hypopigmentation, atypical globules and blotches, regression, and blue-gray veil. In the present study, the authors did not find striae nor blue-gray veils; the vast majority of glob-

ules were typical, and regression was observed in only one lesion.¹⁰

In addition to the difficulty in the follow-up of patients, there is difficulty regarding the long follow-up time, necessary for any changes to appear. The present study sought to evaluate the dermoscopic characteristics and their changes during videodermoscopy follow-up and correlate them to biopsy indications and histopathological results. Using descriptive data, the clinical and dermoscopic characteristics of the CMN in the initial evaluation of the patients were demonstrated.

When comparing the images recorded in the initial and final evaluations, it was observed that there were no significant differences in the studied period. One of the limitations is the reduced follow-up time (mean of 12 months) since many of the expected outcomes (clinical and dermoscopic changes that indicate lesion excision, and the infrequent presence of malignancy) generally develop after many years. Another limitation is the diversity of the studied population, including children and adults, considering that lesions tend to be stable in the latter. The relatively small number of patients (72) is also one of the limiting factors.

The present study obtained results that allow the clinical and dermoscopic characterization of patients with CMN, although studies with a larger sample size and a longer follow-up interval are necessary to demonstrate the real benefit of digital dermoscopy when monitoring these lesions over time.

Financial support

None declared.

Authors' contributions

Camila Roos Mariano da Rocha: Statistical analysis; approval of the final version of the manuscript; design and planning of the study; drafting and editing of the manuscript; collection, analysis, and interpretation of data; intellectual participation in the propaedeutic and/or therapeutic conduct of the studied cases; critical review of the literature; critical review of the manuscript.

Thais Corsetti Graziotin: Design and planning of the study; drafting and editing of the manuscript; collection, analysis, and interpretation of data; effective participation in research orientation; intellectual participation in the propaedeutic and/or therapeutic conduct of the studied cases; approval of the final version of the manuscript.




Renan Rangel Bonamigo: Statistical analysis; design and planning of the study; drafting and editing of the manuscript; collection, analysis, and interpretation of data; effective participation in research orientation; intellectual participation in the propaedeutic and/or therapeutic conduct of the studied cases; approval of the final version of the manuscript.

Conflicts of interest

None declared.

References

- Caccavale S, Calabrese G, Mattiello E, Broganelli P, Ramondetta A, Pieretti G, et al. Cutaneous melanoma arising in congenital melanocytic nevus: a retrospective observational study. *Dermatology*. 2020;14:1–6.
- Kopf AW, Bart RS, Hennessey P. Congenital nevocytic nevi and malignant melanomas. *J Am Acad Dermatol*. 1979;1:123–30.
- Wu PA, Mancini AJ, Marghoob AA, Frieden IJ. Simultaneous occurrence of infantile hemangioma and congenital melanocytic nevus: coincidence or real association? *J Am Acad Dermatol*. 2008;58 Suppl:S16–22.
- Tannous ZS, Mihm Jr MC, Sober AJ, Duncan LM. Congenital melanocytic nevi: clinical and histopathologic features, risk of melanoma, and clinical management. *J Am Acad Dermatol*. 2005;52:197–203.
- Zaal LH, Mooi WJ, Klip H, Horst CMAM. Risk of malignant transformation of congenital melanocytic nevi: a retrospective nationwide study from The Netherlands. *Plast Reconstr Surg*. 2005;116:1902–9.
- Sahin S, Levin L, Kopf AW, Rao BK, Triola M, Koenig K, et al. Risk of melanoma in mediumsized congenital melanocytic nevi: a follow-up study. *J Am Acad Dermatol*. 1998;39:428–33.
- Seidenari S, Martella A, Pellacani G. Polarized light-surface microscopy for description and classification of small and mediumsized congenital melanocytic naevi. *Acta Derm Venereol*. 2003;83:1–6.
- Fernandes NC, Machado JLR. Estudo clínico dos nevos melanocíticos congênitos na criança e no adolescente. *An Bras Dermatol*. 2009;84:129–35.
- Cengiz FP, Emiroglu N, Ozkaya DB, Su O, Onsun N. Dermoscopic features of small, medium, and large-sized congenital melanocytic nevi. *Ann Dermatol*. 2017;29:26–32.
- Changchien L, Dusza SW, Agero ALC, Korzenko AJ, Braun RP, Sachs D, et al. Age- and site-specific variation in the dermoscopic patterns of congenital melanocytic nevi: an aid to accurate classification and assessment of melanocytic nevi. *Arch Dermatol*. 2007;143:1007–14.
- Stefanaki C, Soura E, Stergiopoulou A, Kontochristopoulos G, Katsarou A, Potouridou I, et al. Clinical and dermoscopic characteristics of congenital melanocytic naevi. *J Eur Acad Dermatol Venereol*. 2018;32:1674–80.

Camila Roos Mariano da Rocha  a,*
Thais Corsetti Graziotin  b,
Renan Rangel Bonamigo  a,c,d

^a Universidade Federal de Ciências da Saúde de Porto Alegre, Porto Alegre, RS, Brazil

^b Escola de Medicina, Pontifícia Universidade Católica do Rio Grande do Sul, Porto Alegre, RS, Brazil

^c Faculdade de Medicina, Universidade Federal do Rio Grande do Sul, Porto Alegre, RS, Brazil

^d Dermatology Service, Irmandade Santa Casa de Misericórdia de Porto Alegre, Porto Alegre, RS, Brazil

* Corresponding author.

E-mail: camilamarianodarocha@gmail.com (C.R. Rocha).

Received 25 November 2020; accepted 20 March 2021

Available online 22 July 2022

<https://doi.org/10.1016/j.abd.2021.03.016>
0365-0596/ © 2022 Published by Elsevier España, S.L.U. on behalf of Sociedade Brasileira de Dermatologia. This is an open access article under the CC BY license (<http://creativecommons.org/licenses/by/4.0/>).

Dermoscopy and ultrasonography of Kaposi's sarcoma nodules: new insights to guide intralesional chemotherapy?[☆]



Dear Editor,

Kaposi's Sarcoma (KS) is a rare, Human Herpes Virus 8 (HHV-8) associated angioproliferative low-grade mesenchymal neoplasm, characterized by cutaneous patches, plaques, and nodules.¹

Dermoscopy and Ultrasonography (US) are useful complementary techniques in the study of KS lesions,^{2,3} the latter also providing valuable guidance for intralesional treatment.⁴ Correlation between dermoscopic, and ultrasonographic findings has not been reported in KS. Herein, we describe two cases of treatment-naïve, medium-to-large-

sized KS nodules with complex architectural and vascular features, assessed by means of dermoscopy, and the US. We speculate that non-invasive recognition of complex KS lesional structure may aid in the adequate management of intralesional chemotherapy.

Patient 1

An eighty-two-year-old male with biopsy-proven, long-standing, classic KS and an otherwise unremarkable medical history complained of a newly formed lesion on the left heel, clinically appearing as a violaceous 9 × 6 mm nodule, with a peripheral scaly collarette. Dermoscopy showed two violaceous, large vascular areas separated by a white grayish structureless area (Fig. 1a–b). At the B-mode examination, the lesion presented an oval hypoechoic structure with well-demarcated edges and with an inner median normoechoic septum delimitating two separate subunits. Color Doppler examination revealed that the subunits were supplied by two different blood vessels. Moreover, their blood flow did

[☆] Study conducted at the Dermatology Unit of Fondazione IRCCS Ca' Granda Ospedale Maggiore Policlinico in Milan, Italy.