




Clinical intra-cardiac 4D flow CMR: acquisition, analysis, and clinical applications

Ahmet Demirkiran ¹, **Pim van Ooij**², **Jos J.M. Westenberg**³, **Mark B.M. Hofman**⁴, **Hans C. van Assen**³, **Linda J. Schoonmade**⁵, **Usman Asim**¹, **Carmen P.S. Blanken**², **Aart J. Nederveen**², **Albert C. van Rossum**¹, and **Marco J.W. Götte**^{1*}

¹Department of Cardiology, Amsterdam UMC, Vrije Universiteit Amsterdam, Amsterdam Cardiovascular Sciences, De Boelelaan 1117, 1081 HV, Amsterdam, The Netherlands; ²Department of Radiology, Amsterdam UMC, University of Amsterdam, Meibergdreef 9, 1105 AZ, Amsterdam, The Netherlands; ³Department of Radiology, Leiden University Medical Center, Albinusdreef 2, 2333 ZA, Leiden, The Netherlands; ⁴Department of Radiology and Nuclear Medicine, Amsterdam UMC, Vrije Universiteit Amsterdam, De Boelelaan 1117, 1081 HV, Amsterdam, The Netherlands; and ⁵Medical Library, Amsterdam UMC, Vrije Universiteit Amsterdam, De Boelelaan 1117, 1081 HV, Amsterdam, The Netherlands

Received 6 November 2020; editorial decision 15 May 2021; accepted 25 May 2021; online publish-ahead-of-print 18 June 2021

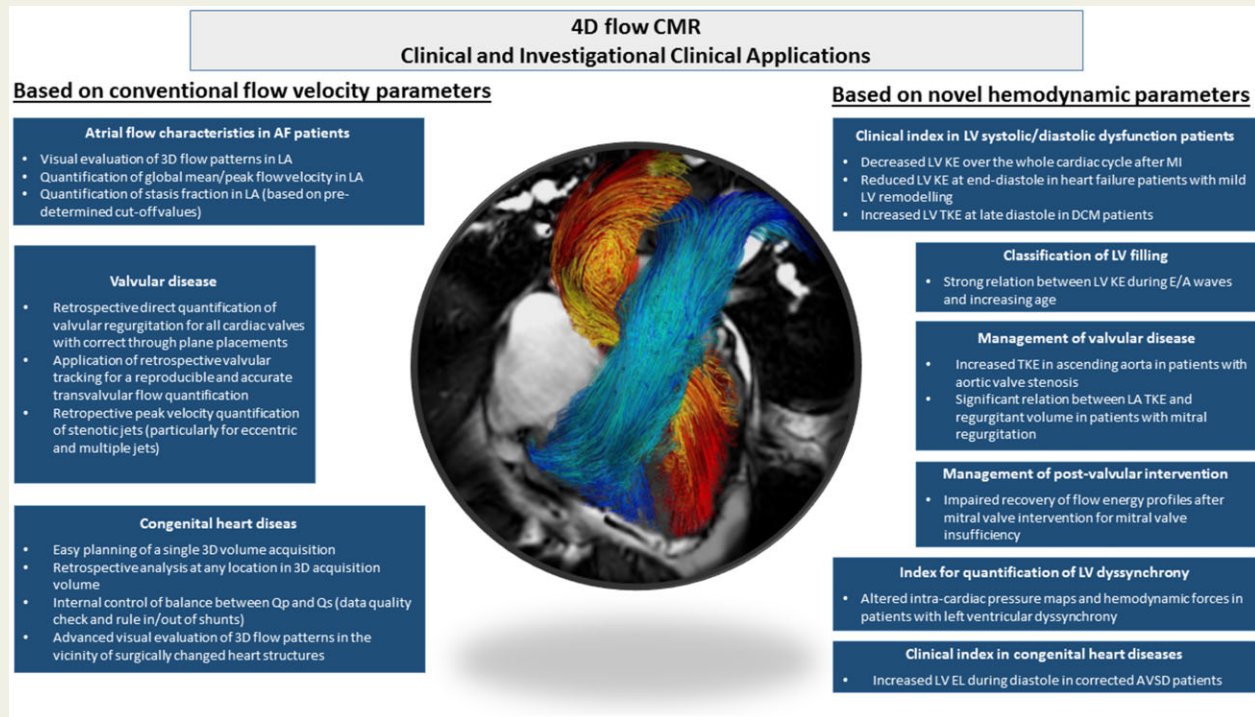
Identification of flow patterns within the heart has long been recognized as a potential contribution to the understanding of physiological and pathophysiological processes of cardiovascular diseases. Although the pulsatile flow itself is multi-dimensional and multi-directional, current available non-invasive imaging modalities in clinical practice provide calculation of flow in only 1-direction and lack 3-dimensional volumetric velocity information. Four-dimensional flow cardiovascular magnetic resonance imaging (4D flow CMR) has emerged as a novel tool that enables comprehensive and critical assessment of flow through encoding velocity in all 3 directions in a volume of interest resolved over time. Following technical developments, 4D flow CMR is not only capable of visualization and quantification of conventional flow parameters such as mean/peak velocity and stroke volume but also provides new hemodynamic parameters such as kinetic energy. As a result, 4D flow CMR is being extensively exploited in clinical research aiming to improve understanding of the impact of cardiovascular disease on flow and vice versa. Of note, the analysis of 4D flow data is still complex and accurate analysis tools that deliver comparable quantification of 4D flow values are a necessity for a more widespread adoption in clinic. In this article, the acquisition and analysis processes are summarized and clinical applications of 4D flow CMR on the heart including conventional and novel hemodynamic parameters are discussed. Finally, clinical potential of other emerging intra-cardiac 4D flow imaging modalities is explored and a near-future perspective on 4D flow CMR is provided.

*Corresponding author. Tel: +31 20 444 0123; Fax: +31 20 4442446, Email: m.j.w.gotte@amsterdamumc.nl

© The Author(s) 2021. Published by Oxford University Press on behalf of the European Society of Cardiology.

This is an Open Access article distributed under the terms of the Creative Commons Attribution Non-Commercial License (<http://creativecommons.org/licenses/by-nc/4.0/>), which permits non-commercial re-use, distribution, and reproduction in any medium, provided the original work is properly cited. For commercial re-use, please contact journals.permissions@oup.com

Graphical Abstract



Keywords

4D flow cardiovascular MRI • clinical • flow • velocity • kinetic energy

Introduction

Reliable analysis of blood flow carries a great importance for the accurate interpretation and management of cardiovascular diseases. Available non-invasive imaging modalities in clinical practice allow for calculation of velocity in only 1-direction and lack 3-dimensional (3D) volumetric velocity information. This prohibits a critical assessment of blood flow in cardiac cavities and great vessels, since the flow is multi-dimensional and multi-directional.¹

Four-dimensional flow cardiovascular magnetic resonance imaging (4D flow CMR) has been introduced as a novel tool for visualization and quantification of flow within the heart and major blood vessels.² This technique allows for simultaneous velocity encoding in all three directions and provides 3D volumetric information resolved over time (4D = 3 spatial dimensions + time). Initial 4D flow CMR clinical and research applications mainly focused on major blood vessels due to straightforward morphology and relatively low amount of dynamic deformation over the cardiac cycle. Of note, recent technical improvements in the technique have led to significant improvements in dynamic cardiac chamber segmentation over the cardiac cycle. As a result, a large amount of data have been recently mounted in the literature regarding intra-cardiac 4D flow CMR applications. In particular, in addition to intra-cardiac flow examination with conventional flow parameters such as mean/peak velocity and stroke volume,³ an increasing number of 4D flow data derived novel hemodynamic

parameters [e.g. kinetic energy (KE)] have been recently introduced.^{4,5} These novel parameters have provided valuable insights particularly into cardiac energetics. Moreover, a large variety of analysis tools became available for 4D flow data analysis. However, a standard post-processing approach is missing, which impacts interpretation and limits clinical adoption.

The aim of this review is to serve as a guide for clinicians who consider using intra-cardiac 4D flow CMR in clinical practice and for research. In the first part, the 4D flow acquisition and analysis processes are briefly discussed. In the second part, clinical applications of 4D flow CMR regarding cardiac diseases are discussed with emphasis on novel hemodynamic parameters. Finally, 4D flow imaging potential of other modalities (e.g. echocardiography) is reviewed and a near-future perspective on 4D flow CMR is provided.

Acquisition

Data acquisition

The 4D flow CMR data acquisition is based on the ECG-gated phase-contrast (PC) technique including time-resolved spoiled gradient echo pulse sequences.⁶ The retrospective ECG-gating is preferable, as the prospective-gating does not integrate the entire cardiac cycle and consequently, the evaluations of the late-diastolic mitral flow and diastolic function are compromised. Motion suppression is essential,

since the image quality is significantly reduced with respiratory motion.⁷ Compensation for respiratory motion-related artefacts can be achieved by using bellows reading, navigator gating of the diaphragm motion, or recently introduced self-gating techniques which provide the unique advantage of using the raw k-space data itself.⁸ The 4D flow CMR data acquisition may be performed after contrast administration. Although this procedure presents the advantage of increased signal-to-noise ratio (SNR), the influence of contrast agents on data acquisition may vary according to the duration from contrast agent administration.

Duration of acquisition

Despite application of acceleration techniques, 4D flow image acquisition is still time consuming (up to 15 min). Important acceleration approaches include parallel imaging,⁹ compressed sensing,¹⁰ and non-Cartesian trajectory techniques.¹¹ However, acceleration of the image acquisition impacts essential scan parameters such as SNR, spatial and temporal resolution. For this reason, a 4D flow CMR consensus report introduced reference acquisition and reconstruction values such as <40 ms for temporal resolution and $3.0 \times 3.0 \times 3.0 \text{ mm}^3$ for spatial resolution.¹ More recently, recommended values regarding use of 4D flow CMR in congenital heart disease (CHD) were reported.¹² Although a combination of acceleration techniques may provide effectively reduced scanning time, one should be cautious since such techniques may impact the efficiency of the other one. The performances of the acceleration techniques may vary in terms of susceptibility to artefacts, image quality, and consistency of intra-cardiac flow quantifications. Nonetheless, recent research reported feasible error ratios (<8%) for commonly applied acceleration techniques compared to phantom models.¹³ Finally, to compensate the loss in SNR due to the use of accelerated acquisition techniques, high field strength magnetic resonance imaging (MRI) systems (e.g. 3 Tesla) can be employed,¹⁴ yet the field strength may affect the quantification of the parameters including novel hemodynamic parameters.

Sources of errors

Several sources of error impact the quality and accuracy of 4D flow data and require correction prior to flow visualization and quantification. Similar to other types of PC CMR methods, the major sources of errors comprise concomitant gradient field effects (Maxwell terms), gradient field non-linearity, Eddy current effects, and phase wraps. It is important to note that correction methods for background phase offsets may vary according to MRI systems, sequences, protocol, and region of interest. While some MRI vendors provide correction for concomitant gradient field effects during standard reconstruction, additional correction is often required to improve analysis.

Velocity encoding

Similar to 2D PC-CMR, the sensitivity of velocity encoding (Venc) should be set by the operator prior to the image acquisition as $\sim 10\%$ higher than the maximum expected velocity. If the Venc is set too high, this causes a decreased SNR, while too low Venc leads to aliasing artefacts. Since the prediction of the maximum velocity is not feasible for every case, regular use of an anti-aliasing algorithm is recommended, as well.¹ A 2D velocity sensitivity scout can also be helpful to avoid velocity aliasing. For cardiovascular conditions featuring a wide range of flow velocities such as valvular diseases associated with

stenotic/regurgitant flow, setting multiple Vencs may help to assess the whole velocity spectrum.¹⁵ However, this approach is not very practical due to a significant increase in acquisition time (e.g. 15 min).

Visualization

3D phase-contrast MR angiography can be derived from 4D flow CMR data for orientation and visualization.¹⁶ 4D flow CMR visualization can also be fused with balanced steady-state free precession cine images to guide anatomic orientation. The most commonly used 4D flow visualization techniques are streamlines and pathlines.¹ The magnitude of velocity can be represented by colour-coding or adjustment of the vector size, or both. Streamlines are instantaneous traces tangent to the local velocity vectors demonstrating the blood flow directions at specific time points,¹⁷ as shown in *Figure 1* and [Supplementary data online, Video S1a–f](#). Time-resolved pathlines represent a path followed by a virtual massless particle over time¹⁸ and thus visualize the temporal course of flow over time. Using pathline visualization, separate components of left ventricular inflow (e.g. inflow leaves the ventricle within one cardiac cycle) were demonstrated.¹⁹ Pathlines in combination with streamlines allow identification of through-plane placements for quantification in complex flow patterns.²⁰

Analysis tools

Today, 4D flow CMR acquisition sequences are available across all major vendors (i.e. Siemens, GE, Philips). Recently, a wide range of comprehensive analysis tools emerged providing visualization and quantification of the various parameters. The non-standardized structure of these analysis tools appears as an important problem slowing down transition towards regular clinical use. We provide detailed information regarding the variability, citation frequency, and current functionality of the available analysis tools based on clinical intra-cardiac 4D flow CMR studies, in a supplemental file. The majority of the analysis tools offer a dedicated 4D flow CMR data visualization and analysis [e.g. Segment-Medviso, Mass, GTFlow (gyrotools), Arterys, CAAS MR (Pie Medical Imaging), cvi42 (Circle Cardiovascular Imaging, MEVISFlow)]. It should be noted that provided analysis regions (e.g. vascular, intra-cardiac) and properties substantially differ between the packages. For instance, a package may not offer aortic evaluation, while another lacks valvular flow quantification. Furthermore, some platforms are involved in 4D flow CMR data analysis through in-house programming (e.g. Matlab, EnSight, Mimics-Materialize, Paraview, ITK-SNAP, R'-Tech, FourFlow). These analysis tools are generally implemented for correction of the technical artefacts such as background phase offset errors, visualization, and segmentation of the region of interest. *Figure 2* summarizes the visual and quantitative analysis process of 4D flow CMR in a conceptual manner.

Clinical relevance of 4D flow CMR in intra-cardiac diseases

Atrial flow characteristics in patients with atrial fibrillation

Thromboembolic events in atrial fibrillation (AF) are mainly attributed to embolism of the thrombus originating from the left atrium

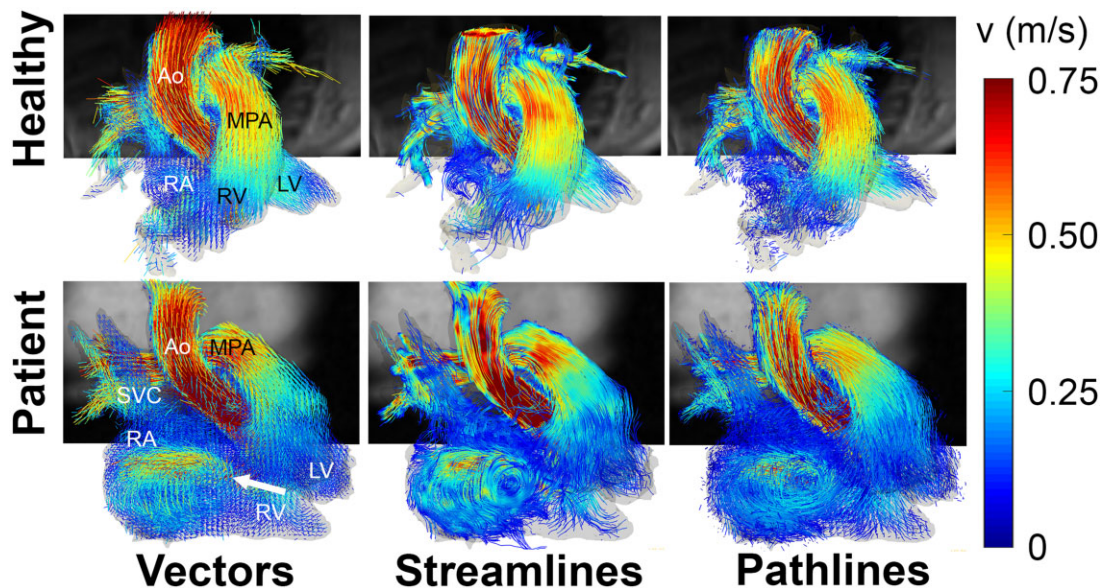


Figure 1 3D blood flow visualization with 4D flow CMR. 3D blood flow visualization on the whole heart is shown during mid-systole in a 28-year-old healthy male (top) and a 52-year-old female patient with tricuspid regurgitation (white arrow) after ventricular septal defect repair. Vectors, streamlines, and pathlines are illustrated from left to the right. Ao, aorta; MPA, main pulmonary artery; RA, right atrium; SVC, superior vena cava.

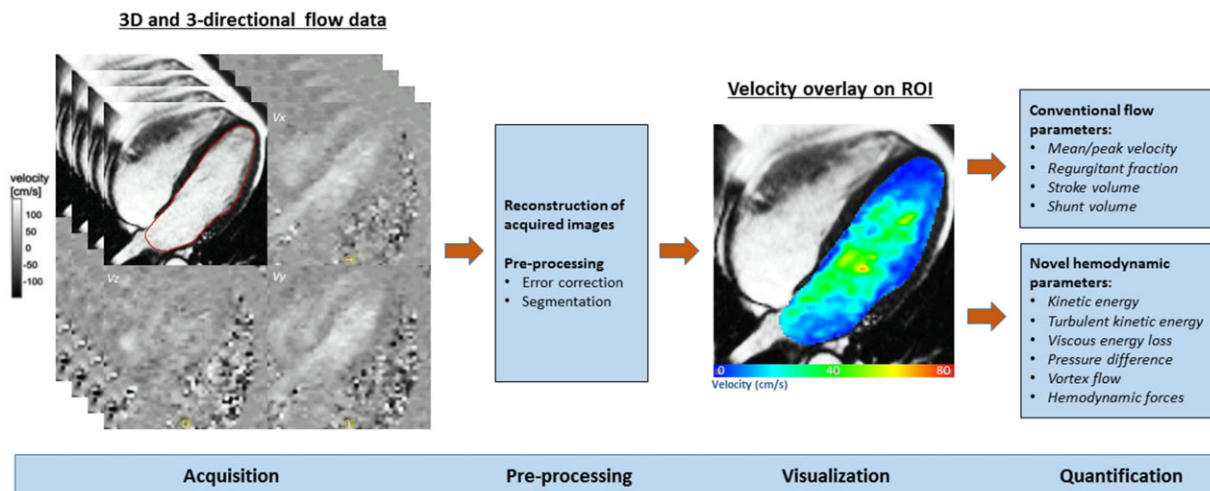


Figure 2 Overview of 4D flow CMR acquisition and analysis process. A typical workflow for 4D flow CMR data acquisition and analysis is demonstrated using images of a healthy volunteer (33-year-old male). On the left side, the acquisition of images in 3-direction (x, y, z) in a 3-dimensional volume of interest is displayed through flow velocity and magnitude images. Thereafter, acquired images are reconstructed and sequence-specific errors are corrected either manually or automatically. The segmentation is performed to determine the region of interest for visualization and quantification. In the middle-right, velocity overlay on the left ventricle and atrium during early diastole was illustrated. On the right side, conventional and novel hemodynamic parameters which can be generated through 4D flow CMR data are displayed. ROI, region of interest.

(LA). Detailed evaluation of flow in the atria may help to understand the mechanism of thrombus formation. Using capabilities of 4D flow CMR, vortical flow in the LA during systole and diastole was reported

in healthy individuals (Figure 3 and Supplementary data online, Video S2a–c).²¹ Duration and frequency of vortices correlated inversely with increase in age²² and it was reported that patients with vortex

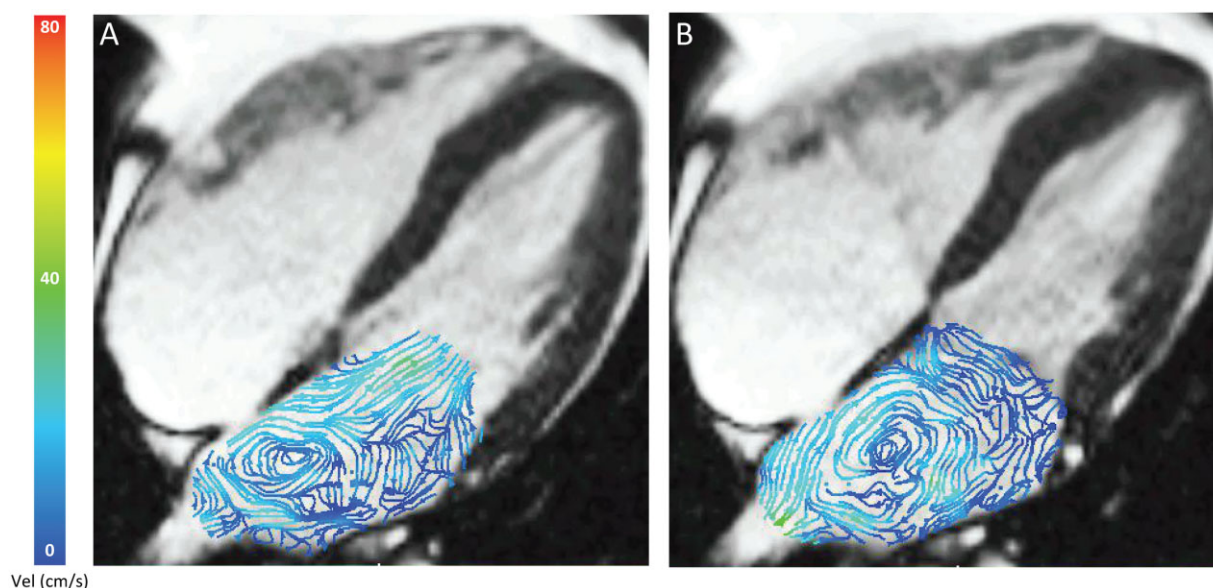


Figure 3 Two-dimensional streamline as overlay. Four-chamber view with 2-dimensional streamlines as overlay on the left atrium of a healthy volunteer (33-year-old male). Formation of a vortex can be observed in left atrium both during diastole (left side) and systole (right side) using streamlines.

formation in the LA have a smaller LA volume and higher peak flow velocity.²³ Therefore, it is postulated that formation of vortices within atria may have a role in avoiding atrial blood flow stasis.

4D flow CMR has the ability to provide global quantification of flow metrics within the heart. Patients with persistent AF demonstrated lower mean blood flow velocity within the LA compared to patients in sinus rhythm.²⁴ A larger study including 40 patients revealed that LA blood flow velocities are remarkably reduced in patients in sinus rhythm with a history of AF.³ In the same study, a significant inverse correlation was found between mean/peak LA velocity and CHA₂DS₂-VASc score, which is the recommended risk model to estimate the stroke risk in patients with AF,²⁵ indicating that LA flow metrics acquired by 4D flow CMR may add value for risk stratification of stroke. Markl et al.²⁶ compared the flow dynamics between LA and left atrial appendage (LAA) in healthy controls and patients with AF. Interestingly, there was no significant difference for mean and peak flow velocities between LA and LAA. These findings suggest that AF distorts flow dynamics not merely in the LAA, but in the entire LA. Finally, multi-centre studies exploring multiple factors predicting stroke in patients with AF including fibrosis, geometry, shape, and flow characteristics are awaited.

Valvular heart diseases

Accurate quantification of valvular regurgitation is of great importance for the clinical management. Using 4D flow CMR, analysis planes can be modified according to the location and angulation of moving valvular structures for quantification of valvular regurgitation. Besides, implementation of retrospective valve tracking allows reproducible and robust trans-valvular flow assessment at each of the four heart valves (Figure 4).²⁷ Using retrospective valve tracking, the planes of flow quantification follow the valve plane over the cardiac cycle

and can be adjusted according to the blood flow direction. 4D flow CMR with retrospective valve tracking was reported to be superior than conventional 2D 1-directional velocity mapping in patients with mitral and tricuspid valve regurgitations.²⁸ Yet, the manual placement and tracking of multiplanar reformatting planes in every cardiac phase is time consuming. Using an automated valve tracking method, the analysis time to quantify flow across four valves is considerably shortened compared to manual tracking (i.e. 14 vs. 25 min).²⁹ Recently, it has been shown that aligning the analysis plane with the velocity jet rather than the valve further improved quantification of regurgitation.³⁰

4D flow CMR could allow robust peak velocity quantification of stenotic jets, although phase dispersion due to highly turbulent flow may compromise the accuracy. It has been shown that 4D flow CMR exhibited higher peak velocities than 2D flow CMR both for aortic and pulmonary valves.³¹ Possibly, this may be explained by accurate detection of the site with the highest velocity using streamlines and the advantage of 3-directional flow velocity information. Another recent study has reported that transthoracic echocardiography (TTE) slightly underestimates peak velocities for aortic stenosis compared to 4D flow CMR suggesting that 4D flow CMR may be the preferred option especially for eccentric and multiple jets.³²

A novel hemodynamic parameter derived from 4D flow data is wall shear stress (WSS). Although this measure is referring to frictional shear stress on the aorta and the true WSS is not directly accessible due to insufficient spatial resolution, it provided significant insights regarding clinical consequences of bicuspid aortic valve (BAV) and aortic valve stenosis.³³ It has been argued that a BAV may have an asymmetrical orifice and thus an increased eccentric flow angle which leads to increased WSS and dilation of the ascending aorta.³⁴ Furthermore, BAV with stenosis yielded an even larger

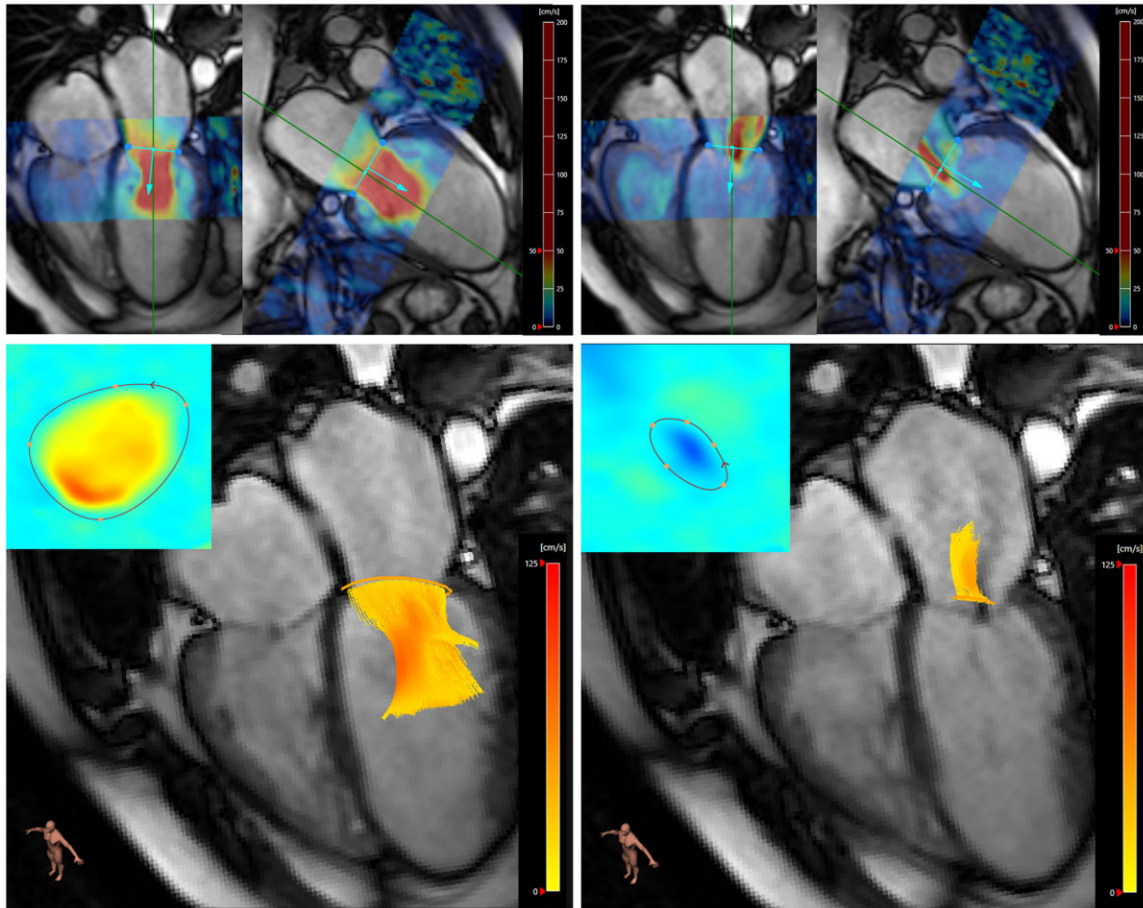


Figure 4 Retrospective valve tracking in a patient with mitral valve regurgitation. The left part of the figure shows valve tracking in a diastolic timeframe and the right part shows valve tracking in a systolic timeframe during regurgitation of a patient (45-year-old female) with a mitral valve regurgitation. In the top images, the colours represent the in-plane speed measured from 4D flow CMR projected on to 2-chamber and 4-chamber cine images. The bottom images show the streamlines with insets of phase velocity images resulting from the valve tracking. The regurgitation volume was measured 28.5 mL/beat and forward flow volume was 82.3 mL/beat.

extent of increased WSS in the ascending aorta than without stenosis.³⁵ Evaluation of WSS in the aorta is promising to be used in the management of aortic valve disease and valve replacement strategies.³⁶

Congenital heart diseases

CHD frequently results in important alterations in cardiovascular flow dynamics, which may have clinical consequences. Accurate quantification of flow parameters in this patient group is therefore essential for optimal patient management. Careful planning of 2D flow CMR with the use of several imaging planes leads to long acquisition times and potential misalignment of planes may underestimate velocity measurements. Easy planning of a single 3D volume in 4D flow CMR may provide faster scanning than 2D flow CMR. Moreover, 4D flow CMR permits retrospectively placement of analysis planes at any arbitrary location within the acquisition volume. It has been shown that flow quantification with 4D flow CMR may provide improved and time-efficient flow quantification compared to 2D flow CMR in

CHD.³⁷ However, small shunt flow volumes may still be underestimated by 4D flow CMR due to insufficient spatial resolution. In these particular cases, evaluation of pulmonary vs. systemic flow volume can be performed using 4D flow CMR to ensure the accuracy of the results.³⁸ Finally, visualization of abnormal flow patterns within the heart may contribute to understanding the interaction between surgically changed heart structures and hemodynamics in CHD.³⁹

Investigational clinical applications of 4D flow CMR-derived hemodynamic parameters

Kinetic energy

An important part of the total work of the heart transfers into KE of blood and KE is directly involved in the movement of blood.⁴⁰ Recent

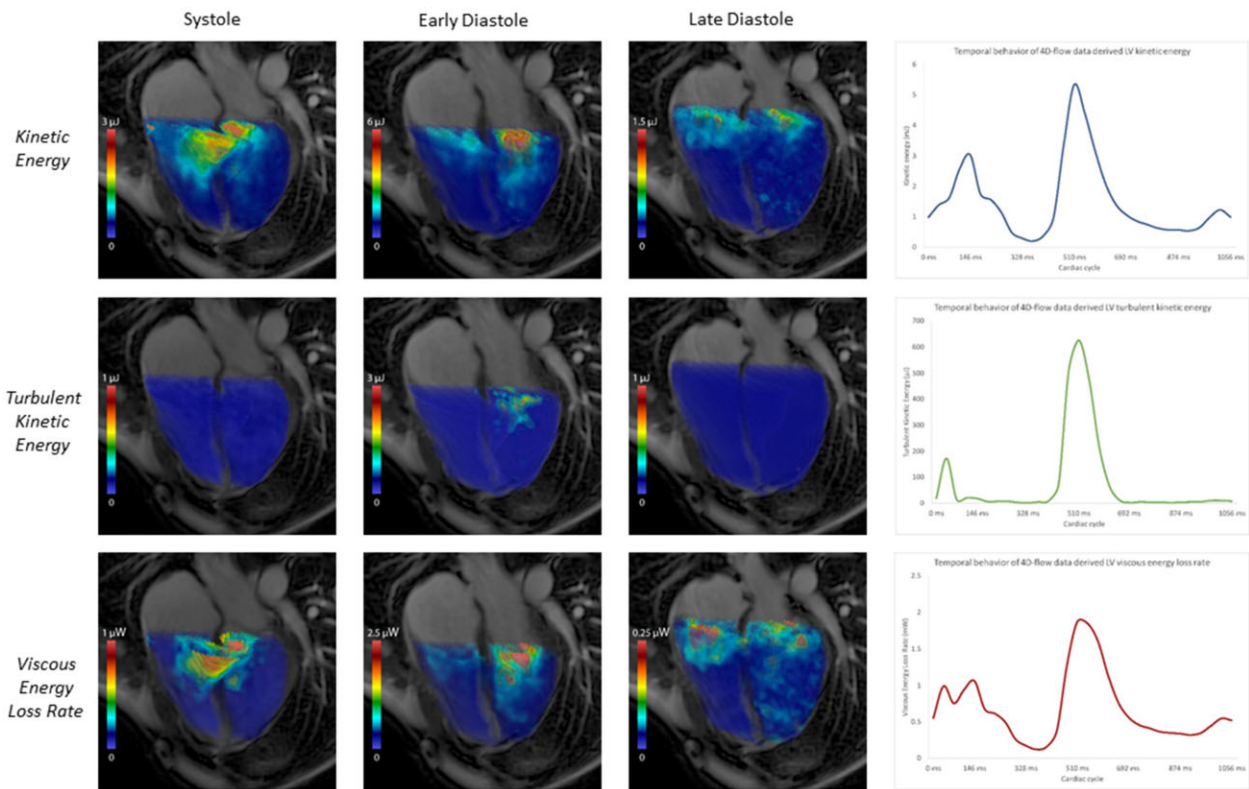


Figure 5 Demonstration of visual and quantitative abilities of KE, TKE, and EL. Visualization of KE, TKE, and EL rate in the LV and RV cavities in a healthy volunteer (48-year-old male), on a standard 4-chamber view during mid-systole, early diastole, and late diastole. Furthermore, entire LV KE, TKE, and EL rate are temporally plotted over the cardiac cycle on the far-right side of the figure.

developments of 4D flow CMR enable quantification and mapping of KE of blood flow within the heart (Figure 5 and Supplementary data online, Video S3a–c).⁴¹ For every voxel, KE is computed by multiplying 0.5 times the density of blood with the voxel volume, and velocity magnitude squared. The KE of the region of interest can then be computed by summing the KE of each voxel at a certain time frame.

Evaluation of intra-cardiac energy profiles integrated over a complete cardiac chamber may provide more comprehensive clinical data than only planar measurements can offer. Eriksson et al.⁴² reported that heart failure patients with mild left ventricle (LV) remodelling exhibited impaired preservation of inflow KE compared to healthy individuals despite equivalent stroke volumes. In particular, the total direct flow KE at end-diastole was lower in heart failure patients which may closely affect diastolic–systolic coupling. Furthermore, it was documented that myocardial infarction resulted in a decrease of the average LV KE over the whole cardiac cycle.⁴³ Although these studies provide insight into altered energy levels in patients with LV dysfunction, study settings and results are not coherent enough to draw clear clinical conclusions.

Assessment of LV energetics may provide a consistent classification for impaired LV filling. In healthy individuals, LV KE during E and A waves presented a stronger relation with increasing age than 2D mitral inflow measurements.⁴ Another study investigated right and left atrial KE in healthy volunteers and demonstrated three peaks in

KE time profiles in both atria: during ventricular systole, early ventricular diastole, and atrial contraction. Early diastolic KE of the LA was correlated with LV mass, whereas the same situation was not observed in the right chambers.⁴¹ Presumably, LV mass plays a determinant role in increasing the pressure gradient within the LV during diastole.⁴⁴

Finally, following mitral valve intervention for mitral valve insufficiency, a decrease of mean systolic and early-diastolic KE peaks was observed.⁴⁵ However, late-diastolic KE peak remained close to pre-operative high levels suggesting that physiological flow patterns within the LV may not be fully restored after surgery.

Turbulent kinetic energy

While standard cardiovascular blood flow is predominantly laminar, it can transitionally become turbulent with high-velocity fluctuations due to conditions such as valvular stenosis. Part of the energy content of turbulent flow dissipates as heat and is irreversibly lost from the blood flow. Turbulent kinetic energy (TKE) provides a measure of this energy loss and can be estimated by 4D flow CMR based on intra-voxel velocity distribution and its relation with the MR signal.⁴⁶

Significance of turbulence within the normal heart has long been investigated, but no agreement has been reached, yet.⁴⁷ Using 4D flow CMR, TKE values were found similar for LA and LV ranging from

0 to 5 mj in healthy subjects.^{47,48} Besides, LV TKE values were compared between healthy subjects and individuals with dilated cardiomyopathy (DCM).⁴⁷ Although early diastolic LV TKE did not differ between groups, late diastolic LV TKE was significantly higher in DCM patients, suggesting that inefficient flow is particularly occurring during late diastole. In another study in patients with clinically significant mitral regurgitation, average LA TKE per cardiac cycle was associated with the regurgitant volume indicating the severity of mitral valve regurgitation.⁴⁸ Furthermore, patients with aortic valve stenosis demonstrated higher TKE in the ascending aorta compared to healthy individuals.^{49,50} TKE may serve as a complementary tool to echocardiography to tailor the management of aortic stenosis. Finally, patients with repaired Tetralogy of Fallot with a high level of pulmonary regurgitation demonstrated higher TKE levels in the right ventricle (RV) compared to ones with a low pulmonary regurgitation,⁵¹ and a strong relationship was observed between TKE levels and the RV end-diastolic volume index.

Viscous energy loss

Another form of energy loss within blood flow is called viscous energy loss (EL) and this does not necessarily require any pathological situation such as TKE. The EL arises as a result of frictional forces between blood flow elements due to the variability of flow velocities within a vessel.⁵² 4D flow CMR allows quantification of EL by providing the 3-directional flow velocity field and using the Navier–Stokes equations.⁵³

Using 4D flow CMR, the association between EL and altered flow dynamics within the LV was investigated in patients with corrected atrioventricular septal defect. It was found that EL was higher during diastole in this patient group compared to healthy individuals.⁵³ Presumably, new positioning of the left atrioventricular valve created a more laterally directed inflow pattern and altered LV filling dynamics. Moreover, it was demonstrated that in patients after surgical correction of the pulmonary circulation according to the Fontan procedure, intraventricular EL is increased compared to healthy subjects.⁵ In another recent study, hemodynamic stress response on intraventricular EL, KE, and vorticity were shown to be inversely related to maximal exercise capacity in Fontan patients.⁵⁴ Since it is unclear how the heart reacts to elevated levels of EL in the LV, further studies investigating the clinical relevance of EL are warranted.

Pressure difference

4D flow CMR offers the quantification of pressure gradients throughout the cardiovascular system based on either the simplified Bernoulli equation (pressure gradient = $4V_{\text{peak}}^2$) or the Navier–Stokes equation. 4D flow CMR allows for the estimation of spatial and temporal information of flow-related pressure differences,⁵⁵ not absolute pressure values.

Relative pressure maps can be employed to assess intra-cardiac pressure differences (Figure 6).^{56,57} Furthermore, intra-cardiac hemodynamic forces which are closely related to pressure variations could be quantified in three directions.⁵⁸ Importantly, it was reported that hemodynamic forces significantly differ between patients with left ventricular dyssynchrony and healthy controls including loss of longitudinal forces in diastole.⁵⁹ This new approach of quantification of left ventricular dyssynchrony may play a potential role in improving cardiac synchronization therapy outcomes.

4D flow CMR vs. 4D colour Doppler echocardiography and 4D flow CT

The expected clinical benefits of cardiac flow imaging in its complete dimensionality are prompting clinicians to have such option in clinical practice through a robust modality. In this regard, 4D application of colour Doppler echocardiography has undergone extensive clinical research, as well. For consistent use of nomenclature, we will use the term of 4D (3D + time) colour Doppler echocardiography throughout the manuscript. A summary of comparison of typical features between 4D flow CMR and 4D colour Doppler echocardiography is provided in Table 1.

An important and highly clinically relevant advantage of both 4D flow CMR and 4D colour Doppler echocardiography is that they enable retrospectively flow assessment. Although 4D colour Doppler echocardiography can evaluate flow in 3D and against time, this can only be done in a single direction, whereas 4D flow CMR offers simultaneous 3-directional Venc, which provides assessment of flow in any direction in the acquired volume of interest. Advanced 3D flow visualization tools of 4D flow CMR assist in identification of complex flow patterns and only 4D flow CMR can offer a full quantification of flow at an arbitrary location within the acquired volume of interest, which precludes the missing region of interests for flow quantification. Importantly, these applications can be benefitted during post-processing with the employment of specific software and naturally are time consuming. Colour flow imaging with 4D echocardiography allows the advantage of fast viewing of flow during acquisition, yet the quality of images can significantly be affected due to low spatial and temporal resolution. Notably, the implication of 4D colour Doppler echocardiography can allow improved atrioventricular valve regurgitation grading through proximal iso-velocity surface area (PISA) and vena contracta (Figure 7 and Supplementary data online, Video S4a and b). Transesophageal echocardiography (TEE)-derived 3D integrated PISA was found more accurate than TTE-derived 3D integrated PISA and 2D echocardiography PISA approaches for mitral regurgitation quantification in a study validated against CMR.⁶⁰ The superiority of TEE-derived 3D approach may be primarily due to no geometric assumption as a result of 3D imaging and increased proximity to the valve with TEE imaging. Importantly, no grading cut-off values have been established yet regarding 4D echocardiography colour Doppler indexes.

Of note, 4D flow CMR exceptionally permits generation of several novel hemodynamic parameters such as KE which may lead to enhanced clinical management for cardiac diseases (e.g. heart failure).⁴² Furthermore, in addition to 4D flow imaging, CMR can provide a comprehensive whole-heart imaging experience in a single scan including gold standard quantification of volume and function, evaluation of myocardial edoema and myocardial fibrosis. Therefore, CMR can be considered as a reasonable modality in terms of cost-effectiveness, although CMR stands intrinsically as an expensive modality.

Alternatively, intra-cardiac 4D flow evaluation with computed tomography has been recently explored in a feasibility study.⁶¹ This application is simply based on combination of computational fluid dynamics with conventional coronary CT angiography data. Although

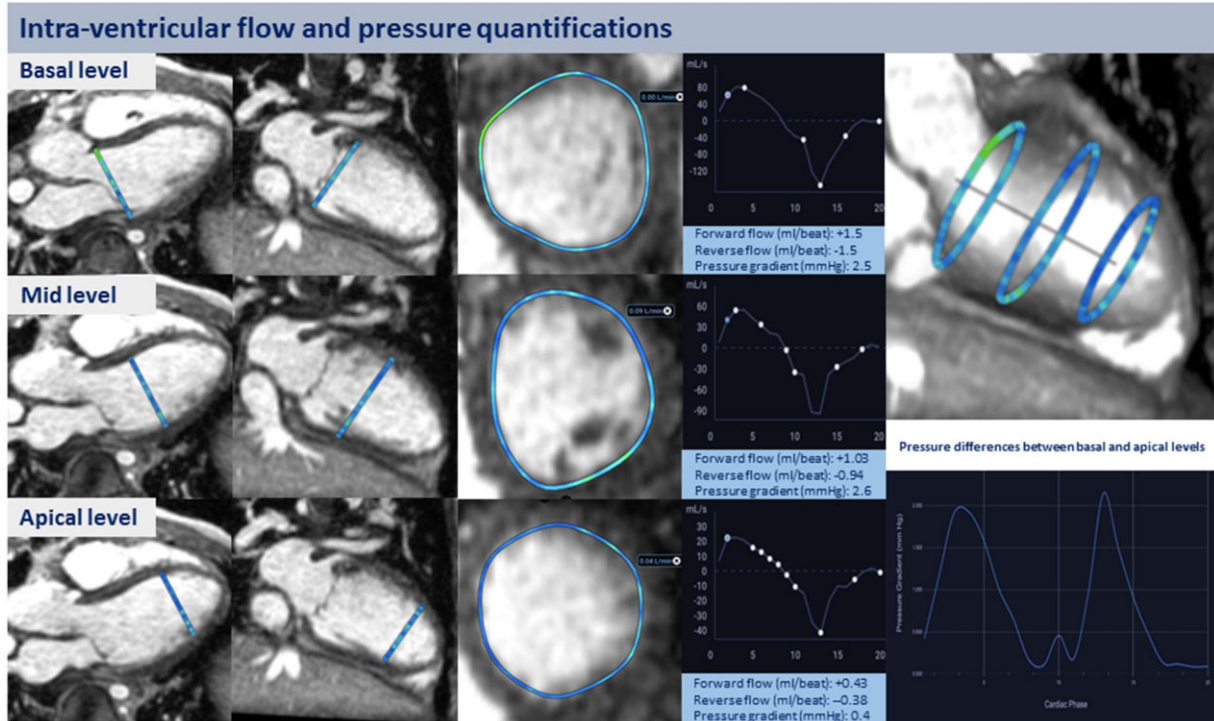


Figure 6 Flow and pressure gradient assessment in the left ventricle. Demonstration of flow and pressure quantifications in the left ventricle at basal, mid, and apical levels in a 12-year-old healthy male. On the left side, determination of the levels on the long-axis and segmentation on the short-axis views, in the middle-right, flow curves and the relevant flow and pressure gradient results are displayed. On the far-right side, 3-dimensional appearances of the levels on a 2-dimensional multi-planar view are shown and the pressure differences between basal and apical levels are temporally plotted over the cardiac cycle.

having the advantage of submillimeter spatial resolution, the requirement of retrospective gating for the entire cardiac cycle data prevents the application of this technique in clinical practice, as prospective gating is the accepted approach at present with the aim of reduced radiation. In addition, the lengthy and complex computational process remains another fundamental drawback.

Clinical perspective and future directions

Optimal severity grading values for cardiac valvular diseases should still be established for 4D flow CMR; existing severity classifications are based on echocardiographic and 2D flow assessment. For congenital cases requiring follow-up, an important advantage of the use of 4D flow CMR is that comprehensive accurate hemodynamic data can readily be obtained without using radiation. The novel hemodynamic parameters reveal underlying mechanisms of cardiac diseases and hold promise for employment in clinical practice, albeit they remain research parameters yet. Recent research documented a consistent relationship between left-heart diastolic novel hemodynamic quantities (e.g. KE, vorticity) and healthy ageing.^{4,22} Besides, gender-related significant differences were observed for LV and LA

3D vortex flow.^{22,62} Advancing these investigations may provide a deeper understanding regarding the physiological effects of age and gender differences on the intra-cardiac flow. Notably, there is a fundamental need for multi-center longitudinal studies to test the clinical validity of these and other preliminary findings.

The acquisition process of 4D flow CMR although time consuming is relatively straightforward, whilst analysis of the data is still quite complex. In contrast to the previous decade, options of analysis tools became diverse presenting a non-standardized structure in terms of provided analysis region, ancillary tools such as valvular tracking and application methodology. Further development and establishment of a standardized analysis process that allows for a uniform workflow will generate reproducible and comparable quantification.

In addition, 4D flow CMR datasets are intrinsically of large volume and therefore integration of artificial intelligent approaches such as machine learning can allow much more rapid acquisition and analysis processes. Reconstruction duration can be significantly shortened as less amount of sampling will be needed and automation of segmentation will extremely decrease analysis time. Moreover, further improvement in image quality of 4D flow magnitude data in terms of signal intensity and contrast will enable a much more effective and fast segmentation and improved feature tracking. Considering the current rate of respective technological developments and expanding

Table 1 Comparison of characteristics between 4D flow CMR and 4D colour Doppler echocardiography

	4D flow CMR	4D colour Doppler echocardiography
Acquisition	ECG-gated, phase contrast, segmented cine acquisition	Real time, single or multi-beat acquisition
Respiration control	Free breathing, navigator gating, bellows reading, self-gating	Breath hold
Velocity encoding	3D, full 3D velocity vector field	Single direction (in the direction of ultrasound beam)
Spatial resolution	$1.5 \times 1.5 \times 1.5$ – $3.0 \times 3.0 \times 3.0$ mm ³	Variable ^a
Temporal resolution	30–40 ms	10–25 frame rate per second (40–100 ms) for zoomed/full volume single-beat acquisitions
Flow visualization	3D (streamlines, pathlines)	3D velocity profiles
Flow quantification	Retrospective globally or planar analysis at any location in 3D acquisition volume of interest	Semi-quantification (vena contracta, PISA of atrioventricular valves)
Total scan time	5–20 minutes (dependent on heart rate, efficiency of respiration control, type of parallel imaging)	10–20 s per 3D view with colour flow imaging
Flow data analysis	Full quantification, large variety of analysis tools, time consuming	Semi-quantification, large variety of analysis tools
Requirement of expertise	Experienced CMR team is needed	Experienced echo team is needed
Derivation of hemodynamic parameters	KE, TKE, EL, pressure difference, vortex flow, haemodynamic forces	–
Clinical applications	Valvular disease, congenital heart disease	Valvular disease, congenital heart disease
Cost effectiveness	Relatively expensive	TTE: inexpensive TEE: relatively inexpensive
Prosthetic valve flow	Not ideal, high level of metallic artefacts	Not ideal, only prosthetic rings can be optimally visualized

^aDependent on several factors, but it is considered significantly lower than 4D flow CMR.

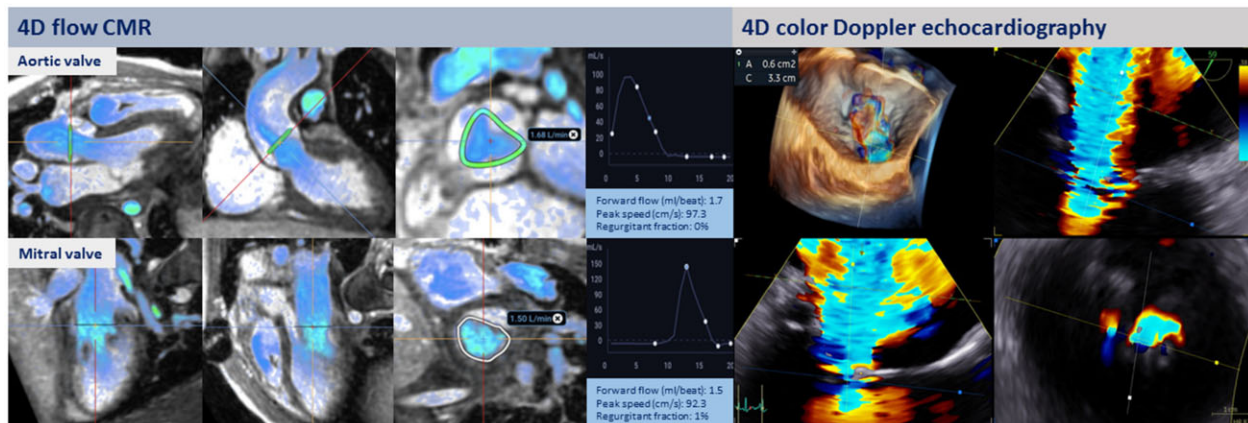


Figure 7 Valvular flow quantification with 4D flow CMR and 4D colour Doppler echocardiography. On the left side, valvular flow visualization and quantification of 4D flow CMR is displayed in a 12-year-old healthy male. 3D blood flow on multi-planar views during systole for aortic valve and during diastole for mitral valve is visualized. The segmentations were done using an artificial intelligence approach. Furthermore, aortic and mitral valve flows are temporally plotted over the cardiac cycle and valvular flow measurements are provided. On the right side, measurement of 3D vena contracta area of functional mitral regurgitation with 4D colour Doppler transesophageal echocardiography in a 51-year-old male is shown. Volume rendering view (top left), two perpendicular long-axis views of mitral regurgitation jet and one short-axis view (bottom right) at the level of coaptation defect are visualized. Vena contracta area was measured as 0.6 cm² and circumference of the jet as 3.3 cm.

incorporation of artificial intelligence in 4D imaging, it is of the high likelihood that 4D flow CMR will be an essential clinical tool within the upcoming 5–10 years and massively enhance the understanding of flow within the heart.

To conclude, 4D (3 dimensions + time) flow CMR is a novel, powerful tool to study the impact of cardiovascular disease on flow and vice versa. Multiple advanced hemodynamic parameters can retrospectively be derived from the 4D flow CMR datasets. While offering clear advantages over other imaging modalities including 4D colour Doppler echocardiography and 4D flow CT, the lack of analysis tools that allow for standardized quantification of 4D flow values prevents a rapid widespread adoption for routine clinical use.

Supplementary Data

Supplementary data are available at *European Heart Journal - Cardiovascular Imaging* online.

Acknowledgements

The first author, Ahmet Demirkiran, has received a research grant from the International Research Fellowship Programme by the Turkish Society of Cardiology. The last author, Marco J.W. Götte, is a consultant to Circle Cardiovascular Imaging, Inc., Calgary, Canada. We would like to thank Otto Kamp and Konstantinos Papadopoulos (both cardiologist and EACVI-accredited cardiac imaging specialist) for their valuable contribution in the description and demonstration of the 4D colour Doppler echocardiography technique.

Conflict of interest: none declared.

References

- Dyverfeldt P, Bissell M, Barker AJ, Bolger AF, Carlhall CJ, Ebberts T et al. 4D flow cardiovascular magnetic resonance consensus statement. *J Cardiovasc Magn Reson* 2015;**17**:72.
- Wigstrom L, Sjoqvist L, Wranne B. Temporally resolved 3D phase-contrast imaging. *Magn Reson Med* 1996;**36**:800–3.
- Lee DC, Markl M, Ng J, Carr M, Benefield B, Carr JC et al. Three-dimensional left atrial blood flow characteristics in patients with atrial fibrillation assessed by 4D flow CMR. *Eur Heart J Cardiovasc Imaging* 2016;**17**:1259–68.
- Crandon S, Westenberg JJM, Swoboda PP, Fent GJ, Foley JR, Chew PG et al. Impact of age and diastolic function on novel, 4D flow CMR biomarkers of left ventricular blood flow kinetic energy. *Sci Rep* 2018;**8**:14436.
- Kamphuis VP, Elbaz MSM, van den Boogaard PJ, Kroft LJM, van der Geest RJ, de Roos A et al. Disproportionate intraventricular viscous energy loss in Fontan patients: analysis by 4D flow MRI. *Eur Heart J Cardiovasc Imaging* 2018.
- Bryant DJ, Payne JA, Firmin DN, Longmore DB. Measurement of flow with NMR imaging using a gradient pulse and phase difference technique. *J Comput Assist Tomogr* 1984;**8**:588–93.
- Dyverfeldt P, Ebberts T. Comparison of respiratory motion suppression techniques for 4D flow MRI. *Magn Reson Med* 2017;**78**:1877–82.
- Buehrer M, Curcic J, Boesiger P, Kozerke S. Prospective self-gating for simultaneous compensation of cardiac and respiratory motion. *Magn Reson Med* 2008;**60**:683–90.
- Jung B, Honal M, Ullmann P, Hennig J, Markl M. Highly k-t-space-accelerated phase-contrast MRI. *Magn Reson Med* 2008;**60**:1169–77.
- Lustig M, Donoho D, Pauly JM. Sparse MRI: the application of compressed sensing for rapid MR imaging. *Magn Reson Med* 2007;**58**:1182–95.
- Sigfridsson A, Petersson S, Carlhall CJ, Ebberts T. Four-dimensional flow MRI using spiral acquisition. *Magn Reson Med* 2012;**68**:1065–73.
- Zhong L, Schrauben EM, Garcia J, Uribe S, Grieve SM, Elbaz MSM et al. Intracardiac 4D flow MRI in congenital heart disease: recommendations on behalf of the ISMRM Flow & Motion Study Group. *J Magn Reson Imaging* 2019;**50**:spc0ne–81.
- Garg P, Westenberg JJM, van den Boogaard PJ, Swoboda PP, Aziz R, Foley JR et al. Comparison of fast acquisition strategies in whole-heart four-dimensional flow cardiac MR: two-center, 1.5 Tesla, phantom and in vivo validation study. *J Magn Reson Imaging* 2018;**47**:272–81.
- Wiesemann S, Schmitter S, Demir A, Prothmann M, Schwenke C, Chawla A et al. Impact of sequence type and field strength (1.5, 3, and 7T) on 4D flow MRI hemodynamic aortic parameters in healthy volunteers. *Magn Reson Med* 2021;**85**:721–33.
- Callaghan FM, Kozor R, Sherrah AG, Vallely M, Celermajer D, Figtree GA et al. Use of multi-velocity encoding 4D flow MRI to improve quantification of flow patterns in the aorta. *J Magn Reson Imaging* 2016;**43**:352–63.
- Bustamante M, Gupta V, Carlhall CJ, Ebberts T. Improving visualization of 4D flow cardiovascular magnetic resonance with four-dimensional angiographic data: generation of a 4D phase-contrast magnetic resonance CardioAngiography (4D PC-MRCA). *J Cardiovasc Magn Reson* 2017;**19**:47.
- Napel S, Lee DH, Frayne R, Rutt BK. Visualizing three-dimensional flow with simulated streamlines and three-dimensional phase-contrast MR imaging. *J Magn Reson Imaging* 1992;**2**:143–53.
- Buonocore MH. Visualizing blood flow patterns using streamlines, arrows, and particle paths. *Magn Reson Med* 1998;**40**:210–26.
- Bolger AF, Heiberg E, Karlsson M, Wigstrom L, Engvall J, Sigfridsson A et al. Transit of blood flow through the human left ventricle mapped by cardiovascular magnetic resonance. *J Cardiovasc Magn Reson* 2007;**9**:741–7.
- Houtzager JH, Westenberg JJ, de Koning PJ, Hazekamp MG, Roest AA. Helical flow pattern in the right pulmonary artery after Fontan palliation. *Eur Heart J Cardiovasc Imaging* 2014;**15**:1183.
- Fyrenius A, Wigstrom L, Ebberts T, Karlsson M, Engvall J, Bolger AF. Three dimensional flow in the human left atrium. *Heart* 2001;**86**:448–55.
- Foll D, Taeger S, Bode C, Jung B, Markl M. Age, gender, blood pressure, and ventricular geometry influence normal 3D blood flow characteristics in the left heart. *Eur Heart J Cardiovasc Imaging* 2013;**14**:366–73.
- Suwa K, Saitoh T, Takehara Y, Sano M, Nobuhara M, Saotome M et al. Characteristics of intra-left atrial flow dynamics and factors affecting formation of the vortex flow—analysis with phase-resolved 3-dimensional cine phase contrast magnetic resonance imaging. *Circ J* 2015;**79**:144–52.
- Fluckiger JU, Goldberger JJ, Lee DC, Ng J, Lee R, Goyal A et al. Left atrial flow velocity distribution and flow coherence using four-dimensional FLOW MRI: a pilot study investigating the impact of age and pre- and postintervention atrial fibrillation on atrial hemodynamics. *J Magn Reson Imaging* 2013;**38**:580–7.
- Kirchhof P, Benussi S, Kotecha D, Ahlsson A, Atar D, Casadei B, ESC Scientific Document Group et al. 2016 ESC Guidelines for the management of atrial fibrillation developed in collaboration with EACTS. *Eur Heart J* 2016;**37**:2893–962.
- Markl M, Lee DC, Furiasse N, Carr M, Foucar C, Ng J et al. Left atrial and left atrial appendage 4D blood flow dynamics in atrial fibrillation. *Circ Cardiovasc Imaging* 2016;**9**:e004984.
- Roes SD, Hammer S, van der Geest RJ, Marsan NA, Bax JJ, Lamb HJ et al. Flow assessment through four heart valves simultaneously using 3-dimensional 3-directional velocity-encoded magnetic resonance imaging with retrospective valve tracking in healthy volunteers and patients with valvular regurgitation. *Invest Radiol* 2009;**44**:669–75.
- Westenberg JJ, Roes SD, Ajmone Marsan N, Binnendijk NM, Doornbos J, Bax JJ et al. Mitral valve and tricuspid valve blood flow: accurate quantification with 3D velocity-encoded MR imaging with retrospective valve tracking. *Radiology* 2008;**249**:792–800.
- Kamphuis VP, Roest AAW, Ajmone Marsan N, van den Boogaard PJ, Kroft LJM, Aben JP et al. Automated Cardiac Valve Tracking for Flow Quantification with Four-dimensional Flow MRI. *Radiology* 2019;**290**:70–8.
- Blanken CP, Westenberg JJ, Aben J-P, Bijvoet GP, Chamuleau SA, Boekholdt SM et al. Quantification of mitral valve regurgitation from 4D flow MRI using semiautomated flow tracking. *Radiol Cardiothorac Imaging* 2020;**2**:e200004.
- Nordmeyer S, Riesenkampff E, Messroghli D, Kropp S, Nordmeyer J, Berger F et al. Four-dimensional velocity-encoded magnetic resonance imaging improves blood flow quantification in patients with complex accelerated flow. *J Magn Reson Imaging* 2013;**37**:208–16.
- da Silveira JS, Smyke M, Rich AV, Liu Y, Jin N, Scandling D et al. Quantification of aortic stenosis diagnostic parameters: comparison of fast 3 direction and 1 direction phase contrast CMR and transthoracic echocardiography. *J Cardiovasc Magn Reson* 2017;**19**:35.
- Garcia J, Barker AJ, Markl M. The role of imaging of flow patterns by 4D flow MRI in aortic stenosis. *JACC Cardiovasc Imaging* 2019;**12**:252–66.
- Hope MD, Hope TA, Crook SE, Ordovas KG, Urbania TH, Alley MT et al. 4D flow CMR in assessment of valve-related ascending aortic disease. *J Am Coll Cardiol Img* 2011;**4**:781–7.
- van Ooij P, Markl M, Collins JD, Carr JC, Rigsby C, Bonow RO et al. Aortic valve stenosis alters expression of regional aortic wall shear stress: new insights from a 4-dimensional flow magnetic resonance imaging study of 571 subjects. *J Am Heart Assoc* 2017;**6**:1–13.

36. Bissell MM, Loudon M, Hess AT, Stoll V, Orchard E, Neubauer S *et al*. Differential flow improvements after valve replacements in bicuspid aortic valve disease: a cardiovascular magnetic resonance assessment. *J Cardiovasc Magn Reson* 2018;**20**:10.
37. Valverde I, Nordmeyer S, Uribe S, Greil G, Berger F, Kuehne T *et al*. Systemic-to-pulmonary collateral flow in patients with palliated univentricular heart physiology: measurement using cardiovascular magnetic resonance 4D velocity acquisition. *J Cardiovasc Magn Reson* 2012;**14**:25.
38. Hsiao A, Tariq U, Alley MT, Lustig M, Vasawala SS. Inlet and outlet valve flow and regurgitant volume may be directly and reliably quantified with accelerated, volumetric phase-contrast MRI. *J Magn Reson Imaging* 2015;**41**:376–85.
39. Francois CJ, Srinivasan S, Schiebler ML, Reeder SB, Niespodzany E, Landgraf BR *et al*. 4D cardiovascular magnetic resonance velocity mapping of alterations of right heart flow patterns and main pulmonary artery hemodynamics in tetralogy of Fallot. *J Cardiovasc Magn Reson* 2012;**14**:16.
40. Prec O, Katz LN. Determination of kinetic energy of the heart in man. *Am J Physiol* 1949;**159**:483–91.
41. Arvidsson PM, Toger J, Heiberg E, Carlsson M, Arheden H. Quantification of left and right atrial kinetic energy using four-dimensional intracardiac magnetic resonance imaging flow measurements. *J Appl Physiol* 2013;**114**:1472–81.
42. Eriksson J, Bolger AF, Ebberts T, Carlhall CJ. Four-dimensional blood flow-specific markers of LV dysfunction in dilated cardiomyopathy. *Eur Heart J Cardiovasc Imaging* 2013;**14**:417–24.
43. Garg P, Crandon S, Swoboda PP, Fent GJ, Foley JRJ, Chew PG *et al*. Left ventricular blood flow kinetic energy after myocardial infarction—insights from 4D flow cardiovascular magnetic resonance. *J Cardiovasc Magn Reson* 2018;**20**:61.
44. Steding-Ehrenborg K, Arvidsson PM, Toger J, Rydberg M, Heiberg E, Carlsson M *et al*. Determinants of kinetic energy of blood flow in the four-chambered heart in athletes and sedentary controls. *Am J Physiol Heart Circ Physiol* 2016;**310**:H113–22.
45. Al-Wakeel N, Fernandes JF, Amiri A, Siniawski H, Goubergrits L, Berger F *et al*. Hemodynamic and energetic aspects of the left ventricle in patients with mitral regurgitation before and after mitral valve surgery. *J Magn Reson Imaging* 2015;**42**:1705–12.
46. Dyverfeldt P, Kvitting JP, Sigfridsson A, Engvall J, Bolger AF, Ebberts T. Assessment of fluctuating velocities in disturbed cardiovascular blood flow: in vivo feasibility of generalized phase-contrast MRI. *J Magn Reson Imaging* 2008;**28**:655–63.
47. Zajac J, Eriksson J, Dyverfeldt P, Bolger AF, Ebberts T, Carlhall CJ. Turbulent kinetic energy in normal and myopathic left ventricles. *J Magn Reson Imaging* 2015;**41**:1021–9.
48. Dyverfeldt P, Kvitting JP, Carlhall CJ, Boano G, Sigfridsson A, Hermansson U *et al*. Hemodynamic aspects of mitral regurgitation assessed by generalized phase-contrast MRI. *J Magn Reson Imaging* 2011;**33**:582–8.
49. Dyverfeldt P, Hope MD, Tseng EE, Saloner D. Magnetic resonance measurement of turbulent kinetic energy for the estimation of irreversible pressure loss in aortic stenosis. *J Am Coll Cardiol Imaging* 2013;**6**:64–71.
50. Binter C, Gotschy A, Sundermann SH, Frank M, Tanner FC, Luscher TF *et al*. Turbulent kinetic energy assessed by multipoint 4-dimensional flow magnetic resonance imaging provides additional information relative to echocardiography for the determination of aortic stenosis severity. *Circ Cardiovasc Imaging* 2017;**10**:
51. Fredriksson A, Trzebiatowska-Krzynska A, Dyverfeldt P, Engvall J, Ebberts T, Carlhall C-J. Turbulent kinetic energy in the right ventricle: potential MR marker for risk stratification of adults with repaired Tetralogy of Fallot. *J Magn Reson Imaging* 2018;**47**:1043–53.
52. Akins CW, Travis B, Yoganathan AP. Energy loss for evaluating heart valve performance. *J Thorac Cardiovasc Surg* 2008;**136**:820–33.
53. Elbaz MS, van der Geest RJ, Calkoen EE, de Roos A, Lelieveldt BP, Roest AA *et al*. Assessment of viscous energy loss and the association with three-dimensional vortex ring formation in left ventricular inflow: in vivo evaluation using four-dimensional flow MRI. *Magn Reson Med* 2017;**77**:794–805.
54. Kamphuis VP, Elbaz MSM, van den Boogaard PJ, Kroft LJM, Lamb HJ, Hazekamp MG *et al*. Stress increases intracardiac 4D flow cardiovascular magnetic resonance-derived energetics and vorticity and relates to VO₂max in Fontan patients. *J Cardiovasc Magn Reson* 2019;**21**:43.
55. Bock J, Frydrychowicz A, Lorenz R, Hirtler D, Barker AJ, Johnson KM *et al*. In vivo noninvasive 4D pressure difference mapping in the human aorta: phantom comparison and application in healthy volunteers and patients. *Magn Reson Med* 2011;**66**:1079–88.
56. Eriksson J, Bolger AF, Carlhall CJ, Ebberts T. Spatial heterogeneity of four-dimensional relative pressure fields in the human left ventricle. *Magn Reson Med* 2015;**74**:1716–25.
57. van Ooij P, Allen BD, Contaldi C, Garcia J, Collins J, Carr J *et al*. 4D flow MRI and T1-mapping: assessment of altered cardiac hemodynamics and extracellular volume fraction in hypertrophic cardiomyopathy. *J Magn Reson Imaging* 2016;**43**:107–14.
58. Toger J, Arvidsson PM, Bock J, Kanski M, Pedrizzetti G, Carlsson M *et al*. Hemodynamic forces in the left and right ventricles of the human heart using 4D flow magnetic resonance imaging: phantom validation, reproducibility, sensitivity to respiratory gating and free analysis software. *PLoS One* 2018;**13**:e0195597.
59. Arvidsson PM, Toger J, Pedrizzetti G, Heiberg E, Borgquist R, Carlsson M *et al*. Hemodynamic forces using four-dimensional flow MRI: an independent biomarker of cardiac function in heart failure with left ventricular dyssynchrony? *Am J Physiol Heart Circ Physiol* 2018;**315**:H1627–H1639.
60. Brugger N, Wustmann K, Hurzeler M, Wahl A, de Marchi SF, Steck H *et al*. Comparison of three-dimensional proximal isovelocity surface area to cardiac magnetic resonance imaging for quantifying mitral regurgitation. *Am J Cardiol* 2015;**115**:1130–6.
61. Lantz J, Gupta V, Henriksson L, Karlsson M, Persson A, Carlhall CJ *et al*. Intracardiac flow at 4D CT: comparison with 4D flow MRI. *Radiology* 2018;**289**:51–8.
62. Rutkowski DR, Barton GP, François CJ, Aggarwal N, Roldán-Alzate A. Sex differences in cardiac flow dynamics of healthy volunteers. *Radiol Cardiothorac Imaging* 2020;**2**:e190058.