

Traction Induced Vertical Displacement of Odontoid due to Type III Odontoid Fracture with Unrecognized Ligamentous Injury: A Case Report

Min-Ho Jung, MD, Jung-Kil Lee, MD, Hyuk Hur, MD,
Jae-Won Jang, MD, Jae-Hyoo Kim, MD, and Soo-Han Kim, MD

Department of Neurosurgery, Chonnam National University Hospital, Gwangju, Korea

Dens fractures are a common traumatic cervical spine injury. Among them, a type III fracture is the second common fracture. Although there are several treatment options, it has been accepted that type III fracture is usually healed by non-surgical method. After adequate reduction with traction, subsequent external immobilization has been associated with successful union rates. However, in the review of literatures, there are some cases with neurological deterioration after application of skull traction. So, the authors report a case of type III dens fracture with initially unrecognized ligamentous injury in which vertical dissociation and quadriplegia occurred after only five-pound Gardner-Well tongs traction. And also, the authors raise awareness of this potentially injury.

(Korean J Neurotrauma 2014;10(2):149-151)

KEY WORDS: Cervical vertebrae · Fracture fixation internal · Traction.

Introduction

Dens fractures have accounted for 7% to 15% of all fractures of the cervical spine and 1% to 2% of all spine fractures.¹⁾ Despite numerous publications on this injury, with a trend toward early surgical stabilization,⁴⁾ the treatment modality for this frequent injury remains controversial. Especially, in the case of type III fracture which is divided by the Anderson and D'Alonzo (1974) classification,¹⁾ there are many debates for the optimal treatment modality. Although most authors suggest that type III fracture usually healed without surgical intervention, some authors insist that early internal fixation is necessary for immediate stabilization and early rehabilitation in selected cases.⁸⁾ Better or not reduction is still necessary for displacement-fractures and the most simply used reduction tool is traction. It is particularly applied to patients for neural decompression and

stabilization when the early surgical intervention does not be performed due to combined injuries and/or other medical problems. However, it may be very harmful to apply the skeletal traction device to the patient of type III fracture associated vertical instability without close attention throughout the procedure. Here, the authors describe the case of a patient who developed vertical dissociation and quadriplegia after only five-pound Gardner-Well tongs traction and consider to that avoid this potentially fatal complication.

Case Report

A 43-year-old woman, who had been involved in motor-vehicle accident, was transferred from another hospital. Initial computed tomography (CT) scans of cervical spine presented type III dens fracture with mild anterior displacement (about 4 mm)(Figure 1). In the review of the medical record of local private hospital, the patient presented with no motor weakness on arrival at the hospital. Thus, the patient was implemented to skull traction for reduction and underwent light wand-guided orotracheal intubation following sedation in this hospital. However, about 30 minutes after traction, there was no movement of all extremities to painful

Received: September 12, 2014 / **Revised:** October 12, 2014

Accepted: October 15, 2014

Address for correspondence: Jung-Kil Lee, MD
Department of Neurosurgery, Chonnam National University Hospital, 42 Jebong-ro, Dong-gu, Gwangju 501-757, Korea
Tel: +82-62-220-6602, Fax: +82-62-224-9865
E-mail: jkl@chonnam.ac.kr

stimulations consistently, although the patient was in sedative state. Follow-up cervical X-ray revealed vertical displacement of axis and prevertebral swelling (Figure 2A). Immediately, performed neck collar, discontinued of skull traction and started steroid therapy, the patient was transferred to the author's hospital for further evaluation and treatment. Follow-up CT scans of cervical spine showed a maximal separation within the body of the axis of 5.7 mm in the coronal, 5.8 mm in the sagittal plane, angulation of 20°, and the fracture extended into left atlantoaxial joint with partial articular disruption on left with 3.3 mm of separation (Figure 2B). Because of poor mental status due to diffuse axonal injury and medical condition of the patient, we decided to delay the operative procedure. Six weeks later after recovery of patient's general medical condition, we performed anterior transodontoid screw fixation and pos-

terior unilateral atlantoaxial transarticular screw fixation with interspinous wiring and posterolateral fusion simultaneously (UCSS; Medtronic, Sofamor Danek, Memphis, TN, USA)(Figure 3). For the fusion materials, autologous iliac bone was used. Because of the patient's general medical condition was not enough to be checked preoperative cervical spine magnetic resonance imaging (MRI), therefore, ligamentous injury of the atlantoaxial junction could not prove on preoperative radiologic examinations. However, we could identify posterior ligamentous complex injury of C1–2 area during operation.

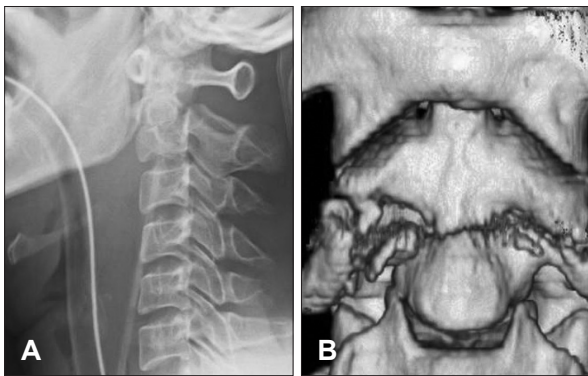


FIGURE 1. Lateral cervical radiograph revealing a type III dens fracture with slight anterolisthesis, angulation of dens, vertical displacement (A). A cervical spine computed tomography with 3D reconstructions revealing a type III dens fracture with extension into left facet joint, and separation between the fragments of axis (B).

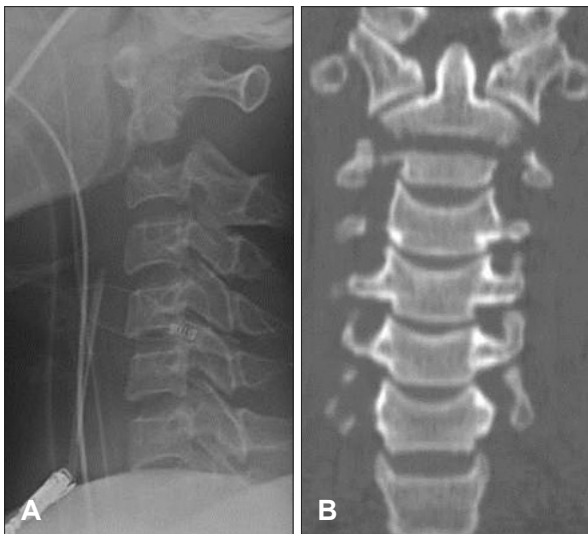


FIGURE 2. Lateral cervical radiography (A) and computed tomography with 2D coronal reconstructions (B) revealing vertical displacement of axis greater than 5 mm.

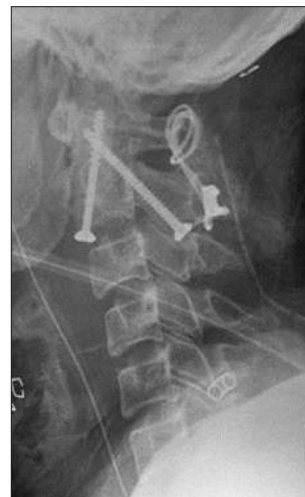

FIGURE 3. Postoperative lateral cervical radiography revealing anterior transodontoid screw fixation and unilateral C1–2 posterior transarticular screw fixation with wiring achieved reduction of odontoid fracture.

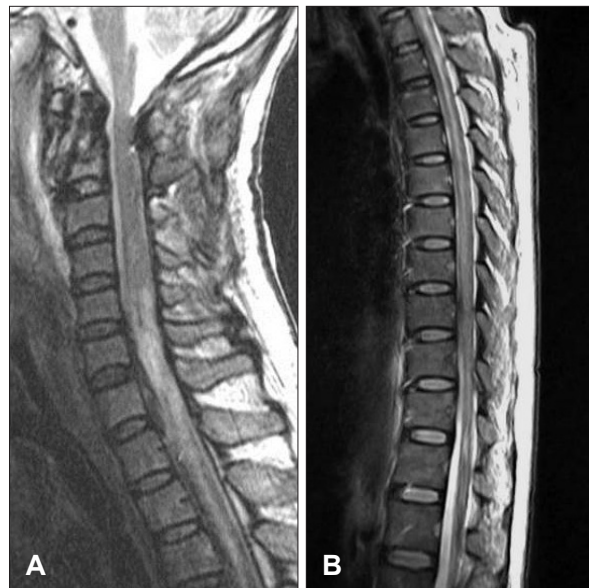

FIGURE 4. Cervical MRI revealing heterogeneous high signal intensity (consider to hemorrhagic contusion) in spinal cord of C3–T2 level (A) and extensive syringomyelia in thoracic spinal cord (B).

One week later after surgery, we checked postoperative cervical MRI that revealed hemorrhagic contusions with mixed stage on spinal cord at C3–T2 body level (Figure 4A) and extensive syringomyelia in thoracic spinal cord (Figure 4B). Three weeks later, the patient was able to ambulation assisted by wheel-chair. Six months after surgery, the motor grade of this patient was improved to grade IV, and now rehabilitation has been performed.

Discussion

Type III dens fractures are usually relatively benign injuries associated with few complications.⁶⁾ For example, low nonunion rates with halo traction and/or immobilization have been reported.¹¹⁾ But some authors reported, in routine skeletal traction, there were few patients with fractures associated with increasing the vertical displacement and neurologic deteriorations.^{5,10)} Similarly we have an experience that vertically unstable type III dens fractures for which initial treatment with traction device was associated with neurological problem.

It was necessary that we should identify characteristic abnormal imaging findings suggesting severe ligamentous disruption that could lead to excessive distraction.⁹⁾ Several radiologic features can be identified that should suggest the potential risk factors of skeletal traction for immobilization or reduction. Kirkpatrick et al.,⁶⁾ all of this study patients had >5 mm of vertical displacement of the dens on the initial imaging studies. They believe that type III dens fractures with >5 mm of vertical distraction are unstable.⁶⁾ These findings indicate tearing of the anterior atlantoaxial ligament, the tectorial membrane, the interspinous ligament and the atlantoaxial facet capsules, suggesting the possibility of longitudinal distraction with skeletal traction.⁹⁾ In our case, we performed surgical treatment because of the maximal separation within the body of the axis about 5.7 mm.

Postmortem studies have been shown odontoid fractures accompanied by complete disruption of the anterior atlantoaxial ligament, tectorial membrane and facet capsules on both sides with the dens held loosely by the alar ligaments.¹⁾ These injuries appear to have been vertically unstable type III dens fractures. And identification of C1 transverse process fractures,³⁾ local craniocervical junction soft tissue hemorrhages²⁾ and atlantoaxial joint subluxations⁷⁾ also suggest the presence of craniocervical junction ligamentous inju-

ries. Another study reported that cervical prevertebral swelling following trauma was indicative of ligament injury in cervical MRI.¹²⁾ In our case, the odontoid fracture was accompanied by the disruption of left atlantoaxial joint with fracture and severe swelling of prevertebral space, therefore, physicians should consider that the case might be associated with severe instability prior to cervical traction.

Conclusion

Skull traction can make severe neurologic deficits with vertical displacement of fractured line as the complication in a case with type III dens fracture. To avoid this complication, physicians should recognize the imaging findings associated with instability of type III dens fracture, such as C1 transverse process fracture, disruption of atlantoaxial joint, or craniovertebral junction hemorrhage before cervical traction.

■ The authors have no financial conflicts of interest.

REFERENCES

- 1) Adams VI. Neck injuries: II. Atlantoaxial dislocation--a pathologic study of 14 traffic fatalities. *J Forensic Sci* 37:565-573, 1992
- 2) Coast GC, Gee DJ. Traumatic subarachnoid haemorrhage: an alternative source. *J Clin Pathol* 37:1245-1248, 1984
- 3) Contostavlos DL. Massive subarachnoid hemorrhage due to laceration of the vertebral artery associated with fracture of the transverse process of the atlas. *J Forensic Sci* 16:40-56, 1971
- 4) Fairholm D, Lee ST, Lui TN. Fractured odontoid: the management of delayed neurological symptoms. *Neurosurgery* 38:38-43, 1996
- 5) Hammer AJ. Lower cranial nerve palsies. Potentially lethal in association with upper cervical fracture-dislocations. *Clin Orthop Relat Res*:64-69, 1991
- 6) Kirkpatrick JS, Sheils T, Theiss SM. Type-III dens fracture with distraction: an unstable injury. A report of three cases. *J Bone Joint Surg Am* 86-A:2514-2518, 2004
- 7) Lindenberg R, Freytag E. Brainstem lesions characteristic of traumatic hyperextension of the head. *Arch Pathol* 90:509-515, 1970
- 8) Pryputniewicz DM, Hadley MN. Axis fractures. *Neurosurgery* 66(3 Suppl):68-82, 2010
- 9) Przybylski GJ, Welch WC. Longitudinal atlantoaxial dislocation with type III odontoid fracture. Case report and review of the literature. *J Neurosurg* 84:666-670, 1996
- 10) Robertson PA, Ryan MD. Neurological deterioration after reduction of cervical subluxation. Mechanical compression by disc tissue. *J Bone Joint Surg Br* 74:224-227, 1992
- 11) Ryan MD, Taylor TK. Odontoid fractures. A rational approach to treatment. *J Bone Joint Surg Br* 64:416-421, 1982
- 12) Silberstein M, Tress BM, Hennessy O. Prevertebral swelling in cervical spine injury: identification of ligament injury with magnetic resonance imaging. *Clin Radiol* 46:318-323, 1992