

Network meta-analysis of percutaneous vertebroplasty, percutaneous kyphoplasty, nerve block, and conservative treatment for nonsurgery options of acute/subacute and chronic osteoporotic vertebral compression fractures (OVCFs) in short-term and long-term effects

Xiao-Hua Zuo, MD^{a,b}, Xue-Piao Zhu, MM^b, Hong-Guang Bao, MD^{a,*}, Chen-Jie Xu, MD^a, Hao Chen, MD^a, Xian-Zhong Gao, MB^a, Qian-Xi Zhang, MB^b

Abstract

Background: Osteoporotic vertebral compression fractures (OVCFs) commonly afflicts most aged people resulting back pain, substantial vertebral deformity, functional disability, decreased quality of life, and increased adjacent spinal fractures and mortality. Percutaneous vertebral augmentation (PVA) included percutaneous vertebroplasty (PVP) and percutaneous kyphoplasty (PKP), nerve block (NB), and conservative treatment (CT) are used for the nonsurgery treatment strategy of OVCFs, however, current evaluation of their efficacy remains controversial.

Methods and analysis: A systematic literature search was carried out in PubMed, EMBASE, Web of Knowledge, and the Cochrane Central Register of Controlled Trials up to October 31, 2017. Randomized controlled trials (RCTs) were compared PVP, PKP, NB, or CT for treating OVCFs. The risk of bias for each trial was rated according to the Cochrane Handbook. Mean differences (MDs) with 95% confidence intervals (CIs) were utilized to express VAS (visual analog scale) outcomes. The network meta-analysis (NMA) of the comparative efficacy measured by change of VAS on acute/subacute and chronic OVCFs was conducted for a short-term (<4 weeks) and long-term (≥6–12 months) follow-up with the ADDIS software.

Results: A total of 18 trials among 1994 patients were included in the NMA. The PVA (PVP and PKP) had better efficacy than CT. PKP was first option in alleviating pain in the case of the acute/subacute OVCFs for long term, and chronic OVCFs for short term and long term, while PVP had the most superiority in the case of the acute/subacute OVCFs for short term. NB ranks higher probability than PKP and PVP on acute/subacute OVCFs in short and long-term, respectively.

Conclusions: The present results suggest that PVA (PVP/PKP) had better performance than CT in alleviating acute/subacute and chronic OVCFs pain for short and long-term. NB may be used as an alternative or before PVA, as far as pain relief is concerned. Various nonsurgery treatments including CT, PVA (PVP/PKP), NB, or a combination of these treatments are performed with the goal of reducing pain, stabilizing the vertebrae, and restoring mobility.

Abbreviations: ADDIS = aggregate data drug information system, CBP = chronic back pain, CT = conservative treatment, EQ-5D = EuroQol five-dimensional questionnaire, FEA = finite element analysis, NB = nerve block, NMA = network meta-analysis, ODI = Oswestry disability index, OVCFs = osteoporotic vertebral compression fractures, PKP = percutaneous kyphoplasty, PMMA = polymethylmethacrylate, PSRF = potential scale reduction factor, PVA = percutaneous vertebral augmentation, PVP = percutaneous vertebroplasty, QUALEFFO = quality of life questionnaire of the European foundation for osteoporosis, RCT = randomized controlled trials, RMDQ = Roland-Morris disability questionnaire, SF-36 = 36-item short form survey instrument, SI = sagittal index, VAS = visual analog scale, VBH = vertebral body height.

Keywords: balloon kyphoplasty, conservative treatment, nerve block, network meta-analysis, osteoporotic vertebral compression fractures, percutaneous kyphoplasty, percutaneous vertebroplasty

Editor: Jianxun Ding.

The authors have no conflicts of interest to disclose.

^a Department of Anesthesiology, Nanjing First Hospital, Nanjing Medical University, Nanjing, ^b Department of Pain Management, Huai'an Hospital Affiliated to Xuzhou Medical University, Second People's Hospital of Huai'an City, Huai'an, Jiangsu, China.

* Correspondence: Hong-Guang Bao, Department of Anesthesiology, Nanjing First Hospital, Nanjing Medical University, Nanjing, Jiangsu 210006, China (e-mail: hongguang_bao@hotmail.com).

Copyright © 2018 the Author(s). Published by Wolters Kluwer Health, Inc.

This is an open access article distributed under the terms of the Creative Commons Attribution-Non Commercial-No Derivatives License 4.0 (CCBY-NC-ND), where it is permissible to download and share the work provided it is properly cited. The work cannot be changed in any way or used commercially without permission from the journal.

Medicine (2018) 97:29(e11544)

Received: 19 April 2018 / Accepted: 21 June 2018

<http://dx.doi.org/10.1097/MD.00000000000011544>

1. Introduction

Osteoporosis is a systemic bone disorder with decrease in bone mineral density and degradation of skeletal microarchitecture. Asymptomatic osteoporosis can be observed in daily life, but the fracture may cause serious problems after a substantial trauma, even like a fall, sudden bending, lifting, or jumping movements. Osteoporotic vertebral compression fractures (OVCFs) are one of the most common complications of osteoporosis.^[1] OVCFs commonly afflicts most aged people resulting back pain, substantial vertebral deformity, functional disability, decreased quality of life and increased adjacent spinal fractures and mortality both in the short term and long term. OVCFs have a prevalence of >30% in the population older than 65 years during the remainder of their lifetimes, and they have become a more increasingly serious disease and a significant health problem worldwide that will obviously increase social and economic burdens to society and family.^[2]

When progressive spinal deformity occurred, subsequent to sagittal imbalance, overload posterior element of facet joints, paraspinal muscles, occasionally impingement of spinous processes, sympathetic nerve, or spinal nerve.^[3,4] Although the exact mechanism of pain remission remains unclear, pain is likely to be attributable to vertebral body and other factors such as paravertebral muscles, tendon,^[5] facet joint,^[6] sympathy nerve, and radiculopathy due to foraminal height or space decreases with vertebral body collapse, facet hypertrophy, decreased disc height, and foraminal or extraforaminal disc herniations.^[7] Various nonsurgery treatments including conservative treatment (CT), percutaneous vertebral augmentation (PVA, both PVP and PKP) and nerve block (NB), are performed with the goal of reducing pain, stabilizing the vertebrae, and restoring mobility. CT was considered the gold standard for treating OVCFs in the past, which includes treatments with a combination of antiosteoporotic drugs, short periods of bed rest or bedridden, postural reduction, various pharmacological agents, recreational therapy, bracing, and physical therapy.^[8] However, CT is certain effectively, and approximately one-third of patients remain persistent pain and progressive functional limitation.^[9] Moreover, CT does not restore vertebral height or reverse segmental kyphosis, and has many complications such as pneumonia, urinary infection, bed sores, bone demineralization, and deep vein thrombosis which are used to relieve symptoms and strengthen the spine. In PVP, polymethylmethacrylate (PMMA) is injected into the vertebral body to stabilize the fracture and release pain. In PKP, an inflatable bone tamp is used to restore segmental kyphosis or alignment, followed by injection of PMMA.^[10] While PVA is a minimally invasive procedure, it cannot be performed without risk, and complications including pulmonary embolism, infection, costly and paraplegia, and an increase in new adjacent vertebral compression fractures. However, nerve block could break vicious cycle to reduce pain,^[11] which is lower risk and less costly. Under the nerve block before PVP, the exact fracture level can be diagnosed by elimination of radiating pain and patients with OVCFs lie down with less painful during the procedure.^[12] Nerve block is an option or adjuvant in treating painful OVCF,^[13] but does not restore spine anatomy.

To address this controversy, it is inevitable to conduct an NMA to ascertain the relative short-term and long-term efficacy of PVP, PKP, NB, and CT for patients with acute/subacute and chronic OVCFs, respectively. Because the former NMA on OVCFs were only analyzed PVP, PKP, and CT treatments without nerve block,

and time-dependent on acute/subacute and chronic OVCFs for short-term (<4 weeks) and long-term (≥6–12 months) follow-ups,^[8,14,15] Moreover, malignancy-related spinal fractures was analyzed in this NMA.^[16,17]

2. Methods

2.1. Data sources and search strategy

PubMed, Embase, Web of Knowledge, and the Cochrane Central Register of Controlled Trials (CENTRAL) were search by 2 independent reviewers until October 31, 2017. Language or publication was limited to English. The search strategy will include related title, abstract, medical subject headings (MeSH) on RCTs regarding the nonsurgery treatment (PVP, PKP, CT, NB) of OVCFs. Related systematic reviews and meta-analyses were searched for additional-related studies. All analyses were based on previous published studies, thus ethical approval and patient consent were not required.

2.2. Study selection

Titles and abstracts of the identified searches were independently screened by 2 investigators. Any disagreement was resolved by a third reviewer. RCTs were included patients with OVCFs, published in full in English, and had a control group that underwent PVP, PKP, NB, or CT. Trials were excluded without fulfilling the eligibility criteria. After removing the duplicated and apparently unrelated studies, the remaining publications in full text were reviewed and confirmed. The most complete data and the longest follow-up were included during the multiple repeated data set trials. Excluded trials and the reasons for exclusion were summarized and ascertained by a third investigator. The main outcome variables on acute/subacute and chronic OVCFs were pain intensity (visual analog score, VAS) at short-term and long-term follow-ups. Nonrandomized trials, reviews, reports, abstract, meeting proceedings, comments, editorial, and letters were excluded.

2.3. Data extraction

Two investigators will independently extract the following information: trial characteristics, patient characteristics (such as mean fracture age, fracture site, fracture number, and follow-up), intervention details for each treatment group and outcome measures (VAS). Data were recalculated or measured by graphs when there is no direct information in the texts.^[14,18] Any disagreements were resolved by consensus among all the investigators.

In order to analysis quantitative and time-dependent effects, the outcomes were analyzed as short term (≤4weeks) and long term (≥6–12 months) on acute/subacute (≤8weeks) and chronic (>8 weeks) OVCFs. In cases where multiple time points were assessed, we utilized those closest to 4 weeks for the early and 6 to 12 months for the late groups.^[19] The data closest to the 4 weeks consider as the short term, closest to the 12 months as the long term.

2.4. Risk of bias assessment

The study quality was assessed the risk of bias according to the Cochrane Handbook by 2 independent investigators. The criteria for assessment involve 7 aspects, that is, random sequence generation, allocation concealment, blinding of participants and

personnel, blinding of outcome assessment, incomplete outcome data, selective reporting, and other bias. Each of the domains is determined as follows: “+,” low risk of bias; “?” unclear risk of bias; “-,” high risk of bias. Discrepancies were resolved via a consensus with a third reviewer.

2.5. Statistical analysis

For continuous outcomes of VAS, the mean difference (MD) with 95% confidence interval (CIs) was used to evaluate the effects of different treatments.^[14] The risk of bias summary was conducted by the RevMan software (version 5.3). The automated software Aggregate Data Drug Information System (ADDIS, version 2.0, GZ Groningen, the Netherlands), using Markov chain Monte Carlo methods in a Bayesian framework, was used for evaluating consistency with the node-splitting analysis. A consistency model was adopted when a P -value $> .05$ was observed during the comparison between direct and indirect evidence, and an inconsistency model was selected otherwise. NMA were performed acute/subacute (≤ 8 weeks) and chronic fractures (> 8 weeks) based on the duration of short term (< 4 weeks) or long term (≥ 6 –12 months) follow-ups, respectively.^[20–23] The convergence of iterative simulation was interpreted by the potential scale reduction factor (PSRF) calculated by the Brooks–Gelman–Rubin method. The rank probability for each treatment was also estimated graphically with the ADDIS software. Finally, funnel plot was used to verify the potential for publication bias.

3. Results

3.1. Included studies

The PRISMA flow chart was illustrated in Figure 1. After omitting duplicates and screening, 1409 literatures were identified from electronic database, 454 literatures could be reserved. Around 955 publications literatures were excluded by

the inclusion criteria. For 76 records with full-text publications, 378 were weeded out, since they did not include proper comparisons, targeted outcomes, or might report an identical trial.

3.2. Characteristics of included studies and quality assessment

After publications identified and checked, 27 RCTs^[21,22,24–48] meet the inclusion criteria. The duplicate set of patients from multiple RCTs were regarded as one RCT named by the complete data and latest one or two, leaving a total of 18 RCTs^[22,24,25,27,28,30,32,36,37,39–47] compared the efficacy of PVP, PKP, NB, and CT in the aspects of VAS. The primary traits were listed in Table 1, indicating that a total of 1994 patients, the mean age of the patients above 60 and majority of female (551 males and 1443 females). The individual trial sample size ranged from 16 to 191 patients. Among these 18 trials, VAS was the most frequent reported outcome by all the trials. Of the 18 RCTs, 7 RCTs compared PVP with CT, 4 RCTs compared PVP with PKP, 1 RCT compared PVP with NB, 1 RCTs compared PKP with CT, 3 RCTs compared PKP with sham, and 1 RCT compared NB with Sham (Fig. 2).

We considered 8 studies in the NMA for the acute/subacute OVCFs in short- and long-term follow-up, 7 studies for the chronic OVCFs in short term, 6 studies for the chronic OVCFs in long term. The results of the NMA might suggest that PVA (PVP and PKP) had better efficacy than CT in the case of the acute/subacute OVCFs in short term. PVP might be the first option in terms of acute/subacute OVCFs in short term. PKP showed the greatest probability of being the efficacy therapy on acute/subacute OVCFs in long term, and chronic OVCFs in short and long term. The analysis of probability on acute/subacute OVCFs for being the pain relief treatment showed that NB ranks higher probability than PKP and PVP in short and long term, respectively (Fig. 3).

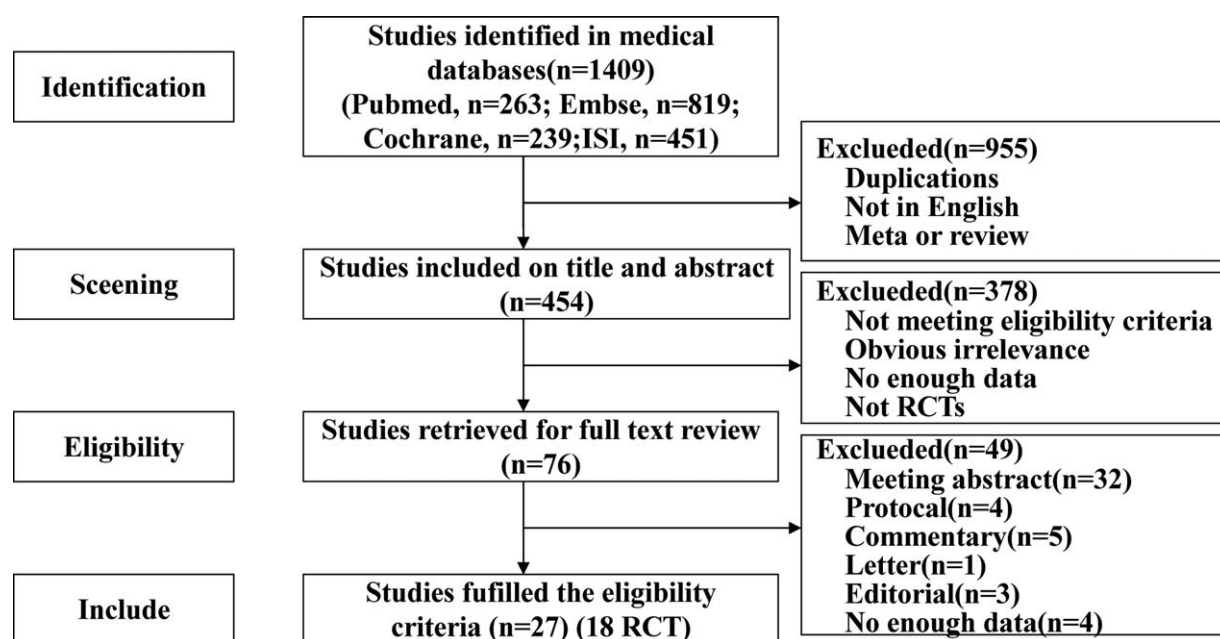


Figure 1. PRISMA flow diagram of the study selection process.

Table 1
Study characteristics of intervention and measurement of RCTs.

Included trials	Fracture site (no.)	Mean fracture age, weeks	Treatment	Female (%)	Age, years	Main outcomes	Follow-up, months
Chen D, 2013 (China)	NA (2.3±1.0) NA (2.0±1.0)	28.3±12.0 27.2±10.0	PVP CT	32 (70%) 30 (70%)	64.6±9.1 66.5±9.1	VAS, ODI RMDQ fractures	12
Blasco J, 2012 (Spain)	T4-L5 (2.5±1.6)	20.0±13.7 20.4±18.6	PVP CT	47 (73%) 50 (82%)	71.3±10.0 75.3±8.5	VAS QUALEFFO fractures	12
Farrokhi MR, 2011 (Iran)	T5-L5 (NA)	27.0 (4-50) 30.0 (6-54)	PVP CT	30 (75%) 30 (71%)	72 (59-90) 74 (55-87)	VAS, ODI VBH, SI fractures	36
Klazen CA, 2010 (the Netherlands, Belgium)	T5-L5 (2.4±1.9) T5-L5 (2.1±1.5)	4.2±2.4 3.8±2.3	PVP CT	70 (69%) 70 (69%)	75.2±9.8 75.4±8.4	VAS,RMDQ QUALEFFO fractures	12
Rousing R, 2010 (Denmark)	T7-L4 (NA)	1.2 CI (0.5, 1.9) 1.0 CI (0.3, 1.6)	PVP CT	19 (76%) 21 (88%)	80 (65-96) 80 (71-93)	VAS, EQ-5D, SF-36, fractures	12
Buchbinder R, 2009, KroonF, 2014 (Australia, New Zealand)	NA (1-2)	9 (3.8-13.0) 9.5 (3.0-17.0)	PVP Sham	31 (82%) 31 (78%)	74.2±14.0 78.9±9.5	VAS, EQ-5D RMDQ QUALEFFO fractures	24
Voormolen M, 2006 (the Netherlands, Belgium)	T6-L5 (1-3)	12.1 (6.8-19.7) 10.1 (6.6-20.1)	PVP CT	14 (78%) 14 (88%)	72 (59-84) 74 (55-88)	VAS, RMDQ QUALEFFO fractures	0.5
Liu JT, 2015 (China)	T12-L1 (1-2)	2.4±1.1 2.3±1.0	PVP PKP	39 (78%) 38 (76%)	72.3±7.6 74.3±6.4	VAS, VBH, SI, fractures	60
Endres S, 2012 (Germany)	T9-L5 (1) (1-3)	NA (≤6.0)	PVP PKP	12 (57%) 14 (70%)	71.3 (63-77) 63.3 (53-77)	VAS, ODI fractures	6
Dohm M, 2014 (USA)	T5-L5 (1-3)	NA (≤24.0)	PVP PKP	295 (77%)	75.6	VAS,ODI, EQ-5D,SF-36	24
Clark W, 2016 (Australia)	T4-L5 (1-2)	2.8±1.6 2.4±1.4	PVP Sham	48 (79%) 40 (68%)	80.0±7.0 81.0±7.0	VAS, EQ-5D, RMDQ QUALEFFO	6
Yang EZ, 2015 (China)	T5-L5 (1-2)	0.8±0.6 0.8±0.5	PVP CT	36 (64%) 33 (65%)	77.1±6.0 76.2±5.6	VAS, ODI, QUALEFFO	12
Wang B, 2016 (China)	NA (NA)	NA (NA, ≤8.0)	PVP NB	81 (81%) 84 (84%)	63.7±5.8 62.6±5.3	VAS, ODI SF-36,RMDQ fractures	12
Comstock BA, 2013 (USA, UK, Australia)	T4-L5 (1-3)	(NA,≤48.0)	PVP Sham	99 (76%)	73.8±9.5	VAS, RMDQ	12
Evans AJ, 2016 (USA)	T4-L5 (>=1)	11.9±18.4 7.1±6.7	PVP PKP	38 (68%) 43 (73%)	75.1±10.1 76.1±10.0	VAS, SF-36 RMDQ, EQ-5	12
Ohtori S, 2009 (Japan)	L3-L4 (1)	NA (acute /subacute)	NB Sham	30 (100%)	69.6±7.5	VAS, SF-36 RMDQ	4
Li YH, 2017 (China)	T10-L3 (NA)	NA (2 hours to 2 weeks)	PKP CT	10 (25%) 14 (35%)	74.3±7.0 74.3±7.4	VAS, ODI VBH, SI	6

CT=conservative treatment, EQ-5D=EuroQol five-dimensional questionnaire, NB=nerve block, ODI=Oswestry disability index, PVP=percutaneous vertebroplasty, PKP=percutaneous kyphoplasty, QUALEFFO=quality of life questionnaire of the European foundation for osteoporosis, RCT=randomized controlled trials, RMDQ=Roland-Morris disability questionnaire; SI=sagittal Index, SF-36=36-Item short form survey instrument, VBH=vertebral body height, VAS=visual analog scale; NA=not available.

The methodological quality in 18 RCTs was assessed as low risk of bias, especially in the domain of the “selection bias, attribution bias and reporting bias.” We found an unclear risk of bias domain in the “other bias.” The probability of bias in all domains was not considered as high risk of bias (Fig. 4). A node-splitting analysis was conducted to check for inconsistencies and showed that *P*-values were all > .5, indicating a lack of significant inconsistency. In addition, PSRF for the outcomes was between 0.99 and 1.01, suggesting a complete convergence and good iteration simulation. Given these results, a consistency model was adopted for NMA. Publication bias was not assessed because the number of trials was limited on acute/

subacute and chronic OVCFs in short term and long term, respectively (<10).

4. Discussion

OVCFs commonly afflicts most aged people resulting back pain, substantial vertebral deformity, functional disability, depression, stroke, decreased quality of life, and increased adjacent spinal fractures and mortality. When progressive spinal deformity occurred, subsequent to sagittal imbalance, overload anterior element of endplate and posterior element of facet joints, paraspinal muscles, occasionally impingement of spinous

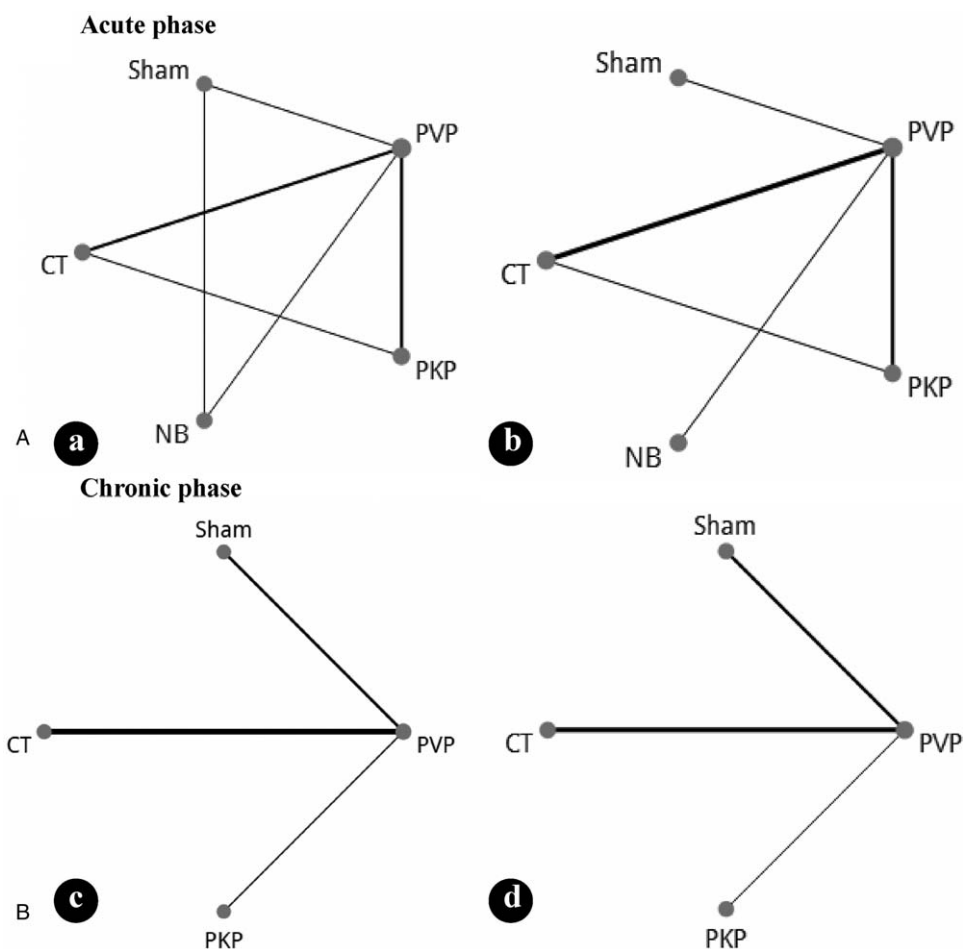


Figure 2. Network diagram of the treatments acute/subacute and chronic OVCFs for short-term (a, b)/long-term (c, d). CT=conservative treatment, NB=nerve block, PKP=percutaneous kyphoplasty, OVCFs=osteoporotic vertebral compression fractures, PVP=percutaneous vertebroplasty.

processes, sympathetic nerve, or spinal nerve.^[4] MR signal changes in facet joints and endplate due to subsequent impact of kyphosis.^[6,49] Sagittal imbalance was present by radiologic factors, like pelvic incidence, pelvic tilt, lumbar lordosis, and thoracic kyphosis.^[50] Increased sagittal vertical axis is correlation with less pain relief following vertebroplasty.^[51] The von Mises stresses increased under flexion load, vertical compression load have been also confirmed by finite element analysis (FEA), which simulates the mechanical behavior spinal fracture.^[52] Although the exact mechanism of pain remission remains unclear, there were several categories of axis and nonmidline pain from OVCFs patients.^[53] Pain is likely to be attributable to vertebral body and other factors such as paravertebral muscles, tendon,^[5] facet joint,^[6] sympathy nerve, and radiculopathy due to foraminal height or space decreases with vertebral body collapse, facet hypertrophy, decreased disc height, foraminal, or extraforaminal disc herniations^[7] (Fig. 5). In some instances, thoracic and lumbar OVCFs without definite canal compromise cause radiculopathic radiating pain and claudication.^[53] Nonmidline pain included radicular pain and referred pain, which is a well-discriminated neurogenic pain caused by nerve impingement, whereas distant referred “pain is referred to the region corresponding roughly to the somatic distribution of the afferent fibers of the spinal nerve with which the afferent sympathetic fibers enter the spinal canal.”^[53] Although around one-third of OVCFs is clinically diagnosed and treated, approximately 10%

to 20% patients with OVCFs may develop to chronic back pain (CBP) and impair quality of life. Therefore, various nonsurgery treatments including PVA (PVP/PKP), NB, and CT are performed with the goal of reducing pain, stabilizing the vertebrae, and restoring mobility.

Numerous trials had certified that PVA could spontaneously relieve pain when pain mainly origin from the fracture itself,^[3] which was consistent to our result that PVA(PVP/PKP) had better performance than CT in pain relief. The exact mechanism of pain remission in PVP remains controversial. This function was possibly achieved in at least two known ways, mechanical stabilization reducing microfractures of the fractured site applied to nociceptive endings within the bone, as well as thermal necrosis or chemotoxicity of intraosseous pain receptors.^[54,55] However, the treatment-related adverse events cannot be ignored, such as the cement leakage, the incidence was reported as approximately 33% in the PVP arm.^[56] In consideration of the existence of cement “container” for PKP with lower the incidence of cement leakage than PVP, but still have hazard factors to cause paraplegia in a certain probability.^[8] However, the therapeutic effect of PVP for OVCFs was questioned owing to 2 NEJM multicenter, randomized, placebo-controlled trials, reporting that sham injection (local anaesthetic as “control” group) provided similar pain relief and restoration of function as PVP.^[37,46] Different patient population of fracture age (mean fracture age from 8.7 to 19.5 weeks) and treatment were possibly

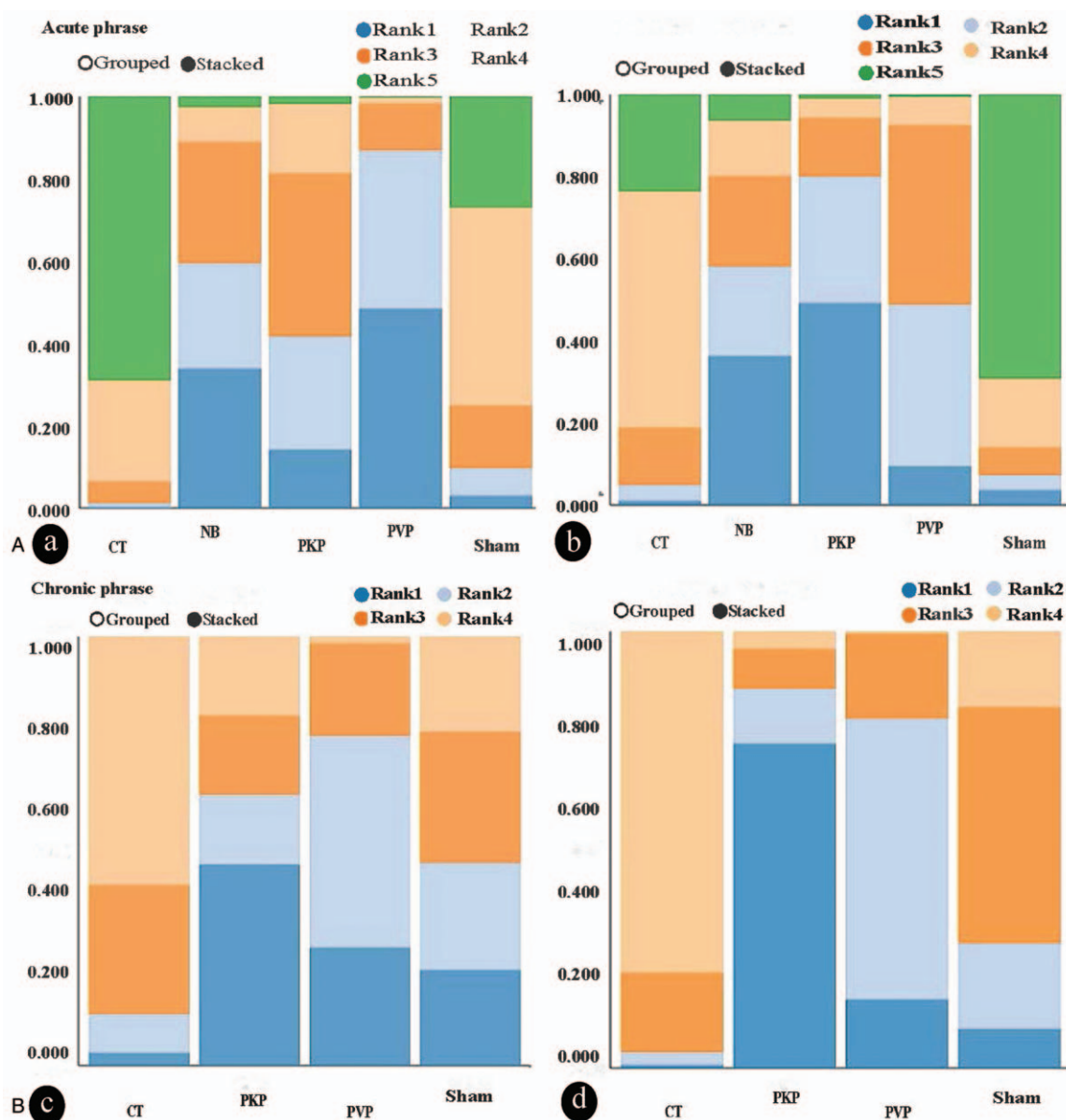
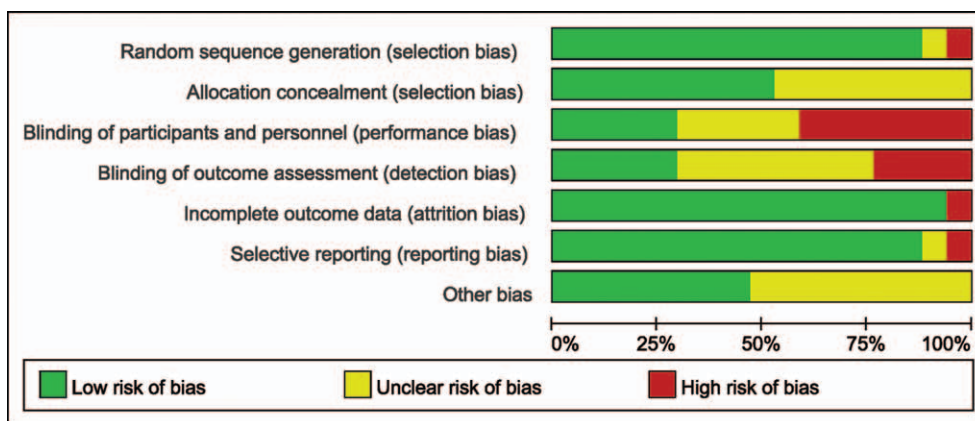


Figure 3. (a–d) Rank probability of the best treatment. Graph shows the probability analysis of the best treatment for acute/subacute OVCFs for short-term (a) and long term (b) probability of the best treatment for chronic OVCFs for short term (c), and probability of the best treatment for chronic OVCFs for long-term (d). CT = conservative treatment, NB = nerve block, OVCFs = osteoporotic vertebral compression fractures, PKP = percutaneous kyphoplasty, PVP = percutaneous vertebroplasty.

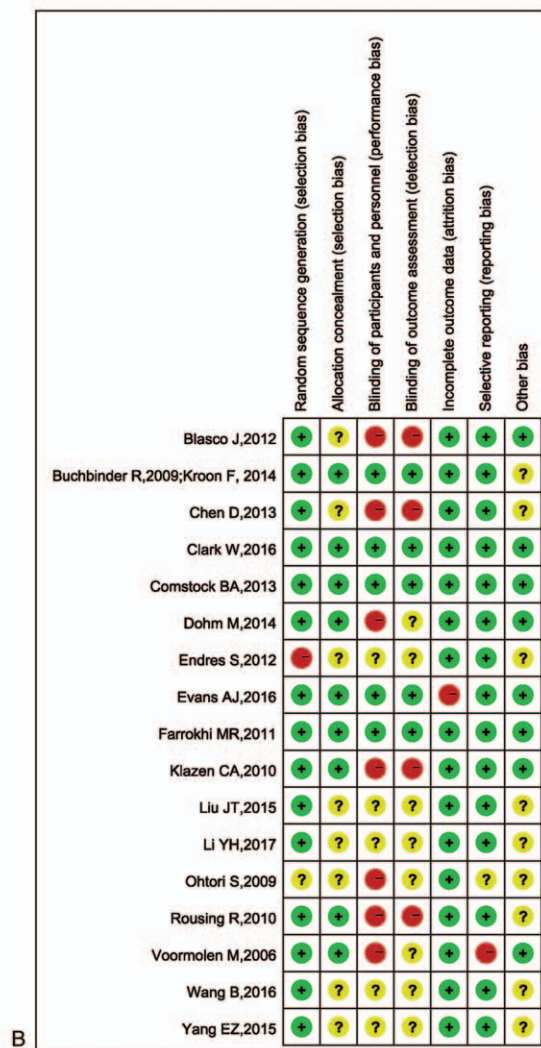contributed the majority of patients to this report. Both PVP and control groups in these 2 studies had local anesthetic with bupivacaine infiltrated around the posterior elements of the spine (facet joints and spine periosteum). Administration of local anesthetics agents reportedly creates as a nerve block to have long-term pain relief benefits through complex neurophysiologic mechanisms.^[57] These factors might contribute to the impaired effect of PVP for some chronic OVCFs. For a more convincing conclusion, more and large sample size of RCTs with sham controls should be fulfilled.^[58]

Nerve block could break the vicious pain cycle to release pain for short term or long term,^[11] which is lower risk and less costly. NB ranks higher probability than PKP and PVP on acute/subacute OVCFs in short and long term, respectively. Several studies showed numerous nerve block of successful treatment in

OVCFs patients, such as facet joint block for thoracolumbar or lumbar axial pain, bilateral or unilateral hip pain, and referred pain of the low extremities,^[59] only facet joint block,^[3,60] PVP with facet joint block^[12,61] or medial branch block of the facet joint for thoracic or lumbar vertebral bodies,^[62] gray ramus communicans nerve block in thoracic and lumbar spine,^[63] nerve-root injections for thoracic or lumbar radiculopathy,^[64] L2 spinal nerve block for acute/subacute midlumbar compression fracture,^[28] and radiofrequency resulted in short-term or long-term pain relief.^[19,65] Nerve block is an option in treating painful OVCFs in the AAOS Clinical Practice Guideline,^[13] but does not restore vertebral height or reverse kyphotic deformity. Nerve block is effective in relieve pain in patients with OVCFs and that these patients should be recognized for this treatment as an alternative or adjuvant choice before PVA.^[64]



A



B

Figure 4. Results of quality assessment. (A) Summary of the risk of bias for included randomized clinical trials. (B) Graph of the risk of bias for included randomized clinical trials.

Our network meta-analysis has some limitations regarding 3 categories of heterogeneities methodological, clinical, and statistical forms. Methodological heterogeneity varies in the demographics and co-morbidities of all of the included trials participants were not reported. The clinical heterogeneity differs in inclusion–exclusion criteria (e.g., the fracture age, the volume of cement, bilateral or unilateral, and time endpoints). Moreover, various antiosteoporotic drugs in certain patients were not

examined due to lacking of information. The investigated outcomes were restricted to the quality of current trials which mostly potency on pain relief. Around 64% and 70% of patients in papers by Buchbinder et al and Kallmes et al, declined to participate in those trials, respectively, raised major concerns selection bias. Owing to the limited number of included trials and various outcomes measures, we could not analyze the influence of other clinically relevant factors, for example, initial medication,

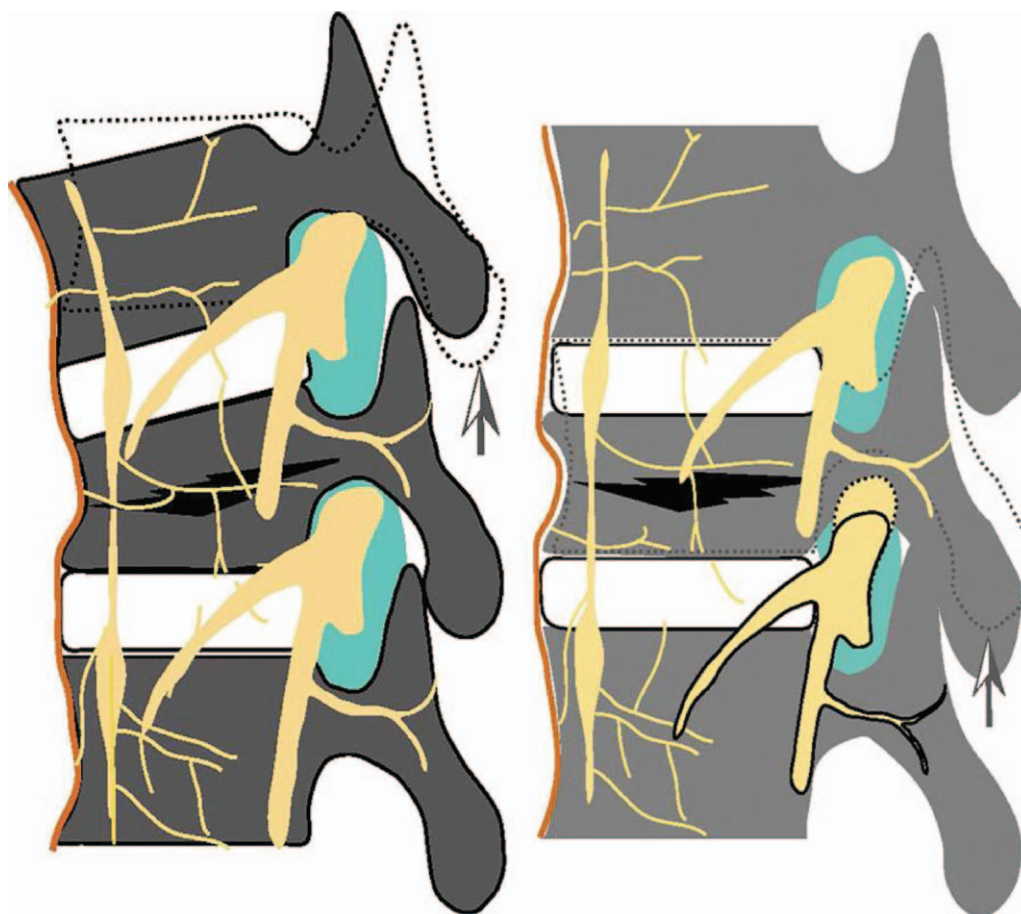


Figure 5. A graphic model of pain action with OVCFs. OVCFs=osteoporotic vertebral compression fractures.

daily life, and vertebral fractures site, number and types. Incomplete data and potentially biased outcomes were caused by missing information such as loss to follow-up, declining participation, and crossover. But some of them used ITT analysis to presumably decrease the bias. Therefore, further high quality, large sample size and more research indexes RCTs between different treatments were demanded to replenish this NMA to offer more invaluable and convincing conclusion.

5. Conclusion

The present results suggest that PVA (PVP/PKP) had better performance than CT in alleviating acute/subacute and chronic OVCFs pain, NB may be used as an alternative or before PVA, as far as pain relief is concerned. NB without restoration vertebral height or correction segmental kyphosis, has some advantages over PVA with lower risk and less costly, and associated complications, such as vein embolism and neural injury. Therefore, various nonsurgery treatments including conservative treatment, PVA (PVP/PKP), nerve block, or a combination of these treatments are performed with the goal of reducing pain, stabilizing the vertebrae, and restoring mobility.

Author contributions

Data curation: Xiao-Hua Zuo, Xue-Piao Zhu.

Formal analysis: Xiao-Hua Zuo, Chen-Jie Xu.

Investigation: Qian-Xi Zhang.

Methodology: Xiao-Hua Zuo, Hao Chen.

Project administration: Hong-guang Bao.

Resources: Chen-Jie Xu.

Software: Xiao-Hua Zuo, Xian-Zhong Gao.

Supervision: Hong-Guang Bao.

Validation: Hao Chen.

Visualization: Xian-Zhong Gao.

Writing – original draft: Xiao-Hua Zuo.

Writing – review & editing: Hong-Guang Bao.

References

- [1] Strom O, Borgstrom F, Kanis JA, et al. Osteoporosis: burden, health care provision and opportunities in the EU: a report prepared in collaboration with the International Osteoporosis Foundation (IOF) and the European Federation of Pharmaceutical Industry Associations (EFPIA). *Arch Osteoporos* 2011;6:59–155.
- [2] Zhao JG, Zeng XT, Wang J, et al. Association between calcium or vitamin D supplementation and fracture incidence in community-dwelling older adults: a systematic review and meta-analysis. *JAMA* 2017;318:2466–82.
- [3] Wilson DJ, Owen S, Corkill RA. Facet joint injections as a means of reducing the need for vertebroplasty in insufficiency fractures of the spine. *Eur Radiol* 2011;21:1772–8.
- [4] Zhang YL, Shi LT, Tang PF, et al. Correlation analysis of osteoporotic vertebral compression fractures and spinal sagittal imbalance. *Orthopaed* 2017;46:249–55.

- [5] Georgy BA. Interventional techniques in managing persistent pain after vertebral augmentation procedures: a retrospective evaluation. *Pain Physician* 2007;10:673–6.
- [6] Lehman VT, Wood CP, Hunt CH, et al. Facet joint signal change on MRI at levels of acute/subacute lumbar compression fractures. *AJNR* 2013;34:1468–73.
- [7] Kim DE, Kim HS, Kim SW, et al. Clinical analysis of acute radiculopathy after osteoporotic lumbar compression fracture. *J Korean Neurosurg Soc* 2015;57:32–5.
- [8] Zhang YL, Shi LT, Tang PF, et al. Comparison of the efficacy between two micro-operative therapies of old patients with osteoporotic vertebral compression fracture: a network meta-analysis. *J Cell Biochem* 2017; 118:3205–12.
- [9] Ye LQ, Liang J, Jiang XB, et al. Risk factors for the occurrence of insufficient cement distribution in the fractured area after percutaneous vertebroplasty in osteoporotic vertebral compression fractures. *Pain Physician* 2018;21:E33–42.
- [10] Yuan WH, Hsu HC, Lai KL. Vertebroplasty and balloon kyphoplasty versus conservative treatment for osteoporotic vertebral compression fractures: a meta-analysis. *Medicine (Baltimore)* 2016;95:e4491.
- [11] Hasue M. Pain and the nerve root: an interdisciplinary approach. *Spine* 1993;18:2053–8.
- [12] Kim TK, Kim KH, Kim CH, et al. Percutaneous vertebroplasty and facet joint block. *J Korean Med Sci* 2005;20:1023–8.
- [13] Esses SI, McGuire R, Jenkins J, et al. The treatment of symptomatic osteoporotic spinal compression fractures. *J Am Acad Orthop Surg* 2011;19:176–82.
- [14] Chen LX, Li YL, Ning GZ, et al. Comparative efficacy and tolerability of three treatments in old people with osteoporotic vertebral compression fracture: a network meta-analysis and systematic review. *PLoS One* 2015;10:e0123153.
- [15] Zhao S, Xu CY, Zhu AR, et al. Comparison of the efficacy and safety of 3 treatments for patients with osteoporotic vertebral compression fractures: a network meta-analysis. *Medicine* 2017;96:
- [16] Song DW, Meng B, Gan MF, et al. The incidence of secondary vertebral fracture of vertebral augmentation techniques versus conservative treatment for painful osteoporotic vertebral fractures: a systematic review and meta-analysis. *Acta Radiol* 2015;56:970–9.
- [17] Wardlaw D, Cummings SR, Van Meirhaeghe J, et al. Efficacy and safety of balloon kyphoplasty compared with non-surgical care for vertebral compression fracture (FREE): a randomised controlled trial. *Lancet* 2009;373:1016–24.
- [18] Li L, Ren J, Liu J, et al. Results of vertebral augmentation treatment for patients of painful osteoporotic vertebral compression fractures: a meta-analysis of eight randomized controlled trials. *PLoS One* 2015;10: e0138126.
- [19] Anderson PA, Froysheter AB, Tontz WLJ. Meta-analysis of vertebral augmentation compared with conservative treatment for osteoporotic spinal fractures. *J Bone Miner Res* 2013;28:372–82.
- [20] Zhao G, Liu X, Li F. Balloon kyphoplasty versus percutaneous vertebroplasty for treatment of osteoporotic vertebral compression fractures (OVCFs). *Osteoporos Int* 2016;27:2823–34.
- [21] Rousing R, Hansen KL, Andersen MO, et al. Twelve-months follow-up in forty-nine patients with acute/semiacute osteoporotic vertebral fractures treated conservatively or with percutaneous vertebroplasty: a clinical randomized study. *Spine (Phila Pa 1976)* 2010;35:478–82.
- [22] Wang B, Guo H, Yuan L, et al. A prospective randomized controlled study comparing the pain relief in patients with osteoporotic vertebral compression fractures with the use of vertebroplasty or facet blocking. *Eur Spine J* 2016;25:3486–94.
- [23] Lee WS, Sung KH, Jeong HT, et al. Risk factors of developing new symptomatic vertebral compression fractures after percutaneous vertebroplasty in osteoporotic patients. *Eur Spine J* 2006;15:1777–83.
- [24] Yang EZ, Xu JG, Huang GZ, et al. Percutaneous vertebroplasty versus conservative treatment in aged patients with acute osteoporotic vertebral compression fractures: a prospective randomized controlled clinical study. *Spine (Phila Pa 1976)* 2016;41:653–60.
- [25] Voormolen MH, Mali WP, Lohle PN, et al. Percutaneous vertebroplasty compared with optimal pain medication treatment: short-term clinical outcome of patients with subacute or chronic painful osteoporotic vertebral compression fractures. The VERTOS study. *AJNR* 2007;28: 555–60.
- [26] Staples MP, Howe BM, Ringler MD, et al. New vertebral fractures after vertebroplasty: 2-year results from a randomised controlled trial. *Arch Osteoporos* 2015;10:229.
- [27] Rousing R, Andersen MO, Jespersen SM, et al. Percutaneous vertebroplasty compared to conservative treatment in patients with painful acute or subacute osteoporotic vertebral fractures: three-months follow-up in a clinical randomized study. *Spine (Phila Pa 1976)* 2009; 34:1349–54.
- [28] Ohtori S, Yamashita M, Inoue G, et al. L2 spinal nerve-block effects on acute low back pain from osteoporotic vertebral fracture. *J Pain* 2009;10:870–5.
- [29] Martinez-Ferrer A, Blasco J, Carrasco JL, et al. Risk factors for the development of vertebral fractures after percutaneous vertebroplasty. *J Bone Miner Res* 2013;28:1821–9.
- [30] Liu JT, Li CS, Chang CS, et al. Long-term follow-up study of osteoporotic vertebral compression fracture treated using balloon kyphoplasty and vertebroplasty. *J Neurosurg Spine* 2015;23:94–8.
- [31] Liu JT, Liao WJ, Tan WC, et al. Balloon kyphoplasty versus vertebroplasty for treatment of osteoporotic vertebral compression fracture: a prospective, comparative, and randomized clinical study. *Osteoporos Int* 2010;21:359–64.
- [32] Li YH, Zhu J, Xie CF. A comparative study of percutaneous kyphoplasty and conservative therapy on vertebral osteoporotic compression fractures in elderly patients. *Int J Clin Exp Med* 2017;10:8139–45.
- [33] Leali PT, Solla F, Maestretti G, et al. Safety and efficacy of vertebroplasty in the treatment of osteoporotic vertebral compression fractures: a prospective multicenter international randomized controlled study. *Clin Cases Miner Bone Metab* 2016;13:234–6.
- [34] Kroon F, Staples M, Ebeling PR, et al. Two-year results of a randomized placebo-controlled trial of vertebroplasty for acute osteoporotic vertebral fractures. *J Bone Miner Res* 2014;29:1346–55.
- [35] Klazen CA, Venmans A, de Vries J, et al. Percutaneous vertebroplasty is not a risk factor for new osteoporotic compression fractures: Results from VERTOS II. *AJNR* 2010;31:1447–50.
- [36] Klazen CA, Lohle PN, de Vries J, et al. Vertebroplasty versus conservative treatment in acute osteoporotic vertebral compression fractures (Vertos II): an open-label randomised trial. *Lancet* 2010; 376:1085–92.
- [37] Kallmes DF, Comstock BA, Heagerty PJ, et al. A randomized trial of vertebroplasty for osteoporotic spinal fractures. *N Engl J Med* 2009; 361:569–79.
- [38] Kallmes DF, Comstock BA, Gray LA, et al. Baseline pain and disability in the investigational vertebroplasty efficacy and safety trial. *AJNR* 2009; 30:1203–5.
- [39] Farrokhi MR, Alibai E, Maghami Z. Randomized controlled trial of percutaneous vertebroplasty versus optimal medical management for the relief of pain and disability in acute osteoporotic vertebral compression fractures. *J Neurosurg Spine* 2011;14:561–9.
- [40] Evans AJ, Kip KE, Brinjikji W, et al. Randomized controlled trial of vertebroplasty versus kyphoplasty in the treatment of vertebral compression fractures. *J Neurointerv Surg* 2016;8:756–63.
- [41] Endres S, Badura A. Shield kyphoplasty through a unipedicular approach compared to vertebroplasty and balloon kyphoplasty in osteoporotic thoracolumbar fracture: a prospective randomized study. *Orthop Traumatol Surg Res* 2012;98:334–40.
- [42] Dohm M, Black CM, Dacre A, et al. A randomized trial comparing balloon kyphoplasty and vertebroplasty for vertebral compression fractures due to osteoporosis. *AJNR* 2014;35:2227–36.
- [43] Comstock BA, Sitalani CM, Jarvik JG, et al. Investigational vertebroplasty safety and efficacy trial (INVEST): patient-reported outcomes through 1 year. *Radiology* 2013;269:224–31.
- [44] Clark W, Bird P, Gonski P, et al. Safety and efficacy of vertebroplasty for acute painful osteoporotic fractures (VAPOUR): a multicentre, randomised, double-blind, placebo-controlled trial. *Lancet* 2016;388: 1408–16.
- [45] Chen D, An ZQ, Song S, et al. Percutaneous vertebroplasty compared with conservative treatment in patients with chronic painful osteoporotic spinal fractures. *J Clin Neurosci* 2014;21:473–7.
- [46] Buchbinder R, Osborne RH, Ebeling PR, et al. A randomized trial of vertebroplasty for painful osteoporotic vertebral fractures. *N Engl J Med* 2009;361:557–68.
- [47] Blasco J, Martinez-Ferrer A, Macho J, et al. Effect of vertebroplasty on pain relief, quality of life, and the incidence of new vertebral fractures: a 12-month randomized follow-up, controlled trial. *J Bone Miner Res* 2012;27:1159–66.
- [48] Hao DJ, Guo H, Wang B, et al. Treatment for acute or subacute osteoporosis vertebral compression fractures: Percutaneous vertebroplasty versus facets blocking (a clinical randomized study). *Spine J* 2014;15:S124–5.
- [49] Patil S, Nene AM. Predictors of kyphotic deformity in osteoporotic vertebral compression fractures: a radiological study. *Eur Spine J* 2014;23:2737–42.

- [50] Yi HJ, Jeong JH, Im SB, et al. Percutaneous vertebroplasty versus conservative treatment for one level thoracolumbar osteoporotic compression fracture: results of an over 2-year follow-up. *Pain Physician* 2016;19:E743–50.
- [51] Kim YC, Bok DH, Chang HG, et al. Increased sagittal vertical axis is associated with less effective control of acute pain following vertebroplasty. *Bone Joint Res* 2016;5:544–51.
- [52] Zhao WT, Qin DP, Zhang XG, et al. Biomechanical effects of different vertebral heights after augmentation of osteoporotic vertebral compression fracture: a three-dimensional finite element analysis. *J Orthop Surg Res* 2018;13:32.
- [53] Gibson JE, Pilgram TK, Gilula LA. Response of nonmidline pain to percutaneous vertebroplasty. *AJR* 2006;187:869–72.
- [54] Belkoff SM, Mathis JM, Jasper LE, et al. The biomechanics of vertebroplasty. The effect of cement volume on mechanical behavior. *Spine (Phila Pa 1976)* 2001;26:1537–41.
- [55] Belkoff SM, Mathis JM, Jasper LE, et al. An ex vivo biomechanical evaluation of a hydroxyapatite cement for use with vertebroplasty. *Spine (Phila Pa 1976)* 2001;26:1542–6.
- [56] Schofer MD, Efe T, Timmesfeld N, et al. Comparison of kyphoplasty and vertebroplasty in the treatment of fresh vertebral compression fractures. *Arch Orthop Trauma Surg* 2009;129:1391–9.
- [57] Manchikanti L, Singh V, Falco FJ, et al. Effectiveness of thoracic medial branch blocks in managing chronic pain: a preliminary report of a randomized, double-blind controlled trial. *Pain Physician* 2008;11:491–504.
- [58] Shi MM, Cai XZ, Lin T, et al. Is there really no benefit of vertebroplasty for osteoporotic vertebral fractures? A meta-analysis. *Clin Orthop Relat Res* 2012;470:2785–99.
- [59] Park KD, Jee H, Nam HS, et al. Effect of medial branch block in chronic facet joint pain for osteoporotic compression fracture: one year retrospective study. *Ann Rehabil Med* 2013;37:191–201.
- [60] Im TS, Lee JW, Lee E, et al. Effects of facet joint injection reducing the need for percutaneous vertebroplasty in vertebral compression fractures. *Cardiovasc Intervent Radiol* 2016;39:740–5.
- [61] Mitra R, Do H, Alamin T, et al. Facet pain in thoracic compression fractures. *Pain Med* 2010;11:1674–7.
- [62] Bogduk N, MacVicar J, Borowczyk J. The pain of vertebral compression fractures can arise in the posterior elements. *Pain Med* 2010;11:1666–73.
- [63] Chandler G, Dalley G, Hemmer J, et al. Comparison of thoracic versus lumbar gray ramus communicans nerve block in the treatment of painful osteoporotic vertebral compression fracture. *Pain Physician* 2000;3:240.
- [64] Kim DJ, Yun YH, Wang JM. Nerve-root injections for the relief of pain in patients with osteoporotic vertebral fractures. *J Bone Joint Surg Br* 2003;85:250–3.
- [65] O'Connor RC, Andary MT, Russo RB, et al. Thoracic radiculopathy. *Phys Med Rehabil Clin N Am* 2002;13:623–44. viii.