

# Surgical Tips for Aesthetic Lower Lid Blepharoplasty: Prevention of Round Eye

Marco Klinger, MD\*  
 Valeriano Vinci, MD††  
 Maria Angela Romeo, MD†  
 Andrea Battistini, MD\*  
 Francesco Klinger, MD§  
 Valeria Bandi, MD\*  
 Luca Maione, MD\*  
 Paolo Vinciguerra, MD†¶  
 Alessandra Di Maria, MD†¶

**Purpose:** In the present study, we highlight surgical tips based on our experience in lower eyelid blepharoplasty. These have been shown to be crucial in the prevention of several complications, specifically lateral lower-lid displacement.

**Methods:** A series of bilateral lower-lid blepharoplasties were performed on 280 patients at Humanitas-Research-Hospital (Milan, Italy) between January 2016 and January 2020. Patients with a history of lower-lid blepharoplasty and patients requiring canthopexy/canthoplasty were excluded. Needing to singularly evaluate and correct several lower-eyelid structures to obtain a harmonic result, we preoperatively assessed the amount of skin excess, the eyelid margin malposition relative to the globe, and the presence/absence of herniated fat-pads. Pre- and postoperative standard photographs were collected. Patients were evaluated by measuring scleral show, snap-back test, and distraction test. Blinded-fashioned photograph analysis was performed by independent plastic and oculoplastic surgeons who did not execute the procedures. A visual analogue scale was administered to all patients to assess satisfaction.

**Results:** In total, 280 patients underwent successful lower blepharoplasty, with satisfactory results of scleral show, snap-back test, and distraction test. Of the 280 patients, four presented postoperative complications. At 10-month follow-up visit, we achieved a mean patient visual analogue scale satisfaction score of 8.4. Postoperative surgeon's photographs mean score was 4.5.

**Conclusions:** Without the use of muscle flaps, our technique averts tarsal ligament misposition, preserves orbicularis-muscle innervation, and limits thermal spread, assuring excellent stability of results and high patient and surgeon satisfaction. Cosmetic outcome in terms of symmetry, appearance, and lower lid line definition revealed high satisfaction with the result over time, with a remarkably low complication rate. (*Plast Reconstr Surg Glob Open* 2023; 11:e5092; doi: 10.1097/GOX.0000000000005092; Published online 3 July 2023.)

## INTRODUCTION

Lower eyelids are extremely predisposed to the effects of aging, such as skin laxity, loss of ligamentous

support, atonia, and lower orbicularis-oculi muscle ptosis, as well as thinning of the orbital septum, which leads to orbital-fat prolapse.<sup>1,2</sup> These physiological transformations are mediated by gravitational and mechanical factors, which lead to retro-orbital tissues loosening. Nowadays, it is well known that an appropriate restoration to youthful appearance by lower eyelid blepharoplasty varies according to the specific lower eyelid defect pathogenesis. Hence, an overall evaluation of different orbital structures is paramount to optimize lower lid rejuvenation.

Lower eyelid malposition, with severity ranging from increased scleral show to ectropion, is the most common complication following a lower eyelid blepharoplasty.<sup>3</sup> "Round eye" is an anatomical condition in which the sclera area is exposed.<sup>4</sup> As a matter of fact, anterior lamellar shortening, excessive skin removal, and scar contraction following a lower blepharoplasty may be the causative agents for inferior traction and eyelid rounding, leading to excessive scleral show.<sup>5,6</sup> Round eye can be considered

*From the \*Plastic Surgery Unit, Department of Medical Biotechnology and Translational Medicine BIOMETRA, Humanitas Clinical and Research Hospital, Reconstructive and Aesthetic Plastic Surgery School, University of Milan, Milan, Italy; †Department of Biomedical Sciences, Humanitas University, Milan, Italy; ‡Department of Aesthetic Plastic and Reconstructive Surgery, Humanitas Clinical and Research Center-IRCCS, Milan, Italy; §University of Milan, Department of Health Sciences, Ospedale San Paolo, Milan, Italy; and ¶Department of Ophthalmology, Humanitas Clinical and Research Center-IRCCS, Milan, Italy.*

*Received for publication February 15, 2023; accepted May 5, 2023.*

*Copyright © 2023 The Authors. Published by Wolters Kluwer Health, Inc. on behalf of The American Society of Plastic Surgeons. This is an open-access article distributed under the terms of the Creative Commons Attribution-Non Commercial-No Derivatives License 4.0 (CCBY-NC-ND), where it is permissible to download and share the work provided it is properly cited. The work cannot be changed in any way or used commercially without permission from the journal.*

DOI: 10.1097/GOX.0000000000005092

Disclosure statements are at the end of this article, following the correspondence information.

a disabling complication of lower lid blepharoplasty, affecting both aesthetic outcome and visual function, significantly impacting eye discomfort.<sup>7</sup> Several surgical approaches were adopted for round eye prevention during the last decades, and their evolution has been driven by the nature of postoperative complications, given the high rate of unsatisfactory results.<sup>5,7,8</sup>

Herein, we describe surgical tips based on our experience, which have helped us in preventing complications, more specifically, lateral lower lid displacement, with long-lasting results, thus guaranteeing a greater patient visual analogue scale (VAS) satisfaction score during an aesthetic lower lid blepharoplasty.

## MATERIALS AND METHODS

### Clinical Assessment and Patient Selection

Between January 2016 and January 2020, we performed bilateral lower lid blepharoplasty on 280 patients at Humanitas Research Hospital (Rozzano, Milano, Italy), following our technique. We use this technique for all our patients, as it was shown to prevent round eye. Patients with a history of previous lower lid blepharoplasty and patients requiring canthopexy or canthoplasty were excluded from this study.

All patients were evaluated preoperatively in terms of ocular surface parameters: (a) lower eyelid retraction using “scleral show,” defined as the visible portion of the sclera between the upper rim of the lower eyelid and the inferior limbus; (b) lower eyelid laxity using the snap-back test (Table 1), the distraction test, and the assessment of eyelid margin malposition relative to the globe<sup>9</sup>; (c) amount of skin excess; (d) asymmetry; and (e) presence/absence of orbital fat herniation (7.0.1. Adobe Photoshop-Inc, California, was used to measure the distance).

Routine complete blood count and ECG were performed in all patients. Preoperative standard photographs were collected, with the camera at a fixed 1-meter distance. Blinded-fashion preoperative and 10-month postoperative photograph analysis was performed by one independent plastic surgeon and one oculoplastic surgeon who did not execute the procedures to estimate both functional and aesthetic outcomes. Hence, postoperative photographs were scored from 1 (unsatisfactory outcome) to 5 (optimal outcome).

Finally, at 10-month follow-up visit, a VAS from 0 to 10 was administered to all patients to assess patient satisfaction in terms of lower lid appearance and symmetry

**Table 1. Snap-Back Test**

Grade	Dynamics of Eyelid Response
Grade 0	Normal lid, which immediately springs back into the globe.
Grade 1	Lid takes 2 or 3s.
Grade 2	Lid takes 4 or 5s.
Grade 3	Lid takes more than 5s, but it returns to its normal position with blinking.
Grade 4	Lid never returns to the normal position.

### Takeaways

**Question:** How to prevent surgical complications in lower eyelid blepharoplasty?

**Findings:** We highlight novel insights into a surgical technique for lower eyelid reconstructive surgery based on our 20-year experience in this specific field, which avoids the use of muscle flaps, thus preventing tarsal ligament dystopia, limiting thermal spread, and preserving orbicularis-muscle innervation. We discuss clinical manifestations, such as epiphora, dry eye, blurred vision, eye discomfort, and photophobia, and their relation to lower lid displacement.

**Meaning:** Our technique helped us in preventing surgical complications, specifically lateral canthal dystopia, which ranges from round eye to ectropion. This improves postoperative outcomes, revealing high patient and surgeon satisfaction over time.

compared to baseline. The VAS was shown to be less vulnerable to bias from confounding factors compared to other scales.<sup>10</sup>

### Surgical Technique

Preoperative antibiotic prophylaxis with one shot cefazolin-2000 mg-i.v. was administered to all patients. All procedures were performed under local anesthesia (mepivacaine 20 mg/mL with epinephrine 1:200,000) and procedural sedation. A transcutaneous approach, 1mm below the eyelash line, was used in all patients enrolled in this study. A 2-mm-long myocutaneous incision was made inferolaterally to the lateral canthus, then straight iris scissors were used to extend the incision medially, 2mm before the vertical projection of the medial canthus. Using the same straight scissors, an orbicularis muscle skin flap was dissected inferiorly (in a preseptal plane) down to the inferior orbital rim, releasing orbicularis retaining ligaments. Lateral dissection was limited within the lateral orbital rim to preserve the orbicularis innervation provided by terminal branches of the zygomatic branch of the facial nerve. The septum was then incised to identify and remove medial and central fat pads. We usually do not remove fat from the lateral area unless it is frankly herniated during preoperative evaluation. Also, we always try to be as conservative as possible in both dissection and fat-pad removal to avoid lateral area lymphatic disruption and denervation. Care was taken to ensure adequate hemostasis of fat-pad pedicles to prevent possible bleeding, by using bipolar forceps. Only the amount of fat coming out of the septal incision was removed to avoid a “hollow-eye appearance” that is not considered a sign of youthfulness. The orbital septum was not sutured.

At this point, the skin flap was gently grasped with forceps and pulled temporally and upward (performing a snap test); after recoiling, it was possible to see the skin excess covering the eyeball, which corresponds to the amount of skin to resect. Care was taken to avoid excessive vertical tension on the flap. The triangular wedge

corresponding to the redundant skin was, therefore, excised with care along the upper border of the flap, preserving the integrity of the underlying pretarsal orbicularis oculi.

Once the vertical skin excess was removed, we corrected the horizontal skin laxity, which could be obtained in two different ways. This process is elucidated in more detail in the next section. Multiple interrupted sutures were then used to close the skin with single 6/0 nylon stitches. Postoperative care consisted of the application of an ophthalmic antibiotic, steroidal ointment, and moisturizing tears. All patients were discharged from the hospital on the same day of the operation. Sutures were removed on the seventh postoperative day.

### Surgical Tips to Prevent Lower Lateral Canthal Displacement

A longstanding and satisfying experience with this technique let our group develop peculiar shrewdness crucial in the prevention of round eye. Particularly, our expertise focuses on the following strategical aspects:

1. The correction of horizontal skin laxity through fixation of the lateral portion of the orbicularis oculi. Two possible surgical approaches, with or without the use of muscle flaps, can be used:
  - Reidy-Adamson technique: a triangular flap is harvested in the upper lateral portion of the lower orbicularis-oculi muscle. This is passed beneath a superolateral canthal tunnel and then fixed at the periosteum of the upper lateral orbital rim (above the Whitnall tubercle) to obtain optimal lower eyelid contour.
  - Our alternative technique, which does not imply the use of a muscle flap: during the skin excision, the orbicularis-oculi muscle is removed in a complementary fashion. Skin stitches are positioned to grasp skin-muscle-skin in an oblique fashion. This lateral vector puts into tension the muscle, compensating the horizontal skin laxity. As this approach has appeared to be very effective in a relatively short

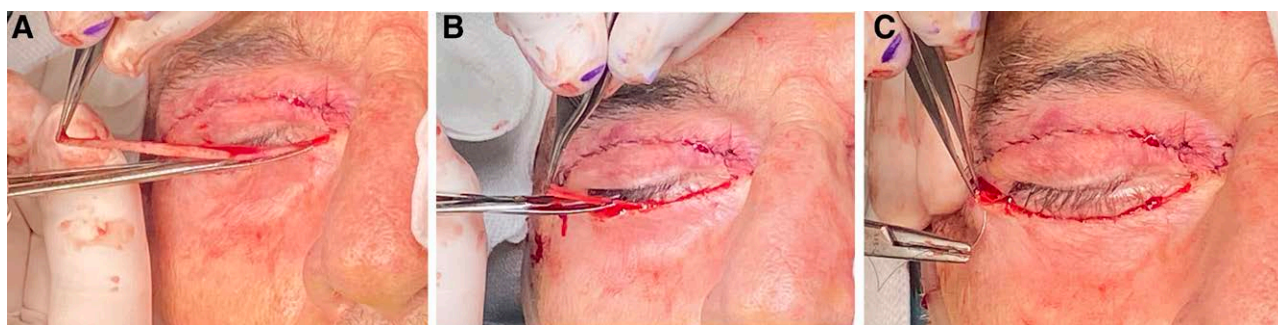operative time, it has been used as our routine technique for more than 20 years now.

2. Spraying of tarsal ligaments, through a transcutaneous lower lid incision made 1 mm below the eyelashes line, directed to the prevention of dystopia following the tarsal ligament healing process and subsequent ectropion. In fact, misposition of tarsal ligament may lead to palpebral and bulbar conjunctiva detachment, altering the lateral final aesthetic profile of the patient.
3. Preserve the orbicularis innervation from the facial nerve by limiting inferolateral skin dissection within the orbital rim.<sup>11</sup>
4. Control of thermal spread by using cold blade dissection and diathermocoagulation in bipolar mode. We always avoid the use of cautery in monopolar mode, by preferring cold blade dissection that has been shown to be less traumatic and by avoiding histologic alteration of tissues, thus leading to less risk of conjunctival thermal injury. In case of punctate bleeding, coagulation is obtained by using bipolar forceps, which is more effective in limiting excessive thermal spread and reducing the risk of unintended injury and edema of collateral tissues, thus favoring and speeding up the healing process.

Complication rate was assessed during follow-up, made at 1 week, 2 months, and 10 months postoperatively. Specifically, patients were screened for lower eyelid malposition (including round eye, ectropion, and entropion), epiphora, dry eye, red eye, "foreign body sensation," blurred vision, photophobia, and eye discomfort. Furthermore, the presence of infections, peribulbar hematoma/seroma, suture abscesses/cysts/granulomas, bad scarring and webbing, injury of inferior-oblique muscle or bulb, and relapse of the orbital fat were evaluated (Fig. 1A–C).

## RESULTS

A total of 280 patients (bilateral eyelids) underwent successful lower blepharoplasty. There were 228 women (81.4%) and 52 men (18.6%), with mean age of 53.5 years (range, 31–69 years). Seventy-three patients had a history



**Fig. 1.** Intraoperative photographs showing the technique for inferior eyelid blepharoplasty. A, Through a 2-cm-long myocutaneous incision made 1 mm below eyelashes to spare tarsal ligaments and extended laterally in Borges's lines and an incised septum with central fat pad identification, a complementary fashioned skin flap dissection was performed. B, A complementary fashioned preseptal orbicularis-muscle flap dissection limited within the lateral orbital rim to preserve orbicularis innervation was performed. C, Skin stitches are positioned in order to grasp skin-muscle-skin in an oblique fashion. This oblique vector puts the muscle into tension, compensating the horizontal skin laxity.



**Table 2. Mean Preoperative Values**

Time of Observation	Scleral Show (mm)	Snap-back Test 0–IV, n (%)					Distraction Test (mm)	Orbital Fat Herniation, n (%)
		Grade 0	Grade I	Grade II	Grade III	Grade IV		
Preoperative	0.9 (0.7–2.8)	—	58 (20.71)	151 (53.92)	61 (21.78)	10 (3.57)	7.26	68 (24.28)

of tobacco use (26.07%). Minimum follow-up time was 10 months (mean, 14.3 months). We had no patients lost to follow-up.

Preoperatively, mean scleral show was 0.9mm (range, 0.7–2mm), associated with a certain grade of asymmetry for each patient. Snap-back test was assessed preoperatively: 10 (3.57%), 61 (21.78%), 151 (53.92%), and 58 (20.71%) individuals showed grades IV, III, II, and I, respectively. No patients obtained grade 0 at preoperative evaluation. Preoperative distraction test had a mean value of 7.26mm (Table 2); 24.28% of the population had orbital fat herniation.

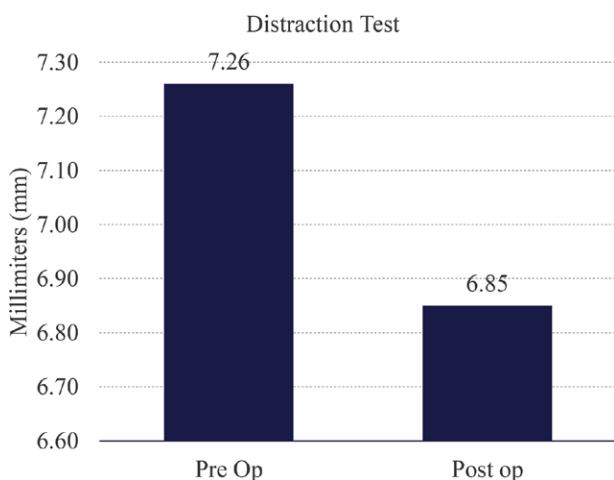
Postoperative complications arose in four of 280 patients considered in this study; only three male patients developed lower eyelid malposition (ectropion, subsequently reoperated) and one female patient developed soft tissue infection.

Cosmetic outcome in terms of symmetry, appearance, and lower lid line definition revealed high contentment with the result over time. Of the patients, 99.28% were evaluated as grade 0 at snap-back test and did not present scleral show at follow-up visit. Postoperative distraction test was measured, and the mean value was 6.85mm without significant gender differences at follow-up visit, consistently with the literature<sup>12</sup> (Fig. 2).

We achieved a mean patient VAS score of 8.4 after 10 months from the procedure. Postoperative surgeon photograph mean evaluation score was 4.5. Epiphora was assessed in 27.15% of the population using corneal fluorescein staining at follow-up visit (Figs. 3–5).

**DISCUSSION**

In recent years, blepharoplasty has become one of the most performed facial plastic surgery interventions, with



**Fig. 2.** Distraction test mean pre- and postoperative values.

the ability to rejuvenate the patient’s appearance in a natural fashion. The primary aesthetic concerns are associated with herniated orbital fat pads and lower eyelid rhytides. Herniation of orbital fat pads through the orbicularis-oculi muscle is typically consequent to the physiological lower lid weakening, and only in rare cases, it can be related to a real augmentation in orbital fat volume. Nevertheless, particular attention must be paid to lower eyelid horizontal laxity.

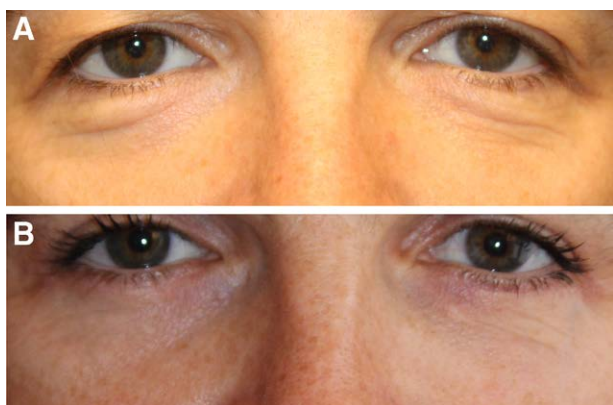Numerous blepharoplasty surgical techniques have been proposed throughout time. Compared to the well-known satisfactory outcomes of superior blepharoplasty, lower blepharoplasty has always been at the center of debate, in terms of both aesthetic outcomes and persistence of results. Lower eyelid malposition, with severity ranging from increased scleral show to ectropion, is the most common complication following a lower eyelid blepharoplasty.<sup>3</sup>

Thus, “round eye” is characterized by the presence of scleral show, an anatomical condition in which the sclera area is visible.<sup>4</sup> As a matter of fact, the inferior part of the cornea, at the level of the corneoscleral junction, is anatomically tangential to the border of the lower eyelid; consequently, this area of sclera should not be visible. Scleral show should not be confused with ectropion, another common form of eyelid malposition characterized by eversion of the tarsal plate of lower eyelid. Understandably, when ectropion occurs, an exaggerated show of the sclera in the lower third eye globe is present, and it is usually greater than 3mm.<sup>5</sup>

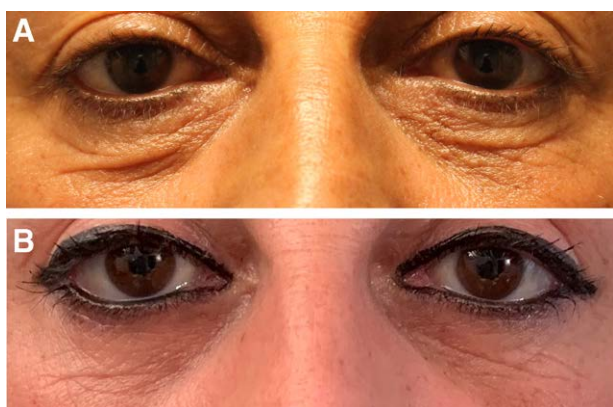
Round eye and ectropion present varied etiologies, which mainly include complications following lower eyelid blepharoplasty. Among all, anterior lamellar shortening, orbicularis-oculis-muscle damage, excessive skin, fat or muscle removal from the lower eyelid, and scar contracture should be mentioned, giving inferior traction of the eyelid and rounding of the lateral canthus, leading to excessive scleral show.<sup>5,6</sup> In addition, these conditions may be aggravated by the lower eyelid structures’ laxity propension, driven by gravitational forces. Indeed, the skin excess must be carefully quantified and resected following a vertical fashion, without shortening the anterior lamella. Also, adipose tissue can be removed or redraped depending on the patient’s presentation, and the muscle must be readjusted, strengthening the anterior lamellae and giving a horizontal tension on the upward skin.

The round eye affects both aesthetic outcome and visual function, as it is associated with several clinical manifestations, including epiphora and dry eye.<sup>7</sup>

Epiphora is defined as excessive tearing. Indeed, this is due to lacrimal punctum malposition with respect to the lower eyelid fornix. Therefore, lagophthalmos should be assessed by corneal fluorescein staining at slit-lamp examination.

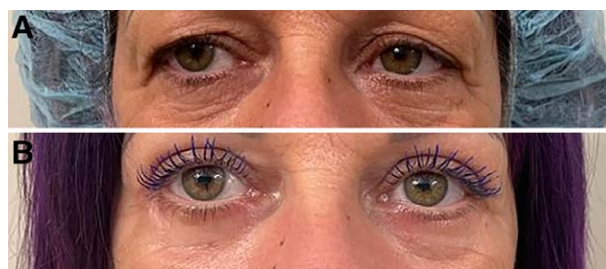

**Fig. 3.** Pre- and postoperative photographic evidence. A, A 40-year-old woman presented with no scleral show, a grade 0 snap-back test, a right eyelid distraction test of 6.9 mm, a left eyelid distraction test of 6.9 mm, a right eyelid skin excess of 3.3 mm, and a left eyelid skin excess of 3.1 mm. The left lateral canthus appeared slightly downslated with respect to the contralateral one. Orbital fat pads were herniated in both sides, more pronounced on the right. The patient underwent lower eyelid blepharoplasty through our technique. B, Six months postoperatively.



**Fig. 4.** Pre- and postoperative photographic evidence. A, A 47-year-old woman presented with no scleral show, a grade 1 snap-back test, a right eyelid distraction test of 7.0 mm, a left eyelid distraction test of 6.9 mm, a right eyelid skin excess of 2.9 mm, and a left eyelid skin excess of 2.7 mm. The left medial and lateral canthi appeared slightly downslated with respect to the right ones. Left orbital fat pads were assessed in the left side. The patient underwent upper and lower eyelid blepharoplasty at our center. The aforementioned technique was used for the correction of the inferior eyelids. B, Four months postoperatively.

On the other hand, despite the presence of excessive tearing, dry eye is one of the most disabling conditions: tears cannot be adequately drained, flowing outside the visual organ, causing dryness. It is an important source of symptoms, as it is associated with red eye, “foreign body sensation,” blurred vision, mild to severe photophobia, and eye discomfort or pain, as well as the increased risk of corneal abrasion. Dry eye is the result of lid margin alteration, associated with an abnormal congruity with the eye bulb. This affects the function and shape of tear menisci, adversely affecting the tear film distribution and



**Fig. 5.** Pre- and postoperative photographic evidence. A, Preoperative assessment of a 54-year-old woman who presented with no scleral show, a grade 2 snap-back test, a right eyelid distraction test of 7.1 mm, a left eyelid distraction test of 7.0 mm, a right eyelid skin excess of 8.6 mm, and a left eyelid skin excess of 7.5 mm. No asymmetry was assessed in the canthal position. Right orbital fat pads were more pronounced than left ones. Lower eyelid blepharoplasty was performed. B, Twelve-month postoperative results.

lipid layer spreading, thus influencing qualitative composition of tears, increasing the risk for inflammation and infections.<sup>13</sup>

Moreover, muscular pressure over the meibomian glands, which is necessary for them to work, is impaired by eyelid laxity. Inefficient blinking also proceeds in the accumulation of toxin, pathogens, and foreign bodies.<sup>14</sup>

In conclusion, epiphora and dry eye predispose to eye rubbing, which can further worsen lower eyelid laxity.<sup>5</sup>

Several surgical approaches were adopted for round-eye prevention during the last decades, and their evolution has been driven by the nature of the postoperative complications, given the high rate of unsatisfactory postoperative results.<sup>5,7,8</sup> Yet, there is an ongoing controversy regarding the optimal approach to consider.<sup>15</sup> Most of the time, a separate management of the skin and muscle is the best option to address the weakness of the anterior lamellae, resulting in more stable results in patients with a considerably lower eyelid skin excess with inferior rim hollowing (where a conventional transconjunctival approach would fail in achieving the best aesthetic outcome).

One of the most popular surgical techniques to reinforce the anterior lamellae is the use of an orbicularis oculi muscle suspension flap, also known as the Reidy-Adamson flap.<sup>16,17</sup> This technique is based on the anchorage of a lateral orbicularis muscle triangular flap to the periosteum of the lateral border of the upper orbital rim, enough to produce good tension on the lower lid, increase lower definition, and prevent postoperative eyelid mispositioning. In an attempt to improve the surgical purposes, many variations were proposed, such as extensive skin resection to intentionally produce a mild ectropion, as well as temporary suspension sutures<sup>12</sup> and lower lateral dermal flap harvesting,<sup>18</sup> as was performed by Milbratz-Moré et al and Kam et al, respectively. Also, improvements on the correction of both vertical and horizontal lower eyelid skin laxity were described by Reidy<sup>16</sup> and Adamson.<sup>17</sup> Since then, a few refinements have been described, such as the one from Rosenberg et al,<sup>19</sup> who combined a transconjunctival and transcutaneous approach (“inside-out” technique). These techniques are extremely useful in patients with

both vertical and horizontal lower eyelid skin excess with inferior rim hollowing. Indeed, traditional transcutaneous/transconjunctival blepharoplasty alone or lateral canthal tightening procedures are not able to tackle these defects completely. The Reidy-Adamson flap resuspends the orbicularis muscle, corrects the age-related skin laxity, and helps reinforce the orbital septum, the thinning of which is responsible for the formation of saddle bags.

Our group has used the Reidy-Adamson flap technique for many years with good results, and our expertise in oculoplastic surgery has improved over time, giving us the chance to apport some procedural modifications until the development of a surgical maneuver based on a specific suture aimed at obtaining the same effect of the orbicularis muscle flap, without the risks related to its harvesting.

Indeed, our series of 280 inferior lid blepharoplasties proved to be functionally effective, surgically logical, and easy to reproduce. We propose a limited dissection of the skin from the underlying orbicularis muscle. Consequently, the lateral vector created by the skin can put the muscle into tension, thus compensating for the horizontal skin laxity and decreasing the risk of significant postoperative complications, including misalignment of the lower tendons. The reinforcement of the anterior lamellae is based on the anchorage of a lateral orbicularis-muscle triangular flap to the periosteum of the lateral border of the upper orbital rim, enough to produce a good tension on the lower lid and increase lower definition preventing postoperative canthal mispositioning. Moreover, as aging may contribute to herniation of fat compartments anteriorly to the orbital rim, surgical debulking should be required in patients with significant prolapse. The locations of these anatomical structures are key for the positioning of the lower eyelid; therefore, inattentive removal of the herniated fat pads has a higher risk of horizontal eyelid incompetence. Notice should be taken while addressing the horizontal plane, curtailing lower eyelid dystopia.

As a matter of fact, postoperative scleral show was inconspicuous in 98.92% of the population ( $n = 277$ ). Also, skin laxity was improved, as shown by a mean distraction test of 6.85 mm (versus 7.26 mm preoperatively) and grade 0 snap-back test in 99.28% of the population ( $n = 278$ ). Moreover, surgical removal of orbital fat pad herniation was performed in 68 patients with successful results. In the remaining 212, this procedure was not necessary, and hence, was not performed.

Indeed, over the past decade, the described technical approach has been successfully used with excellent functional and aesthetic outcomes on all our patients. Complications were limited to a minority of the population, without any of significant extent, in particular, no entropion, lower eyelid retraction, bad scarring, injury to the inferior oblique muscle or bulb, or fat-pad dislocation. To date, minor complications were ectropion, which was assessed in three patients (one of whom had sclerodermia), and infection, which was assessed in one patient. Moreover, a great advantage of our technique is the minimal ecchymosis and minimal edema, starting from day 3 postoperatively. This study reports data on a sequentially

randomized cohort, with an adequate follow-up period of 10 months, and with no patients lost during follow-up. Reliable estimation of the outcomes was achieved by comparison between pre- and postoperative measures. Also, pre- and postoperative standard photographs were collected in all patients to guarantee an objective evaluation in terms of both functional and aesthetic outcomes. Fluorescein staining was used to assess the presence of lagophthalmos during follow-up visits. Its presence in 27.15% ( $n = 76$ ) of the population could be related to the high prevalence of this condition, not attributable to round eye.

Nevertheless, this study is characterized by some limitations. Indeed, its retrospective and descriptive nature, as well as the confinement to our single institution, does not allow us to draw definitive conclusions. Still, the multidisciplinary approach that blends plastic and oculoplastic skills guaranteed a longstanding and gratifying experience, allowing our group to develop sustaining sagacity, crucial in the prevention of round eye.

## CONCLUSIONS

Lower lid blepharoplasty through a minimally invasive lower eyelid crease incision can effectively address lower eyelid laxity and/or canthal dystopia, resulting in an aesthetic correction of the lateral canthus. Thus, we share our experience in the prevention of round eye and ectropion through the application of the aforementioned surgical shrewdnesses. Furthermore, we achieved excellent stability of results with low complication rate and high patient and surgeon satisfaction.

Valeriano Vinci, MD  
 Department of Biomedical Sciences  
 Humanitas University  
 Via Rita Levi Montalcini 4, Pieve Emanuele  
 20090 Milan, Italy;  
 and  
 Humanitas Clinical and Research Center-IRCCS  
 Via Manzoni 56, Rozzano  
 20089, Milan, Italy  
 E-mail: [valeriano.vinci@humanitas.it](mailto:valeriano.vinci@humanitas.it)

## DISCLOSURE

*The authors have no financial interest to declare in relation to the content of this article.*

## PATIENT CONSENT

*Patients provided written consent for the use of their images.*

## ACKNOWLEDGMENTS

*The principles outlined in the Declaration of Helsinki were followed in this study. This article does not contain any studies involving human participants or animals. We have taken every precaution to ensure that the study is conducted in an ethical and responsible manner, and we are committed to upholding the highest standards of scientific integrity and ethical conduct. No relationships/activities/interests are applicable to this article.*

## REFERENCES

1. Carriquiry CE, Seoane OJ, Londinsky M. Orbicularis transposition flap for muscle suspension in lower blepharoplasty. *Ann Plast Surg.* 2006;57:138–141.
2. Furnas DW. Festoons of orbicularis muscle as a cause of baggy eyelids. *Plast Reconstr Surg.* 1978;61:540–546.
3. Edgerton MT, Wolford FG. The dermal-flap canthal lift for lower eyelid support. A technique of value in the surgical treatment of facial palsy. *Plast Reconstr Surg.* 1969;43:42–51.
4. Loeb R. Scleral-show. *Aesthetic Plast Surg.* 1988;12:165–170.
5. Guthrie AJ, Kadakia P, Rosenberg J. Eyelid malposition repair: a review of the literature and current techniques. *Semin Plast Surg.* 2019;33:92–102.
6. Pacella SJ, Codner MA. Minor complications after blepharoplasty: dry eyes, chemosis, granulomas, ptosis, and scleral-show. *Plast Reconstr Surg.* 2010;125:709–718.
7. Carraway JH, Mellow CG. The prevention and treatment of lower lid ectropion following blepharoplasty. *Plast Reconstr Surg.* 1990;85:971–981.
8. Zoumalan CI, Roostaeian J. Simplifying blepharoplasty. *Plast Reconstr Surg.* 2016;137:196e–213e.
9. Labib AM, Patel BC, Milroy C. Lower eyelid laxity examination. May 25, 2022. *StatPearls [Internet]*. Treasure Island, Fla.: StatPearls Publishing; 2022.
10. Voutilainen A, Pitkääho T, Kvist T, et al. How to ask about patient satisfaction? The visual analogue scale is less vulnerable to confounding factors and ceiling effect than a symmetric Likert scale. *J Adv Nurs.* 2016;72:946–957.
11. Innocenti A, Mori F, Melita D, et al. Effects of orbicularis oculi flap anchorage to the periosteum of the upper orbital rim on the lower eyelid position after transcutaneous blepharoplasty: statistical analysis of clinical outcomes. *J Plast Reconstr Aesthet Surg.* 2017;70:385–391.
12. Milbratz-Moré GH, Pauli MP, Lohn CLB, et al. Lower eyelid distraction test: new insights on the reference value. *Ophthalmic Plast Reconstr Surg.* 2019;35:574–577.
13. Aragona P, Giannaccare G, Mencucci R, et al. Modern approach to the treatment of dry eye, a complex multifactorial disease: a P.I.C.A.S.S.O. board review. *Br J Ophthalmol.* 2021;105:446–453.
14. Zhang X, M VJ, Qu Y, et al. Dry eye management: targeting the ocular surface microenvironment. *Int J Mol.* 2017;18:1398.
15. Prischmann J, Sufyan A, Ting JY, et al. Dry eye symptoms and chemosis following blepharoplasty: a 10-year retrospective review of 892 cases in a single-surgeon series. *JAMA Facial Plast Surg.* 2013;15:39–46.
16. Reidy JP. Swellings of eyelids. *Br J Plast Surg.* 1960;13:256–267.
17. Adamson JE, McCraw JB, Carraway JH. Use of a muscle flap in lower blepharoplasty. *Plast Reconstr Surg.* 1979;63:359–363.
18. Kam KY, Cole CJ, Bunce C, et al. The lateral tarsal strip in ectropion surgery: is it effective when performed in isolation? *Eye (Lond).* 2012;26:827–832.
19. Rosenberg DB, Lattman J, Shah AR. Prevention of lower eyelid malposition after blepharoplasty: anatomic and technical considerations of the inside-out blepharoplasty. *Arch Facial Plast Surg.* 2007;9:434–438.