

Dermatoscopy of folliculosebaceous cystic hamartoma

Emiko Watanabe-Okada¹, Yuichi Kurihara¹, Shunichi Miyakawa¹, Masaru Tanaka²

¹ Division of Dermatology, Kawasaki Municipal Hospital, Kawasaki, Japan

² Department of Dermatology, Tokyo Women's Medical University Medical Center East, Tokyo, Japan

Keywords: folliculosebaceous cystic hamartoma, sebaceous trichofolliculoma, yellowish-white network, yellowish-orange dots/globules, dermatoscopy

Citation: Watanabe-Okada E, Kurihara Y, Miyakawa S, Tanaka M. Dermatoscopy of folliculosebaceous cystic hamartoma. *Dermatol Pract Concept*. 2014;4(3):8. <http://dx.doi.org/10.5826/dpc.0403a08>

Received: February 4, 2014; **Accepted:** March 18, 2014; **Published:** July 31, 2014

Copyright: ©2014 Watanabe-Okada et al. This is an open-access article distributed under the terms of the Creative Commons Attribution License, which permits unrestricted use, distribution, and reproduction in any medium, provided the original author and source are credited.

Funding: None.

Competing interests: The authors have no conflicts of interest to disclose.

All authors have contributed significantly to this publication.

Corresponding author: Emiko Watanabe-Okada, M.D. Tel. +81-44-233-5521; Fax. +81-44-245-9600. Email: emicat720@yahoo.co.jp

ABSTRACT A 29-year-old Japanese man presented to our institution with a nodule on his nose that had increased in size since childhood. Physical examination indicated the presence of an elastic, firm, pedunculated red nodule measuring 15 mm in size. Dermatoscopic examination of the nodule indicated a yellowish-white network, yellowish-orange dots/globules at its center, and a pinkish-white structureless peripheral area. Histopathological examination of an excisional biopsy specimen showed a dilated infundibulocystic structure with sebaceous lobules proliferating radially, surrounded by fibrous stroma. Moreover, mature adipocytes and small vessels were noted in the stroma. Based on these histopathologic findings, the patient was diagnosed with folliculosebaceous cystic hamartoma.

Case presentation

A 29-year-old Japanese man presented with a reddish nodule, of approximately 15 mm in diameter, on the nose (Figure 1). The lesion had gradually grown in size since childhood. The patient had no associated symptoms or family history. Dermatoscopic examination of the nodule revealed a yellowish-white network, yellowish-orange globules at its center, and a pinkish structureless peripheral area (Figure 2A). We initially suspected that the lesion was an adnexal tumor or a sebaceous neoplasm. The tumor was excised completely.

On histopathological examination, we observed an exophytic lesion composed of dilated, follicular infundibular

structures connected with multiple sebaceous lobules and surrounded by fibrous connective tissue with thick collagen bundles (Figure 3A). Cleft formation between fibroepithelial units and intervening stroma was evident (Figure 3C). Moreover, the surrounding stroma was fibrotic, with a high number of small vessels (Figure 3C). No hair shafts were present in the cystic cavity. These findings were consistent with a diagnosis of folliculosebaceous cystic hamartoma (FSCH).

Discussion

FSCH, first described by Kimura et al. in 1991, is characterized by a relatively rare cutaneous hamartoma composed

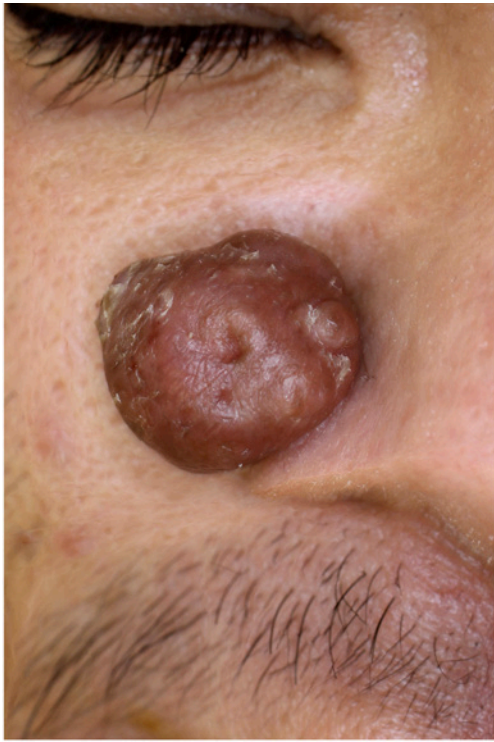

Figure 1. Clinical photograph showing a pedunculated reddish nodule on the nose. [Copyright: ©2014 Watanabe-Okada et al.]

of follicular, sebaceous, and mesenchymal components [1]. FSCH clinically manifests as a solitary skin-colored sessile or pedunculated nodule that is most commonly located on the central part of face, particularly on the nose or the paranasal area. The lesion is usually < 3 cm in size [2].

FSCH shares several similar histopathological features with sebaceous trichofolliculoma (STF) and may be considered a variant of STF with a marked sebaceous component

[3]. However, certain histopathologic features of FSCH are believed to be distinct, and thus, this condition can be differentiated from STF. Ansai et al. described that the prominent mesenchymal component and double cleft formation between fibroepithelial units and the altered stroma are distinguishing features of FSCH. In contrast, STF has rudimentary hair follicles and hair shafts connecting to the infundibular cyst wall, and lacks the distinctive mesenchymal component observed in FSCH [2].

On dermatoscopy, we detected a yellowish-white network and yellowish-orange dots/globules at its center, with a pinkish structureless peripheral area (Figure 2A). The whitish-yellow network observed on histopathological examination represented the elongation of the rete ridges in addition to dermal sebaceous components (Figures 2B and 3B). Moreover, whitish-yellow clods were identified at the center of the nodule, indicating the presence of exophytic lesions consisting of sebaceous lobules connected to the dilated infundibular cystic structures via sebaceous ducts (Figure 2B). Furthermore, at the center of the nodule, the yellowish-orange globules represented conglomerations of sebaceous glands located in the superficial dermis (Figure 2C). The color of the pinkish structureless peripheral area appeared similar to that of dermal dilated blood vessels. Based on the clinical findings, the differential diagnoses would include melanocytic nevus, poroma, and sebaceoma. However, additional features observed via dermatoscopy could help exclude these disorders, including the lack of residual pigmentation around the hair follicles suggesting melanocytic nevus, the absence of glomerular or hairpin vessels and a whitish-pink network suggesting poroma, and the presence of a yellowish structureless area and arborizing vessels suggesting sebaceoma.

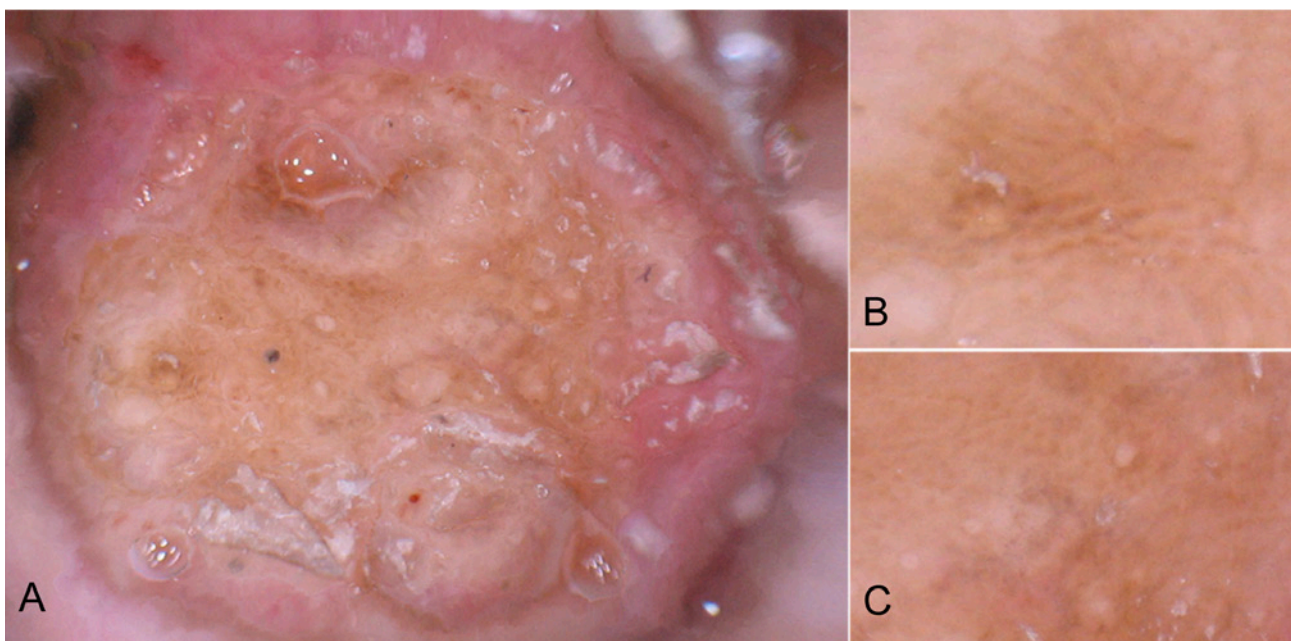


Figure 2. (A) A pinkish-white structureless peripheral area. (B) Dermatoscopy of the nodule shows white structureless areas, a yellowish-white network and (C) yellowish-orange dots/globules at its center. [Copyright: ©2014 Watanabe-Okada et al.]

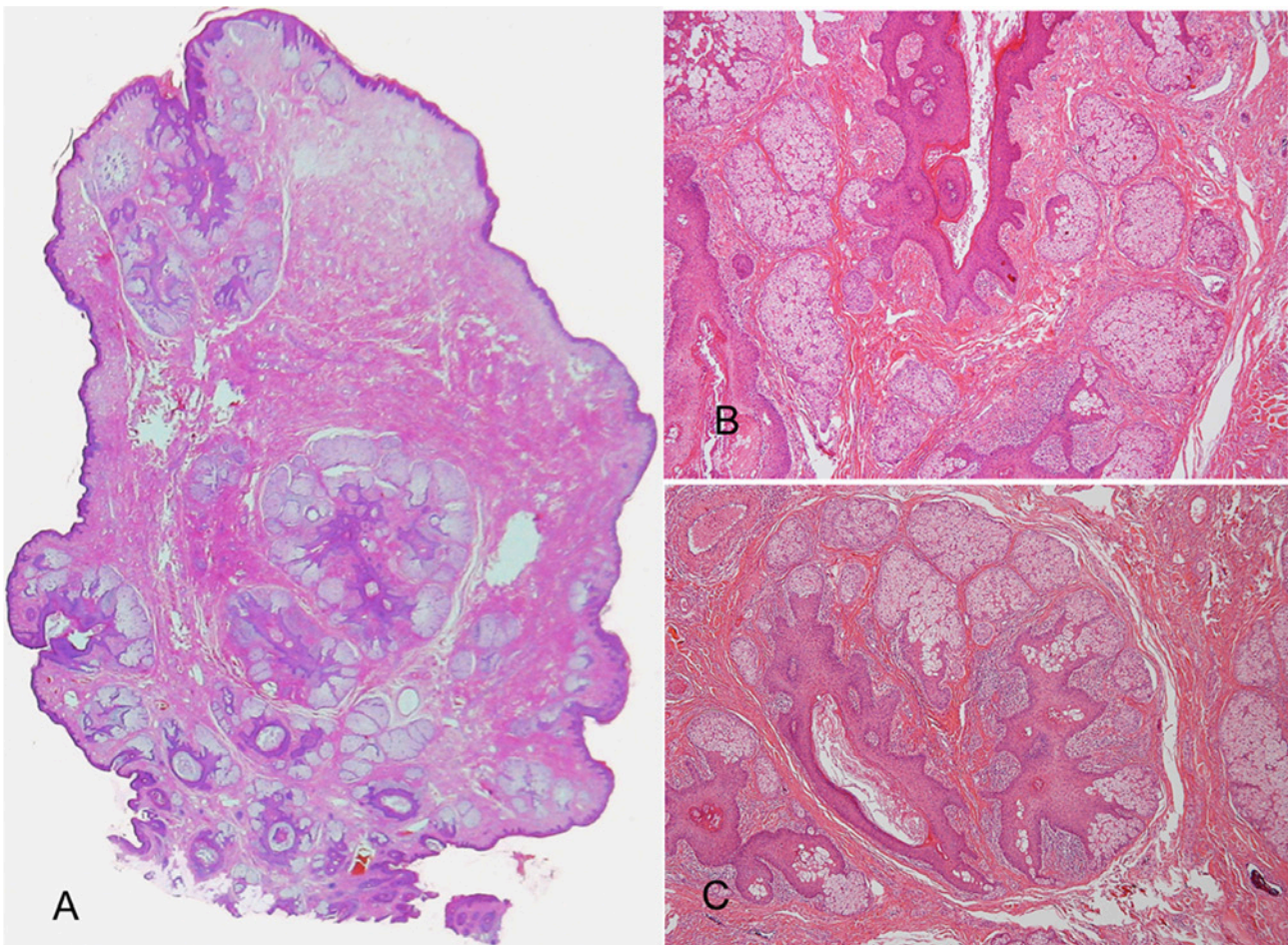


Figure 3. (A) Histopathologic examination reveals an exophytic lesion consisting of a dilated infundibular cystic structure with sebaceous lobules connected via sebaceous ducts. (H&E x5). (B) Numerous mature sebaceous lobules along with the elongation of the rete ridges in the epidermis are seen. (H&E x20). (C) A cleft is noted between the fibroepithelial units and the surrounding stroma; the stroma is prominent, with fibrillar bundles of collagen and a high number of small blood vessels. (H&E x40). [Copyright: ©2014 Watanabe-Okada et al.]

To our knowledge, only one case presenting with the dermatoscopic features of FSCH has been reported in Japan [4]. In that report, the dermatoscopic features of FSCH included a yellowish-orange area and whitish-yellow globules. Although FSCH can only be diagnosed based on the microscopic features, certain characteristic dermatoscopic features observed in the present case may also be useful to distinguish among several differential diagnoses. Moreover, we believe that the awareness of this entity and the use of dermatoscopy can facilitate the diagnosis of FSCH.

In conclusion, we described the dermatoscopic features of FSCH, such as a whitish-yellow network, yellowish-orange dots/globules, and whitish-yellow clods. However, additional

dermatoscopic findings are needed to elucidate whether the features described here are characteristic findings in FSCH.

References

1. Kimura T, Miyazawa H, Aoyagi T, et al. Folliculosebaceous cystic hamartoma: A distinctive malformation of the skin. *Am J Dermatopathol.* 1991;13:213-20.
2. Ansai S, Kimura T, Kawana S. A clinicopathologic study of folliculosebaceous cystic hamartoma. *Am J Dermatopathol* 2010;32:815-20.
3. Plewig G. Sebaceous trichofolliculoma. *J Cutan Pathol.* 1980;7: 394-403.
4. Oishi K, Ohara K. A yellow-red colored nodule on an infant's cheek. *J Jpn Dermatohistopathol Soc.* 2009;25:9-12 (in Japanese).