



Case Report

Intraperitoneal Loss of Pelvic Array Pin During Navigated Total Hip Arthroplasty

Heng Kan, MBBS, MTrauma^{*}, Iulian Nusem, MD, FRACS (ORTHO)

Department of Orthopaedics, Logan Hospital, Brisbane, Queensland, Australia

ARTICLE INFO

Article history:

Received 28 August 2022

Received in revised form

6 November 2022

Accepted 8 November 2022

Available online xxx

Keywords:

Arthroplasty

Navigation

THA

Total hip arthroplasty

Robotic surgery

Complications

THR

ABSTRACT

Pelvic array pin placement during navigated total hip arthroplasty has been known to cause complications; however, most of them are minor. We report a 78-year-old female who underwent a routine computer-navigated total hip replacement which was subsequently complicated by complete loss of the pelvic array pin requiring retrieval via laparotomy. No structures were injured despite the surrounding urological, vascular, and visceral anatomy. The patient recovered and subsequently underwent a total hip arthroplasty without complication 6 weeks later. This case illustrates the dangers of inserting a pelvic array pin within patients with poor bone quality and highlights necessary considerations of pin design and surgical techniques to minimize this complication.

© Crown Copyright © 2022 Published by Elsevier Inc. on behalf of The American Association of Hip and Knee Surgeons. This is an open access article under the CC BY-NC-ND license (<http://creativecommons.org/licenses/by-nc-nd/4.0/>).

Introduction

Computer navigation in total hip arthroplasty aims to improve the reliability of implant positioning by reducing the presence of positional outliers [1]. Emerging literature has shown its clinical application in reducing rates of dislocation [2] and revision rates secondary to dislocation [3]. An essential aspect of the procedure is to insert intraosseous iliac array pins to establish a stable reference of patient position for the navigation software. While already rare, there are complications surrounding pin placement during navigated total hip replacement such as additional wound site infection, persistent local tenderness, periprosthetic fracture, and retained bony debris appearing in postoperative films, which are readily reported in the literature [4-7].

While intraoperative pin migration has been documented as a complication, a complete loss of the iliac array pin within the peritoneum has not been reported in literature. This unique case highlights the need to discuss this potential complication with patients during the counseling process. We also emphasize the importance of examining the design of array pins and surgical

technique when inserting it in patients with poor bone quality to avoid this complication.

Case history

A 78-year-old female underwent a routine computer-navigated total hip arthroplasty for the indication of severe osteoarthritis. The Intellijoint HIP (Intellijoint Surgical, Kitchener, ON, Canada) posterior approach platform was used with the standard workflow whereby iliac array pins were inserted percutaneously through a stab incision prior to primary incision.

The 6.5-mm self-tapping navigation pin was inserted as per surgical technique recommended by the manufacturer. Surgical landmarks were referenced at the apex of the iliac wing between the anterior superior iliac spine and posterior inferior iliac spine. The pins are then inserted 1 cm distal to that point to ensure sufficient circumferential bone stock. This allows maximal purchase and prevents the pin from skiving along the pelvic brim.

The typical insertion technique of the senior surgeon is to initially mallet the pin to engage the outer table of the iliac wing. Subsequently, a handheld screwdriver is then attached to advance to engage the inner table of the ilium. In this case, however, upon attachment of the handheld screwdriver to advance the pin, a sudden loss of purchase was encountered whereby the shaft of the

^{*} Corresponding author. Department of Orthopaedics, Logan Hospital, Loganlea Rd, Meadowbrook, Queensland 4131, Australia. Tel.: +61 07 3299 8899.

E-mail address: Henry.heng.kan@gmail.com

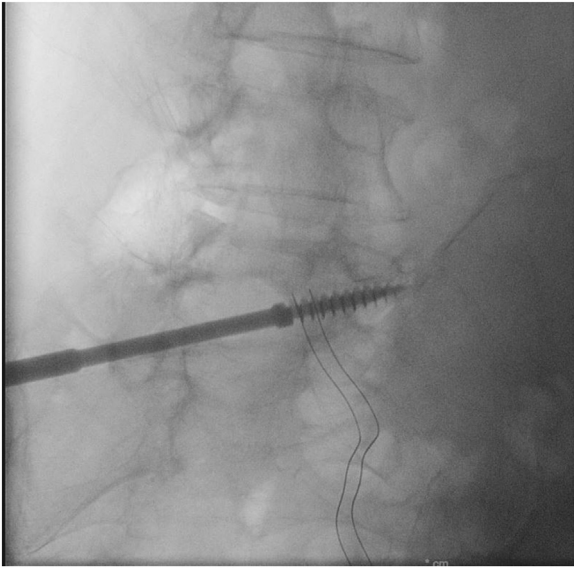


Figure 1. Intraoperative fluoroscopy confirming position of pin within pelvis.

screwdriver, including the pin attached, plunged into the pelvis leading to the loss of the pin.

On-table retrieval was attempted by taking down the external oblique attachment to the iliac crest to gain access to the medial side, but the pin was unable to be located. An intraoperative x-ray was performed to demonstrate an intrapelvic position (Fig. 1).

The primary total hip arthroplasty was abandoned. As the surgery was performed in a peripheral metropolitan center, initially an on-table general surgical opinion was obtained. Given the position of the pin to the iliac vessels, a vascular opinion was also acquired from the nearby tertiary center. On-table clinical examination revealed a hemodynamically stable patient with strong bounding pedal pulses bilaterally. A computed tomography angiogram was performed displaying the pin's proximity to the right common iliac artery (Fig. 2). Examining the bony details, there was no evidence of fracture, incorrect entry point, or skiving of the pin. Instead, the image revealed a circular hole just bigger than the diameter of the pin (Fig. 3). The patient was kept anesthetized to mitigate any further harm from patient movement while the screw remained within the pelvis, and she was immediately transferred to the tertiary center 20 minutes away.

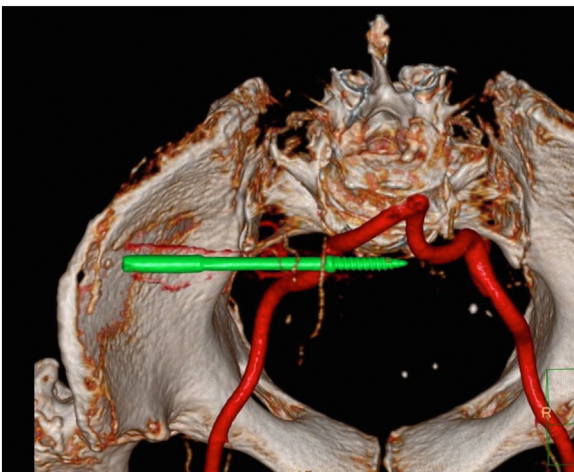


Figure 2. 3D reconstruction CT sequence of pelvis within pelvic cavity.

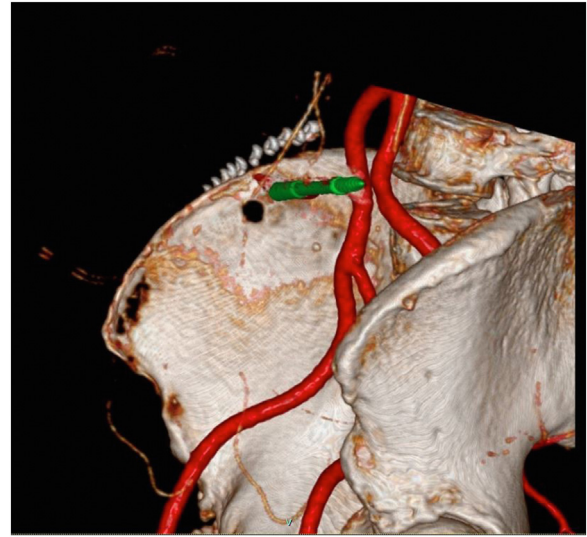


Figure 3. 3D reconstruction demonstrating no fractures but rather a perfectly circular hole demonstrating bone yielding around the thread of the pin.

The patient was taken directly to theater, and a limited midline laparotomy was performed to retrieve the screw by a combined vascular and general surgical team. The exploratory laparotomy found that the distal one-fifth of the pin was intraperitoneal while the remaining portion was intrapelvic. The tip of the pin perforated the posterior peritoneum in close proximity to the right common iliac artery, right ureter, and small bowel. However, fortunately, no structures were injured.

The patient recovered well from laparotomy and was transferred back to the original unit the following day and was successfully discharged 1 week later. She subsequently received her total hip arthroplasty as intended 2 months following this event without complications, using only primary instrumentation without the use of Intellijoint navigation. She has been subsequently followed up in clinic 3 and 12 months after her total hip replacement. The patient reports a complete recovery with no further complications from either the total hip arthroplasty or exploratory laparotomy. Written informed consent was obtained from the patient for the purpose of this case report.

Discussion

The insertion of a pelvic array is a key step in navigated total hip arthroplasty. Computer navigation has been persistently shown in literature to improve implant placement particularly in the acetabular component [1,8]. This is the first reported case in literature of intrapelvic pin loss requiring laparotomy retrieval. Despite the rarity, a complication of this magnitude must be understood by surgeons when inserting pelvic array pins given the potential for major vascular or visceral organ injuries.

It is likely that this complication occurred in this patient due to the poor quality of the bone, which meant that during the malleting process, while engaging the outer cortex, the inner cortex was unintentionally breached, leading to the surrounding bone to yield or blow out with subsequent loss of pin. This is supported radiographically whereby the computed tomography scan did not reveal any fracture lines. Instead, it shows the bone circumferentially surrounding the entry hole which perfectly matches the diameter of the threads of the screw.

Ultimately, this case of intrapelvic pin loss is an amalgamation of a failure at the pin-bone interface between the array pin and the

ilium. While no literature exists specifically addressing the pin-cortex interface in the context of pelvic array pins in navigated total hip arthroplasty, this issue has been explored in the context of external fixators which can be appropriately adapted to this case.

Factors that contribute directly to pin-bone interface biomechanics at the time of insertion have been described below.

- Age/bone quality [9]
- Number of pins [9]
- Depth of bone to pin engagement [10]

In addressing the issue of effects of age and bone quality on the pin-bone interface, Brockstedt et al. demonstrated reduction of iliac bone mass with increasing age, particularly in postmenopausal women [11]. Furthermore, Donaldson et al. demonstrated significantly increased volume of yielded bone at the pin-bone interface in the cohort of simulated aged bone samples with external fixation pins [9]. Considering this, our patient, a 78-year-old female, had diagnosed osteopenia with a T score of -1.6 and consequently has been at high risk of pin-bone interface failure.

While severe osteoporosis has been specifically listed as a contraindication by the original developers of Intellijoint [12], poor bone quality has been listed as a relative contraindication. As no specific qualitative guidelines exist to inform surgeons who are at risk, there is a need for further research in this area.

Donaldson et al. also demonstrated in their biomechanical model that an addition of a third pin to the bone reduces yielding bone volume by 65%-75% compared to the 2 pin models [9]. Currently the Intellijoint platform relies on the camera to be mounted on 2 pins only with no further capacity to add additional pins if needed.

Finally, Kim et al. demonstrated a directly positive correlation between distance of bone-pin engagement and torque strength of half pins in elderly cadaveric tibia samples [10]. The current workflow for the Intellijoint HIP system requires the insertion of its navigation pins in a perpendicular fashion as recommended by their surgical technique as the mounting platform for the viewing camera is nonarticulated and must be parallel to the floor [12]. While we recognize that the mounting array needs to be perpendicular to the floor as a reference point, this trajectory limits the amount of bone the pins can engage with as the average width of the iliac crest is 17 mm [13].

With the prevalence of osteoporosis and osteopenia rates in series of patients awaiting total hip arthroplasty at 18% and 41%, respectively [14], maximizing pin fixation efficiency to prevent migration is evidently critical for patient safety and implantation accuracy. With these issues in mind, we recommend 3 solutions to minimize these issues in future:

We advocate for the pin design to be a tapered, whereby the proximal portion of the array pin is larger than the diameter of the threads, as this would prevent complete loss in the event of loss of purchase from the bone. We also advocate an additional pin placement to further increase pin-to-bone fixation.

The pin trajectory should follow between the tables of the iliac wing instead of being perpendicular to the iliac crest, this would not only increase the depth of pin-to-bone engagement but also prevent the pin heading directly toward the iliac vessels if loss of bony purchase would occur. This design is consistent with other commercially available platforms such as the Stryker MAKO Robotic Hip platform (Stryker, Inc., Kalamazoo, MI) which uses an articulated adjustable mounting platform to facilitate pin trajectory along the iliac wing to allow the array and camera position to be adjusted to remain parallel with the horizontal axis.

A consideration in surgical technique particularly for those with poor bone quality is to insert the pin via a power driver connected via a collet instead of using the mallet. This would ensure a constant control over the advancement of the pin.

Summary

We describe a unique case of intraperitoneal loss of a pelvic array pin in the setting of routine navigated total hip arthroplasty. The surgical technique and pin design should be considered when inserting the Intellijoint HIP pelvic pins to prevent such devastating complications.

Conflicts of interest

The authors declare there are no conflicts of interest.

For full disclosure statements refer to <https://doi.org/10.1016/j.artd.2022.11.003>.

Informed patient consent

The authors confirm that informed consent has been obtained from the involved patient or, if appropriate, from the parent, guardian, power of attorney of the involved patient and that she has given approval for this information to be published in this article.

References

- [1] Xu K, Li YM, Zhang HF, Wang CG, Xu YQ, Li ZJ. Computer navigation in total hip arthroplasty: a meta-analysis of randomized controlled trials. *Int J Surg* 2014;12:528–33.
- [2] Bohl DD, Nolte MT, Ong K, Lau E, Calkins TE, Della Valle CJ. Computer-assisted navigation is associated with reductions in the rates of dislocation and acetabular component revision following primary total hip arthroplasty. *J Bone Joint Surg Am* 2019;101:250–6.
- [3] Agarwal S, Eckhard L, Walter WL, et al. The use of computer navigation in total hip arthroplasty is associated with a reduced rate of revision for dislocation: a study of 6,912 navigated THA procedures from the Australian orthopaedic association National joint replacement registry. *J Bone Joint Surg Am* 2021;103:1900–5.
- [4] Kurmis AP. Retained pelvic pin site debris after navigated total hip replacement: masquerading as an early-stage chondrosarcomatous lesion. *J Postgrad Med* 2020;66:215–7.
- [5] Lambers AP, Salim XG, Jennings R, Bucknill AT. Morbidity and safety of iliac crest reference array pins in navigated total hip arthroplasty: a prospective cohort study. *J Arthroplasty* 2018;33:1557–61.
- [6] Kamara E, Berliner ZP, Hepinstall MS, Cooper HJ. Pin site complications associated with computer-assisted navigation in hip and knee arthroplasty. *J Arthroplasty* 2017;32:2842–6.
- [7] Brozovich A, Lionberger DR. Periprosthetic fracture of greater trochanter in total hip replacement stemming from pin site placement in navigation-assisted surgery. *Case Rep Orthop* 2019;2019:1–5. 1945895.
- [8] Snijders T, van Gaalen SM, de Gast A. Precision and accuracy of imageless navigation versus freehand implantation of total hip arthroplasty: a systematic review and meta-analysis. *Int J Med Robot* 2017;13:1–7.
- [9] Donaldson FE, Pankaj P, Simpson AH. Bone properties affect loosening of half-pin external fixators at the pin-bone interface. *Injury* 2012;43:1764–70.
- [10] Kim SJ, Kim SH, Kim YH, Chun YM. Effect of the starting point of half-pin insertion on the insertional torque of the pin at the tibia. *Yonsei Med J* 2015;56:154–9.
- [11] Brockstedt H, Kassem M, Eriksen EF, Mosekilde L, Melsen F. Age- and sex-related changes in iliac cortical bone mass and remodeling. *Bone* 1993;14:681–91.
- [12] Paprosky WG, Muir JM. Intellijoint HIP((R)): a 3D mini-optical navigation tool for improving intraoperative accuracy during total hip arthroplasty. *Med Devices (Auckl)* 2016;9:401–8.
- [13] von Glinski A, Frieler S, Blecher R, et al. The iliac pillar - definition of an osseous fixation pathway for internal and external fixation. *Orthop Traumatol Surg Res* 2020;106:869–75.
- [14] Delmann MM, Strahl A, Muhlenfeld M, et al. High prevalence and under-treatment of osteoporosis in elderly patients undergoing total hip arthroplasty. *Osteoporos Int* 2021;32:1661–8.