

Strangulation of the penis: two case reports

Oleg Banyra¹, Roman Sheremeta², Alexander Shulyak²

¹2nd Lviv Municipal Polyclinic, Lviv, Ukraine

²Danylo Halytsky Lviv National Medical University, Lviv, Ukraine

Article history

Submitted: Jan. 18, 2013

Accepted: April 3, 2013

Correspondence

Alexander Shulyak

6, Boguna Street

Apt. 6, Lviv 79013, Ukraine

phone: +38 06 767 08 952

a.vshulyak@yandex.ua

Till now numerous reports have depicted the different constricting devices (CDs) previously threaded on the penis for obtaining of sexual pleasure or/and prolonged erection. The causes of CD bearing on the penis are sexual or autoerotic actions.

Here we present two cases of successful removal of a metal device from a penis that was associated with trauma grade II according to Bhat et al. The techniques used are also described. In both cases the essential features of successful device removal were its motionless fixation by nippers or vice combined with placing a metal plate under the constricting ring. The CDs were successfully removed without complications.

Key Words: penile strangulation ◊ incarceration ◊ constricting devices

INTRODUCTION

Strangulation of the penis has been firstly reported by Gauthier M. in 1755 [1]. Till now numerous articles have been appeared describing different con-

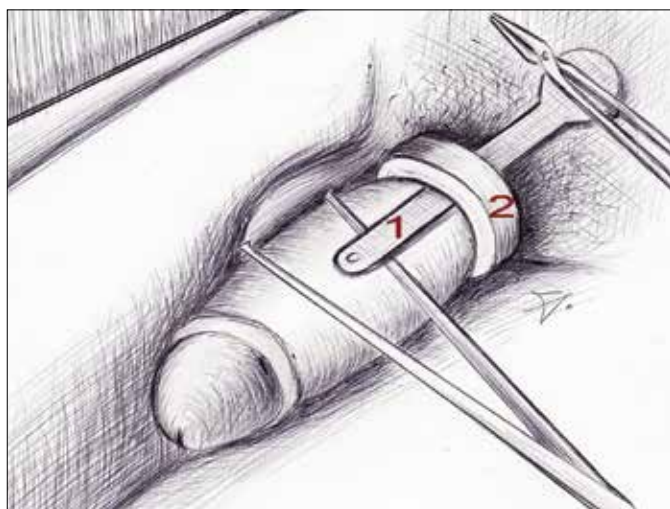


Figure 1. Metal plate (1) was placed under the CD (2). Penal tissues are pulled aside by tweezers to prevent trauma while cutting the metal.

stricting devices (CDs) threaded on the penis to influence blood circulation thereby obtaining prolonged erection and/or sexual pleasure. In a part of patients, different concomitant psychiatric abnormalities were registered [2].

It is known from experience that the presence of various devices on the penis requires their removal. Men and children sometimes use hair rollers, thread, or even the bark from a tree [3–6].

Strangulation of the penis violates the venous and lymphatic return causing distal edema. Patients seek medical help because they themselves cannot take the CDs off.

We present two cases of successful removal of a metal CD from a penis that was associated with trauma grade II according to Bhat et al. grading system. The techniques used are also described [7].

CASE REPORTS

Case 1

In August of 2006, a 45-year old male was admitted to our clinic with complaining of an inability to urinate, and enlargement and tenderness of penis. Eighteen hours before, the patient had put on his pe-

nis a metal ring for the prolongation of erection. Inspection revealed that the metal ring had settled at the base of the penis. The penile tissues were edematous, hyperemic, and cyanotic.

The distal edema did not allow us to use the string technique so it was decided to cut the CD with an angle grinder equipped with a diamond disc.

After local anesthesia, a metal plate was inserted between the skin and the ring to allow pushing aside the penile tissue outwards from the CD and rotating the ring to prevent injury. Tweezers were used for protection of the penis too (Figure 1).

Both ends of the metal plate were manually fixed by nippers to remain motionless throughout the procedure (Figure 2). The gradual cutting of the ring surface by means of angle grinder was performed. The metal proved to be hard and required a long cutting time. During the first 20 minutes of the procedure we managed to make only a few superficial scratches on the supporting base of the bearing. The bearing box was irrigated with cold water in order to reduce its temperature. Approximately 25 liters of water were used (Figure 2).

At the end of the 1st hour of the procedure, inspection of the ring revealed a furrow that proved the possibility of achieving a successful result. After the 2nd hour of CD destruction the upper part was completely cut. The CD was then cut at the opposite side, which completely released the penis (Figures 3, 4).

Penile pulsation was defined once 10 minutes after device removal.

The patient's condition after the procedure remained satisfactory without hemorrhages, burns, or injury of the penile tissues. He was able to micturate within 30 minutes of CD removal. The swelling and tenderness decreased by the 2nd day following the



Figure 2. Cutting the CD by means of angle grinder.

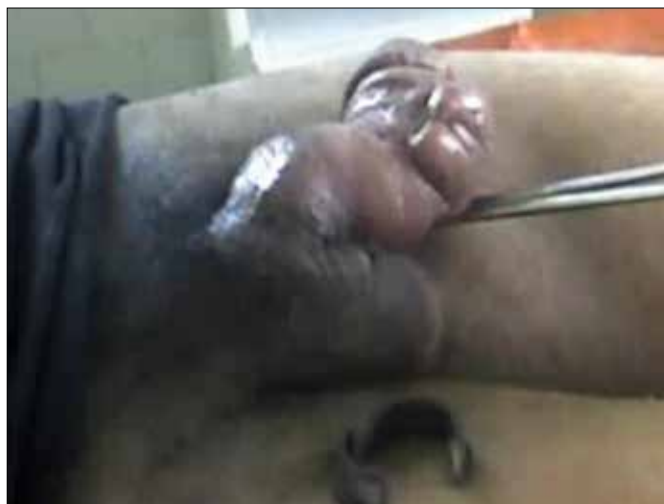

Figure 3. Bearing box has been removed from the penis.



Figure 4. Any signs of hemorrhages, burns, injury of the penile tissues were registered. Penile edema was present until the 2nd day after CD removal.

procedure. The patient complained only of mild paresthesia at the *glans penis* and urethra. After one month he had no complaints of micturition problems or sexual disorders.

Case 2

Another patient, a 69 y.o.m. was treated in the early 90s. For prolongation of erection he put a metal ring made from alloy steel on his penis. After intercourse he fell asleep and was awoken in the middle of the night because of genital pain. The ring was placed nine hours before presenting to the doctor.

At the time of inspection the penis was enlarged, edematous, and contained a metal ring with rounded edges strangulating the penis at the base.

As in the first case a significant distal edema did not allow us to use the string technique for CD removal. After diagnosis attempts to saw the ring off included first the use of a file followed by a small hand saw. However, because the CD was made from an alloy material the cutting instruments were sliding on its surface. After that the decision to use a mechanical diamond-tooth circular saw was made. The procedure was performed under local anesthesia.

Again, the metal ring was fixed by small vice to remain motionless throughout the procedure. Afterwards, two angular cuts were made in diametrically opposite points of the CD. In order to protect the penis from the cutting blade a metal plate was placed between ring and penile tissues. The procedure length was approximately 25 minutes. Short breaks were taken to prevent excessive heating of the ring during sawing. This time the cooling irrigation used only five liters of water.

Penile pulsation was defined once after device removal and micturition was resumed.

Thirty-two hours after the procedure the penis became almost normal, although patient complained of hypoesthesia at the *glans penis* and dysuria.

In both cases the essential features of successful metal CD removal were their motionless fixation by tweezers or vice combined with insertion of a metal plate under the CD to avoid damaging the penis in case the cutting instruments slipped out of the cutting plane. No complications were observed after the procedures, which is why the patients did not require a special follow-up.

DISCUSSION

Penile incarceration with different objects is a rare but constant worldwide occurrence [8, 9].

Depending on the *status localis*, in 1991, Bhat et al. presented an excellent original classification for penile incarceration composed of 5 grades [7]:

I. Distal edema only;

II. Distal edema, skin and urethral trauma, corpus spongiosum compression, decreased penile sensation;

III. Skin and urethral trauma, no distal sensation;

IV. Separation of corpus spongiosum, urethral fistula, corpus cavernosum compression, no distal sensation;

V. Gangrene, necrosis, or distal penile amputation.

Basing on this classification it is possible to evaluate the severity of complications that occurred after incarceration as well as to determine the treatment tactic.

Treatment techniques for penile incarceration can generally be divided into four groups: the string technique and its variants, with and without aspiration of blood from the glans; aspiration techniques; cutting devices; and surgery [10]. The technique chosen is influenced by the characteristics of the CD and grade of trauma [8]. In the presented cases the string technique was not suitable because of the significant distal edema of the penises.

Due to the kind of CD and industrial grade of steel used in its creation, various cutting devices are used because the manual cutters are often insufficient. The choice of the tool depends not only on the inventiveness of the surgeons, but also on the equipment available, size/thickness of the metallic object, and grade of penile injury [2]. To avoid damaging the surrounding edematous tissues, a protecting device made from different materials should be placed under the surface of CD. We used a metal plate as the protecting device.

Thermal burns from the mechanical frictions of sawing and drilling are commonly prevented with cool water irrigation or water sprays [7, 8]. In the first presented case we used significantly more cooling water than in the second because the duration of the first procedure was much longer.

CONCLUSIONS

Cutting of the constricting ring is an effective method for the treatment of penile incarceration. In cases with significant distal edema, the string technique is not feasible – a cutting device approach should be considered as a method of choice.

The motionless fixation of the constricting ring during its cutting and the placement of other protective devices are necessary to avoid trauma to the penile tissues by the cutting saw. A water-cooling irrigation should be used to prevent skin burns.

Such cases of penile strangulation may be prevented by physician consultation regarding appropriate methods for the prolongation and maintenance of an erection.

References

1. Gauthier M. Observation d'un étranglement des testicules et de la verge, occasionné par le passage d'un briquet. *J Med Chir Pharmacol.* 1755; 3: 358.
2. Jain S, Gupta A, Singh T, Aggarwal N, Sharma S, Jain S. Penile strangulation by a hard plastic bottle: a case report. *Indian J. Surg.* 66:173–175.
3. Shah S. Long-standing penile strangulation by a thread leading to urethral constriction. 2009, Available at: bjui.org
4. Okeke LI. Thread embedded into penile tissue over time as an unusual hair thread tourniquet injury to the penis: a case report. *J Med Case Rep.* 2008; 2: 230.
5. Dar NR, Siddiqui S, Qayyum R, Ghafoor T. Hair coil strangulation—an uncommon cause of penile edema. *Pediatr Dermatol.* 2007; 24: E33–35.
6. Bhat AL, Saxena G, Goyal R, Patni M. A rare foreign body on penis leading to incarceration. *Int Urol Nephrol.* 2001; 32: 399–401.
7. Bhat AL, Kumar A, Mathur SC, Gangwal KC. Penile strangulation. *Br J Urol* 1991; 68: 618–21.
8. Snoy FJ, Wagner SA, Woodside JR, Orgel MG, Bordem TA. Management of penile incarceration. *Urology.* 1984; 24: 18–20.
9. Ivanovski O, Stankov O, Kuzmanoski M, Saidi S, Banev S, Filipovski V, et al. Penile strangulation: two case reports and review of literature. *J Sex Med.* 2007; 4: 1775–1778.
10. Detweiler M. Penile Incarceration with Metal Objects *Scand J Urol Nephrol.* 2001; 35 212–217. ■